

Technical Note

Penetrating thoracic spinal cord injury with ice pick extending into the aorta. A technical note and review of the literature

Rani Nasser, Jonathan Nakhla, Saadat Sharif, Merritt Kinon, Reza Yassari

Department of Neurological Surgery, Montefiore Medical Center/Albert Einstein College of Medicine, New York, USA

E-mail: *Rani Nasser - rani.nasser@gmail.com; Jonathan Nakhla - jonathan.nakhla@gmail.com; Saadat Sharif - sshariff@montefiore.org;

Merritt Kinon - mkinon@montefiore.org; Reza Yassari - ryassari@montefiore.org

*Corresponding author

Received: 21 March 16 Accepted: 02 May 16 Published: 09 November 16


Abstract

Background: Penetrating spinal cord injuries pose a great challenge to both patients and the treating physicians. Although the overall incidence of penetrating spinal cord injury is the highest in the military, the ubiquity of guns in our society continues to make penetrating spinal cord injury prevalent in the civilian population. These types of injuries are particularly complicated because, beyond the trauma to the neural elements and supporting structures, other organs can be affected and a team approach is required for successful treatment.

Case Description: In this report, the authors present a unique case of an ice pick penetrating posteriorly through the spinal canal into the aorta. The described surgical management involved careful consideration and planning to prevent worsening vascular and neurological compromise. Among the challenges faced are neurological compromise, vascular injury, spinal instability, and cerebrospinal fluid leak.

Conclusion: To the author's knowledge, this challenging case represents the first description of a successful removal of a penetrating thoracic spinal foreign body that terminated within the lumen of the thoracic aorta.

Key Words: Aorta, penetrating trauma, thoracic spine, vascular injury

Access this article online
Website: www.surgicalneurologyint.com
DOI: 10.4103/2152-7806.193729
Quick Response Code:


INTRODUCTION

Penetrating spinal cord injuries pose a great challenge to both patients and the treating physicians. Although the overall incidence of penetrating spinal cord injury is the highest in the military, the ubiquity of guns in our society continues to make penetrating spinal cord injury prevalent in the civilian population. These types of injuries are particularly complicated because, beyond the trauma to the neural elements and supporting structures, other organs can be affected and a team approach is required for successful treatment. Among the challenges faced are neurological compromise, vascular injury, spinal instability and cerebrospinal fluid

(CSF) leak; the latter has been shown to be as high as 36% in patients status after removal of the penetrating foreign bodies.^[18] In this report, the authors present a unique case of an ice pick penetrating posteriorly

This is an open access article distributed under the terms of the Creative Commons Attribution-NonCommercial-ShareAlike 3.0 License, which allows others to remix, tweak, and build upon the work non-commercially, as long as the author is credited and the new creations are licensed under the identical terms.

For reprints contact: reprints@medknow.com

How to cite this article: Nasser R, Nakhla J, Sharif S, Kinon M, Yassari R. Penetrating thoracic spinal cord injury with ice pick extending into the aorta. A technical note and review of the literature. *Surg Neurol Int* 2016;7:S763-6. <http://surgicalneurologyint.com/Penetrating-thoracic-spinal-cord-injury-with-ice-pick-extending-into-the-aorta.-A-technical-note-and-review-of-the-literature/>

through the spinal canal into the aorta. The described surgical management involved careful consideration and planning to prevent worsening vascular and neurological compromise. To the author's knowledge, this challenging case represents the first description of a successful removal from this location.

CASE PRESENTATION

A 34-year-old male presented as a trauma after he was assaulted with an ice pick. On presentation, he was an American Spinal Injury Association (ASIA) score C; the motor exam of the lower extremities demonstrated full strength in the right leg and weakness in the left leg; based on the MRC scale, the patient was 2/5 in the proximal and 3/5 in the distal muscle groups. His bowel and bladder function and sensation to light touch and pinprick remained intact. There was a small skin puncture site slightly asymmetric to the right in the lower thoracic spine that was identified as the entry point. A computed tomography (CT) scan demonstrated an 8 cm hyperdense foreign body, consistent with an ice pick fragment, entering the right T10 lamina with an upward and medial trajectory [Figure 1]. The foreign body then traversed the spinal canal and thoracic spinal cord, penetrated the T9 thoracic vertebral, entered the left chest cavity, and perforated the descending thoracic aorta [Figure 2].

Given the patient's neurologic status and concern for worsening vascular injury, a decision was made to take the patient to the operating room to repair the breach in the aorta and remove the retained ice pick. A multidisciplinary team consisting of neurosurgery, vascular surgery, and cardiothoracic surgery was formed, and the treatment plan consisted of endovascular repair of the aortic injury and removal of the ice pick from the aorta. The patient was positioned in a "lazy" left lateral decubitus position to allow access to the groins and the back. Although the foreign body was eccentric to the right, placing the position on the left would allow the cardiothoracic surgeons access to the aorta, in the event an endovascular solution was unsuccessful. Vascular surgery first gained bilateral access to the common femoral arteries under ultrasound guidance. A thoracic pigtail catheter was

placed from the right side to image the descending thoracic aorta. A 12-French sheath was placed in the left common femoral artery in preparation for occlusion of the thoracic aorta with a Coda balloon if the patient became hemodynamically unstable. The aorta was measured and sized using the previous CT of the chest and a Cook TX2 28 × 80 mm graft was deemed appropriate for the repair of the aorta. First, an aortogram was performed via the pigtail catheter that showed no active extravasation of contrast from the entry site. The endograft was then advanced from the left side and positioned at T9. Once the endograft was in place, neurosurgery began exposing the foreign body. A paramedian incision that incorporated the entry site was made and the tract of the foreign body was followed to the spinous process of T10. A subperiosteal dissection was done and the foreign body was localized at its entry point in to the lamina medial to the spinous process. A circumferential exposure required drilling of the surrounding bone structures to optimize access to the foreign body. The distal end of the ice pick was then removed with a large thoracic sternal needle driver [Figure 3]. As the foreign body was removed, the vascular surgery team deployed the thoracic stent graft. A completion angiogram of the descending thoracic aorta was performed which showed no evidence of extravasation or endoleak.

After securing the aortic injury, we examined the entry point of the ice pick. CSF was leaking posteriorly through the lamina with Valsalva maneuvers. A fat graft and fibrin sealant were placed over the defect. Special care was taken to minimize the dead space during the closure of the muscle and fascial layers. A lumbar drain was placed at the L4/L5 interspace with caution not to engage the level of the spinal cord injury with the catheter. A chest tube was placed by CT surgery to address the hemothorax; however, the chest tube was purposefully left closed for a few hours before the drainage was started to avoid creating an anterior CSF fistula. The patient was extubated on postoperative day 1, with improvement of his neurological examination (4/5 in all muscle groups of the left lower extremity). The lumbar drain was clamped 48 hours postoperatively and was removed after verifying that there was no leak from the incision site posteriorly. The patient had an uncomplicated hospital stay and was

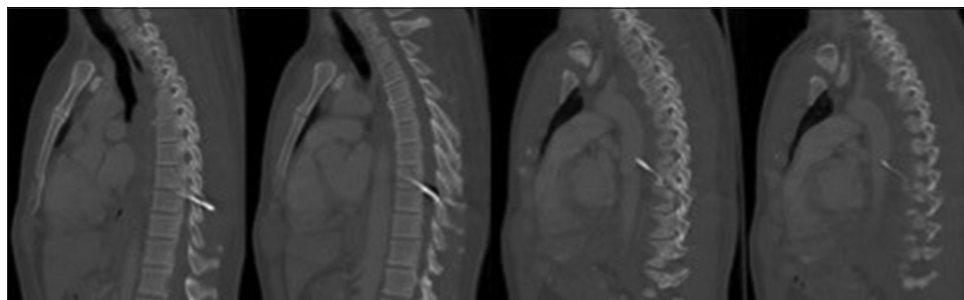


Figure 1: Sagittal computed tomography with contrast of the thorax demonstrating an 8 cm linear foreign body extending through the spinal canal and terminating in the lumen of the descending thoracic aorta

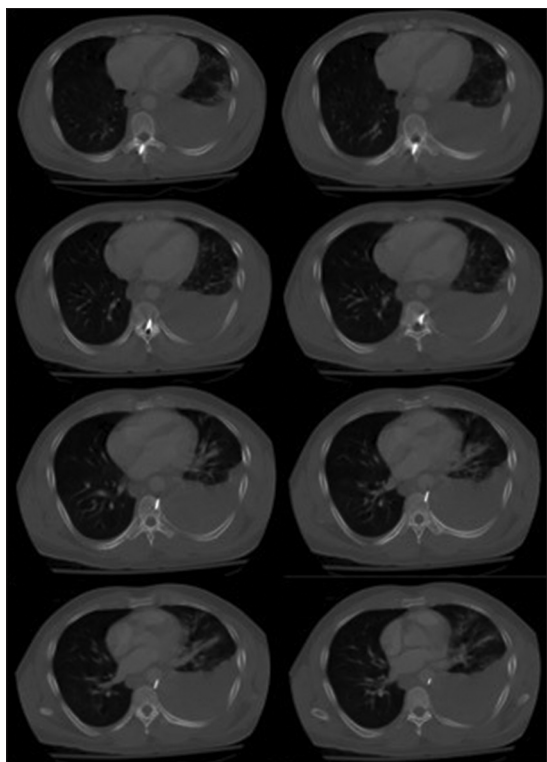


Figure 2: Axial computed tomography angiogram of the thorax demonstrating an 8 cm linear foreign body extending through the spinal canal and terminating in the lumen of the descending thoracic aorta. Also note a left hemothorax

discharged on postoperative day 6 with a normal motor exam except for the left extensor hallucis longus and dorsiflexion at 5-/5.

DISCUSSION

The overall mortality of penetrating spinal cord injury in the military has been on the decline; during World War I, the mortality rate was 71.8% whereas by the end of the Vietnam War the rate had decreased to 2.3%.^[6,9] However, the high incidence of non-military use of fire arms in the United States, make these types of injuries common place in emergency rooms across the United States. Eighty four percent of the victims were men and the National Spinal Cord Injury Database had a mean age of 29.7 years for victims of penetrating spinal cord injury.^[14,16] The management of these injuries can vary. In a series performed by the US Military, laminectomy was advocated for patients with an incomplete spinal cord injury.^[8] Conservative management of penetrating spinal cord injuries was described by Lipschitz and Block among 130 patients with penetrating injuries.^[10] In their series, 27% of patients were discharged with complete recovery and returned to their prior occupations without having had any surgical intervention.^[10] Moreover, 53% of patients who underwent conservative management after spinal cord injury had a partial recovery and were

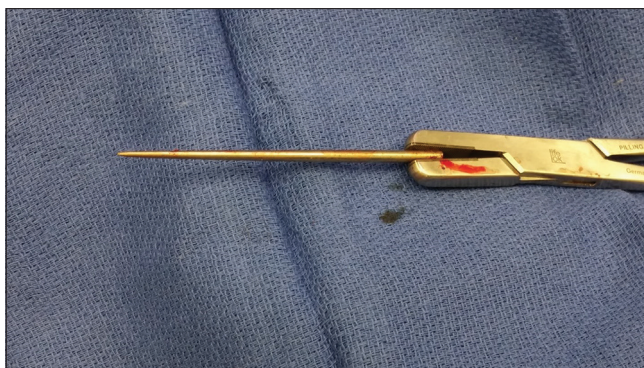


Figure 3: The 8 cm foreign body identified to be an ice pick

able to obtain employment.^[10] According to Harrington *et al.*, approximately one-third of the patients who suffered from penetrating trauma to the spine remained paraplegic.^[3]

In our case, the foreign body was an ice pick which was 3.8 cm deep from the skin, adjacent to the T10 spinous process. Although the patient had an incomplete spinal cord injury, a laminectomy was not performed. The authors believed that the foreign body could be accessed and retrieved without removing the lamina. Furthermore, care was taken to minimize the tissue dissection to minimize the dead space for potential CSF collections. The need to surgically explore the trauma site of a penetrating injury remains controversial. While the basis to intervene largely depends on the patient's hemodynamic status and neurological function, there are other factors that may compel surgeons to surgically explore. Gulamhuseinwala *et al.* described such factors as CSF leak and extrinsic cord compression to help guide management.^[5] If an intervention is indicated, the timing of the intervention may have clinical consequences. Manzone *et al.* retrospectively reported that early extraction of a foreign body in penetrating spinal injury may reduce incidences of myelopathy, infection, and delayed neurological deficits.^[11]

Imaging studies are necessary to appropriately assess and manage instances of penetrating spinal cord injury. Careful consideration must be made using X-ray/CT or CT myelogram. Any unidentified ferromagnetic fragments may pose additional risk to the patient, and the risk of an MRI needs to be assessed.^[13] Furthermore, foreign bodies may be occult on X-ray/CT and MRI. Gul *et al.* described a case of a wooden foreign body penetrating the spine that had characteristics which probably made identification difficult.^[4]

In penetrating spinal injuries with associated CSF leaks, it is advisable to promptly start broad spectrum antibiotics to prevent meningitis.^[18] In the present case, broad spectrum antibiotics were administered for 72 hours, until the lumbar drain was removed and there was no concern

for CSF leak. Thakur *et al.* retrospectively described a meningitis rate of 18% in non-missile penetrating spinal cord injury.^[18] If the CSF leak is persistent or a CSF fistula has formed, surgical exploration may be warranted.^[8]

The use of steroids (methylprednisolone) in patients with penetrating spinal cord injury have been shown to have an adverse outcome in the National Acute Spinal Cord Injury II trial,^[15] and were not used in this case.

An injury to the thoracic aorta by any etiology can be fatal due to the immediate massive hemorrhage in the mediastinal and intrathoracic cavity.^[1] We debated whether to proceed with an open or an endovascular approach to repair the defect in the aorta. However, balloon occlusion of the proximal aorta prior to the removal of the penetrating ice pick substantially decreased the risk for massive hemorrhage.^[1] Furthermore, according to Xenos *et al.*, endovascular repair of the thoracic aorta appears to have lower mortality compared to an open approach. Specifically, spinal cord ischemia is less likely with a minimally invasive endovascular approach.^[19] The primary comparison between open and endovascular therapy involved in the analysis was repair of a descending thoracic aortic aneurysms.^[19] In concert with endovascular techniques decreasing spinal cord morbidity, lumbar drainage has also been shown to reduce the potential for cord ischemia.^[2] Of concern during thoracolumbar injury is the artery of Adamkiewicz. This important branch of the aorta supplies the lower two-thirds of the spinal cord through the anterior spinal artery.^[17] The artery of Adamkiewicz is found 73% of the time between T8 and T10.^[12] In the present case, the penetrating injury occurred at T9-T10, which was statistically in proximity to the artery of Adamkiewicz. Prior to the endovascular deployment of the endograft, an angiogram was performed to help visualize and avoid occlusion of the artery of Adamkiewicz, as described by Kamada *et al.*^[7] With this in mind, the endograft was safely deployed with no changes in neurological monitoring. After the foreign body was removed, neurophysiological monitoring was also helpful in surveying a possible compression from an intraspinal, subdural, or epidural hematoma. Upon successful extubation, the patient was followed clinically very closely. The patient was admitted to the intensive care unit for hourly neurological checks to assess a possible neurological decline secondary to a compressive hematoma.

CONCLUSION

The mortality and morbidity from penetrating spinal cord injury remains a challenging and difficult to treat condition in trauma patients. This case illustrates how

advancement in endovascular treatment minimizes the surgical trauma to the patient and allows for a safe and successful removal of an otherwise potentially fatal problem. The optimal treatment strategy is often assessed on a case-by-case basis and most often requires a multidisciplinary team approach.

Financial support and sponsorship

Nil.

Conflicts of interest

There are no conflicts of interest.

REFERENCES

1. Biffi WL, Fox CJ, Moore EE. The role of REBOA in the control of exsanguinating torso hemorrhage. *J Trauma Acute Care Surg* 2015;78:1054-8.
2. Bischoff MS, Di Luozzo G, Griep RB, Griep RB. Spinal cord preservation in thoracoabdominal aneurysm repair. *Perspect Vasc Surg Endovasc Ther* 2011;23:214-22.
3. Gentleman D, Harrington M. Penetrating injury of the spinal cord. *Injury* 1984;16:7-8.
4. Gul S, Dusak A, Songur M, Kalayci M, Acikgoz B. Penetrating spinal injury with a wooden fragment: A case report and review of the literature. *Spine* 2010;35:E1534-6.
5. Gulamhuseinwala N, Terris J. Evolving presentation of spinal canal penetrating injury. *Injury* 2004;35:948-9.
6. Jacobs GB, Berg RA. The treatment of acute spinal cord injuries in a war zone. *J Neurosurg* 1971;34 (2 Pt 1):164-7.
7. Kamada T, Yoshioka K, Tanaka R, Makita S, Abiko A, Mukaida M, *et al.* Strategy for thoracic endovascular aortic repair based on collateral circulation to the artery of Adamkiewicz. *Surg today* 2015 [Epub ahead of print].
8. Klimo P Jr, Ragel BT, Rosner M, Gluf W, McCafferty R. Can surgery improve neurological function in penetrating spinal injury? A review of the military and civilian literature and treatment recommendations for military neurosurgeons. *Neurosurg Focus* 2010;28:E4.
9. Lee KH, Lin JS, Pallatroni HF, Ball PA. An unusual case of penetrating injury to the spine resulting in cauda equina syndrome: Case presentation and a review of the literature. *Spine* 2007;32:E290-3.
10. Lipschitz R, Block J. Stab wounds of the spinal cord. *Lancet* 1962;2:169-72.
11. Manzone P, Domenech V, Forlino D. Stab injury of the spinal cord surgically treated. *J Spinal Disord* 2001;14:264-7.
12. N'da H A, Chenin L, Capel C, Havet E, Le Gars D, Peltier J. Microsurgical anatomy of the Adamkiewicz artery-anterior spinal artery junction. *Surg Radiol Anat* 2015 [Epub ahead of print].
13. Offiah C, Twigg S. Imaging assessment of penetrating craniocerebral and spinal trauma. *Clin Radiol* 2009;64:1146-57.
14. Peacock WJ, Shrosbree RD, Key AG. A review of 450 stabwounds of the spinal cord. *S Afr Med J* 1977;51:961-4.
15. Prendergast MR, Saxe JM, Ledgerwood AM, Lucas CE, Lucas WF. Massive steroids do not reduce the zone of injury after penetrating spinal cord injury. *J Trauma* 1994;37:576-9.
16. Stover SL, Fine PR. The epidemiology and economics of spinal cord injury. *Paraplegia* 1987;25:225-8.
17. Takase K, Sawamura Y, Igarashi K, Chiba Y, Haga K, Saito H, *et al.* Demonstration of the artery of Adamkiewicz at multi-detector row helical CT. *Radiology* 2002;223:39-45.
18. Thakur RC, Khosla VK, Kak VK. Non-missile penetrating injuries of the spine. *Acta Neurochir* 1991;113 (3-4):144-8.
19. Xenos ES, Minion DJ, Davenport DL, Hamdallah O, Abedi NN, Sorial EE, *et al.* Endovascular versus open repair for descending thoracic aortic rupture: Institutional experience and meta-analysis. *Eur J Cardiothorac Surg* 2009;35:282-6.