

OPEN

# Reversible Severe Eosinophilic Endomyocardial Fibrosis During Pregnancy

## A Case Report

Marc Pineton de Chambrun, MD, Philippe Charron, MD, PhD, Danièle Vauthier-Brouzes, MD, Philippe Cluzel, MD, PhD, Julien Haroche, MD, PhD, Jean-Emmanuel Kahn, MD, PhD, Zahir Amoura, MD, MSc, and Fleur Cohen Aubart, MD, PhD

### INTRODUCTION

**Abstract:** Idiopathic hypereosinophilic syndrome (HES) is a condition of unknown origin characterized by clinical manifestations attributable to eosinophilia and eosinophilic infiltration of tissues. Cardiac involvement is rare and threatening accounting for 33% to 43% of death in HES. Management of pregnant patients with HES is challenging and have rarely been reported, particularly in the setting of heart failure.

We here report on the case of a 29-year-old woman with HES who developed severe endomyocardial fibrosis with heart failure during pregnancy. Outcome was favorable under treatment with prednisone and azathioprine.

This case illustrates a favorable outcome of endomyocardial fibrosis during pregnancy.

(*Medicine* 94(32):e1307)

**Abbreviations:** FIP1L1 = factor interacting with PAPOLA and CPSF1, HES = hypereosinophilic syndrome, JAK2 = janus kinase 2, LV = left ventricle, MRI = magnetic resonance imaging, NYHA = New York Heart Association, PDGFRA =  $\alpha$ -type platelet-derived growth factor receptor, WA = week of amenorrhea.

Editor: Anastasios Lymperopoulos.

Received: May 28, 2015; revised and accepted: June 22, 2015.

From the Service de Médecine Interne 2 (MPdC, JH, ZA, FCA), Institut E3M, Centre National de Référence Lupus Systémique, Syndrome des Anticorps Anti-Phospholipides et Maladies Auto-Immunes Systémiques Rares, Hôpital de la Pitié-Salpêtrière, Assistance Publique-Hôpitaux de Paris, France; Université Pierre et Marie Curie (MPdC, DV-B, PCluzel, JH, ZA, FCA), Sorbonnes Universités, Paris, France; Centre de Référence Maladies Cardiaques Hérititaires (PCharron), ICAN, Inserm UMR\_1166, Hôpital de la Pitié-Salpêtrière, Assistance Publique-Hôpitaux de Paris, Paris, France; Université de Versailles-Saint Quentin (PCharron), Hôpital Ambroise Paré, Assistance Publique-Hôpitaux de Paris, Boulogne-Billancourt, France; Service de Gynécologie Obstétrique (DV-B), Hôpital de la Pitié-Salpêtrière, Assistance Publique-Hôpitaux de Paris, Paris, France; Département d'Imagerie Cardiovasculaire et de Radiologie Interventionnelle (PCluzel), Hôpital de la Pitié-Salpêtrière, Assistance Publique-Hôpitaux de Paris, Paris, France; Institut National de la Santé et de la Recherche Médicale (PCluzel), INSERM-CNRS-LIB, Paris, France; Service de Médecine Interne (JEK), Hôpital Foch, Suresnes, France; and French Eosinophil Network (JEK), Institut d'Immunologie, Université de Lille, Lille, France.

Correspondence: Fleur Cohen Aubart, Service de Médecine Interne 2, Institut E3M, Hôpital de la Pitié-Salpêtrière, 47-83 Boulevard de l'Hôpital, 75651-Paris Cedex 13, France (e-mail: fleur.cohen@psl.aphp.fr).

The authors have no funding and conflicts of interest to disclose.

Copyright © 2015 Wolters Kluwer Health, Inc. All rights reserved.

This is an open access article distributed under the Creative Commons Attribution-NonCommercial-NoDerivatives License 4.0, where it is permissible to download, share and reproduce the work in any medium, provided it is properly cited. The work cannot be changed in any way or used commercially.

ISSN: 0025-7974

DOI: 10.1097/MD.0000000000001307

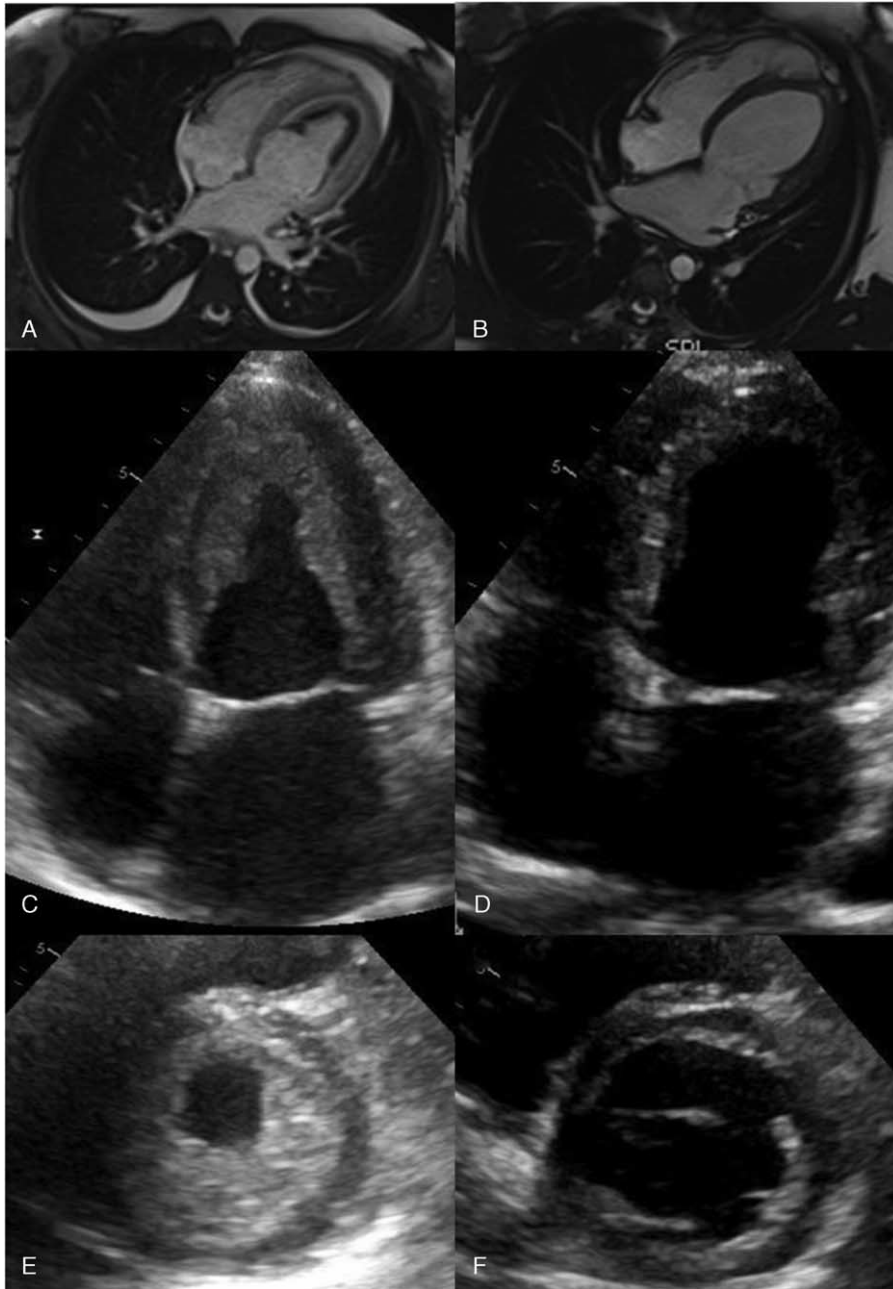
Idiopathic hypereosinophilic syndrome (HES) is a condition of unknown origin characterized by clinical manifestations attributable to eosinophilia and eosinophilic infiltration of tissues. Cardiac involvement is rare and threatening accounting for 33% to 43% of death in HES. Management of pregnant patients with HES is challenging and rarely been reported, particularly in the setting of heart failure.

### CASE REPORT

A 29-year-old woman returning from Saint Martin Island presented in April 2013 with dyspnea and chest pain, which were then diagnosed as clinically suspected eosinophils-associated myocarditis because of pulmonary edema, elevated troponin, and high eosinophils blood count. She received 3 pulses of steroids and was also treated with 2 doses of ivermectine as *Strongyloides* serology was positive. In July 2013, troponin dosage, eosinophils blood count, echocardiography, and cardiac magnetic resonance imaging (MRI) were normal.

In December 2013, when she was pregnant with 18 weeks of amenorrhea (WA), she was admitted to the intensive cardiology unit department for respiratory distress. Electrocardiogram was normal but chest x-ray was consistent with pulmonary edema. Blood tests showed elevated ultrasensitive troponin: 139 ng/mL ( $N < 0.14$ ), NT-proBNP: 3350 ng/L, and markedly increased circulating eosinophils at  $4.75 \times 10^9/L$ . Renal and liver tests were normal. A transthoracic echocardiogram revealed hyperkinetic left ventricular with subtotal thrombotic occlusion of left ventricle (LV) (Figure 1C and E). Systolic pulmonary artery pressure was elevated at 75 mm Hg. Cardiac MRI revealed diffuse LV endomyocardial fibrosis with circumferential intraventricular adherent LV thrombus (Figure 1A). No extra-cardiac involvement (i.e., neurological, pulmonary, cutaneous, or gastrointestinal) was detected. Screening for all etiology of secondary or clonal eosinophilia was negative including extended lymphoid phenotyping, janus kinase 2 mutation (JAK2), and factor interacting with PAPOLA and CPSF1 (FIP1L1)- $\alpha$ -type platelet-derived growth factor receptor (PDGFRA) transcript fusion testing. Bone marrow biopsy was also normal despite marked eosinophil infiltration. The diagnosis of idiopathic hypereosinophilic syndrome (HES)-associated severe endomyocardial fibrosis was suspected.

Symptomatic treatment included diuretics, low-dose  $\beta$ -blockers, and curative anticoagulation with enoxaparin. Three intravenous pulses of 1 g methylprednisolone were administered followed by 1 mg/kg/d of oral prednisone. She quickly improved, keeping a class III New York Heart Association (NYHA) dyspnea. Despite persistent severe postcapillary pulmonary hypertension, pregnancy was continued. One month later, echocardiography was stable and eosinophils were still at



**FIGURE 1.** (A) Four-chamber view during cine acquisition after gadolinium injection shows subendocardial enhancement of the left ventricle (LV) with a large adherent thrombus inside the ventricular cavity. (B) Remission after treatment. (C and E) Echocardiogram findings during heart failure. Apical and parasternal short-axis view reveal subtotal occlusion of LV with thrombus. Dynamic studies revealed hyperkinetic LV with high ejection fraction. (D and F) Echocardiogram findings 6 month after delivery showing complete disappearance of LV thrombus and normal LV ejection fraction.

1.0 g/L (Figure 2). Azathioprine was introduced (2 mg/kg/d) and steroids were progressively tapered down.

At 35 WA, she underwent a C-section because of fetal heart rate abnormalities. The newborn's weight was 1900 g (between 10th and 25th percentile), and birth blood pH and lactate were 7.26 and 3 mmol/L, respectively. Early outcome was favorable for the mother and the baby. Under azathioprine, 6 months after delivery, she was asymptomatic, and eosinophils blood count as well as echocardiography and cardiac MRI had normalized (Figure 1).

## DISCUSSION

Here we described a case of severe eosinophilic endomyocardial fibrosis occurring during pregnancy. Under treatment with steroids and azathioprine, despite severe pulmonary hypertension, pregnancy had a favorable outcome. Six months after delivery, the patient had fully recovered from endomyocardial fibrosis.

Acquired eosinophilia is classified as secondary (parasitic, drug-induced, vasculitis, ...), clonal (myeloid or lymphoid

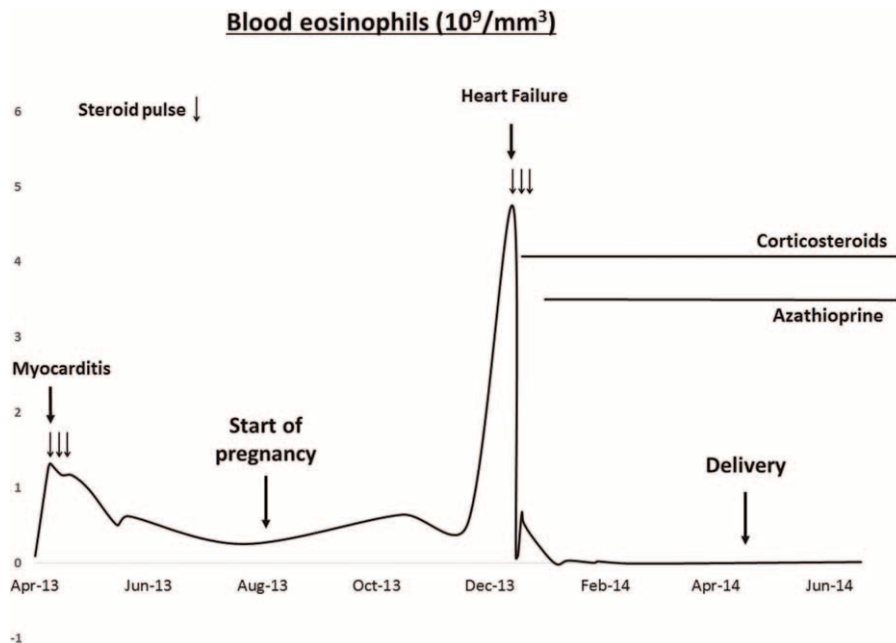


FIGURE 2. Eosinophils blood count evolution during pregnancy.

malignancies, . . .), or idiopathic. After exclusion of secondary causes of eosinophilia, a stepwise diagnostic algorithm should include peripheral blood screening for FIP1L1–PDGFRA transcript fusion, bone marrow biopsy, JAK2 mutation testing, peripheral blood lymphocytes phenotyping, and T-cell receptor gene rearrangement studies in order to discard clonal causes of eosinophilia. The diagnostic of HES can be advocated in case of negativity of all the test cited above.<sup>1</sup> Cardiac involvement of HES is rare and life-threatening, accounting for 33% to 43% of deaths, with a frequency reported from 5% to 72%.<sup>2–4</sup>

Treatment of chronic acquired eosinophilia strongly depends on whatever the cause of eosinophilia. In clonal eosinophilia, treatment mainly consists of kinase inhibitor. In HES, corticosteroids remain the first-line treatment and corticosteroid-sparing agents nowadays mainly rely on hydroxyurea, interferon- $\alpha$ , or cyclosporine. Despite a promising preliminary study, mepolizumab and other anti-interleukin-5 antibodies have not been approved in this setting. No specific drugs have been advocated in cardiac involvement of HES except for heart failure treatment and anticoagulation therapy because of the high frequency of intracardiac thrombus. The use of azathioprine as a corticosteroid-sparing agent for HES has been only anecdotally reported without clear information about its efficacy.<sup>4</sup>

Only 3 cases of pregnancy during HES have been reported, all with favorable outcomes.<sup>5–7</sup> Two patients were treated with steroids (maintenance doses between 20 and 25 mg/d) and the last one was left untreated. One of those patients had a cardiac involvement consisting in right and LV thrombus but without cardiac failure. Cardiac MRI was not performed because of pregnancy.

Our patient suffered from a particularly severe cardiac manifestation of HES during pregnancy. Steroids allowed quick improvement but the patient still complained of NYHA III dyspnea. The persistence of pulmonary hypertension and elevated circulating eosinophils counts led us to introduce a corticosteroid-sparing agent, namely, azathioprine, because of the safety profile during pregnancy. Outcome was good for the mother and baby.

Six months after delivery, echocardiography and cardiac MRI confirmed full resolution of interventricular thrombus with regression of endomyocardial fibrosis.

In conclusion, even in a severe cardiac involvement of HES, pregnancy can successfully be conducted using steroids and azathioprine. This study has been approved by the ethics committee: Comité de Protection des Personnes (CPP) “Ile-de-France VI,” Hôpital Pitié-Salpêtrière, Paris, France.

### ACKNOWLEDGMENTS

The authors would like to thank Professor David Grant for his help in editing the manuscript.

### REFERENCES

- Tefferi A, Gotlib J, Pardanani A. Hypereosinophilic syndrome and clonal eosinophilia: point-of-care diagnostic algorithm and treatment update. *Mayo Clin Proc.* 2010;85:158–164.
- Podjasek JC, Butterfield JH. Mortality in hypereosinophilic syndrome: 19 years of experience at Mayo Clinic with a review of the literature. *Leuk Res.* 2013;37:392–395.
- Rothenberg ME, Klion AD, Roufosse FE, et al. Treatment of patients with the hypereosinophilic syndrome with mepolizumab. *N Engl J Med.* 2008;358:1215–1228.
- Ogbogu PU, Bochner BS, Butterfield JH, et al. Hypereosinophilic syndrome: a multicenter, retrospective analysis of clinical characteristics and response to therapy. *J Allergy Clin Immunol.* 2009;124:1319–1325.
- Ault P, Cortes J, Lynn A, et al. Pregnancy in a patient with hypereosinophilic syndrome. *Leuk Res.* 2009;33:186–187.
- Darki A, Kodali PP, McPheters JP, et al. Hypereosinophilic syndrome with cardiac involvement in a pregnant patient with multiple sclerosis. *Tex Heart Inst J.* 2011;38:163–165.
- Albrecht AE, Hartmann BW, Kurz C, et al. Idiopathic hypereosinophilic syndrome and pregnancy. *Acta Obstet Gynecol Scand.* 1997;76:485–486.