

## Research Article



# Morphological characteristics of the mesiobuccal root in the presence of a second mesiobuccal canal: a micro-CT study

Lucas P. Lopes Rosado ,<sup>1</sup> Matheus Lima Oliveira ,<sup>1</sup> Karla Rovaris ,<sup>2</sup>  
Deborah Queiroz Freitas ,<sup>1</sup> Frederico Sampaio Neves <sup>1,3</sup>

<sup>1</sup>Department of Oral Diagnosis, Division of Oral Radiology, Piracicaba Dental School, University of Campinas (UNICAMP), Piracicaba, São Paulo, Brazil

<sup>2</sup>Department of Pathology and Dentistry Clinic, School of Dentistry, Federal University of Piauí (UFPI), Teresina, Piauí, Brazil

<sup>3</sup>Department of Propeudetics and Integrated Clinic, Division of Oral Radiology, School of Dentistry, Federal University of Bahia (UFBA), Salvador, Bahia, Brazil



**Received:** Feb 2, 2021

**Revised:** Mar 21, 2021

**Accepted:** Apr 1, 2021

**Published online:** Jan 18, 2022

Rosado LPL, Oliveira ML, Rovaris K, Freitas DQ, Neves FS

### \*Correspondence to

Lucas P. Lopes Rosado, DDS, MSc. Ph.D  
Student

Department of Oral Diagnosis, Division of Oral Radiology, Piracicaba Dental School, University of Campinas (UNICAMP), Av. Limeira, 901, Piracicaba, São Paulo 13414-903, Brazil.  
Email: lucaslopesrosado@gmail.com

Copyright © 2022. The Korean Academy of Conservative Dentistry

This is an Open Access article distributed under the terms of the Creative Commons Attribution Non-Commercial License (<https://creativecommons.org/licenses/by-nc/4.0/>) which permits unrestricted non-commercial use, distribution, and reproduction in any medium, provided the original work is properly cited.

### Funding

This study was financed in part by the Coordenação de Aperfeiçoamento de Pessoal de Nível Superior - Brasil (CAPES) - Finance Code 001.

### Conflict of Interest

No potential conflict of interest relevant to this article was reported.

<https://rde.ac>

## ABSTRACT

**Objectives:** This study investigated the internal morphology of mesiobuccal (MB) roots of maxillary molars with a second mesiobuccal (MB2) canal.

**Materials and Methods:** Forty-seven maxillary first or second molars from Brazilians were scanned using micro-computed tomography. The following measurements were obtained from the MB roots: root thickness, root width, and dentin thickness of the buccal aspect of the first mesiobuccal (MB1) canal, between the MB1 and MB2 canals, and the palatal aspect of the MB2 and MB1 canals at 3 mm from the root apex and in the furcation region. For statistical analysis, the Student's *t*-test and analysis of variance with the *post-hoc* Tukey test were used ( $\alpha = 0.05$ ).

**Results:** In maxillary molars with an MB2 canal, MB roots were significantly thicker ( $p = 0.0014$ ) and narrower ( $p = 0.0016$ ) than in maxillary molars without an MB2 canal. The dentin thickness of the palatal aspect of the MB1 canal was also significantly greater than that of MB roots without an MB2 canal at 3 mm from the root apex ( $p = 0.0007$ ) and in the furcation region ( $p < 0.0001$ ). In the furcation region of maxillary molars with an MB2 canal, the dentin thickness between the MB1 and MB2 canals was significantly smaller than that in the buccal and palatal aspects ( $p < 0.0001$ ).

**Conclusions:** The internal morphology of MB roots of maxillary molars with an MB2 canal revealed differences in dentin thickness, root diameter, and distance between the canals when compared with maxillary molars without an MB2 canal.

**Keywords:** Anatomy; Maxillary molar; Mesiobuccal root; Micro-computed tomography; Root canal






## INTRODUCTION

Recent studies in the scientific literature have reported a high percentage of failure to fill second mesiobuccal (MB2) canals during endodontic treatment of maxillary molars [1-

**Author Contributions**

Conceptualization: Rosado LPL, Oliveira ML, Rovaris K, Freitas DQ, Neves FS. Data curation: Freitas DQ, Neves FS. Formal analysis: Rosado LPL, Rovaris K. Funding acquisition: Rosado LPL, Oliveira ML, Rovaris K, Freitas DQ, Neves FS. Investigation: Rosado LPL, Oliveira ML, Rovaris K. Methodology: Rosado LPL, Oliveira ML, Rovaris K. Project administration: Freitas DQ, Neves FS. Resources: Rosado LPL, Oliveira ML, Rovaris K. Software: Rosado LPL. Supervision: Freitas DQ, Neves FS. Validation: Rosado LPL, Oliveira ML. Visualization: Rosado LPL, Oliveira ML, Rovaris K. Writing - original draft: Rosado LPL, Oliveira ML. Writing - review & editing: Freitas DQ, Neves FS.

**ORCID iDs**

Lucas P. Lopes Rosado   
<https://orcid.org/0000-0003-1327-4724>  
Matheus Lima Oliveira   
<https://orcid.org/0000-0002-8054-8759>  
Karla Rovaris   
<https://orcid.org/0000-0003-2179-6282>  
Deborah Queiroz Freitas   
<https://orcid.org/0000-0002-1425-5966>  
Frederico Sampaio Neves   
<https://orcid.org/0000-0001-9178-707X>

3]. The most likely reason for this finding is the high prevalence of MB2 canals, which are associated with a wide variety of configurations of the internal anatomy of the mesiobuccal (MB) root [4,5]. When both first mesiobuccal (MB1) and MB2 canals are present, they may have single or separate orifices on the pulp chamber floor and may also merge at some point or remain independent throughout the MB root of maxillary molars. An MB2 canal may also be underneath a dentin shelf or calcifications in a small groove. These factors can make it difficult for clinicians to detect MB2 canals [4-6].

Because of the different configurations of the MB root, the presence of an MB2 canal can be expected to be related to additional anatomical variations, which—depending on their complexity—can limit the cleaning, shaping, and, consequently, filling of the root canal system and compromise the success of endodontic treatment [7]. Accurate detection and treatment of MB2 canals can prevent pain after endodontic treatment, as well as sinus tract formation, gingival swelling, and periapical bone destruction [7,8].

Because of these factors, previous studies have focused on the canal configuration, number of canals, presence of accessory canals and isthmuses, and apical delta of MB roots in maxillary molars [9-13]. Another study evaluated the dentin thickness in the danger and safety zones in MB roots of maxillary molars with an MB2 canal [14]. Those studies all reported a high prevalence of MB2 canals (greater than 50%) in the maxillary first and second molars. Despite those important findings, it remains unclear in the literature whether the presence of an MB2 canal affects the anatomical aspects of the tooth; an answer to this question would have a positive clinical impact on endodontic treatment planning. To verify possible morphological differences in the MB root, a study needs to include both teeth with and without an MB2 canal, but research with this design is missing in the literature. Therefore, the aim of this study was to assess and compare the internal morphological characteristics of the MB root in teeth with and without an MB2 canal.

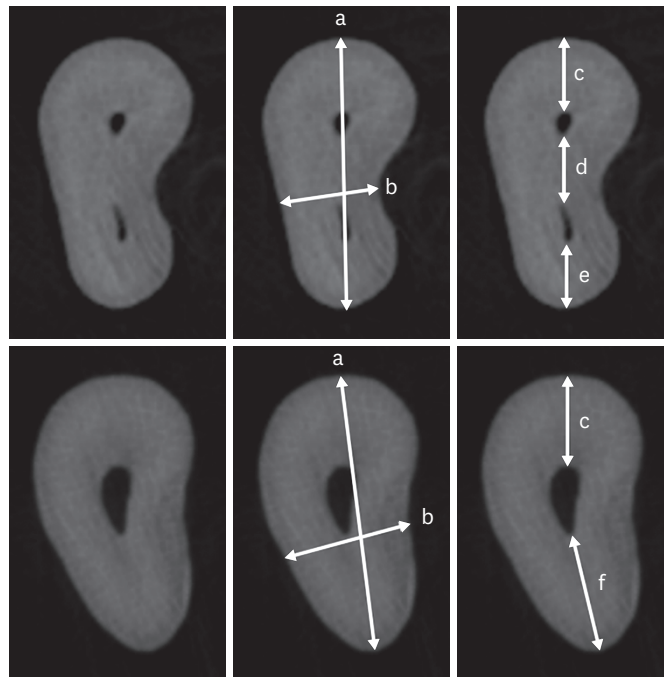
## **MATERIALS AND METHODS**

This study was conducted after being approved by the local Institutional Review Board (protocol number: 10727319.9.0000.5418). Forty-seven maxillary first or second molars from Brazilians were selected and individually scanned using a Bruker 1174 micro-computed tomography (micro-CT) unit (Bruker, Kontich, Belgium). The age and sex of the tooth donors were unknown. An MB2 canal was present in 26 molars of the sample. The acquisition parameters were 800  $\mu$ A, 50 kV, an aluminum filter of 0.5 mm, 1 frame averaging, rotation step of 0.5°, arch rotation of 180°, scan time of 45 minutes, and a voxel size of 31.03  $\mu$ m. The volumes were reconstructed using the NRecon software (Bruker) and reoriented to vertically align the long axis of the molar using the Dataviewer software (Bruker).

### **Image assessment**

From axial reconstructions at 3 mm from the apex of the MB root, the following linear measurements were obtained (**Figure 1**):

- a. Root thickness: largest bucco-palatal extension of the MB root, measured from the outermost point of the buccal aspect of the root to the outermost point of the palatal aspect of the root;

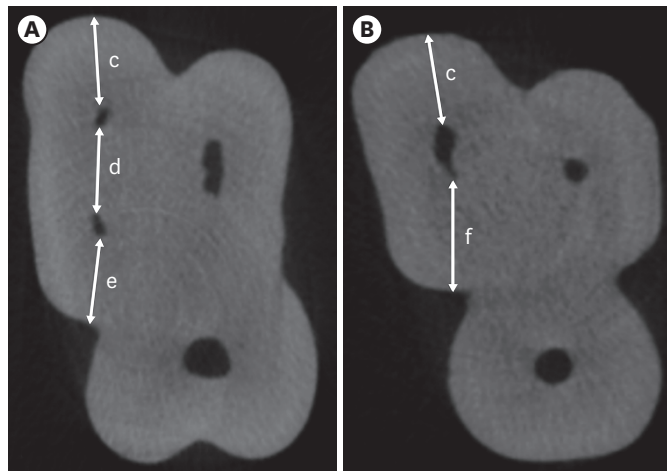


**Figure 1.** Cropped micro-CT axial sections at 3 mm from the apex of the mesiobuccal root with (upper row) and without an MB2 canal (lower row). For better visualization, the same root is shown in triplicate. (a) Root thickness, (b) Root width, (c) MB1 buccal segment, (d) MB1-MB2 segment, (e) MB2 palatal segment, (f) MB1 palatal segment.

CT, computed tomography; MB, mesiobuccal.

- b. Root width: shortest mesio-distal extension of the MB root, measured in the central region of the root from the innermost point of the mesial aspect of the root to the innermost point of the distal aspect of the root;
- c. MB1 buccal segment: dentin thickness in the buccal aspect of the MB1 canal, measured from the outermost point of the buccal aspect of the MB1 canal to the outermost point of the buccal aspect of the root;
- d. MB1-MB2 segment (only when an MB2 canal is present): dentin thickness between the MB1 and MB2 canals, measured from the outermost point of the MB1 canal towards the MB2 canal to the outermost point of the MB2 towards the MB1 canal;
- e. MB2 palatal segment (only when an MB2 canal is present): dentin thickness in the palatal aspect of the MB2 canal, measured from the outermost point of the palatal aspect of the MB2 canal to the outermost point of the palatal aspect of the root;
- f. MB1 palatal segment (only when an MB2 canal is absent): dentin thickness in the palatal aspect of the MB1 canal, measured from the outermost point of the palatal aspect of the MB1 canal to the outermost point of the palatal aspect of the root.

Measurements c–f were also performed in axial reconstructions at 1.5 mm from the floor of the pulp chamber towards the furcation, as proposed by Harris *et al.* [15] (**Figure 2**).



**Figure 2.** Cropped axial sections of measurements taken from the furcation region of maxillary molars with an MB2 canal (A) and without an MB2 canal (B). (c) MB1 buccal segment, (d) MB1-MB2 segment, (e) MB2 palatal segment, (f) MB1 palatal segment. MB, mesiobuccal.

All measurements were performed in triplicate by an oral and maxillofacial radiologist with more than 3 years of experience in micro-CT using the CTAn software (Bruker, Kontich, Belgium) and averaged. Ninety days after the evaluation was completed, 25% of the sample was reevaluated to test the intra-examiner agreement.

### Statistical analysis

Statistical analyses were performed using SPSS (version 24.0, IBM Corp., Armonk, NY, USA) with a level of significance of 5% ( $\alpha = 0.05$ ). To assess intra-examiner agreement, the intraclass correlation coefficient (ICC) was calculated for each measurement studied. The Shapiro-Wilk test showed a normal data distribution for all measurements ( $p > 0.05$ ), and parametric tests were used. The Student's *t*-test was used to compare the MB root thickness and width between maxillary molars with and without an MB2 canal. The Student's *t*-test was also used to assess possible differences in the dentin thickness of the MB1 buccal and palatal segments between maxillary molars with and without an MB2 canal. In maxillary molars with an MB2 canal, the MB1 palatal segment resulted from the sum of the MB1-MB2 and MB2 palatal segments. One-way analysis of variance with the *post-hoc* Tukey was also used to compare the fraction (as a percentage) of the dentin thickness of the buccal, MB1-MB2, and palatal segments in relation to the total MB root thickness of teeth with the MB2 canal at the 2 axial levels.

## RESULTS

The intra-rater reliability measured by the ICC of all measurements performed on each group of teeth (with and without an MB2 canal), showed almost perfect agreement, ranging from 0.988 to 0.999.

**Table 1** shows the mean values of the MB root thickness and width. Maxillary molars with an MB2 canal showed significantly greater MB root thickness ( $p = 0.0014$ ) and significantly smaller MB root width ( $p = 0.0016$ ) than molars without an MB2 canal.

**Table 1.** Mean (variance) values of the MB root thickness and width in maxillary molars with and without an MB2 canal

Measurement	MB2 canal		p value
	With	Without	
Root thickness	5.18 (0.81)	4.30 (0.42)	0.0014
Root width	2.05 (0.20)	2.55 (0.34)	0.0016

Student's *t*-test, power analysis (0.05) = 0.9656.  
MB, mesiobuccal.

**Table 2.** Mean (variance) values of the MB1 buccal and palatal segments in maxillary molars with and without an MB2 canal

Axial level	Root segment	MB2 canal		p value
		With	Without	
3 mm from the apex	MB1 buccal	1.44 (0.10)	1.58 (0.12)	0.1314
	MB1 palatal	2.55 (0.58)*	1.94 (0.12)	0.0007
Furcation region	MB1 buccal	2.14 (0.11)	2.32 (0.13)	0.0850
	MB1 palatal	3.73 (0.33)*	2.84 (0.20)	< 0.0001

Student's *t*-test; power analysis (0.05) = 0.9995.  
MB, mesiobuccal.

\*Sum of the MB1-MB2 and MB2 palatal segments.

**Table 2** shows the mean values of the MB1 buccal and palatal segments at the 2 axial levels evaluated. In the presence of an MB2 canal, the MB1 palatal segment, which resulted from the sum of the MB1-MB2 and MB2 palatal segments, was significantly longer than in the absence of the MB2 canal at 3 mm from the root apex ( $p = 0.0007$ ) and in the furcation region ( $p < 0.0001$ ). The presence of an MB2 canal did not influence the MB1 buccal segment.

**Table 3** shows the mean, variance, minimum, and maximum values of dentin thickness in teeth with and without an MB2 canal at the 2 axial levels evaluated. The MB1-MB2 segment was quite variable, with dentin thicknesses ranging from 0.29 to 3.48 at 3 mm from the apex and from 0.32 to 2.79 in the furcation region. Furthermore, the dentin thickness of the MB2 palatal segment in relation to that of the MB1 buccal segment in maxillary molars with an MB2 canal was smaller at 3 mm from the apex and greater in the furcation region.

**Table 4** shows the fraction (in percentage) of dentin thickness of the MB root segments in relation to the total root thickness of teeth with an MB2 canal at 3 mm from the apex and in the furcation region. Only in the furcation region, the dentin thickness of the MB1-MB2 segment was significantly smaller than those of the buccal and palatal segments ( $p < 0.0001$ ), which were not significantly different from each other ( $p = 0.271$ ).

**Table 3.** Mean, variance, minimum, and maximum values of dentin thickness at 2 axial levels of teeth with and without an MB2 canal

MB2 canal	Axial level	Root segment	Mean	Variance	Minimum	Maximum
With	3 mm from the apex	MB1 buccal	1.44	0.10	0.90	2.08
		MB1-MB2	1.33	0.65	0.29	3.48
		MB2 palatal	1.26	0.22	0.25	2.06
	Furcation region	MB1 buccal	2.14	0.11	1.28	2.88
		MB1-MB2	1.56	0.53	0.32	2.79
		MB2 palatal	2.29	0.23	1.64	3.59
Without	3 mm from the apex	MB1 buccal	1.58	0.12	1.00	2.11
		MB1 palatal	1.94	0.12	1.23	2.60
	Furcation region	MB1 buccal	2.32	0.13	1.66	3.09
		MB1 palatal	2.84	0.20	2.17	3.64

MB, mesiobuccal.

**Table 4.** Fraction (as a percentage) of dentin thickness of MB root segments in relation to the total root thickness of teeth with an MB2 canal at 2 axial levels

Axial level	Root segment			p value
	MB1 buccal	MB1-MB2	MB2 palatal	
3 mm from the apex	0.35 (0.09)	0.33 (0.15)	0.32 (0.11)	0.2710
Furcation region	0.36 (0.05) <sup>A</sup>	0.26 (0.10) <sup>B</sup>	0.38 (0.07) <sup>A</sup>	< 0.0001

One-way analysis of variance; values followed by different letters are significantly different between the root segments (horizontal comparisons).

Power analysis (0.05) = 0.90.

MB, mesiobuccal.

## DISCUSSION

Cases of unsuccessful endodontic treatment involving the MB root in maxillary molars have become a topic of concern due to the frequent association between persistent lesions and unfilled MB2 canals [1-3]. Therefore, in this study, we aimed to assess the morphological characteristics of MB roots with and without an MB2 canal, which, to the best of our knowledge, have not been investigated. Interestingly, most of the measurements obtained in the present study were significantly different in the presence of an MB2 canal, and we believe that these findings can positively contribute to treatment planning, as they shed light on some challenging conditions in the presence of an MB2 canal.

The assessment of the MB root thickness (*i.e.*, the largest bucco-palatal extension) suggested that the presence of an MB2 canal is associated with expansion of the MB root in this direction. Furthermore, unlike our previous hypothesis, the dentin thickness in the buccal aspect of the MB1 was not reduced in the presence of the MB2 canal, which seems to be primarily related to palatal overextension of the MB root as a consequence of a significant increase in the MB1-MB2 and palatal dentin segments. This results in an oval shape of the axial aspect of the MB root, instead of a round shape when an MB2 canal is absent.

Based on our findings related to the MB root width (*i.e.*, the shortest mesio-distal extension), the absence of a single central canal when an MB2 canal is present may contribute to narrowing in this region. This can be indicative of the presence of an MB2 canal and should be taken into account by clinicians when evaluating cone-beam computed tomography (CBCT) findings. In challenging cases when an MB2 canal is not detected even with CBCT, a non-centralized location of the MB1 associated with a narrowed central region may suggest the presence of an MB2 canal. However, it is important to remember that exposing all patients to a preoperative CBCT examination without a precise indication may not be appropriate because of the biological risks associated with X-rays. In such cases, making use of an examination previously acquired for other purposes should be considered as a way to detect an MB2 canal [16].

Another important result of the present study is that the MB1 and MB2 canals were closer to each other at the furcation level than at 3 mm from the apex, a region where the teeth had a similar dentin thickness of root segments. This is in line with our findings that dentin thickness of both the buccal and palatal segments was greater in the furcation, which confirms the close spatial relationship between the canals in this region. Furthermore, these results seem to explain the complexity related to the clinical detection of MB2 canals. Due to the proximity between MB1 and MB2 canals, clinicians can often overlook the presence of an MB2 canal, resulting in a relatively high frequency of unfilled MB2 canals in endodontically treated teeth [1-3].

Recent studies have shown that the amount of dentin removed during endodontic treatment depends on the endodontic instrument used in the preparation and shaping of MB1 and MB2 canals [17,18]. Therefore, dentists should pay special attention to this issue and consider our finding that the dentin thickness in the buccal aspect of an MB1 canal was reduced regardless of the presence of an MB2 canal. Another relevant finding of the present study was that the dentin thickness of the buccal and palatal segments in both canals (MB1 and MB2) was smaller at 3 mm from the apex than in the furcation region. Given this fact, the use of an instrument causing greater dentin wear can lead to a considerable loss of structure in this region, which has been described as an important etiological factor for the occurrence of vertical root fracture [19].

In this study, we chose not to divide teeth into first and second molars because our objective was to assess whether the presence of an MB2 canal could be associated with the presence of morphological changes in the MB root without observing other factors. Since this was a pioneering study comparing teeth with and without an MB2 canal, we chose not to take into account the tooth type. Furthermore, because the 2 groups (with and without an MB2 canal) were composed of first and second molars, they could be compared to each other. Furthermore, the power analysis for all tests was fairly high, reinforcing the reliability of our results. Nevertheless, future studies comparing the morphological characteristics of the MB2 canal of different tooth types are recommended.

In this present study, 2 reconstructions were standardized across the sample using a previous study as a reference [15] to avoid a situation where the examiner would choose reconstructions without clear criteria. These 2 axial reconstructions (at 3 mm from the apex and 1.5 mm from the pulp chamber floor towards the furcation) were chosen because we wanted to conduct between-group comparisons in a region corresponding to the beginning of the root and in a region around the middle third of the root or below that point. Regions above that point were avoided because they are very close to the furcation.

The main objective of this study was to analyze MB roots in the presence and absence of an MB2 canal to identify patterns that clinicians should be aware of when making use of CBCT exams. Although micro-CT scans are not performed in living patients, this imaging modality delivers ultra-high-resolution images, which allowed us to precisely test our hypotheses that the presence of an MB2 canal would be related to important anatomical changes in the MB root.

Despite the relevance of the present results, the lack of information related to the sex and age of the tooth donors is a limitation. Thus, future studies should take these factors into account for a better investigation of additional relevant elements influencing the morphological characteristics of MB2 canals. Because this study was performed in a Brazilian population, caution is needed when extrapolating our results to different populations. Therefore, future studies evaluating different anatomical configurations, measurements, and analyses in teeth from other populations are encouraged.

## CONCLUSIONS

The presence of an MB2 canal in maxillary first and second molars was found to be related to important variations in the internal morphology of the MB root, such as differences in dentin thickness, root diameter, and distance between the canals in the MB root when

compared with maxillary molars without an MB2 canal. Thus, a careful assessment of the morphological characteristics of the MB root may aid in MB2 canal detection.

## REFERENCES

1. Karabucak B, Bunes A, Chehoud C, Kohli MR, Setzer F. Prevalence of apical periodontitis in endodontically treated premolars and molars with untreated canal: a cone-beam computed tomography study. *J Endod* 2016;42:538-541.  
[PUBMED](#) | [CROSSREF](#)
2. Nascimento EHL, Gaêta-Araujo H, Andrade MFS, Freitas DQ. Prevalence of technical errors and periapical lesions in a sample of endodontically treated teeth: a CBCT analysis. *Clin Oral Investig* 2018;22:2495-2503.  
[PUBMED](#) | [CROSSREF](#)
3. do Carmo WD, Verner FS, Aguiar LM, Visconti MA, Ferreira MD, Lacerda MF, Junqueira RB. Missed canals in endodontically treated maxillary molars of a Brazilian subpopulation: prevalence and association with periapical lesion using cone-beam computed tomography. *Clin Oral Investig* 2021;25:2317-2323.  
[PUBMED](#) | [CROSSREF](#)
4. Tomaszewska IM, Jarzębska A, Skinningsrud B, Pękala PA, Wroński S, Iwanaga J. An original micro-CT study and meta-analysis of the internal and external anatomy of maxillary molars-implications for endodontic treatment. *Clin Anat* 2018;31:838-853.  
[PUBMED](#) | [CROSSREF](#)
5. Martins JNR, Alkhawas MAM, Altaki Z, Bellardini G, Berti L, Boveda C, Chaniotis A, Flynn D, Gonzalez JA, Kottoor J, Marques MS, Monroe A, Ounsi HF, Parashos P, Plotino G, Ragnarsson MF, Aguilar RR, Santiago F, Seedat HC, Vargas W, von Zuben M, Zhang Y, Gu Y, Ginjeira A. Worldwide analyses of maxillary first molar second mesiobuccal prevalence: a multicenter cone-beam computed tomographic study. *J Endod* 2018;44:1641-1649.e1.  
[PUBMED](#) | [CROSSREF](#)
6. Das S, Warhadpande MM, Redij SA, Jibhkate NG, Sabir H. Frequency of second mesiobuccal canal in permanent maxillary first molars using the operating microscope and selective dentin removal: a clinical study. *Contemp Clin Dent* 2015;6:74-78.  
[PUBMED](#) | [CROSSREF](#)
7. Estrela C, Holland R, Estrela CR, Alencar AH, Sousa-Neto MD, Pécora JD. Characterization of successful root canal treatment. *Braz Dent J* 2014;25:3-11.  
[PUBMED](#) | [CROSSREF](#)
8. Sipavičiūtė E, Manelienė R. Pain and flare-up after endodontic treatment procedures. *Stomatologija* 2014;16:25-30.  
[PUBMED](#)
9. Somma F, Leoni D, Plotino G, Grande NM, Plasschaert A. Root canal morphology of the mesiobuccal root of maxillary first molars: a micro-computed tomographic analysis. *Int Endod J* 2009;42:165-174.  
[PUBMED](#) | [CROSSREF](#)
10. Verma P, Love RM. A Micro CT study of the mesiobuccal root canal morphology of the maxillary first molar tooth. *Int Endod J* 2011;44:210-217.  
[PUBMED](#) | [CROSSREF](#)
11. Degerness RA, Bowles WR. Dimension, anatomy and morphology of the mesiobuccal root canal system in maxillary molars. *J Endod* 2010;36:985-989.  
[PUBMED](#) | [CROSSREF](#)
12. Kim Y, Chang SW, Lee JK, Chen IP, Kaufman B, Jiang J, Cha BY, Zhu Q, Safavi KE, Kum KY. A micro-computed tomography study of canal configuration of multiple-canal mesiobuccal root of maxillary first molar. *Clin Oral Investig* 2013;17:1541-1546.  
[PUBMED](#) | [CROSSREF](#)
13. Wolf TG, Paqué F, Woop AC, Willershausen B, Briseño-Marroquín B. Root canal morphology and configuration of 123 maxillary second molars by means of micro-CT. *Int J Oral Sci* 2017;9:33-37.  
[PUBMED](#) | [CROSSREF](#)
14. Ordinola-Zapata R, Martins JNR, Versiani MA, Bramante CM. Micro-CT analysis of danger zone thickness in the mesiobuccal roots of maxillary first molars. *Int Endod J* 2019;52:524-529.  
[PUBMED](#) | [CROSSREF](#)



15. Harris SP, Bowles WR, Fok A, McClanahan SB. An anatomic investigation of the mandibular first molar using micro-computed tomography. *J Endod* 2013;39:1374-1378.  
[PUBMED](#) | [CROSSREF](#)
16. Hiebert BM, Abramovitch K, Rice D, Torabinejad M. Prevalence of second mesiobuccal canals in maxillary first molars detected using cone-beam computed tomography, direct occlusal access, and coronal plane grinding. *J Endod* 2017;43:1711-1715.  
[PUBMED](#) | [CROSSREF](#)
17. van der Vyver PJ, Paleker F, Vorster M, de Wet FA. Root canal shaping using nickel titanium, M-wire, and Gold wire: a micro-computed tomographic comparative study of one shape, ProTaper Next, and WaveOne gold instruments in maxillary first molars. *J Endod* 2019;45:62-67.  
[PUBMED](#) | [CROSSREF](#)
18. Zhang Y, Liu J, Gu Y, Wang J, Xu H, Zhang G. Analysis of second mesiobuccal root canal instrumentation in maxillary first molars with three nickel-titanium rotary instruments: a micro-computed tomographic study. *Odontology* 2021;109:496-505.  
[PUBMED](#) | [CROSSREF](#)
19. Reeh ES, Messer HH, Douglas WH. Reduction in tooth stiffness as a result of endodontic and restorative procedures. *J Endod* 1989;15:512-516.  
[PUBMED](#) | [CROSSREF](#)