

## ELASTIC STABLE INTRAMEDULLARY NAILING FOR FRACTURES IN CHILDREN - PRINCIPLES, INDICATIONS, SURGICAL TECHNIQUE

DANA ELENA VASILESCU, DAN COSMA

Department of Pediatric Surgery and Orthopedics, Iuliu Hatieganu University of Medicine and Pharmacy, Cluj-Napoca, Romania

### *Abstract*

*Elastic stable intramedullary nailing (ESIN) is a minimally invasive technique. According to this technique, two elastic nails are introduced through the metaphysis into the medullary canal, advanced through the fracture site and impacted into the opposite metaphysis. These nails are preformed in a C-shaped manner, which allows for their precise orientation and the creation of an elastic system that resists deformation.*

**Keywords:** fracture, children, intramedullary elastic nailing, minimally invasive technique.

### **Introduction**

The classical approach to the treatment of fractures in children paid particular attention to orthopedic treatment. The bone remodeling capacity in children corrects residual deformations through growth, while the classical methods of osteosynthesis may entail many complications. However, these opinions are not always confirmed by facts. Spontaneous bone remodeling is subject to rules referring to the fracture site, the type and degree of displacement, and the age of the patient. When these conditions are not met, osteosynthesis is needed.

The technical procedures that are currently available for the treatment of adults cannot be applied to children. Plate osteosynthesis requires extensive periosteal stripping, in conditions in which the periosteum plays an essential role in the consolidation of fractures in children. Intramedullary osteosynthesis, with the penetration of the growth cartilage, induces endosteal circulation disorders and severe growth problems, because of epiphysiodesis or growth stimulation through the complete obstruction of the medullary canal [1]. In order to eliminate these inconveniences, elastic intramedullary nailing has been designed and used.

Elastic intramedullary nailing, a minimally invasive technique, confers elastic and stable osteosynthesis. Elastic stable intramedullary nailing (ESIN) consists of introducing 2 elastic nails through the metaphysis into the medullary canal, advancing them through the fracture site and impacting them into the opposite metaphysis. These elastic nails are formed in a C-shaped manner before their application, which allows for their precise orientation and

the creation of an elastic system that resists deformation.

The operative technique is in complete accordance with the principles of minimally invasive surgery. Surgery performed without opening the fracture site permits to maintain the hematoma at the fracture site. Considering that osteosynthesis is carried out by the placement of the nails at a distance from the fracture site, the risk of bacterial contamination is completely eliminated [2].

The choice of the adequate nail diameter allows for micromovements and compression at the fracture site during walking, contributing to the stimulation of consolidation. Fracture consolidation is obtained on account of periosteal callus that has a regular fusiform shape. ESIN enables a short period of hospitalization and rapid recovery, while plaster cast immobilization is usually no longer necessary. Due to the short hospitalization period, the cost of treatment of fractures in children is significantly reduced [3].

Under the conditions of a rigorous use of the technique, with the correct establishment of ESIN indications, the difference in the length of the lower limbs becomes practically absent. On the other hand, due to the minimally invasive nature of the procedure, the use of the fluoroscope is required. Studies performed so far have demonstrated that the radiation dose is equal to or even lower than the one received during classical treatment, by traction-extension and plaster cast.

Thus, the indications of ESIN are diaphyseal and metaphyseal fractures in children, which require internal stabilization or too long plaster cast immobilization periods [2-5].

### **Biomechanics**

Intramedullary nails were intensively used in the treatment of diaphyseal fractures, as a means of

alignment. One or two straight nails introduced into the medullary canal can only have an alignment role. Without an immobilization of the fracture, these nails allow for angulation and translation.

The bending of elastic nails creates more points of contact between the bone and the nails. Thus, elastic nails take the role of maintaining reduction [6].

**Mechanics of the nail-bone unit**

The main characteristic of the metal used for the fabrication of elastic nails is, in addition to biocompatibility, elasticity. If the deformation force exceeds the elasticity limit of the metal, the nail will accumulate a residual deformation that will form a new point of balance, which will be regained in the case of a new deformation below the limit of deformability. This phenomenon allows the preforming of the nail, and additional elastic deformations will enable the nail to regain the desired preformed shape. Due to the bending of the nail, a dynamic situation is created in which the bent nail, in order to penetrate the straight medullary canal, will become straight. From this position, the nail will always tend to regain its initial bent position, exerting a continuous pressure on the bone at the level of each tip and at the level of the curve apex. If there is a bone fracture, the nail will tend to regain its bent position, inducing bone deformation. If two nails with the curve apices oriented in opposite directions are used, the recurring tendencies will annul each other, causing the reduction of the fracture in the balance position [7].

**Stable elasticity**

This mechanical concept allows the configuration obtained through the two elastic nails to oppose the outer deforming forces.

Angulation in the nail plane

The deforming force applied to the configuration in the nail bending plane acts in the direction of increasing the elastic reaction force of one of the nails. In the nail whose curve is parallel to the direction of deformation, the elastic reaction force is reduced through the tendency of regaining the initial (bending) position. In contrast, the nail that straightens will have an increased elastic reaction force, and thus, a new point of balance will be reached, in a slight angulation position. When the deforming force stops, the straightened nail, through the increased reaction force, will restore the initial balance position of the ensemble [7].

Angulation in the plane perpendicular to the nail plane

In the plane perpendicular to the nail plane, the same concept of elastic action and reaction is valid. In this plane, both nails are straight. In the case of the action of a deforming force, the nails are bent, storing elastic energy. When the deforming force stops, this accumulated energy will cause the nails to restraighten and regain the initial balance position [7].

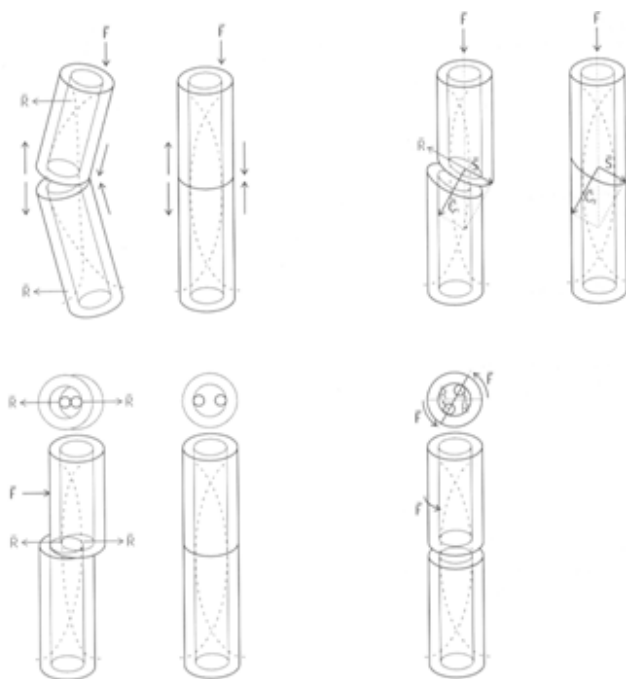
Translation in the nail plane

The elastic force of the nails exerts a constant

pressure inside the medullary canal, at the curve apex. This force opposes the translation tendency of the fragments through the elastic deformation tendency of the curve, in this way preventing deformation at the point of balance [7].

Rotation of fragments

In the case of the rotation of fragments in relation to one another, a torsion deformation force is generated in the ensemble. When this deforming force stops, the elastic energy stored will cause the ensemble to regain its initial balance position [7].



**Figure 1.** Biomechanics of the nail-bone unit: a) stability during angulation; b) stability during translation; c) stability during rotation

**Fixation variants**

In the case when simple fixation with two C-shaped nails does not correct deformation or cannot be achieved for anatomical reasons, alternative fixation variants can be used.

Fixation with an S-shaped nail and a C-shaped nail can reach the balance position when the nails are inserted from the same side.

The elastic reaction forces of the two nails inserted parallel to one another are in the same direction. If one of the nails is rotated by 180°, its elastic force becomes opposite and counterbalances the elastic force of the first. This fixation is less stable than the C-shaped fixation, but is sufficient when deforming forces are not of a high intensity (in the case of the humerus).

There are situations when despite a perfect fixation, a residual deformation at the fracture site persists, due to the outer deforming forces that are higher than the elastic force of the nails. In this case, the two nails can be reoriented so that their concave side opposes residual deformation.

### ***Elastic nails and fracture healing***

Bone consolidation is the main purpose of the use of elastic nails. This aim is rapidly attained and is based on the development of external callus, which is the physiological alternative of consolidation. This callus is rapidly formed and is resistant from the beginning. The development of this type of callus is favored by relative elastic mobility at fracture level and the respect of the biological fracture consolidation principles.

#### ***Elastic mobility at the fracture level***

The term micromovements creates confusion if used indiscriminately in the case of both elastic and rigid osteosynthesis.

Rigid osteosynthesis requires perfect immobilization to induce primary bone consolidation after several months. The finest movements at the fracture site cause osteon breakage, with the delayed formation of internal callus.

In the case of elastic osteosynthesis, micromovements enable the development of external callus starting with the first week. This mobility should be relatively limited so as not to prevent the formation of longitudinal bone bridges between the two fragments. Biomechanical models have demonstrated the ability of elastic nails to convert distraction forces into compression forces and vice versa [2].

#### ***Observance of the biological fracture consolidation principles***

The internal fixation of fractures using elastic nails prevents muscle injury, extensive periosteal stripping, and maintains the vascularization of bone fragments. This type of osteosynthesis favors consolidation by maintaining the integrity of all tissues at the fracture site and preserving post-fracture hematoma, which contains all the factors responsible for the formation of external callus. The role of the periosteum should not be underestimated; its destruction as a result of direct action or massive displacement delays the formation of external callus.

Soft tissues, muscles and tendons in particular, contribute to the stability of the bone-nail unit by 3 factors [7]:

1. rotational stability: muscles and tendons are arranged in a circular manner around the fracture site and act as anchors, limiting angulation and rotation movements;

2. trophic role: the musculature increases bone vascularization and ensures adequate local oxygenation through postoperative contractions. This allows the formation of callus, without an intermediate cartilaginous phase;

3. morphological role: muscle contractions cause the modeling of callus, which initially develops in a disorganized manner, then it becomes fusiform, parallel to the bone axis. This explains the reduced quality of callus developing in patients with neurological disorders.

#### ***Materials***

Implants are represented by elastic nails of different

diameters and lengths, depending on the fractured bone, the fracture level, and the surgeon's preference.

#### ***Choice of implants***

*A sharp or blunt tip?* A blunt tip is preferable in the case of diaphyseal fractures because the insertion of the nails into the medullary canal is relatively easy and is not hindered by bone obstacles. Sharp tip nails are used in the case of metaphyseal fractures, due to the more easy penetration of the epiphyseal bone and to superior anchorage [5].

*Titanium or steel?* Diaphyseal fractures are stabilized by the use of the C-shaped fixation, each nail having 3 points of contact with the bone. Pressure is applied at the level of the proximal and distal metaphysis and at the level of the site fracture. Titanium, which has a higher elasticity modulus compared to steel, is the material of choice in the case of diaphyseal fractures that require a superior elastic reaction force. Metaphyseal fractures are stabilized by 2 elastic nails that diverge in the epiphysis. In this case, elasticity is not the most important factor and this is why steel is preferred in this situation [5].

#### ***Size of the nails***

The nail diameter depends on the medullary canal diameter. The rule for choosing the diameter is the following:  $\phi$  of the nail =  $\phi$  of the medullary canal x 0.4

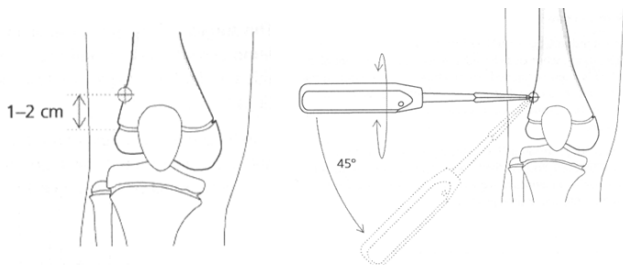
In the case of diaphyseal fractures, the length of the nails is equal to the distance from the entry point to the opposite growth cartilage, plus 2 cm. The ideal length of the nails is equal to the distance between the two opposite growth cartilages, knowing that 2-3 cm of the nail length are left outside the bone to allow for ablation [7].

#### ***Operative technique***

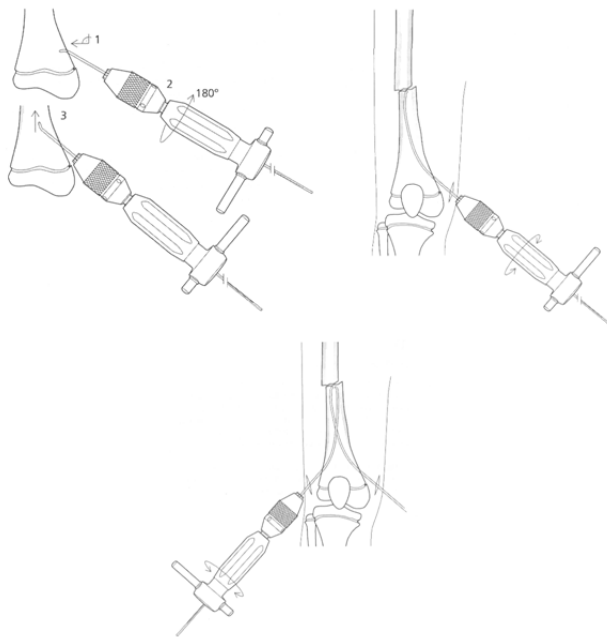
The first stage of this type of osteosynthesis is the obtaining of the closed reduction of the fracture by external manipulation. The limb is then isolated so as to allow the maintenance of the reduction obtained during surgery. Subsequently, the nails with the adequate length and diameter are chosen and formed in a C-shaped manner, so that the maximal curve of approximately 300 is at the same level as the fracture site. When two nails are used for the same bone, the nails should be shaped symmetrically to obtain a good mechanical balance of reduction and stabilizing forces [7].

The classical approach is at the level of the metaphysis, avoiding growth cartilage injury. At this level, an oblique hole with a larger diameter than that of the nails is drilled. If the nails are introduced on the same side, it is preferable to drill two adjacent holes instead of a single large hole that weakens the bone structure. The nail is mounted in a cannulated T-shaped mandrel and inserted into the medullary canal, with the bent tip oriented distally. After having penetrated the medullary canal, the nail is rotated so that its tip is oriented proximally. Progression into the medullary canal is facilitated by the oscillating

rotation movements of the hand piece. Advancement should be easy, without forcing the penetration of the nails with the hammer, which might cause the perforation of the compact bone or even a new fracture [8-10].



**Figure 2.** Choice of the nail insertion site and drilling of holes in the metaphysis



**Figure 3.** Insertion of the nails up to the fracture site

The two nails are advanced symmetrically up to the fracture site. At this point, fracture reduction is performed, after which one of the nails is inserted through the fracture site into the proximal bone fragment. The penetration of both nails into the proximal fragment is fluoroscopically verified, after which their advancement is continued up to the level of the opposite metaphysis. After the fixation of the nails, reduction is checked and if a residual deformation is present, the nails are rotated using the T-shaped piece so that the concave side of the nails opposes deformation [7].

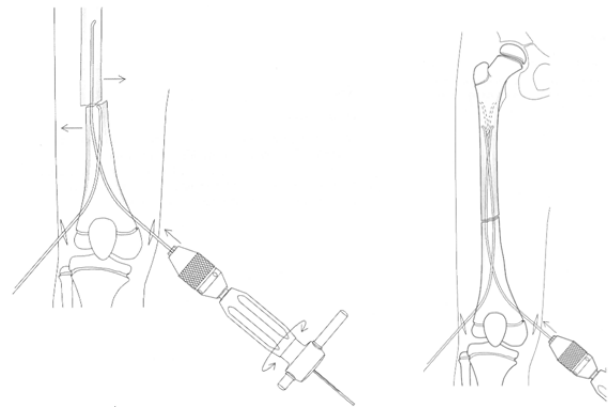
Finally, the nails are impacted using the final impactor, and approximately 2-3 cm of each nail are left outside the bone, so as not to irritate the skin and subcutaneous cell tissue and to allow ablation.

At the end of the intervention, the quality of

reduction is rechecked in AP and LL views.

**Ablation of implants**

The tips of the nails outside the bone are detected and extracted using the nail extractor.



**Figure 4.** Reduction of the fracture and advancement of the elastic nails into the proximal fragment

**References**

1. Papakostidis C, Grotz MR, Papadokostakis G, Dimitriou R, Giannoudis PV. Femoral biologic plate fixation. *Clin Orthop Relat Res.* 2006;450:193-202.
2. Hunter JB. The principles of elastic stable intramedullary nailing in children. *Injury.* 2005;36(suppl 1):20-24.
3. Bader M, Sanz L, Waseem M. Forearm fractures in children: Single bone fixation with elastic stable intramedullary nailing in 20 cases. *Injury.* 2006;37(9):923-924.
4. Salem KH, Lindemann I, Keppler P. Flexible intramedullary nailing in pediatric lower limb fractures. *J Pediatr Orthop.* 2006;26(4):505-509.
5. Berger P, De Graaf JS, Leemans R. The use of elastic intramedullary nailing in the stabilisation of paediatric fractures. *Injury.* 2005;36(10):1217-1220.
6. Kubiak EN, Egol KA, Scher D, Wasserman B, Feldman D, Koval KJ. Operative treatment of tibial fractures in children: are elastic stable intramedullary nails an improvement over external fixation? *J Bone Joint Surg Am.* 2005;87(8):1761-1768.
7. Metaizeau JP. Stable elastic intramedullary nailing for fractures of the femur in children. *J Bone Joint Surg Br.* 2004;86(7):954-957.
8. Fircică A. Elastic intramedullary osteosynthesis for the treatment of metaphysodiaphyseal non-union of the femur and tibia. *Chir Organi Mov.* 1991;76(4):347-353.
9. Fircică A, Troianescu O, Petre M. Osteosynthesis of fractures of the femur with flexible metallic intramedullary nails, *Ital J Orthop Traumatol.* 1978;4(1):23-29.
10. Vasilescu D, Cosma D, Vasilescu D. Particular applications of elastic stable intramedullary nailing (ESIN) for femoral fractures in children, *Jurnalul Pediatrului.* 2005;8(31):51-55.