

Qualitative assessment of the dental groove pattern and its uniqueness for forensic identification

Jyotirmoy Roy,
Muraleedharan M. Rohith,
Debesh Nilendu,
Abraham Johnson
*Laboratory of Forensic
Odontology, Institute of
Forensic Science, Gujarat
Forensic Sciences University,
Gandhinagar, Gujarat, India*

Address for correspondence:

*Dr. Abraham Johnson,
Laboratory of Forensic
Odontology, Institute of
Forensic Science, Gujarat
Forensic Sciences University,
Gandhinagar - 382 007,
Gujarat, India.
E-mail: drabrahamjohnson4000@
yahoo.com*

Introduction


The human dentition has long been used for identification as the dental tissues are the only ones to survive any disasters or events of violence.^[1] The large variation in the morphology of human tooth cannot be easily altered. Thus, the human dentition plays an important role in the forensic identification and it also provides crucial data regarding

the ethnicity and cultural background of an individual.^[2] Over the years, researchers in forensic odontology have been contributing various other parameters to be used for identification purposes, such as lip prints, rugae patterns, and enamel rod patterns.^[3,4] Even the Interpol considers dental records as one of the most reliable parameters for disaster victim identification.^[5]

Abstract

Introduction: Teeth are invaluable in both the living and the deceased for forensic identification and profiling purposes. The occlusal surface patterns in the molars of an individual depend on both intrinsic and extrinsic factors. The individualistic nature of the groove pattern can be used to determine the identity of an individual by the process of comparative identification. **Aim and Objective:** The objective of this study is to determine the uniqueness of the groove pattern among individuals by the means of digital analysis. **Materials and Methods:** An experimental study was conducted on 80 dental casts where the occlusal groove patterns of 1st and 2nd molars from each cast were traced digitally using image analysis software GIMP (v 2.10.6). The traced patterns were then examined to determine their uniqueness. **Results:** The most common groove patterns for the maxillary 1st and 2nd molars were found to resemble “Branched H” and “H”, respectively. “Y” pattern was observed to be the most common in mandibular 1st molar, whereas mandibular 2nd molar most commonly exhibited “+” pattern. No two groove patterns were similar in the analysis. **Conclusion:** Digital method of analysis is preferable over conventional manual methods as it is noninvasive and precise. The individualistic nature of occlusal groove patterns may play an important role in comparative forensic identification.

Key words: Antimere, digital analysis, groove pattern, identification, molars, uniqueness

Access this article online	
Website: www.jfds.org	Quick Response Code 
DOI: 10.4103/jfo.jfds_73_19	

This is an open access journal, and articles are distributed under the terms of the Creative Commons Attribution-NonCommercial-ShareAlike 4.0 License, which allows others to remix, tweak, and build upon the work non-commercially, as long as appropriate credit is given and the new creations are licensed under the identical terms.

For reprints contact: reprints@medknow.com

How to cite this article: Roy J, Rohith MM, Nilendu D, Johnson A. Qualitative assessment of the dental groove pattern and its uniqueness for forensic identification. *J Forensic Dent Sci* 2019;11:42-7.

The patterns of the occlusal surfaces of molars are polygenically conditioned and determined by a combination of allele on two or more sites/loci, and they occur in one of the final stages of molar growth, as a result of the terminal deposition of enamel.^[6] Numerous studies have shown that the genes of the X chromosome regulate the deposition of enamel, whereas genes of the Y chromosome influence the division of the cells involved with the formation of the dentine-enamel bond and enamel deposition.^[7,8]

Previous studies on the occlusal morphology of posterior tooth were conducted from an anthropological point of view to establish the evolutionary trend of the human dentition and to check the prevalence of a specific pattern.^[9,10] In anthropological terms, the same tooth present on the opposite quadrant is known as an antimere,^[11] which though presenting similar anatomy overall, is distinct in its own terms. The occlusal morphology of the molars also heavily depends on various cultural habits and the dietary pattern of an individual.^[12] All the above-mentioned factors make the occlusal morphology of each posterior tooth unique and individualistic in nature.

Photography is inevitably involved with identification. It is considered both as the most common parameter for visual recognition as well as of paramount importance for documentation purposes. With the advent of digitization, photography has become a sophisticated yet easy method to document, record, analyze, and store data. Photography is of great importance in forensics as well, as it provides hassle-free documentation, nondestructive analysis and an easy, long-term medium for the storage of evidence.^[13]

Aim and objectives

The present study aims to establish the uniqueness of the occlusal groove patterns by the means of a noninvasive digital method of analysis and also to determine the prevalence of the occlusal groove pattern of molars in the Gujarati population.

Materials and Methods

A total of 80 dental casts (40 maxillary and 40 mandibular) were obtained with known age and sex from the archives of the Forensic Odontology Laboratory, Institute of Forensic Science, Gujarat Forensic Sciences University, Gujarat, India. Dental casts having intact permanent 1st and 2nd molars on both sides were included in the study. The broken and distorted casts, casts with bubbles, casts showing fractured and destroyed teeth were excluded. Casts presenting restored teeth, reduced teeth, and teeth having the prosthetic crown were also excluded from the study.

All the dental casts were coded in a specific manner and were then photographed using a digital single-lens reflex camera (Canon[®] EOS 1200D) under natural illumination

along with a scale of reference (ABFO #2) using the standard configurations (Aperture size 1/90, focus f/8 and ISO 200). While capturing the images, the long axis of the camera was kept perpendicular to the plane of the object to eliminate any perspective distortion. First, the images were converted to life size before analysis. The image analysis software (GIMP- GNU Image Manipulation Program, Version 2.10.6 (University of California, Berkley) was used to examine the occlusal groove patterns by comparison and superimposition. Later, the groove pattern was selected using the "Free Select" tool, and the traced image was copied to a new layer/working area.

For digital comparison

The traced pattern of two teeth was placed side by side and examined. While comparing the antimeres, the images were flipped horizontally using the option from the image menu. Comparison was based on the nature of the central groove and that of the supplemental grooves. Branching of the grooves was also taken into consideration. The comparison with the same tooth of the other casts was also performed similarly.

For digital superimposition

The traced groove pattern of the tooth under observation was overlapped on its antimere, to assess its orientation; mirror image of the antimere tooth was used for the examination. Results were derived to be matching or not matching based on three parameters are as follows: (1) alignment of the developmental groove, (2) alignment of supplemental groove, and (3) discrepancy in the number of the supplemental groove. The same procedure was repeated for comparing similar tooth of different casts [Figure 1].

Results

On examining the occlusal grooves of the maxillary molars, three distinct patterns resembling "H," "Branched H" and "μ" were observed along with few "Undefined" patterns. "Branched H" and "H" were observed to be the most common pattern for the maxillary 1st and maxillary 2nd molars, respectively. Dryopithecus or "Y" pattern was found to be the most prevalent for mandibular 1st molar. Cruciform or "+" groove pattern was predominantly seen in mandibular 2nd molar [Table 1]. Sexual predilection for the groove patterns was found to be absent in the sample population under study [Table 2 and Figure 2].

Digital comparison

The method of digital comparison was carried out by a detailed examination of the individual characteristics of two occlusal groove patterns at a time, i.e., while observing them side by side. Based on the observations, the following parameters were derived to distinguish the patterns:

- Configuration of the central grooves: straight or wavy
- Organization of the grooves of the triangular fossae: branched or un-branched

Table 1: Frequency of pattern seen in current sample

Tooth type	"Y" pattern, n (%)	"+" pattern, n (%)	"X" pattern, n (%)	"H" pattern, n (%)	Branched "H" pattern, n (%)	"μ" pattern, n (%)	Undefined, n (%)
Maxillary first molar	0	0	0	15 (37.5)	24 (60)	0	1 (2.5)
Maxillary second molar	0	0	0	18 (45)	14 (35)	5 (12.5)	3 (7.5)
Mandibular first molar	30 (75)	10 (25)	0	0	0	0	0
Mandibular second molar	2 (5)	38 (95)	0	0	0	0	0

Table 2: Distribution of groove pattern among males and females

Type of groove pattern	Males				Females			
	UM1	UM2	LM1	LM2	UM1	UM2	LM1	LM2
"Y" pattern	0	0	16	1	0	0	14	1
"+" pattern	0	0	4	19	0	0	6	19
"X" pattern	0	0	0	0	0	0	0	0
"h" pattern	8	10	0	0	7	8	0	0
Branched "H" pattern	11	6	0	0	13	8	0	0
"U" pattern	0	3	0	0	0	2	0	0
Abstract	1	1	0	0	0	2	0	0

UM: Upper molar, LM: Lower molar

- Arrangement of buccal and lingual/palatal grooves: both unbranched, only buccal groove branched, only lingual/palatal groove branched, or branching observed in both the grooves
- Presence or absence of the marginal groove (s)
- The number and the conformation (branched or unbranched) of the supplemental grooves.

Based on the above-mentioned features, the groove patterns were compared with one another [Figure 3]. Observation revealed marked degree of individuality among the patterns. Of the 40 maxillary casts observed, 90% of them presented uniqueness in the occlusal groove pattern of both the 1st and the 2nd molars. About 70% of 40 mandibular casts exhibited uniqueness in the groove pattern of the 1st molars, while 85% of the patterns recorded in the mandibular 2nd molars were found to be unique in nature [Table 3]. Hence, the interpretations of the digital comparison infer that the occlusal groove pattern of the 1st and 2nd molars is unique in the sample population.

Dental superimposition

All the teeth examined following this method reveals maxillary 2nd molars to be having the most unique groove pattern as 85% of the groove patterns did not match with antimere tooth. The least uniqueness was found to be associated with the mandibular 1st molars since about 62.5% of the groove patterns were different from its antimere. The analysis also reveals that most of the groove patterns had discrepancies in two or more parameters which led to their mismatch [Table 4]. The groove patterns were also not matching when they were examined with the similar teeth of other casts.

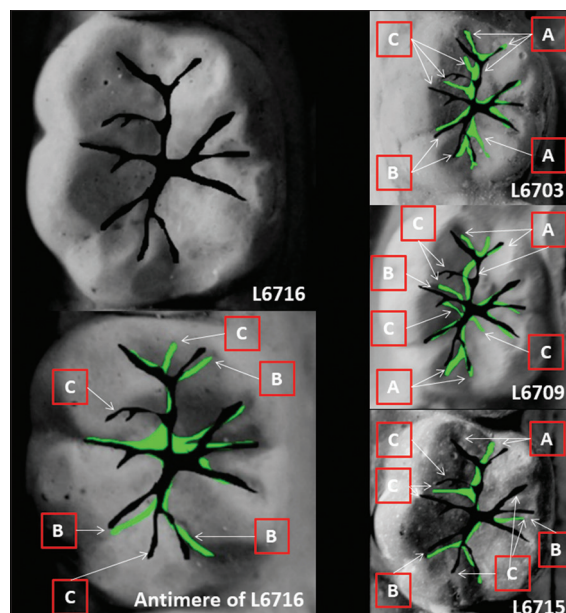


Figure 1: Digital Superimposition (A: Discrepancy of developmental groove pattern alignment, B: Discrepancy of supplemental groove pattern alignment, C: Discrepancy in the number of supplemental groove)

Two independent examiners analyzed the images to eliminate interobserver error. The images were analyzed in a set of 10 images per day to reduce the examiner's fatigue and minimize errors in investigation. A random 20 samples were analyzed again after a period of 1 month, and the readings were compared to check for intraobserver error. Chi-square test was performed for verifying the inter-observer and intra-observer discrepancies, which revealed no statistically significant changes in the values ($P > 0.05$).

Discussion

The formation of occlusal groove patterns begins during the histodifferentiation stage also known as the "Early bell stage" that takes place during the 6th week of intrauterine life.^[14] In this stage, enamel organ is formed which is responsible for the deposition of the enamel and dentin matrix.^[14] According to Simmer *et al.*, the shape and morphology of the crown is dependent on five growth factors.^[15] Due to all these parameters, invagination in the enamel organ occurs which later corresponds to the developmental groove of the molar tooth and smaller wrinkles manifest as the supplemental grooves.^[15] This whole process is mediated by few specific

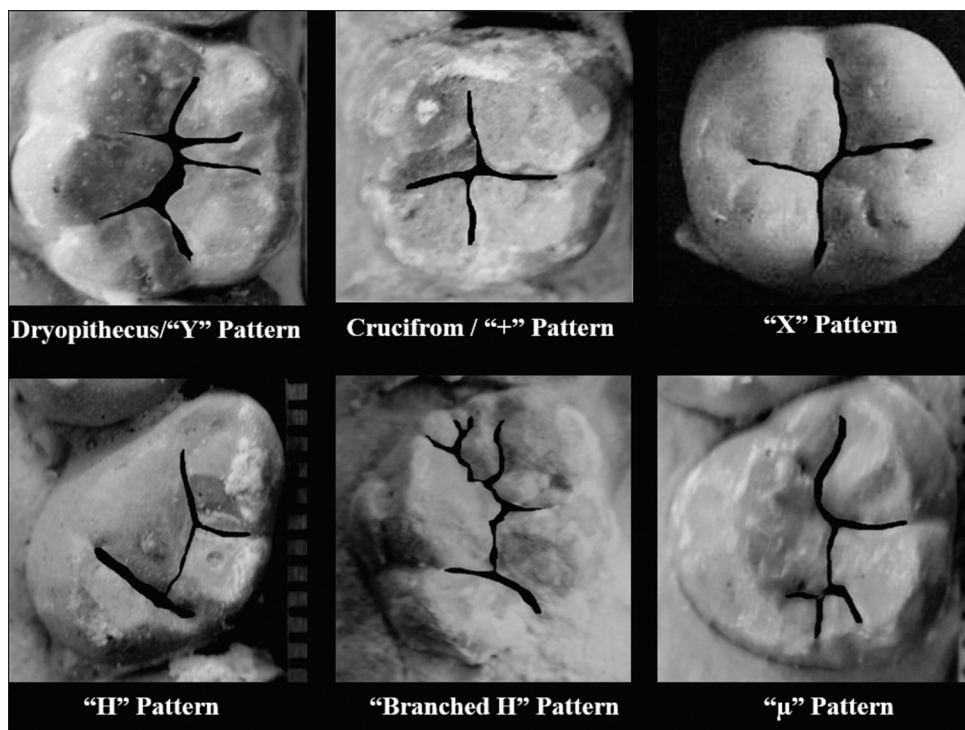


Figure 2: Different types of groove pattern

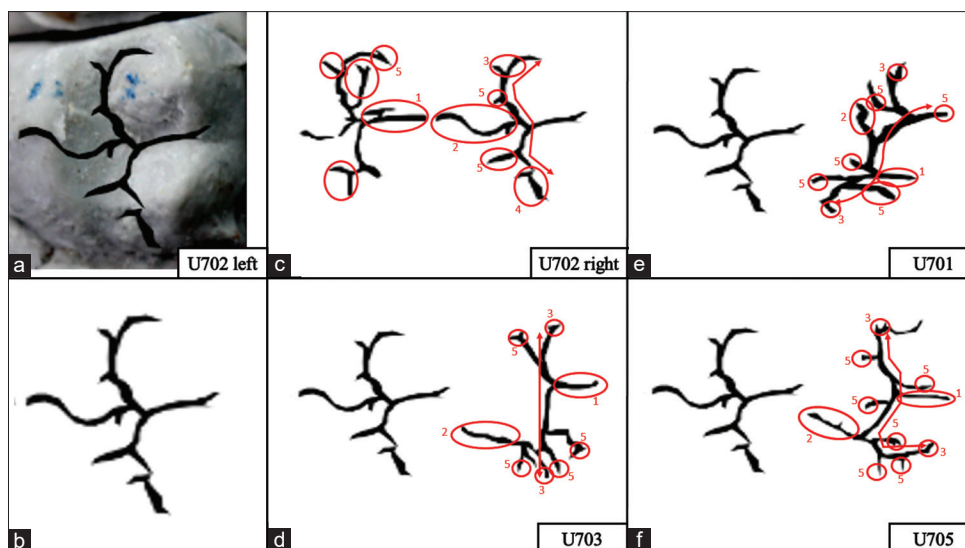


Figure 3: Digital Comparison (a: Groove pattern on maxillary second molar; b: Traced groove pattern for comparison; c: Comparison with antimere; d-f: Comparison with same tooth of different cast)

sets of genes; thus, it is different for each individual.^[15] As so many factors contribute to the final morphology of the occlusal surface of posterior tooth, it is ought to be unique and individualistic.

The present study suggests new distinct groove patterns for the molars in the upper arch owing to the lack of existing literature on the occlusal pattern of maxillary molars. Three new groove patterns were observed in the maxillary molars which resemble to "H," "Branched H" and "μ." The patterns were defined on the basis of

orientation of the buccal groove, palatal groove, and the grooves of the proximal triangular fossae on either side of the transverse groove on the oblique ridge. Confluence of the buccal groove with the mesial groove and the palatal groove with the distal groove produces mesiobuccal and distopalatal grooves, respectively. The "H" pattern was observed when the mesiobuccal groove and distopalatal groove is connected by the transverse groove on the oblique ridge. "μ" pattern was appreciated when any of the buccal or palatal segments of the mesiobuccal groove and distopalatal groove was underdeveloped.

Table 3: Frequency of traits found in the occlusal surface of the molars on digital comparison

Trait	Tooth		Upper first molar (%)	Upper second molar (%)	Lower first molar (%)	Lower second molar (%)
		Variant				
Central groove		Straight	40	57.5	50	70
		Wavy	60	42.5	50	30
Grooves at triangular fossae		Branched	67.5	70	56.25	60
		Unbranched	32.5	30	43.75	40
Buccal and lingual/palatal groove configuration		Unbranched	2.5	22.5	6.25	30
		Only buccal groove branched	45	32.5	6.25	20
		Only lingual/palatal groove branched	15	10	50	20
		Both branched	37.5	35	37.50	30
Marginal grooves		Present	37.5	42.5	37.50	40
		Absent	62.5	57.5	62.50	60
Supplemental grooves		Absent	0	0	0	15
		Unbranched	7.5	12.5	75	30
		Branched	2.5	2.5	12.50	20
		Mixed	90	85	12.50	35
Uniqueness			90	90	75	85

Table 4: Result based on digital superimposition

Tooth type	Matching, n (%)	Not matching			Total, n (%)
		Discrepancy in one parameter, n (%)	Discrepancy in two parameters, n (%)	Discrepancy in three parameters, n (%)	
Maxillary first molar	7 (17.5)	11 (33.33)	13 (39.39)	9 (27.27)	33 (82.5)
Maxillary second molar	6 (15)	7 (20.58)	14 (41.17)	13 (38.23)	34 (85)
Mandibular first molar	15 (62.5)	7 (28)	5 (20)	13 (52)	25 (62.5)
Mandibular second molar	8 (80)	10 (31.25)	16 (50)	6 (18.75)	32 (80)

Parameters are as follows - 1. Discrepancy of developmental groove pattern alignment, 2. Discrepancy of supplemental groove pattern alignment, 3. Discrepancy in the number of supplemental groove

Branching and the presence of supplemental grooves were also taken into consideration while defining the patterns. "Branched H" pattern was observed when the mesiobuccal groove and distopalatal groove were having several attachments of supplemental groove. A groove pattern was considered as "undefined" when excessive numbers of supplemental grooves were present, including the oblique ridge.

During the analysis, it was also observed that dryopithecus/"Y" pattern is the most prevalent pattern among mandibular 1st molars which correspond to a study conducted earlier by Sindhu Nair *et al.* on the Indian population.^[16] A similar result was suggested by a study conducted on Tamil Nadu population by Ahsana *et al.*^[17] Research by Mosharraf *et al.* also reveals that the most prevalent pattern for mandibular 1st molar is "5Y" and "4+" for mandibular 2nd molar, where the numeral denotes the number of cusps and the character denotes the gross pattern.^[18] The result of a study conducted on the Gujarati population by Phulari *et al.* also agrees with the current study.^[19] Another study on the Gujarati population by Dholia and Manjunatha also corroborates with the present study establishing the prevalence of "Y" and "+" patterns in mandibular first and second molars,

respectively.^[20] Although prevalence of a specific type of groove pattern was observed, minute analysis revealed that there are obvious differences in the groove pattern among different individuals. The differences were found to be absence of supplemental grooves, misalignment of the supplemental groove and even in some cases misalignment of the developmental groove itself. The minute supplemental grooves can be compared to the ridges of the fingerprint as they are also unique and individualistic in nature.^[21]

As done in the previous studies, observation under microscope is a strenuous and highly subjective observation technique making it prone to errors. Moreover, many authors have employed manual tracing in the past, which involves more armamentarium and also irreversibly tampers with the cast which is not acceptable from a forensic perspective. On the contrary, photographic method of recording the occlusal grooves was found to be more accurate as the patterns were clearly visible in the high-quality images. The digital analysis is a noninvasive technique, so it preserves the dental cast and does not tampers with the cast in any way. This is the most important point of this method as dental cast is considered as a valuable ante-mortem data which should have high longevity.

A greater sample size and extensive research on various ethnic groups of different regions can be helpful to better establish the importance and uniqueness of the groove patterns. Further oriented studies with equal sexual distribution can help ascertain the individuality of occlusal grooves to aid in the identification process. A basic knowledge regarding the importance of occlusal morphology should be kept in mind by the dental professionals so that it could be preserved for future references as an identification trait.

Conclusion

Researchers have been using occlusal configuration of teeth as a tool in anthropology and to unravel human evolution for years. This makes the groove patterns of the dental occlusal table a reliable parameter for other disciplines, including forensic science. The science of identification always seeks long-lasting tangible evidence, which are not only easy and simple to obtain but also sophisticated and intricate enough to establish its individuality. The present study revealed that occlusal groove patterns are unique among themselves. They are the features of enamel; the hardest substance of the human body, which makes them resilient to most conditions. The digital method of recording the patterns asserts the fact that the methodology of recording is easy and simple as well as compatible with other physical methods. With further research, the groove patterns may prove to be a nontechnique sensitive, cost-effective, and tangible identification trait that experts may look for. As we are entering the digital era, the scientific community may also be benefitted from this easy but accurate technology.

Financial support and sponsorship

Nil.

Conflicts of interest

There are no conflicts of interest.

References

1. Puri PM, Khajuria H. Disaster victim identification (DVI) through dental evidence: Overview and challenges in Indian scenario. *Int J Res Sci Innov* 2015;2:54-7.
2. Kieser JA, van der Merwe CA. Classificatory reliability of the carabelli trait in man. *Arch Oral Biol* 1984;29:795-801.
3. Divakar KP. Forensic odontology: The new dimension in dental analysis. *Int J Biomed Sci* 2017;13:1-5.
4. Krishan K, Kanchan T, Garg AK. Dental evidence in forensic identification – An overview, methodology and present status. *Open Dent J* 2015;9:250-6.
5. Disaster Victim Identification Team of the Bundeskriminalamt, Identifying victims of major incidents in Germany and abroad. Fachbereich KT11-IDKO, 65173 Wiesbaden: Bundeskriminalamt; 2018.
6. Horvath JE, Ramachandran GL, Fedrigo O, Nielsen WJ, Babbitt CC, St Clair EM, *et al.* Genetic comparisons yield insight into the evolution of enamel thickness during human evolution. *J Hum Evol* 2014;73:75-87.
7. Salido EC, Yen PH, Koprivnikar K, Yu LC, Shapiro LJ. The human enamel protein gene amelogenin is expressed from both the X and the Y chromosomes. *Am J Hum Genet* 1992;50:303-16.
8. Lau EC, Slavkin HC, Snead ML. Analysis of human enamel genes: Insights into genetic disorders of enamel. *Cleft Palate J* 1990;27:121-30.
9. Gregory WK, Hellman M. Palaeontology of the human dentition Part I. The crown patterns of fossil and recent human molar teeth and their meaning. *Int J Orthod Oral Surg Radiogr* 1926;12:1027-37.
10. Jørgensen KD. The dryopithecus pattern in recent Danes and Dutchmen. *J Dent Res* 1955;34:195-208.
11. Irish JD. Terms and terminology used in dental anthropology. *A Companion to Dental Anthropology*. Chichester, England: Wiley Blackwell; 2016. p. 85-93.
12. Kullmer O, Benazzi S, Fiorenza L, Schulz D, Bacso S, Winzen O, *et al.* Technical note: Occlusal fingerprint analysis: Quantification of tooth wear pattern. *Am J Phys Anthropol* 2009;139:600-5.
13. Gouse S, Karnam S, Girish HC, Murgod S. Forensic photography: Prospect through the lens. *J Forensic Dent Sci* 2018;10:2-4.
14. Nanci A., editor. Ten Cate's. Development of the tooth and its supporting tissues. In: Antonio Nancy. *Ten Cate's Oral histology, Development, structure, and function*. 9th ed. St. Louis, Missouri: Elsevier; 2018. p. 210-15.
15. Simmer JP, Papagerakis P, Smith CE, Fisher DC, Rountrey AN, Zheng L, *et al.* Regulation of dental enamel shape and hardness. *J Dent Res* 2010;89:1024-38.
16. Nair S, Kotrashetti VS, Nayak R, Hosmani J. Occlusal groove patterns and cusp number in permanent mandibular first and second molar among Indian population-a pilot study. *J Adv Clin Res Ins* 2018;5:115.
17. Ahsana A, Jeevanandan G, Subramanian EM. Evaluation of occlusal groove morphology of primary mandibular second molar in an Indian population. *J Forensic Dent Sci* 2018;10:92-5.
18. Mosharraf R, Ebadian B, Ali Z, Najme A, Niloofar S, Leila K. Occlusal morphology of mandibular second molars in Iranian adolescents. *Indian J Dent Res* 2010;21:16-9.
19. Phulari RG, Rathore R, Takvani MD, Jain S. Evaluation of occlusal groove patterns of mandibular first and second molars in an Indian population: A forensic anthropological study. *Indian J Dent Res* 2017;28:252-5.
20. Dholia B, Manjunatha BS. Occlusal morphology of permanent mandibular first and second molars in Gujarati population. *J Forensic Dent Sci* 2015;7:137-41.
21. Ramotowski R, editor. Lee and Gaensslen's *Advances in Fingerprint Technology*. 3rd ed. Boca Raton, FL: CRC Press; 2012