

White Epidermoid of the Sylvian Fissure Masquerading as a Dermoid Cyst: An Extremely Rare Occurrence

Abstract

We report the case of a 30-year-old female with a Sylvian fissure, white epidermoid which was radiologically looking like a dermoid cyst. The female presented with a headache with no neurological deficits. On radiology, the lesion was in Sylvian fissure, T1 hyperintense, T2 hypointense, and with minimal diffusion restriction medially. Hence a preoperative impression of dermoid cyst was made, a quite uncommon location. Intraoperatively, the classical pearly-white flaky appearance of epidermoid was seen which was confirmed histopathologically. White epidermoids appearing so because of high protein content are a rarity and are more likely to cause aseptic meningitis in the event of intraoperative spillage. Differentiating between a dermoid cyst and white epidermoid preoperatively and radiologically is difficult. Dermoids show diffusion restriction and are usually midline, whereas white epidermoids do not show diffusion restriction and are usually lateral. This is the first report of a white epidermoid in Sylvian fissure to the best of our knowledge.

Keywords: Dermoid cyst, mimicking, Sylvian fissure, white epidermoid

Introduction

Intracranial epidermoids and dermoids being inclusion tumors of the central nervous system are rare, usually benign and slow-growing lesions. Epidermoids constitute around 1% of all intracranial tumors^[1] while dermoids occur less frequently (0.3%).^[2] Epidermoids like dermoids arise from the trapping of ectodermal elements during the closure of neuroectodermal folds between 3rd and 5th week of gestation and contain stratified squamous epithelium, but are differentiated from dermoids in that they do not contain dermal appendages such as hair follicles, sweat glands, and sebaceous glands.^[2] Epidermoids are known to occur in the cerebellopontine angle cistern, in the cisterns around the tentorium, suprasellar, and parasellar cisterns.^[3] The most common presenting symptoms are headache and seizures.^[4]

We are reporting the case of 30-year-old female with “white” epidermoid in the Sylvian fissure who presented with headache as her only complaint for 1 year. To the best of our knowledge, the occurrence of the white epidermoid in

the Sylvian fissure has not been reported previously. This epidermoid mimicked the dermoid cyst radiologically.

Case Report

A 30-year-old female presented with the history of off and on the right hemicranial headache for the past 1 year. She had no other complaints. On examination, there was no neurologic deficits. All laboratory investigations were within normal limits. Noncontrast computed tomography (CT) scan showed a well-defined hypodense lesion in the right Sylvian fissure with no mass effect on adjacent structures. Magnetic resonance imaging (MRI) showed the lesion to be extra-axial and located in the right Sylvian fissure with no mass effect. The lesion was hyperintense on T1-weighted (T1WI) sequence, hypointense on T2-weighted (T2WI) sequence, suppressed on fluid-attenuated inversion recovery (FLAIR), and showed no diffusion restriction on diffusion-weighted imaging (DWI) except a small medial part of the lesion which showed diffusion restriction [Figure 1]. The contrast study was not done. Preoperative radiological differential diagnosis included – dermoid cyst, white epidermoid cyst, and the neuroenteric cyst; with the dermoid cyst being the topmost

**Jaskaran Gosal,
Jeena Joseph,
Deepak Khatri,
Kuntal Kanti Das,
Awadhesh Jaiswal,
Aviral Gupta**

*Department of Neurosurgery,
Sanjay Gandhi Postgraduate
Institute of Medical Sciences,
Lucknow, Uttar Pradesh, India*

Address for correspondence:

*Dr. Jeena Joseph,
Department of Neurosurgery,
Sanjay Gandhi Postgraduate
Institute of Medical Sciences,
Lucknow - 226 014,
Uttar Pradesh, India.
E-mail: jee_potter@hotmail.com*

Access this article online

Website: www.asianjns.org

DOI: 10.4103/ajns.AJNS_241_18

Quick Response Code:



How to cite this article: Gosal J, Joseph J, Khatri D, Das KK, Jaiswal A, Gupta A. White epidermoid of the sylvian fissure masquerading as a dermoid cyst: An extremely rare occurrence. Asian J Neurosurg 2019;14:553-6.

This is an open access journal, and articles are distributed under the terms of the Creative Commons Attribution-NonCommercial-ShareAlike 4.0 License, which allows others to remix, tweak, and build upon the work non-commercially, as long as appropriate credit is given and the new creations are licensed under the identical terms.

For reprints contact: reprints@medknow.com

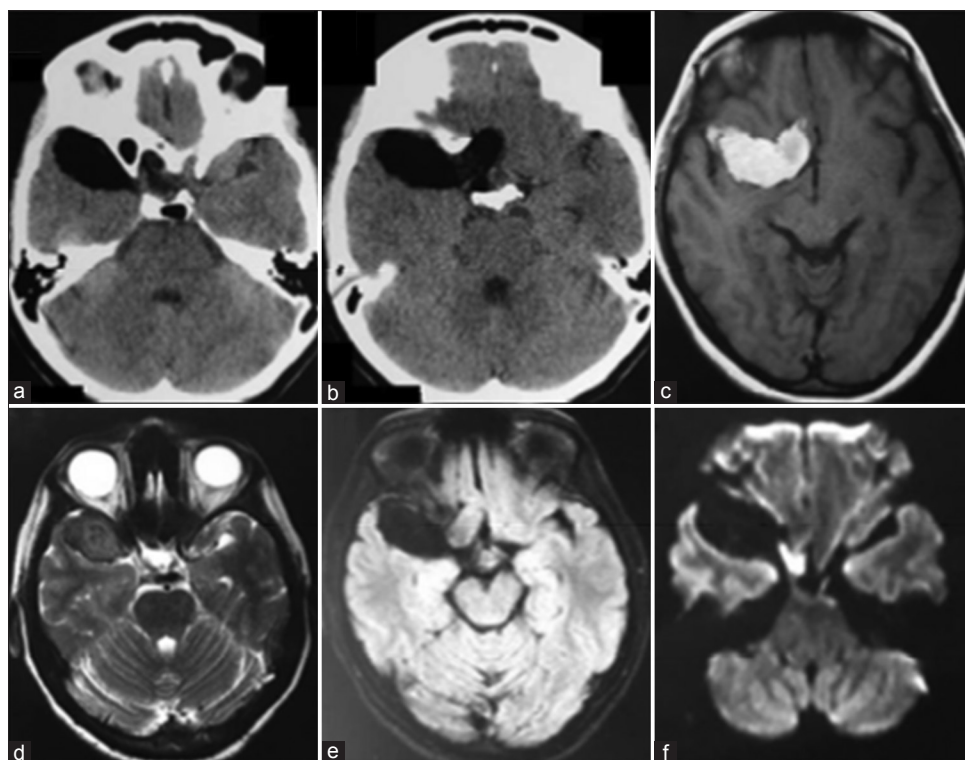


Figure 1: Preoperative imaging (a and b) shows a well-defined hypodensity in the right Sylvian fissure. Note also the pneumatization of the right anterior clinoid and that of posterior clinoids. (c) Shows a T1-weighted magnetic resonance imaging showing a hyperintense lesion in the right Sylvian fissure which is not causing any mass effect or hydrocephalus. (d) depicts a T2-weighted magnetic resonance imaging in which a well-defined extra axial hypointense lesion can be appreciated with cerebrospinal fluid cleft pushing the right temporal pole posteriorly. (e) Shows that the lesion suppresses on fluid-attenuated inversion recovery. (f) Is a diffusion-weighted imaging showing that the lesion is not showing diffusion restriction except that of a small medial portion of the lesion which is restricted on diffusion-weighted imaging

differential as the lesion was corroborating radiologically with all the features of a typical dermoid cyst; although all the three listed differentials are rare in this location. As the patient was having recurring episodes of severe headache (which was not responding to oral analgesics), she was offered microsurgical removal of the lesion. The right minipterional craniotomy was done, and after opening the Sylvian fissure, the classical pearly-white solid consistency typical of epidermoid was encountered. There was no evidence of the presence of dermal appendages like hair and there was no evidence of calcification intraoperatively. Tumor was adhered to middle cerebral artery at one point from which it was separated carefully, and gross total excision of the lesion was done [Figure 2]. Histopathology of the lesion removed was suggestive of epidermoid cyst [Figure 3]. At 6-month follow-up, the patient is doing well and her headache is completely relieved.

Discussion

Although both epidermoids and dermoids are inclusion tumors but there are important differences between the two. Dermoids have a greater tendency to occur in the midline location while epidermoids are known to occur laterally. Dermoids usually present and are treated in pediatric age group while epidermoids tend to present in second to fourth decades of life.^[2] Epidermoids and dermoids are not true

neoplasms since they do not grow by the multiplication of cells rather by the desquamation of epithelial cells; and in case of dermoids by the secretions from sebaceous glands in addition to desquamation,^[5] that is why dermoids present early as they enlarge rapidly than epidermoids.^[2]

Epidermoids can be classified into two types based on their different radiological picture -classical “black” epidermoids and the atypical “white” epidermoids.^[6] White epidermoids constitute only 3% of all the epidermoids.^[7] Epidermoids classically follow cerebrospinal fluid intensity pattern on CT and MRI.^[1] They are hypodense on noncontrast CT, hypointense on T1WI-MRI, hyperintense on T2WI-MRI, suppress on FLAIR (used to differentiate them from the arachnoid cysts which do not suppress on FLAIR) and show diffusion restriction. These tumors are usually solid and have no triglycerides. These classical epidermoids are referred to as black epidermoids.^[6] White epidermoids are atypical in that they due to their high protein content and consequently high viscosity, they are hyperintense on T1WI sequence, hypo- to hyper-intense (commonly hypointense) on T2 and show no diffusion restriction. They are usually cystic and in addition to their high protein content, they usually have high lipid content with mixed triglycerides containing polyunsaturated fatty acids, and no cholesterol further contributing to their high viscosity.^[6] Table 1

Table 1: Radiological characteristics of “black”/“white” epidermoids and dermoid cysts

Imaging/characteristics	Classical “black” epidermoid	Atypical “white” epidermoid	Dermoid
CT	Hypodense	Hypodense (occasionally hyperdense)	Hypodense
MRI-T1WI	Hypointense	Hyperintense	Hyperintense
MRI-T2WI	Hyperintense	Hypointense (occasionally hyperintense)	Hypointense
DWI	Present	Absent	Present
Calcification ^[7] (%)	10-25	Not reported	20

MRI – Magnetic resonance imaging; T1WI – T1-weighted sequence; T2WI – T2-weighted sequence; DWI – Diffusion-weighted imaging; CT – Computed tomography

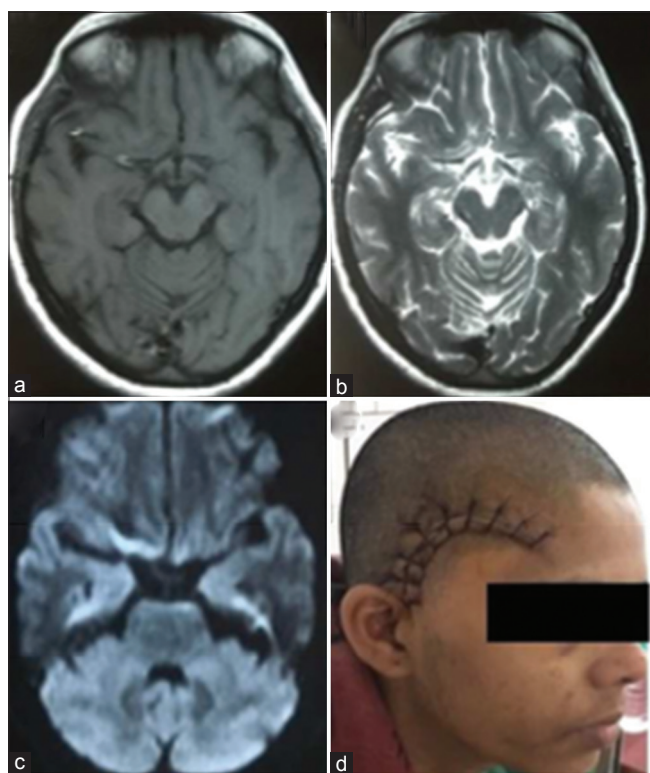


Figure 2: Postoperative magnetic resonance imaging done at 3 months. (a) Is a T1-weighted imaging showing complete excision of the tumor. (b) Is a T2-weighted imaging showing no residual hypointense mass lesion in the right Sylvian fissure. (c) Is the diffusion-weighted imaging which does not show any obvious evidence of diffusion restriction. (d) Is a clinical postoperative photograph of the patient showing the small frontotemporal incision used to remove the lesion

summarizes the radiological features of black and white epidermoid cysts along with that of dermoid cyst.

So epidermoids which are white or hyperintense on T1 are labeled as white epidermoids and are usually hypointense on T2 and show no diffusion restriction.^[1,6,8,9] The loss of the signal intensity on T2WI sequence of MRI due to highly viscous and proteinaceous contents of the white epidermoid cyst has also been termed as the “Shading Sign.”^[8] This is not to be confused with the term “Intracerebral Shading Sign” which is used specifically for the hemorrhagic metastases of squamous cell carcinoma.^[10]

In our patient, the lesion was hypodense on CT, hyperintense on T1WI, hypointense on T2WI, was suppressed on FLAIR, showed no diffusion restriction on

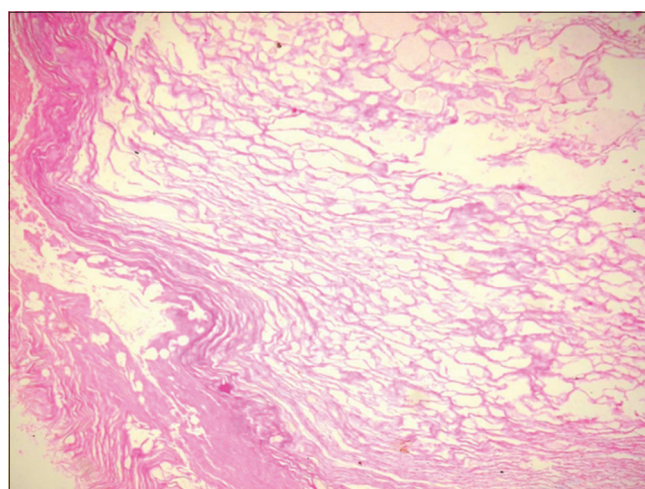


Figure 3: Histopathology of the tumor showing thin squamous epithelial layer filled with keratinous debris

DWI. All the imaging features were suggestive of either a dermoid cyst or a white epidermoid cyst which is very rare and has never been reported in this location. There were two points against dermoid cyst with the first being that the dermoids are usually midline in location and secondly they show diffusion restriction commonly. In our case, there was evidence of diffusion restriction in only a small medial part of the lesion. The contrast study was not done, but it could not have helped either in making the definitive diagnosis radiologically since both the epidermoid and the dermoid cyst do not show any contrast enhancement. Hence, it was difficult to reach a definitive diagnosis in our case preoperatively. The appropriate preoperative diagnosis has important implications as in contrast to typical “black epidermoids” and unruptured dermoid cysts, atypical “white” epidermoids are more prone to spread intraoperatively and cause severe aseptic meningitis.^[11]

Conclusion

It is difficult to differentiate preoperatively between the white epidermoid and dermoid as both of them have similar radiological characteristics. Diffusion-weighted sequence can be used to distinguish between the two, as the dermoids typically show diffusion restriction while the atypical “white” epidermoids do not. Preoperative establishment of the lesion as “white dermoid” is imperative as they have a greater tendency to intraoperative spillage leading

to aseptic meningitis as compared to dermoids and black epidermoids.

Declaration of patient consent

The authors certify that they have obtained all appropriate patient consent forms. In the form the patient(s) has/have given his/her/their consent for his/her/their images and other clinical information to be reported in the journal. The patients understand that their names and initials will not be published and due efforts will be made to conceal their identity, but anonymity cannot be guaranteed.

Financial support and sponsorship

Nil.

Conflicts of interest

There are no conflicts of interest.

References

1. Puranik A, Sankhe S, Goel N, Mahore A. Cerebral shading sign in a giant intraparenchymal white epidermoid. *Neurol India* 2012;60:265-6.
2. Conley FK. Epidermoid and dermoid tumors: Clinical features and surgical management. In: Wilkins RH, Rengachary SS, editors. *Neurosurgery*. 2nd ed. United States of America: McGraw-Hill; 1996. p. 971.
3. Shah A, Makkiyah F, Goel A. Sylvian fissure epidermoid cyst presenting with intention tremor. *Asian J Neurosurg* 2016;11:174-5.
4. Goel A, Muzumdar D, Desai K. Anterior tentorium-based epidermoid tumours: Results of radical surgical treatment in 96 cases. *Br J Neurosurg* 2006;20:139-45.
5. Garces J, Mathkour M, Beard B, Sulaiman OA, Ware ML. Insular and sylvian fissure dermoid cyst with giant cell reactivity: Case report and review of literature. *World Neurosurg* 2016;93:491.e1-5.
6. Horowitz BL, Chari MV, James R, Bryan RN. MR of intracranial epidermoid tumors: Correlation of *in vivo* imaging with *in vitro* 13C spectroscopy. *AJNR Am J Neuroradiol* 1990;11:299-302.
7. Osborn AG. *Osborn's Brain: Imaging, Pathology, and Anatomy*. Salt Lake City, UT: Amirsys Inc.; 2013. p. 782-5.
8. Glastonbury CM. The shading sign. *Radiology* 2002;224:199-201.
9. Ramdasi R, Mahore A, Chagla A, Kawale J. White epidermoid at the foramen magnum. *Neurol India* 2014;62:577-9.
10. Hetts SW, Urban JP, Quiñones-Hinojosa A, Joelson DW, Glastonbury CM. The shading sign in cerebral squamous cell metastases. *AJR Am J Roentgenol* 2004;182:1087-8.
11. Li F, Zhu S, Liu Y, Chen G, Chi L, Qu F, *et al.* Hyperdense intracranial epidermoid cysts: A study of 15 cases. *Acta Neurochir (Wien)* 2007;149:31-9.