

## [ Orthopaedic Surgery ]

# The Importance of the Recognition and Treatment of Glenoid Bone Loss in an Athletic Population

Sanjeev Bhatia, MD,<sup>†</sup> Neil S. Ghodadra, MD<sup>†</sup>, Anthony A. Romeo, MD<sup>†</sup>, Bernard R. Bach, MD<sup>†</sup>, Nikhil N. Verma, MD<sup>†</sup>, Samantha T. Vo, BS,<sup>‡</sup> and Matthew T. Provencher, MD, MC USN<sup>‡</sup>

**Context:** Osseous injury to the glenoid is increasingly being recognized as one of the most important aspects in the successful management of recurrent shoulder instability. Proper early recognition of glenoid bone injury in the setting of recurrent instability will lead to successful nonoperative and operative decision making, particularly in the athletic patient.

**Evidence Acquisition:** We conducted a MEDLINE search on shoulder instability from 2000 to 2010. The emphasis was placed on patient-oriented Level 1 literature from 2000 to 2010.

**Results:** After a traumatic anterior dislocation of the shoulder, the most common structural injury is an avulsion of the anteroinferior capsulolabrum, which is also known as a Bankart lesion. If this specific injury is accompanied by an associated fracture in the glenoid rim, the term *bony Bankart lesion* is more applicable. With diminished articular constraints, the glenohumeral joint is subject to recurrent instability, thereby potentiating the bony injury cycle. Additionally, patients with osseous defects usually complain of instability within the midranges of motion, or they recall a progression of instability. If glenoid bone loss is present, the humeral head often easily subluxates over the glenoid in the midranges of abduction (30°-90°) and lower levels of external rotation. Imaging workup should begin with plain radiographs, but advanced imaging should be obtained if there is any suspicion of bone loss. Treatment includes both nonoperative and operative interventions.

**Conclusions:** Estimation of the amount of glenoid bone loss and the failure of nonoperative care is essential for guiding management, patient expectations, and surgical decision making.

**Keywords:** shoulder instability; glenoid; glenohumeral joint; athlete

The glenohumeral joint's remarkable stability is maintained by numerous anatomic restraints, including the bony articulation and an elaborate array of dynamic and static soft tissue mechanisms. Despite these restraints, the shoulder's extensive range of motion and shallow socket make it prone to subluxation and dislocation injuries. Of the anterior restraints of the shoulder joint, the labrum and capsule are traditionally injured (Bankart tear). An increasingly recognized problem is injury to the bony portion of the glenoid (bony Bankart). Osseous injury to the glenoid is one of the most important factors in the successful management of recurrent shoulder instability.<sup>27,31</sup> Proper early recognition of glenoid bone injury in

the setting of recurrent instability improves nonoperative and operative decision making, particularly in the athletic patient.

## PATHOANATOMY AND BIOMECHANICS OF SHOULDER INSTABILITY

The glenoid articular surface and labrum are approximately 9 mm deep in the superoinferior direction and 5 mm deep in the anteroposterior (AP) direction.<sup>14</sup> The glenoid often has a thinning in its cartilaginous surface; the bare area is consistently equidistant from the anterior, posterior, and inferior glenoid margins.<sup>4</sup> Following initial traumatic dislocation, articular

From the <sup>†</sup>Division of Sports Medicine, Department of Orthopaedic Surgery, Rush University Medical Center, Rush Medical College of Rush University, Chicago, Illinois, and the <sup>‡</sup>Department of Orthopaedic Surgery, Naval Medical Center San Diego, San Diego, California

\*Address correspondence to Sanjeev Bhatia, Department of Orthopaedic Surgery, Rush University Medical Center, 1611 W. Harrison St., Ste. 300, Chicago, IL 60612 (e-mail: sanjeevhatia1@gmail.com).

One or more of the authors has declared a potential conflict of interest: Dr Romeo has received research or institutional support, miscellaneous funding, or royalties from, or is a consultant or employee of, Arthrex, Inc. Dr Bach has received research or educational support from Smith & Nephew, DJ Orthopaedics, Ossur, Arthrex, Inc, Athletico, Miomed, Sheck & Siress, and Conmed Linvatec. Dr Verma has received research or institutional support and is a consultant or employee of Smith & Nephew. MD, and have received institutional support from Arthrex, Inc, DJ Orthopaedics, Ossur, Smith & Nephew, Miomed, Athletico, Linvatec.

The views expressed in this article are those of the authors and do not reflect the official policy or position of the Department of the Navy, Department of Defense, or the United States Government.

DOI: 10.1177/1941738111414126

© 2011 The Author(s)

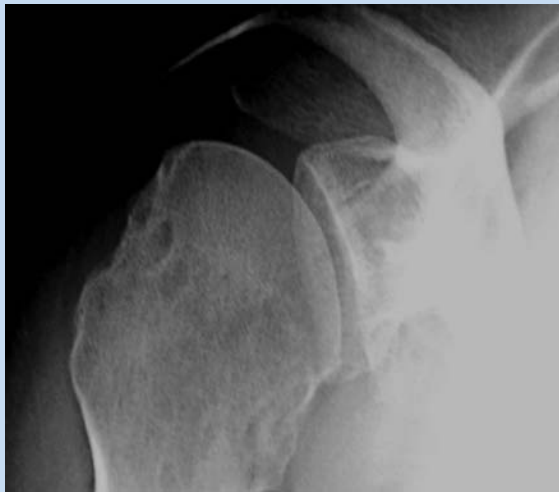

Figure 1. Apical oblique view. A radiographic cassette is placed flat against the scapula on the affected side while the patient sits with his or her arm in the lap. The radiographic beam is focused on the coracoid process, perpendicular to the cassette, except that it is angled 45° caudally off the anteroposterior glenohumeral view. This allows the beam to be tangential to the anteroinferior aspect of the glenoid rim.

constraints in the AP direction may be damaged, reducing the socket depth and the restraining capability of the glenoid.

After a traumatic anterior dislocation of the shoulder, the most common structural injury is an avulsion of the anteroinferior capsulolabrum, also known as a *Bankart lesion*.<sup>2</sup> If there is an associated fracture in the glenoid rim, the term *bony Bankart lesion* is more applicable. True incidence of bony Bankart lesions is difficult to ascertain, but it may be 22% of patients experiencing an initial shoulder dislocation and 90% of those with recurrent shoulder instability.<sup>27,36</sup>

Bony defects of the anterior glenoid result in an arc mismatch allowing the humeral head to subluxate anteriorly easily with less force.<sup>3,27</sup> Disparity in articular surface length often has a negative effect on the glenoid's ability to resist axial forces.<sup>3</sup> Additionally, bony Bankart lesions decrease the depth of the glenoid's articular conformity with the humerus, resulting in a loss of the buttress-type restraint to anterior humeral translation.<sup>3,20</sup> If a corresponding posterolateral humeral head indentation fracture (Hill-Sachs lesion) is present, shoulder instability is exacerbated.<sup>7</sup>

## CLINICAL SIGNIFICANCE OF GLENOID BONE LOSS

In the acute setting (onset < 3 months), fracture fragments of the anterior glenoid may still be present.<sup>28,33</sup> As instability becomes chronic (> 6 months), partial resorption of fracture fragments begins to occur.<sup>35</sup> In 21 patients with recurrent anterior glenohumeral instability at mean 15.0 months after initial traumatic dislocation, erosive bone loss was found

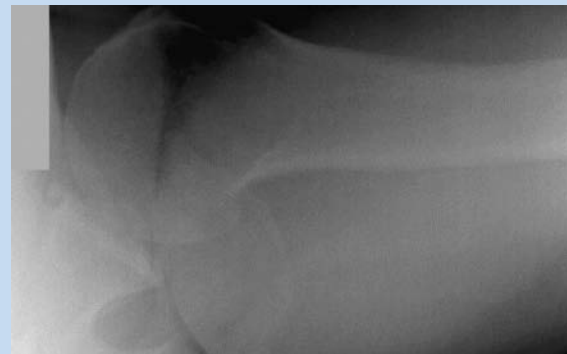

Figure 2. West Point axillary view. With the patient made prone, and the upper arm is abducted 90° from the trunk while the hand is pronated. A radiographic beam is directed at the axilla at a 25° angle medially and 25° angle cephalad, centered inferiorly and medially to the acromioclavicular joint.

without an identifiable Bankart fragment in 10 patients (48%) at time of arthroscopy.<sup>22</sup> Some rim defects occur at the time of initial traumatic anterior glenohumeral dislocation, while other lesions develop in an attritional manner secondary to recurrent instability events.

The size of the defect plays a critical role in determining which osseous lesions are clinically significant. The glenoid's widest anterior-to-posterior dimension is 23 to 30 mm, with most patients between 24 and 26 mm.<sup>15</sup> Osseous defects that measure 6 to 8 mm may actually be 25% of the glenoid articular width.

Osseous defects between 0% and 15% of glenoid width (< 3-4 mm from the original anterior glenoid rim) are usually trivial in most patients, while defects greater than 20% to 30% width (> 6-10 mm from the original anterior glenoid rim) are generally significant.<sup>27</sup> Bone loss in this range may also be significant with high athletic and work demands.

## APPROACH TO PATIENT WITH RECURRENT INSTABILITY

### History and Physical

Glenoid bone loss is suggested when a patient recalls a high-energy injury mechanism, especially if the arm was abducted (70° or more) at that time. Patients with osseous defects usually complain of instability within the midranges of motion (20° to 60° of abduction) or recall a progression of instability. The age and handedness of the patient are important factors. Older patients are more likely to have a concomitant rotator cuff tear, and instability in the dominant arm is likely to be more debilitating.

Subtle physical examination findings are often recognized because of dissymmetry. Special attention should be paid to the magnitude and direction of the instability during the Jobe relocation test,<sup>16</sup> sulcus sign,<sup>23</sup> Gagey hyperabduction sign,<sup>9</sup> and apprehension sign.<sup>21</sup> The apprehension test should be performed to highlight glenoid bone loss in various degrees

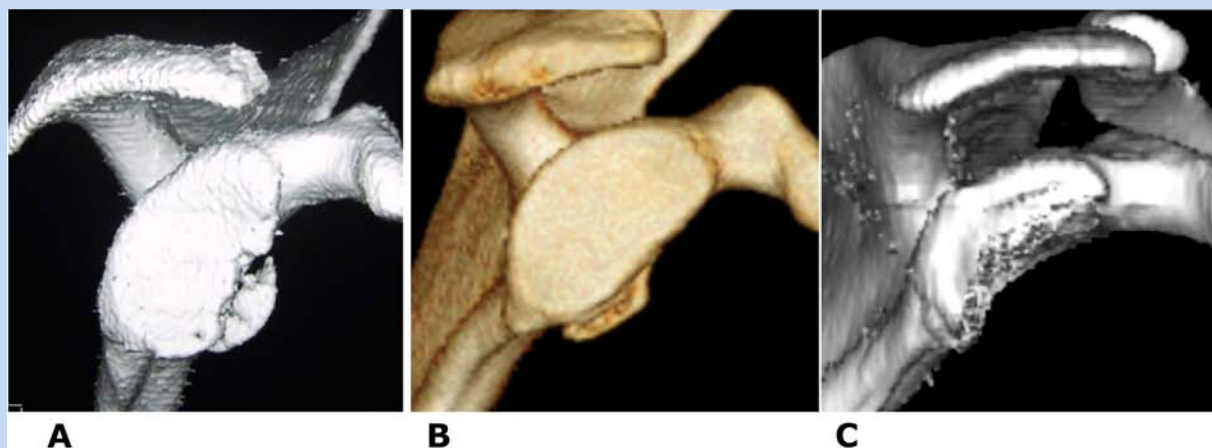


Figure 3. Glenoid bone loss as seen on 3-dimensional computed tomography reconstruction. Bone loss is classified as (A) acute fracture, (B) partial attritional, or (C) chronic attritional.

of abduction and external rotation. Most patients with anterior shoulder instability will have a positive apprehension test when the arm is in the 90°-abduction and 90°-external rotation position. With glenoid bone loss, the humeral head often subluxates in the midranges of abduction (30° to 90°) and lower levels of external rotation. If the humeral head translates anteriorly with crepitus or a palpable clunk, an underlying osseous defect may be present.

### Imaging

Initial plain film evaluation should include an AP view; a “true” AP view in the plane of the scapula, or Grashey projection; an axillary view; and a scapulolateral Y view.<sup>8</sup> The Grashey projection is perpendicular to the glenohumeral joint, providing visualization of the joint space and humeral head positioning. The axillary view visualizes joint space abnormalities and anterior or posterior glenoid rim fractures. It is particularly useful in identifying the direction of subluxation or dislocation, Hill-Sachs lesions, and reverse Hill-Sachs lesions. When patient discomfort compromises the ability to obtain standard axillary views, the trauma axillary view, or Velpeau view, may be employed.<sup>27</sup>

The highest yield projections for detecting glenoid bone loss include the apical oblique view (Garth view),<sup>10</sup> West Point view,<sup>30</sup> and Didiee view.<sup>26</sup> The apical oblique view is optimal for Bankart fractures on the anteroinferior glenoid rim, calcifications, and impression fractures on the posterior margin of the superolateral humeral head following dislocation (Figure 1). The West Point view is tangential to the anteroinferior rim of the glenoid for bony Bankart lesions (Figure 2).

If plain radiographs are suggestive of bone loss, then computed tomography (CT) scan (Figure 3) or magnetic resonance imaging is indicated. The 3-dimensional CT scan allows digital subtraction of the humeral head from the glenohumeral complex. Consequently, the scapula and glenoid fossa can be visualized as a free body not obscured by the humerus. There are also other indications for obtaining a 3-dimensional CT scan (Table 1).

Table 1. Indications for obtaining a computed tomography scan in patients with shoulder instability.<sup>a</sup>

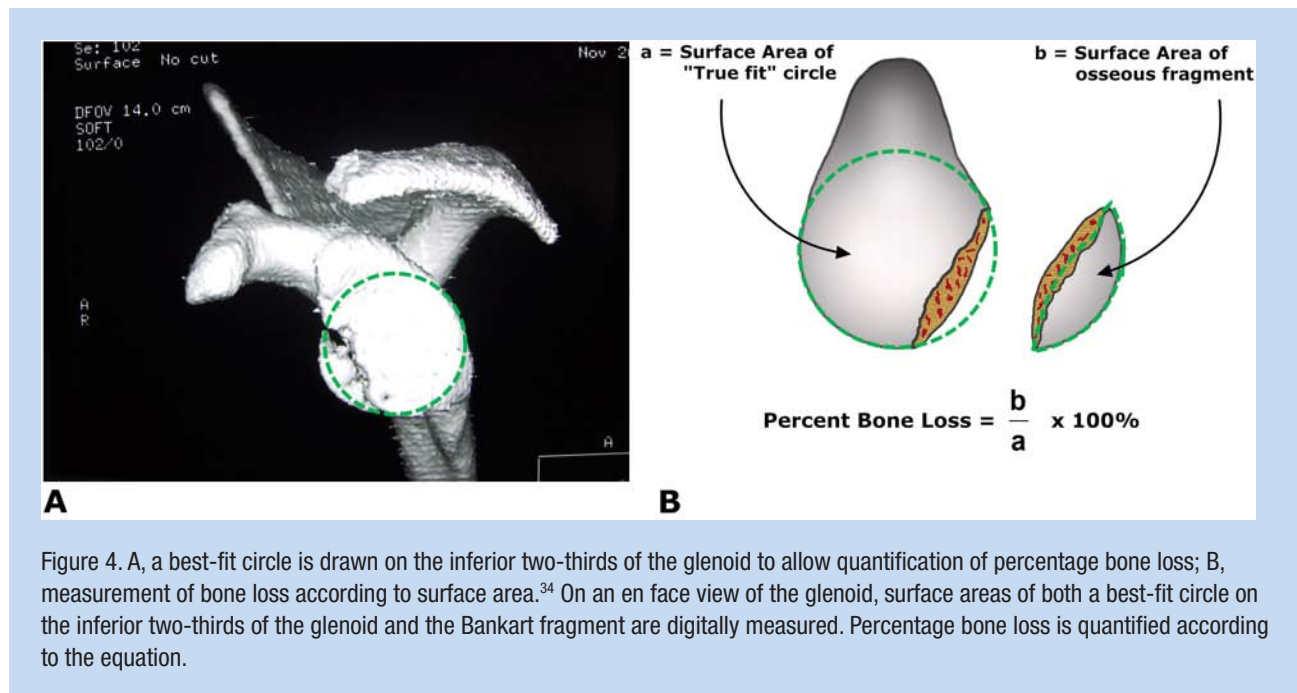
Indications for Computed Tomography Scan
Multiple dislocations
Bilateral shoulder dislocation, especially in nondominant arm
Failed stabilization procedure
Dislocation after trivial trauma (initial episode) or little provocation
Radiographs or MRI demonstrating glenoid bone loss
Instability in midranges of motion

<sup>a</sup>Three-dimensional computed tomography scan is best for quantification of bone loss. Adapted from MT Provencher, “Clinical Grading of Hill-Sachs Injuries: Association With Glenoid Bone Loss and Application of the ‘Glenoid Track’ Concept—When Is There Humeral Head Engagement?” American Shoulder and Elbow Surgeons 2009 closed meeting, New York, NY, 2009.

Magnetic resonance imaging and arthrography may be helpful in identifying soft tissue pathologies, including rotator cuff and superior labral anterior posterior (SLAP) tears, glenoid labrum articular disruptions,<sup>25</sup> anterior labral periosteal sleeve avulsions,<sup>24</sup> and humeral avulsions of the glenohumeral ligaments.<sup>32</sup> Magnetic resonance techniques are generally inferior to 3-dimensional CT scan for bone loss quantification.

### Radiographic Measurement

Estimation of the amount of glenoid bone loss is essential for guiding management, advising patients, and surgical decision making. Very large osseous injuries are rare. More common are defects in the 10% to 25% range (3-9 mm).<sup>27</sup> A 6- to



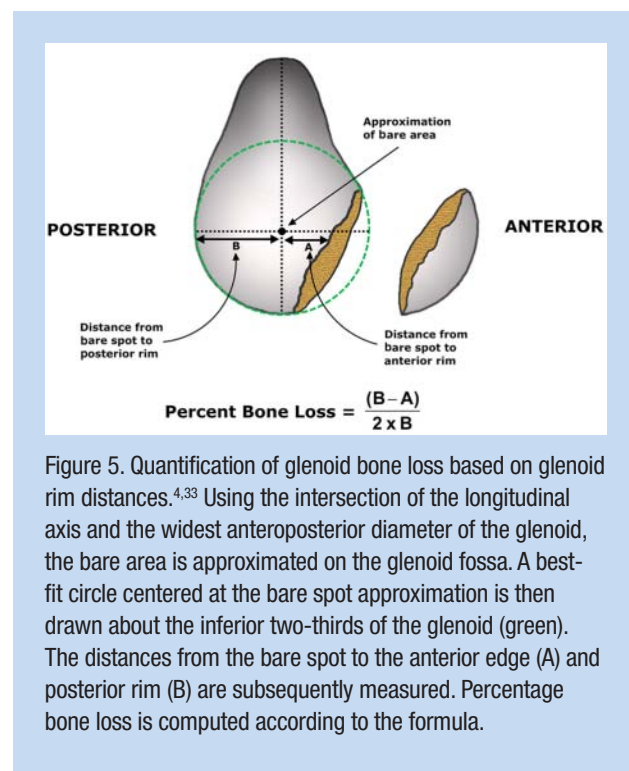
8-mm bony defect may represent 20% to 25% bone loss with disastrous consequences for recurrent shoulder instability and further attritional bone loss.<sup>3,27</sup>

The basic concept for determining glenoid bone loss involves modeling the inferior portion of the glenoid as a true circle on an en face view, thereby facilitating percentage area calculations with basic geometry (Figure 4A).<sup>34</sup> Surface area of the best-fit circle and osseous defect can be digitally measured using specialized computer software (Figure 4B).<sup>34</sup> Alternatively, osseous defects can be measured by bare-spot-to-rim distances on CT scan or at arthroscopy (Figure 5).<sup>4,33</sup> Finally, if the length of the Bankart fragment is greater than the radius of the circle, dislocation resistance is decreased by 70% (Figure 6).<sup>11</sup>

### Surgical Decision Making and Treatment

Surgical intervention is often required in patients with glenoid bone loss, particularly when a trial of conservative treatment fails to reestablish adequate function and quality of life. Surgery is generally recommended for patients who are young (< 25-30 years) and highly athletic (especially overhead or contact athletes) and have had multiple recurrences. Patients with an acute Bankart fracture that comprises greater than 25% to 30% of the glenoid surface will benefit from early operative intervention.<sup>3</sup>

For athletes with recurrent shoulder instability and less than 15% bone loss, bony restoration of the glenoid generally is not required and may be treated with arthroscopic soft tissue stabilization. Athletes with greater than 25% of bone loss usually require bony restoration of glenoid bone loss.<sup>27</sup> A 10-point preoperative instability severity index score can be used to identify the following risk factors for recurrent shoulder instability: 20 years old or younger at time of surgery, participation in competitive contact sports or activities requiring



overhead activity, hyperlaxity, and significant Hill-Sachs lesion.<sup>1</sup> Patients with these characteristics may be better served with an open procedure that reconstitutes osseous anatomy instead of arthroscopic stabilization alone.<sup>1</sup>

Glenoid bone defects can be reconstructed with an open Latarjet procedure, augmentation with an iliac crest bone graft, glenoid osteochondral allograft, or distal tibia osteochondral



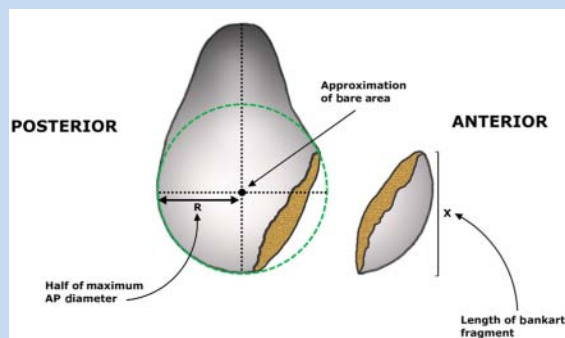


Figure 6. Significance of Bankart fragment length. If length ( $x$ ) is greater than half the widest anteroposterior diameter ( $R$ ), the dislocation resistance is  $\leq 70\%$  that of an intact glenohumeral joint.<sup>11</sup>

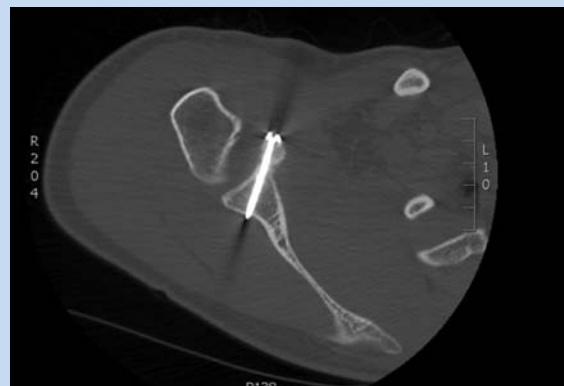

Figure 7. Computed tomography image of glenoid after bone augmentation with Latarjet procedure.

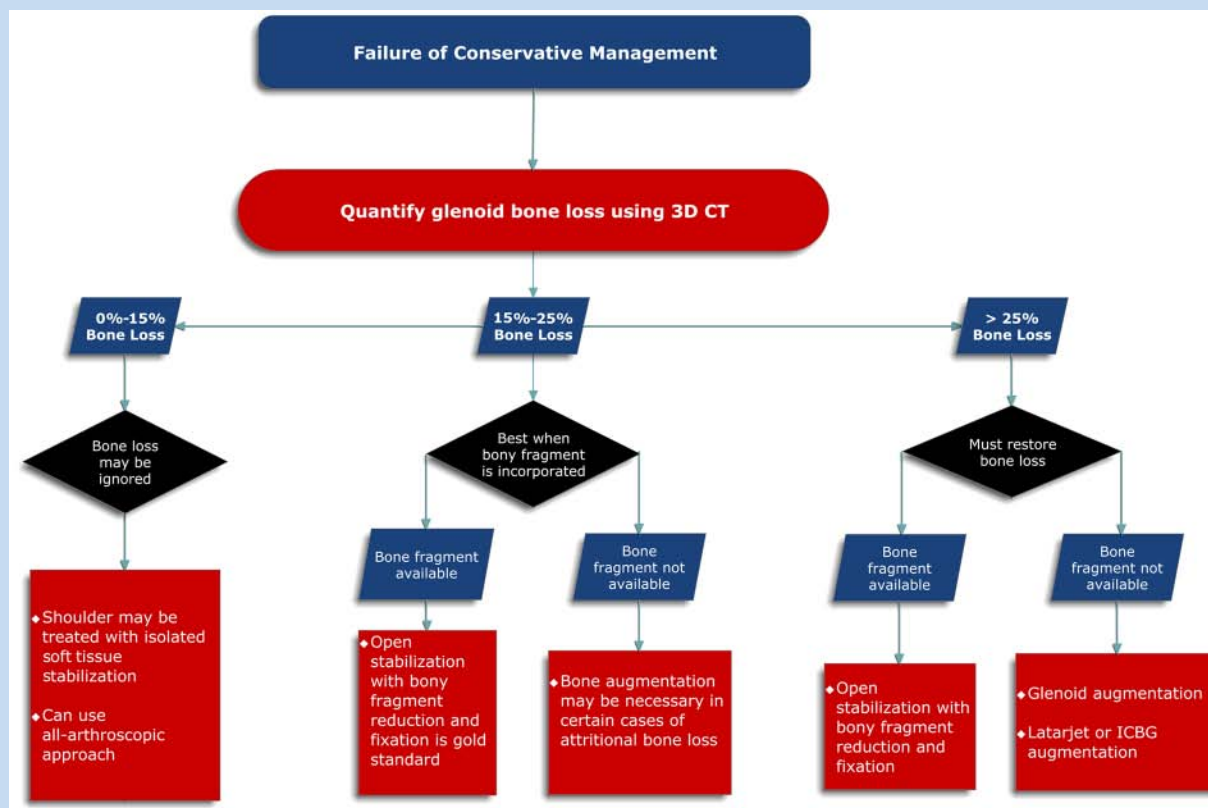


Figure 8. Algorithm for surgical management of glenoid bone loss in athletes with recurrent shoulder instability. Adapted from Piasecki et al.<sup>27</sup>

allograft.<sup>27,29</sup> The Latarjet achieves glenohumeral stability by positioning a coracoid autograft as an extension of the glenoid articular arc (Figure 7).<sup>17,18,19</sup> The attached conjoint tendon functions as a secondary restraint to anterior glenohumeral translation.<sup>5,19</sup>

The inner table of the iliac crest is concave and fits well with the native glenoid curvature.<sup>12,13,38</sup> A glenoid osteochondral

allograft provides an articular surface along with the added bony stability.<sup>6,29,37</sup> The inferior surface of a distal tibia allograft can provide a good anatomic articular surface and is much easier to obtain.<sup>29</sup>

Athletes with marginal bone loss (15%-25%) may not require bony reconstruction of the glenoid.<sup>27</sup> Contact athletes usually require bony restoration of the glenoid, either with the Bankart

fragment (acute setting), Latarjet, or augmentation procedure with iliac crest bone graft or osteochondral allograft (chronic setting) (Figure 8). Low-demand athletes (noncontact athletes) may do well with a soft tissue stabilization procedure alone.

For many patients with anterior glenoid bone loss, a concomitant Hill-Sachs deformity may be present on the humeral head. Treatment for Hill-Sachs lesions is dictated more by the position of the lesion rather than size alone.<sup>39</sup> Hill-Sachs lesions that extend medially over the zone of contact of the humeral head are more likely to be symptomatic and contribute to anterior shoulder instability.<sup>39</sup>

## CONCLUSIONS

Bony injury to the glenoid is one of the most important aspects of recurrent shoulder instability treatment. A 6- to 8-mm bony defect may represent a 20% to 25% osseous injury. Proper early recognition of glenoid bone injury in the setting of recurrent instability will improve decision making, particularly in the athletic patient.

## REFERENCES

- Balg F, Boileau P. The instability severity index score: a simple pre-operative score to select patients for arthroscopic or open shoulder stabilisation. *J Bone Joint Surg Br.* 2007;89(11):1470-1477.
- Bankart ASB. Recurrent or habitual dislocation of the shoulder joint. *Br Med J.* 1923;2:1132-1133.
- Burkhart SS, DeBeer JF. Traumatic glenohumeral bone defects and their relationship to failure of arthroscopic Bankart repairs: significance of the inverted-pear glenoid and the humeral engaging Hill-Sachs lesion. *Arthroscopy.* 2000;16(7):677-694.
- Burkhart SS, DeBeer JF, Tehrany AM, Parten PM. Quantifying glenoid bone loss arthroscopically in shoulder instability. *Arthroscopy.* 2002;18(5):488-491.
- Boileau P, Mercier N, Old J. Arthroscopic Bankart-Bristow-Latarjet (2B3) procedure: how to do it and tricks to make it easier and safe. *Orthop Clin North Am.* 2010;41(3):381-392.
- Chapovsky F, Kelly JD 4th. Osteochondral allograft transplantation for treatment of glenohumeral instability. *Arthroscopy.* 2005;21(8):1007.
- Chen AL, Hunt SA, Hawkins RJ, Zuckerman JD. Management of bone loss associated with recurrent anterior glenohumeral instability. *Am J Sports Med.* 2005;33:912-925.
- Edwards TB, Boulahia A, Walch G. Radiographic analysis of bone defects in chronic anterior shoulder instability. *Arthroscopy.* 2003;19:732-739.
- Gagey OJ, Gagey N. The hyperabduction test. *J Bone Joint Surg Br.* 2001;83:69-74.
- Garth WP Jr, Slappey CE, Ochs CW. Roentgenographic demonstration of instability of the shoulder: the apical oblique projection: a technical note. *J Bone Joint Surg Am.* 1984;66(9):1450-1453.
- Gerber C, Nyffeler RW. Classification of glenohumeral joint instability. *Clin Orthop Relat Res.* 2002;400:65-76.
- Ghodadra N, Gupta A, Romeo AA, et al. Normalization of glenohumeral articular contact pressures after either Latarjet or iliac crest bone grafting procedure: impact of graft type and coracoid orientation. *J Bone Joint Surg Am.* In press.
- Haaker RG, Eickhoff U, Klammer HL. Intraarticular autogenous bone grafting in recurrent shoulder dislocations. *Mil Med.* 1993;158(3):164-169.
- Howell SM, Galinat BJ. The glenoid-labral socket: a constrained articular surface. *Clin Orthop Relat Res.* 1989;243:122-125.
- Huysmans PE, Haen PS, Kidd M, Dhert WJ, Willems JW. The shape of the inferior part of the glenoid: a cadaveric study. *J Shoulder Elbow Surg.* 2006;15:759-763.
- Jobe FW, Kvitne RS, Giangarra CE. Shoulder pain in the overhand or throwing athlete: the relationship of anterior instability and rotator cuff impingement. *Orthop Rev.* 1989;18:963-975.
- Lafosse L, Boyle S. Arthroscopic Latarjet procedure. *J Shoulder Elbow Surg.* 2010;19:2-12.
- Lafosse L, Lejeune E, Bouchard A, Kakuda C, Gobeze R, Kocher T. The arthroscopic Latarjet procedure for the treatment of anterior shoulder instability. *Arthroscopy.* 2007;23(11):1242e1-1242e5.
- Latarjet, M. A propos du traitement des luxations récidivantes de l'épaule. *Lyon Chir.* 1954;49:994-997.
- Lazarus MD, Sidles JA, Harryman DT II, Matsen FA III. Effect of a chondrolabral defect on glenoid concavity and glenohumeral stability: a cadaveric model. *J Bone Joint Surg Am.* 1996;78:94-102.
- Magee DJ. *Orthopaedic Physical Examination.* 2nd ed. Philadelphia, PA: WB Saunders; 1992.
- Mologne TS, Provencher MT, Menzel KA, Vachon TA, Dewing CB. Arthroscopic stabilization in patients with an inverted pear glenoid: results in patients with bone loss of the anterior glenoid. *Am J Sports Med.* 2007;35(8):1276-1283.
- Neer CS II, Foster CR. Inferior capsular shift for involuntary inferior and multidirectional instability of the shoulder: a preliminary report. *J Bone Joint Surg Am.* 1980;62:897-908.
- Neviaser TJ. The anterior labroligamentous periosteal sleeve avulsion lesion: a cause of anterior instability in the shoulder. *Arthroscopy.* 1993;9:17-21.
- Neviaser TJ. The GLAD lesion: another cause of anterior shoulder pain. *Arthroscopy.* 1993;9:22-23.
- Pavlov H, Warren RF, Weiss CB Jr, Dines DM. The roentgenographic evaluation of anterior shoulder instability. *Clin Orthop Relat Res.* 1985(194):153-158.
- Piasecki DP, Verma NN, Romeo AA, Levine WL, Bach BR Jr, Provencher MT. Glenoid bone deficiency in recurrent anterior shoulder instability: diagnosis and management. *J Am Acad Orthop Surg.* 2009;17(8):482-493.
- Porcellini G, Campi F, Paladini P. Arthroscopic approach to acute bony Bankart lesion. *Arthroscopy.* 2002;18:764-769.
- Provencher MT, Ghodadra N, LeClere L, Solomon DJ, Romeo AA. Anatomic osteochondral glenoid reconstruction for recurrent glenohumeral instability with glenoid deficiency using a distal tibia allograft. *Arthroscopy.* 2009;25(4):446-452.
- Rokous JR, Feagin JA, Abbott HG. Modified axillary roentgenogram: a useful adjunct in the diagnosis of recurrent instability of the shoulder. *Clin Orthop Relat Res.* 1972;82:84-86.
- Rowe CR, Zarins B, Ciullo JV. Recurrent anterior dislocation of the shoulder after surgical repair. *J Bone Joint Surg Am.* 1984;66:159-168.
- Spang JT, Karas SG. The HAGL lesion: an arthroscopic technique for repair of humeral avulsion of the glenohumeral ligaments. *Arthroscopy.* 2005;21(4):498-502.
- Sugaya H, Kon Y, Tsuchiya A. Arthroscopic repair of glenoid fractures using suture anchors. *Arthroscopy.* 2005;21:635.
- Sugaya H, Moriishi J, Dohi M, Kon Y, Tsuchiya A. Glenoid rim morphology in recurrent anterior glenohumeral instability. *J Bone Joint Surg Am.* 2003;85(5):878-884.
- Sugaya H, Moriishi J, Kanisawa I, Tsuchiya A. Arthroscopic osseous Bankart repair for chronic recurrent traumatic anterior glenohumeral instability. *J Bone Joint Surg Am.* 2005;87:1752-1760.
- Taylor DC, Arciero RA. Pathologic changes associated with shoulder dislocations: arthroscopic and physical examination findings in first-time, traumatic anterior dislocations. *Am J Sports Med.* 1997;25(3):306-311.
- Tjoumakaris FP, Kropf EJ, Sekiya JK. Osteoarticular allograft reconstruction of a large glenoid and humeral head defect in recurrent shoulder instability. *Tech Shoulder Elbow Surg.* 2007;8(2):98-104.
- Warner JJ, Gill TJ, O'Hollerhan JD, Pathare N, Millett PJ. Anatomical glenoid reconstruction for recurrent anterior glenohumeral instability with glenoid deficiency using an autogenous tricortical iliac crest bone graft. *Am J Sports Med.* 2006;34(2):205-212.
- Yamamoto N, Itoi E, Abe H, et al. Contact between the glenoid and the humeral head in abduction, external rotation, and horizontal extension: a new concept of glenoid track. *J Shoulder Elbow Surg.* 2007;16(5):649-656.

For reprints and permissions queries, please visit SAGE's Web site at <http://www.sagepub.com/journalsPermissions.nav>.