



Contents lists available at ScienceDirect

International Journal of Surgery Case Reports

journal homepage: www.casereports.com

Brachial artery thrombosis following bee sting, case report

Mehmet Huseyin Akgul^{a,*}, Eldar Bagirov^b^a Department of Neurosurgery, Kirikkale State Hospital, Yahsihan, Kirikkale, Turkey^b Department of Cardiovascular Surgery, Kirikkale State Hospital, Yahsihan, Kirikkale, Turkey

ARTICLE INFO

Article history:

Received 8 November 2020

Received in revised form

29 November 2020

Accepted 29 November 2020

Available online 2 December 2020

Keywords:

Bee sting
Ischemic attack
Thrombosis

ABSTRACT

INTRODUCTION: Bee stings are the most common among insect emergencies.**PRESENTATION OF CASE:** We present a 47-year-old male patient who was admitted to the emergency department with complaints of pallor, chills, numbness and bruising on the left palm one hour after a bee sting on his left leg, and a very rare case of brachial artery stenosis in Doppler ultrasonography.**DISCUSSION:** Often bee stings occur only with local allergic reactions; sometimes it can also cause myocardial infarction, pulmonary edema, bleeding, hemolytic anemia, and kidney disease and neurological manifestations. Side effects are generally thought to be related to the dose of this venom in these patients who are admitted to the emergency room with a bruise extending from the left hand to the arm after bee bites.**CONCLUSION:** With this case presented, we wanted to emphasize that thrombosis may occur due to bee stings, albeit rarely, and doctors in emergency departments should recognize these very rare cases.© 2020 Published by Elsevier Ltd on behalf of IJS Publishing Group Ltd. This is an open access article under the CC BY-NC-ND license (<http://creativecommons.org/licenses/by-nc-nd/4.0/>).

1. Introduction

Severe reactions may occur following bee stings and other insects. These reactions can be local or systemic. Local reactions are often characterized by pain, swelling, erythema, itching, and blister, and in general, type 1 mast cells surround the sting site and this is an anaphylactic reaction [1,2]. It differs in poisoning clinics due to honey bee or wasp. Most people are usually locally allergic, and after insertion, reactions including pain, redness, swelling occur in the area and usually disappear within a few hours. It can cause a wide variety of reactions such as bee sting, neurological findings, seizure, ischemic attack. However, in less frequent severe cases, myocardial infarction, pulmonary edema, bleeding, kidney failure, and life-threatening anaphylactic shock may also occur [3]. This case is presented in order to emphasize this very rare and non-literature situation that physicians should be aware of such a complication in order to make an emergency diagnosis and to start early treatment.

2. Presentation of case

A 47-year-old man without comorbid disease applied to the emergency room in the morning with a complaint of paleness, coldness, numbness and bruising in the left palm developing at 1 h after bee sting from his left leg. It was determined that the

patient had a history of medication, a family history including genetic information or smoking status, and did not engage in bee-keeping. The patient did not have any known chronic conditions. On examination, there were signs of coldness, partial parasy and ischemia on the left palm and fingers. Brachial radial and ulnar pulses were nonpalpable. Cardiac rhythms were in sinus rhythm. Doppler ultrasonography performed on the patient revealed stenosis in the brachial artery. Digital angiography was performed by entering the upper extremity femoral artery immediately. Vascular occlusion was observed after brachial bifurcation. It was seen that filling was made from collateral. After the brachial artery was reached with the catheter tip, the metalyse bolus was performed. Then 25,000 of heparin was given. Then, metalyse brachial trunk-tan was given again. Balloon angioplasty was performed on the radial artery. Then, it was observed that the filling of the brachial trunk and ulnar, radial artery increased. Increased flow in collaterals was observed (Figs. 1–4). During peroperative angiography, it was observed that the vessel was opened and the blood supply increased. All these procedures were performed by the cardiovascular surgeon. The patient was taken to cardiovascular intensive care after the operation. Heparin infusion of 1000 units / h iv was given for 24 h. Oral coumadin and aspirin (100 mg) were started on the patient who was taken into the service on the 2nd day. Cyanosis of the patient's arm disappeared and radial and ulnar artery pulses were palpable. There were no complications related to the intervention and the patient tolerated this procedure easily. The patient stated that his complaints disappeared after the treatment, he received after the operation. On the 10th day, the patient was discharged with necessary recommendations.

* Corresponding author.

E-mail address: dr_mhakgul@yahoo.com (M.H. Akgul).

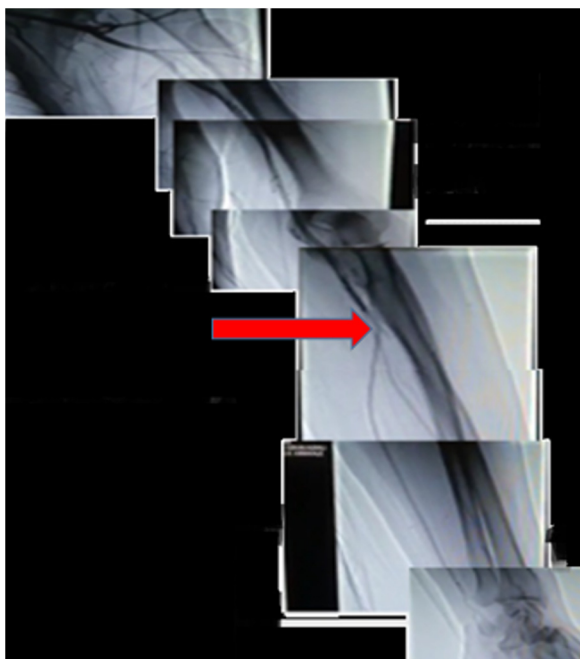


Fig. 1. During the percutaneous intravascular angiographic intervention, the image taken before treatment showed that the flow in the brachial artery distal decreased due to occlusion.

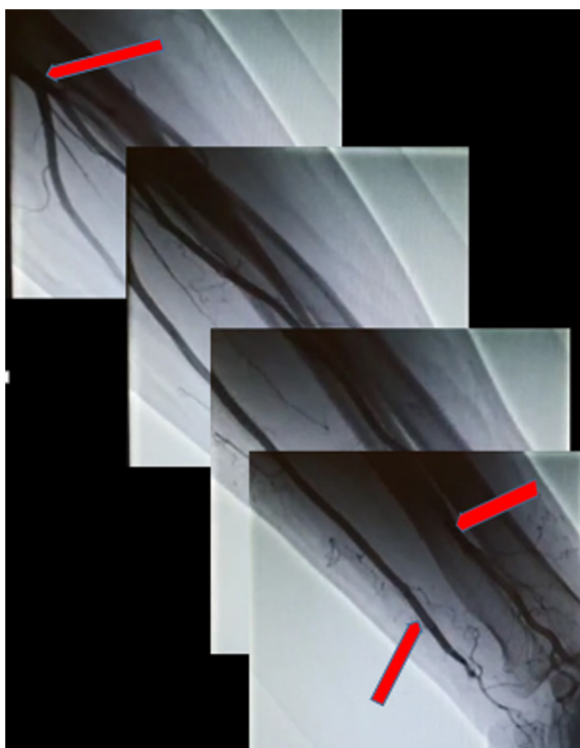

Fig. 2. During percutaneous intravascular angiographic intervention, the image taken after treatment showed a significant increase in flow in the distal of the brachial artery.

3. Discussion

After an allergic reaction to bee sting; skin reaction symptoms (erythema, itching, urticaria and angioedema), respiratory system effects (larynx edema and bronchospasm) and cardiovascular (myocardial depression, hypotension and shock) and gastroin-

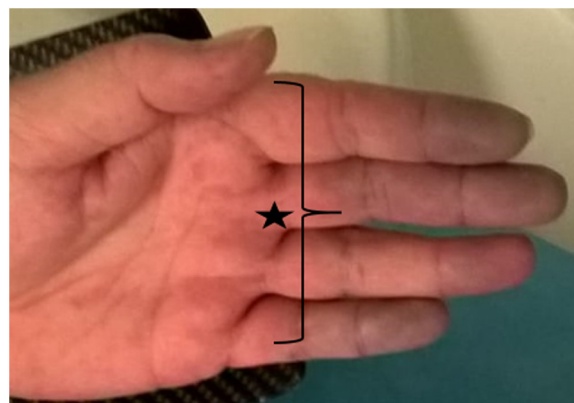


Fig. 3. Cyanotic hand fingers are observed in the patient's emergency image taken before angiography.



Fig. 4. In the image taken after the angiography of the patient, it is observed that the cyanosis in the toes disappeared.

testinal tract events (nausea, vomiting, fecal incontinence) may occur [4–7]. Consequently, severe anaphylactic shock may also lead to cerebral or myocardial ischemia accompanied by permanent sequelae [8]. The clinical picture of bee sting may rarely include diffuse alveolar bleeding, rhabdomyolysis, thrombocytopenic purpura, and vasculitis [5–8]. Although our case did not have any history, it was found appropriate to present because vasospasm and thrombosis developed in the brachial artery following bee sting. This is a very rare clinical presentation of bee stings according to the literature. It contains various chemical components that contribute to the clinical picture such as bee venom, enzymes (phospholipases, hyaluronidase) and biological amines (histamine, serotonin, dopamine, norepinephrine and acetylcholine) (9). Our patient was admitted to the emergency department with a bruise extending from his left hand to his arm after bee stings and was generally thought to be related to the dose of this poison.

It is associated with a variety of reasons that can activate the pathways of hypersensitivity and induce the degranulation of mast cells. In the light of this information, the results of our case were interpreted as toxic findings. Providing life support should be a priority in cases of anaphylaxis. Oxygen delivery, adrenaline (0.5 mg intramuscularly in 1/1000 adult), intervals of 10–15 min, diphenhydramine, prednisolone, ranitidine, fluids or, if necessary, positive inotropes in the presence of bronchospasm. It is recommended to give 2 agonists and aminophylline [9]. In the emergency department, anti-allergic and prophylactic anti-anaphylactic treatments

were applied in line with the treatment protocols recommended to our patient.

Phospholipase A2 is a key enzyme for the activation of the metabolism of arachidonic acid. During the metabolism of arachidonic acid, a number of cytokines and chemokines are released. These include leukotrienes via lipoxygenase and prostaglandins such as thromboxane via cyclooxygenase. These mediators have been accused in many clinical and laboratory studies to induce coronary artery spasm and / or acute myocardial infarction. This shows that the event in our case occurred thrombosis in the vascular bed and secondary vasospasm. Acute allergic attack after bee sting, such as Type II variant of Kounis syndrome, most likely caused plaque erosion or rupture, and vasospasm developed distal to the brachial artery after thrombosis formation [10]. Our study has been reported according to SCARE 2018 criteria [11]. We did not have any limitations in our approach to this case in terms of our treatment strategy, potential risks and complications.

4. Conclusion

The case presented here, albeit rarely, emphasizes the fact that thrombosis may occur due to bee stings and that emergency services should recognize these cases.

Note

Conflicts of Interest do not exist between authors. No funding source was included in this study. All procedures were done with prior permission from the hospital and the patient.

Conflicts of interest

There is no financial disclosures of the authors.

Author Mehmet Hüseyin Akgül declares that he has no conflict of interest.

Author Eldar Bağirov declares that he has no conflict of interest.

Sources of funding

There is no funding sources of the study.

Ethical approval

Ethics committee no approval was obtained. This studies is case report.

Consent

Informed consent is take to patient.

Author contribution

All studies was wrote from to writer.

Registration of research studies

Not applicable.

Guarantor

The writer was guarantor. The name is Mehmet Hüseyin Akgül and Eldar Bağirov.

Provenance and peer review

Not commissioned, externally peer-reviewed.

References

- [1] A.M. Truskinovsky, J.D. Dick, G.M. Hutchins, Fatal infection after a bee sting, *Clin. Infect. Dis.* 32 (2001) 36–38.
- [2] A.K. Ellis, J.H. Day, Clinical reactivity to insect stings, *Curr. Opin. Allergy Clin. Immunol.* 5 (2005) 349–354.
- [3] V. Agarwal, S. DCruz, A. Sachdev, R. Singh, V. Kapoor, Quadripareisis following wasp sting: an unusual reaction, *Indian J. Med. Sci.* 59 (2005) 117–119.
- [4] S.M. Lam, Acute pulmonary hemorrhage following a honeybee sting: a case report, *J. Microbiol. Immunol. Infect.* 31 (1998) 133–136.
- [5] M.B. Bilo, F. Bonifazi, The natural history and epidemiology of insect venom allergy: clinical implications, *Clin. Exp. Allergy* 39 (2009) 1467–1476.
- [6] R.E. Reisman, Unusual reactions to insect stings, *Curr. Opin. Allergy Clin. Immunol.* 5 (2005) 355–358.
- [7] G. Gandolfo, G. Lambeau, M. Lazdunski, C. Gottesmann, Effects on behaviour and EEG of single chain phospholipases A2 from snake and bee venoms injected into rat brain: search for a functional antagonism, *Pharmacol. Toxicol.* 78 (1996) 341–347.
- [8] N.G. Kounis, G.M. Zavras, Histamine-induced coronary artery spasm: the concept of allergic angina, *Br. J. Clin. Pract.* 45 (1991) 121–128.
- [9] D.B. Golden, M.D. Valentine, A. Kagey-Sobotka, Regimens of hymenoptera venom immunotherapy, *Ann. Intern. Med.* 5 (1980) 620–624.
- [10] L.A. Nikolaidis, N.G. Kounis, A.H. Gradman, Allergic angina and allergic myocardial infarction: a new twist on an old syndrome, *Can. J. Cardiol.* 18 (2002) 508–511.
- [11] R.A. Agha, M.R. Borrelli, R. Farwana, K. Koshy, A. Fowler, D.P. Orgill, SCARE Group, The SCARE 2018 statement: updating consensus Surgical Case Report (SCARE) guidelines, *Int. J. Surg.* 60 (2018) 132–136.

Open Access

This article is published Open Access at [sciencedirect.com](https://www.sciencedirect.com). It is distributed under the [IJSCR Supplemental terms and conditions](#), which permits unrestricted non commercial use, distribution, and reproduction in any medium, provided the original authors and source are credited.