

Clinical Efficacy and Safety of Albendazole and Other Benzimidazole Anthelmintics for Rat Lungworm Disease (Neuroangiostrongyliasis): A Systematic Analysis of Clinical Reports and Animal Studies

John Jacob,¹ Argon Steel,¹ Zhain Lin,¹ Fiona Berger,² Katrin Zöeller,³ and Susan Jarvi^{1,6}

¹Daniel K. Inouye College of Pharmacy, University of Hawaii–Hilo, Hilo, Hawaii, USA; ²Department of Pharmacy, University Clermont Auvergne, Clermont Ferrand, France; and ³Department of Pharmacy, Goethe University Frankfurt, Frankfurt, Germany

The safety and efficacy of benzimidazole anthelmintics for the treatment of rat lungworm disease (neuroangiostrongyliasis) have been questioned regardless of numerous experimental animal studies and clinical reports. In this review, 40 of these experimental animal studies and 104 clinical reports are compiled with a focus on albendazole. Among the 144 articles involving an estimated 1034 patients and 2561 animals, 4.1% were inconclusive or vague regarding the use of benzimidazoles. Of the remaining 138 articles, 90.5% found benzimidazoles to be safe and effective (885 patients, 2530 animals), 4.3% as safe but ineffective (73 patients, 3 animals), and 5.0% caused adverse reactions (7 patients, 28 animals). Among those clinical reports that described a confirmed diagnosis of neuroangiostrongyliasis in which albendazole monotherapy was used, 100% reported high efficacy (743 patients, 479 animals). In those where albendazole-corticosteroid co-therapy was used, 97.87% reported it to be effective (323 patients, 130 animals).

Keywords. albendazole; anthelmintics; antiparasitic; neuroangiostrongyliasis; rat lungworm.

Neuroangiostrongyliasis (rat lungworm disease) is a neurological condition caused by the nematode *Angiostrongylus cantonensis*. Infections are mainly caused by the accidental ingestion of third-stage larvae (L3) from infected mollusks, often found on produce. The spectrum of disease severity can range from a mild headache to life-long neurological anomalies, paralysis, and even death. This dramatic range of symptoms is thought to be correlated with the number of L3s to which an individual has been exposed. Early diagnosis and detection of infection can be problematic, and early signs and symptoms are very general and vary from case to case [1–3]. Treatment of neuroangiostrongyliasis has also been controversial, particularly regarding the use of anthelmintics, especially benzimidazoles, whose use has been contraindicated in some reports [4, 5]. This lack of consensus regarding the use of anthelmintics has left the healthcare system with few pharmaceutical tools available for its management.

Benzimidazoles are a chemical classification of anthelmintics that include thiabendazole, mebendazole, and albendazole, among others [6, 7]. Benzimidazole anthelmintics are known to bind to the colchicine-sensitive site of β -tubulin and hinder microtubule assembly, corrupting the cascade of cell division at metaphase, which ultimately leads to death of the parasite [8]. Currently, in the United States, specific treatment for neuroangiostrongyliasis is initiated only after diagnostic confirmation through the detection of *A. cantonensis* DNA in the cerebrospinal fluid (CSF) [9]. However, at this point of the disease, the larvae are likely to have induced neurological damage. In addition, concern has been raised that using anthelmintics to kill larvae that have migrated to the brain could induce further inflammation, causing additional complications [3, 10]. While numerous researchers have investigated the specific question of using benzimidazoles for the management of neuroangiostrongyliasis, their findings are scattered among multiple clinical reports and animal studies [5] and across a wide variety of geographical locations. Thus, a consensus has never been established. This comprehensive review of 144 reports associated with benzimidazole therapy for neuroangiostrongyliasis categorizes these studies based on their treatment regimen and clinical outcomes toward greater insights into efficacy and safety. Although we have reviewed studies associated with all benzimidazole derivatives used, our prime focus is on albendazole as it is currently the only US Food and Drug Administration (FDA)–approved benzimidazole

Received 1 June 2021; editorial decision 19 August 2021; published online 27 August 2021.

Correspondence: S. I. Jarvi, Daniel K. Inouye College of Pharmacy, University of Hawaii at Hilo, 200 West Kawili St., Hilo, Hawaii, 96720 (jarvi@hawaii.edu).

Clinical Infectious Diseases® 2022;74(7):1293–302

© The Author(s) 2021. Published by Oxford University Press for the Infectious Diseases Society of America. This is an Open Access article distributed under the terms of the Creative Commons Attribution-NonCommercial-NoDerivs licence (<https://creativecommons.org/licenses/by-nc-nd/4.0/>), which permits non-commercial reproduction and distribution of the work, in any medium, provided the original work is not altered or transformed in any way, and that the work is properly cited. For commercial re-use, please contact journals.permissions@oup.com <https://doi.org/10.1093/cid/ciab730>

anthelmintic capable of crossing the blood–brain barrier (BBB) [11]. To our knowledge, this is the most extensive review of anthelmintic therapy for neuroangiostrongyliasis to date.

METHODS

Search Strategy

A multilinguistic comprehensive search of databases including PubMed/Medline, Google Scholar, ScienceDirect, and CAB Direct from each database's inception to 28 July 2020 was conducted. The search included ahead-of-print, in-process, and other nonindexed citations. The search terms used were “rat lungworm” [AND] “albendazole,” “rat lungworm” [AND] “mebendazole,” “rat lungworm” [AND] “thiabendazole,” “rat lungworm” [AND] “treatment,” “*Angiostrongylus cantonensis*” [AND] “albendazole,” “*Angiostrongylus cantonensis*” [AND] “mebendazole,” “*Angiostrongylus cantonensis*” [AND] “thiabendazole,” “*Angiostrongylus cantonensis*” [AND] “treatment,” “neuroangiostrongyliasis” [AND] “albendazole,” “neuroangiostrongyliasis” [AND] “mebendazole,” “neuroangiostrongyliasis” [AND] “thiabendazole” and “neuroangiostrongyliasis” [AND] “treatment.” We identified additional candidate studies from the bibliographic references of the eligible primary studies and reviews.

Eligibility Criteria

Eligible studies conducted in humans had to meet all of the following criteria: case reports or case series, confirmed or presumptive diagnosis of neuroangiostrongyliasis or ocular angiostrongyliasis, and treatment with 1 or more benzimidazole anthelmintics with or without coadministration of corticosteroids. Criteria for animal studies included the following: experimental infection of animals with *A. cantonensis* L3 larvae, administration of 1 or more benzimidazole anthelmintics either pre- or post-infection, and confirmation of anthelmintic efficacy by 1 or more of the following: histopathology, polymerase chain reaction (PCR), assessment of inflammatory biomarkers, detection of L1 larvae in the feces, or extraction of *A. cantonensis* from the brain or heart–lungs complex. This article follows the Preferred Reporting Items for Systematic Reviews and Meta-analyses [12].

Study Selection and Data Extraction

Two authors independently screened the article titles in the literature search. A standard data collection form was developed to extract information such as authors, year of publication, country of disease origin, patient's knowledge of exposure, incubation period, time duration between incubation period and initiation of anthelmintic treatment, type of benzimidazole used and its regimen, other coadministered medications, method used to confirm infection, and patient outcome associated with benzimidazole anthelmintic treatment. The data from articles in languages other than English were collected by

a native speaker of the respective language. Case reports and case series were analyzed together as clinical reports, and the animal studies were analyzed separately.

Given the lack of specific diagnostic markers to indicate the severity of *A. cantonensis* infection, severity is determined subjectively and is entirely based on the presenting symptoms. Thus, quantitative analysis of any correlation between benzimidazole therapy and its clinical efficacy against neuroangiostrongyliasis is not valid. Therefore, the efficacy of benzimidazole anthelmintics in the clinical reports analyzed in this study was based entirely on the patient's condition after the therapy, that is, improved, unaffected, or deteriorated. Efficacy and safety of benzimidazoles from the clinical reports and animal studies were categorized into the following 4 groups based on their outcomes: “beneficial outcome” when benzimidazole therapy is reported to be effective and safe, “ineffective” when benzimidazole therapy is reported to be safe but not effective, “adverse outcome” when benzimidazole therapy is reported to have deteriorated the patient's condition, and “inconclusive” when the clinical outcome associated with the benzimidazole therapy is not specific or clear.

RESULTS

Literature searches resulted in clinical reports from 1972 through 2021. The reports of animal studies collected were from 1965 through 2020. As our literature search was multilinguistic, the breakdown for clinical reports was English (n = 80), Chinese (n = 12), French (n = 9), Spanish (n = 2), and German (n = 1); and the breakdown for animal studies was English (n = 35), Chinese (n = 3), French (n = 1), and German (n = 1).

HUMAN DATA

Clinical Outcomes

Our search yielded 104 clinical reports that included both confirmed as well as presumptive diagnoses of neuroangiostrongyliasis. The total number of patients included in these clinical reports was estimated to be 1034; the exact number was undeterminable based on the data provided in some of the published reports. Of these 104 clinical reports, 6 were classified as inconclusive. Of the remaining 98 articles, 87 (885 patients) reported beneficial outcomes associated with benzimidazole anthelmintic treatment, with or without the coadministration of corticosteroids; 5 (73 patients) reported the use of benzimidazoles to be ineffective; and 6 (7 patients) reported adverse outcomes (Figure 1, Table 1). The summary of these clinical reports is provided in Supplementary Table 1.

Diagnosis

Since accurate diagnosis and detection of neuroangiostrongyliasis is an ongoing challenge with other infectious diseases exhibiting similar signs and symptoms [5], we sought to

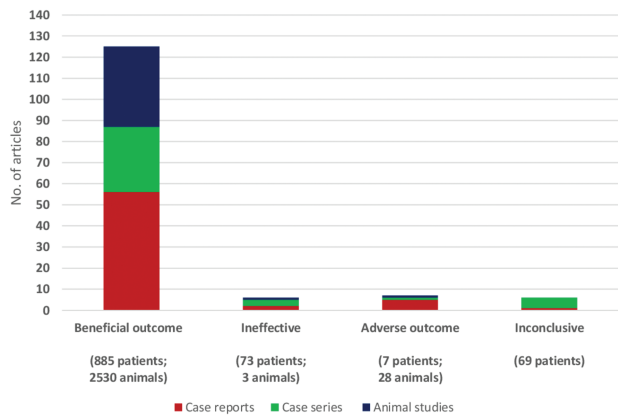


Figure 1. Graphical comparison of outcomes from clinical reports (n = 104) and animal study results (n = 40) associated with the management of neuroangiostrongyliasis using benzimidazole anthelmintics. The numbers of patients and animals involved are estimated.

determine the number of clinical reports that included a confirmed diagnosis and to identify the method used for diagnosis. We defined a case to have a confirmed diagnosis if any larval stage of the parasite was reported to have been recovered from the patient's CSF, eye, or during an autopsy or if there was positive confirmation of infection by PCR or any *A. cantonensis*-specific immunodetection technique performed on the patient's CSF, peripheral blood, or serum. Based on this criterion, 79 of 104 articles reported a confirmed diagnosis, and the remaining 25 reported a presumptive diagnosis.

Benzimidazoles

Benzimidazole monotherapy

The use of benzimidazole anthelmintic monotherapy was reported in 29 articles, where 18 reported a confirmed (117 patients) and 11 reported a presumptive diagnosis (145 patients; Figures 2–4, Table 2). Of the 18 articles that reported a confirmed diagnosis, the diagnosis was categorized as inconclusive in 2 (9 patients), monotherapy was reported to be ineffective in 3 (22 patients), and an adverse outcome was reported in 2 (2 patients). The remaining 11 articles (94 patients) reported monotherapy to be beneficial. Similarly, among those reporting a presumptive diagnosis, 3 of 11 articles (4 patients) reported

monotherapy to have adverse outcomes and the remaining 8 (141 patients) reported monotherapy to be beneficial.

Benzimidazoles–corticosteroid cotherapy

The use of benzimidazole anthelmintics along with corticosteroids was described in 75 of 104 clinical reports (Figures 2–4, Table 2). Of these, a confirmed diagnosis was provided in 61 (486 patients), while the remaining 14 (194 patients) reported a presumptive diagnosis. Use of corticosteroids such as dexamethasone, prednisone, prednisolone, and methylprednisolone was common in the reports that involved cotherapy. Of these 75 articles, 3 were categorized as inconclusive, 2 (54 patients) reported cotherapy to be ineffective, and the remaining 70 (97.2%; 526 patients) reported cotherapy to be beneficial. Interestingly, none of the articles that described use of benzimidazole–corticosteroid cotherapy reported any adverse outcome.

Albendazole

Of the 104 clinical reports reviewed, 77 (743 patients) specifically reported the use of albendazole (Figure 2), of these, 4 were categorized as inconclusive. Of the remaining 73 articles, 2 reported albendazole to be ineffective, 1 reported adverse outcomes, and 70 (96%) reported beneficial outcomes.

Albendazole monotherapy

Of the 77 articles that described the use of albendazole, 17 reported on monotherapy (Figure 2). Of these, 10 reported a confirmed diagnosis, 1 of which was classified as inconclusive [156] and the remaining 9 (100%) reported beneficial outcomes. The estimated mean dose of albendazole reported in these articles was approximately 15 mg/kg/day or 400 mg twice daily (average body weight to be 60 kg). The estimated duration of monotherapy was approximately 2 weeks, the mean time of initiation of albendazole post-exposure was approximately 6 weeks, and the mean time of initiation of albendazole post-onset of symptoms was approximately 4.5 weeks. The remaining 7 of 17 articles that reported albendazole monotherapy had a presumptive diagnosis, and of those, 1 reported an adverse outcome [145]. The remaining 6 articles reported beneficial outcomes.

Table 1. Statistics of Clinical Outcomes From Clinical Reports and Animal Study Results Associated With the Management of Neuroangiostrongyliasis Using Benzimidazole Anthelmintics

Clinical Outcome	Case Reports		Case Series		Total Number of Clinical Reports	Animal Studies	Total Number of Articles
	Confirmed	Presumptive	Confirmed	Presumptive			
Beneficial	46	10	21	10	87 ^a	38 ^b	125
Ineffective	2	0	2	1	5 ^c	1 ^d	6
Adverse	3	2	0	1	6 ^e	1 ^f	7
Inconclusive	1	0	4	1	6 ^g	0	6
Total number of articles	52	12	27	13	104	40	144

^aReferences [13-99], ^bReferences [100-137], ^cReferences [138-142], ^dReference [143], ^eReferences [144-149], ^fReference [150], ^gReferences [151-156].

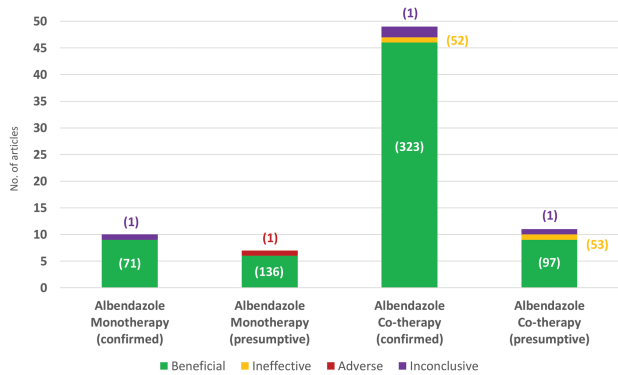


Figure 2. Graphical comparison of clinical reports that described albendazole treatment based on the type of therapy and disease diagnosis. The estimated numbers of patients involved are provided in parentheses. The corresponding references of articles are listed here. References: Albendazole monotherapy (confirmed): beneficial, [14-22]; inconclusive, [156]. Albendazole monotherapy (presumptive): beneficial, [23-28]; adverse, [145]. Albendazole cotherapy (confirmed): beneficial, [13, 29-73]; ineffective, [140]; inconclusive, [151, 153]. Albendazole cotherapy (presumptive): beneficial, [74-82]; ineffective, [139]; inconclusive, [154].

Albendazole–corticosteroid cotherapy

Of the 75 articles that reported benzimidazole-corticosteroid cotherapy, 60 specifically reported use of albendazole (Figure 2). Of those, 49 had a confirmed diagnosis, 2 were classified as inconclusive [151, 153], and 1 reported albendazole–corticosteroid cotherapy to be ineffective [140]. The remaining 46 of 47 articles (97.87%) reported cotherapy to be beneficial. The estimated mean dose of albendazole reported was approximately 15 mg/kg/day or 400 mg twice daily (average body weight to be 60 kg). The estimated duration of cotherapy was approximately 2.5 weeks, the mean time of initiation of cotherapy post-exposure was approximately 3.5 weeks, and the mean time to initiation of cotherapy post-onset of symptoms was approximately 3 weeks. The remaining 11 of 60 articles that reported albendazole–corticosteroid cotherapy described a presumptive diagnosis. Of those, 1 reported cotherapy to be ineffective [139] and 1 was classified as inconclusive [154]. The remaining 9 articles reported beneficial outcomes.

Benzimidazoles Other Than Albendazole

Mebendazole and thiabendazole were the most commonly used benzimidazole anthelmintics in clinical reports after albendazole (Figure 3); in 2 articles, use of flubendazole was reported [97, 152]. Mebendazole use was reported in 12 articles (118 patients); of those, monotherapy use was reported in 4, with 2 reporting adverse outcomes [147, 148], 1 reporting ineffective outcomes [142], and 1 reporting beneficial outcomes [83]. Interestingly, the other 8 articles reported use of corticosteroid cotherapy, and all of those 8 (100%) reported beneficial outcomes (103 patients), irrespective of confirmed or presumptive diagnosis. Similarly, 8 clinical reports described

thiabendazole use (21 patients), with monotherapy use reported in 6. Two articles reported adverse outcomes [144, 146], 2 reported ineffective outcomes [138, 141], and 2 reported thiabendazole to be beneficial [92, 93]. Similar to the outcomes of mebendazole–corticosteroid cotherapy, thiabendazole–corticosteroid cotherapy was reported to be 100% beneficial (2 of 2 articles; 3 patients). Among the ocular angiostrongyliasis reports [175], only 1 advised against the use of benzimidazoles (mebendazole) [148], and the remaining 8 of 9 studies reported beneficial outcomes, primarily with the use of albendazole (Figure 4).

Unspecific or Multiple Benzimidazoles Used

Seven clinical reports reported use of multiple benzimidazole anthelmintics; however, the specific benzimidazole used for the individual patients was not provided (Table 2). Among these 7 reports, 6 confirmed diagnoses according to our study criteria and 1 confirmed infection by peripheral serology (unspecified) [96]. Five of these 7 articles had language that led us to infer that corticosteroids were administered with benzimidazoles as a cotherapy; however, the details of individual patient regimens were not provided. Of these 7 articles, 2 were classified as inconclusive [152, 155] and 1 reported having an adverse outcome in 1 of 3 patients [149]. The remaining 4 reported beneficial outcomes.

ANIMAL DATA

We found 40 articles that investigated the efficacy and safety of various benzimidazole anthelmintics using animal models (Figure 5). The total number of animals included in these

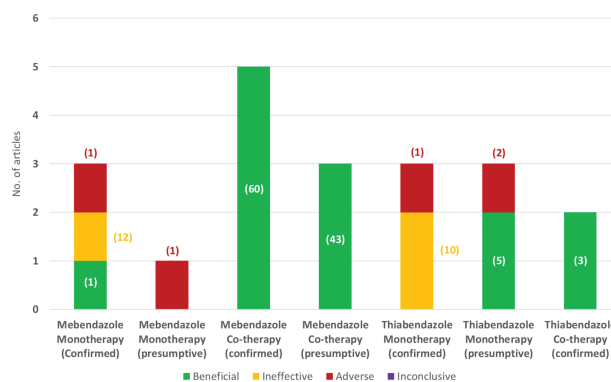


Figure 3. Graphical comparison of clinical reports that described mebendazole or thiabendazole treatment based on the type of therapy and disease diagnosis. The estimated numbers of patients involved are provided in parentheses. The corresponding references of articles are listed here. References: Mebendazole monotherapy (confirmed): beneficial, [83]; ineffective, [142]; adverse, [148]. Mebendazole monotherapy (presumptive): adverse, [147]. Mebendazole cotherapy (confirmed): beneficial, [84-88]. Mebendazole cotherapy (presumptive): beneficial, [89-91]. Thiabendazole monotherapy (confirmed): ineffective, [138-141]; adverse, [146]. Thiabendazole monotherapy (presumptive): beneficial, [92, 93]; adverse, [144]. Thiabendazole cotherapy (confirmed): beneficial, [94, 95].

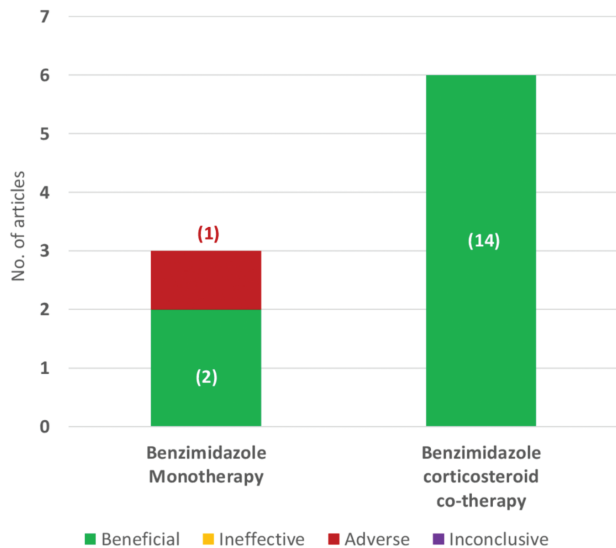


Figure 4. Graphical comparison of clinical reports that described a diagnosis of ocular angiostrongyliasis. The estimated numbers of patients involved are provided in parentheses. The corresponding references of articles are listed here. Reference: Benzimidazole monotherapy: beneficial, [21, 83]; adverse, [148]. Benzimidazole–corticosteroid cotherapy: beneficial, [30, 39, 42, 65, 70, 88].

studies was estimated to be 2561; the exact number was undeterminable based on the data provided in some of the published studies. The animal studies were analyzed separately from the clinical reports, and the summary of these studies is provided in [Supplementary Table 2](#). Twenty-two of 40 animal studies reported use of albendazole (994 animals); 5 of those used corticosteroid cotherapy. Many of these animal studies concurrently reported on the efficacy and safety of other agents as cotherapy with albendazole, for example, Chinese medicines, immune modulators, and fungal extracts, all with beneficial outcomes. Similarly, 8 articles reported on the efficacy of mebendazole; of those, 1 used mebendazole–betamethasone (corticosteroid) cotherapy [100]. Six studies investigated the

Table 2. Categorization of Clinical Reports That Used Multiple Benzimidazole Anthelmintics With or Without Corticosteroid Cotherapy

Multiple Benzimidazole Anthelmintics	
Monotherapy	Corticosteroid Cotherapy
Beneficial Outcome (n = 1 Article, 12 Patients ^a)	Beneficial Outcome (n = 3 Articles, 39 Patients ^a)
Albendazole, thiabendazole [96]	Albendazole, flubendazole [97] Albendazole, mebendazole [98, 99]
Inconclusive (n = 1 Article, 8 Patients ^a)	Inconclusive (n = 1 Article, 7 Patients ^a)
Mebendazole, thiabendazole [155]	Albendazole, mebendazole, flubendazole [152] Adverse outcome (n = 1 Article, 1 Patient ^a) Albendazole, thiabendazole [149]

^aThe number of patients involved is estimated.

efficacy of thiabendazole (482 animals) with primarily beneficial results. In 8 studies, flubendazole was used (65 animals), and 2 studies investigated the efficacy of parabendazole [101, 124]; all reporting beneficial outcomes.

Of these 40 animal studies involving an estimated 2561 animals, only 1 reported the use of benzimidazole anthelmintics (thiabendazole) to be ineffective in 3 rats [143]. Similarly, 1 study advised against the use of benzimidazoles (albendazole) with 28 rabbits [150]. The remaining 38 (95%) animal studies, involving approximately 2530 animals, reported benzimidazoles to be beneficial and effective against neuroangiostrongyliasis.

DISCUSSION

Benzimidazoles are one of the few classes of anthelmintics that are effective against *A. cantonensis* [157], especially albendazole, which is currently the only available FDA-approved benzimidazole known to be capable of crossing the BBB [11]. An increasing number of guidelines recommend the use of albendazole–corticosteroid cotherapy for the management of neuroangiostrongyliasis, for example, the Sydney Children’s Hospital Network, Australia (2018) [158]; the Children’s Health Queensland Hospital and Health Services, Australia (2019) [159]; the Hilo Medical Center, Hawaii (2020) [160]; and the Hawaii Governor’s Joint Task Force on Rat Lungworm Disease Clinical Subcommittee [9]. Experimental studies have also demonstrated the in vitro efficacy of albendazole on *A. cantonensis* L3 [157, 161]. However, doubt remains regarding albendazole’s safety, primarily due to concerns that it may cause further inflammation and associated complications induced by the killed larvae in the brain [3, 10]. For further clarification, we extensively reviewed and compiled relevant reports on its use in the treatment of angiostrongyliasis, but not without associated challenges. These studies involved a broad array of objectives, methodologies, and data reporting standards that were used over the time span of the articles included. Other challenges more specific to angiostrongyliasis were the lack of specific diagnostic markers or accepted diagnostic guidelines to indicate the severity of infection and the nonspecific nature of disease presentation.

Given the preponderance of evidence that supports the use of benzimidazoles for management of neuroangiostrongyliasis (90.5% of articles), studies that indicated otherwise deserve further review. Those articles that reported adverse outcomes were generally vague, using such descriptions as “symptoms remarkably worsened” [144, 147], “deterioration of symptoms” [145, 148], “condition exacerbated” [145], “relapse of symptoms” [146], and so on. The fact that no new symptoms were reported suggests that these adverse outcomes were the result of an increase in the severity of existing conditions and thus leads us to believe that the adverse outcomes reported in these articles are due to the inefficacy of

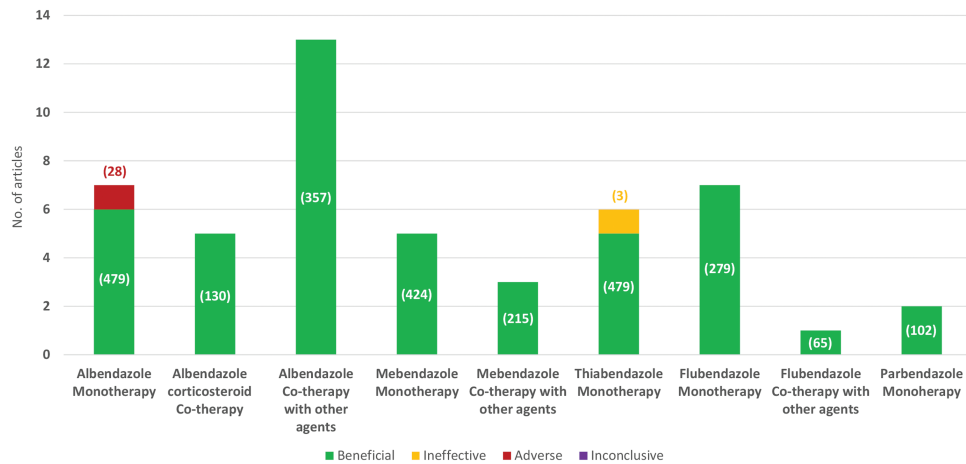


Figure 5. Graphical comparison of animal studies that investigated the efficacy and safety of benzimidazole anthelmintics for neuroangiostrongyliasis. The estimated numbers of animals involved are provided in parentheses. The corresponding references of articles are listed here. References: Albendazole monotherapy: beneficial, [102-107]; adverse, [150]. Albendazole–corticosteroid cotherapy: beneficial, [108-112]. Albendazole cotherapy with other agents: beneficial, [108, 109, 111, 113-122]. Mebendazole monotherapy: beneficial, [106, 123-126]. Mebendazole cotherapy with other agents: beneficial, [100, 127, 128]. Thiabendazole monotherapy: beneficial, [124, 129-132]; ineffective, [143]. Flubendazole cotherapy with other agents: beneficial, [125, 126, 130, 133-136]. Flubendazole cotherapy with other agents: beneficial, [137]. Parbendazole monotherapy: beneficial, [101-124].

benzimidazole rather than drug–parasite immune response or benzimidazole-related toxicity. Additionally, the articles that reported adverse outcomes had certain factors in common; they used either mebendazole or thiabendazole monotherapy (not albendazole) or made a presumptive (not confirmed) diagnosis.

The use of mebendazole appeared to be beneficial in 75% of clinical reports and 100% of animal studies. Berkhout et al [147] reported 2 presumptive cases in which only 1 patient received mebendazole as discharge medication and reported worsening of symptoms 24 hours post-discharge. Since the larvicidal effect of benzimidazole anthelmintics occurs during subsequent cell division in the nematode [162], which takes at least 1 week [163, 164], these early adverse events are unlikely due to mebendazole. Tseng et al [142] reported 9 confirmed cases who were treated with mebendazole for approximately 6 days, with or without the coadministration of corticosteroids, with ineffective outcomes. However, the specifics of the treatment were not reported, and mebendazole’s inability to cross the BBB [165] renders it less than ideal for the management of neuroangiostrongyliasis [166], as the parasite likely reached the central nervous system prior to administration of the drug.

The use of thiabendazole is similarly problematic. Thiabendazole is a predecessor of albendazole and mebendazole, with the ability to cross the BBB. However, due to its severe side effects, such as hepatitis, tinnitus, headaches, dizziness, photosensitivity, and mood swings, it has been withdrawn from the market in most countries (<https://www.ncbi.nlm.nih.gov/books/NBK548194/>) [167]. Many of these side effects mimic the symptoms of neuroangiostrongyliasis [1], making it difficult

to distinguish between the disease and the side effects from thiabendazole. While 83% of the animal studies of thiabendazole found it to be effective, only 50% of the clinical reports showed beneficial effects compared with mebendazole (75%) and albendazole (96%).

As an illustration of thiabendazole’s lack of efficacy, Kliks et al [138] describes 16 fishermen who were infected; 9 were treated with thiabendazole for 3 days (a comparatively short treatment duration), with no appreciable effect on the disease course. Similarly, Scemama [141] reported on a 14-month-old for whom thiabendazole was initiated for 1 week, but there was no improvement in her condition. Bisseru et al [146] reported on a patient who was given thiabendazole for 2 weeks, and the patient was discharged symptom-free. However, approximately 10 days later, the patient was readmitted because of a relapse of symptoms, and it was concluded that the relapse was due to an inflammatory reaction to the dead or dying larvae in the brain. Similarly, Bowden [144] reported on 2 presumptive cases who died of neuroangiostrongyliasis, but neither of the deceased patients actually received thiabendazole. The authors also reported adverse outcomes with the use of thiabendazole in 2 other patients who eventually recovered. It is likely that the results from these early studies with thiabendazole have substantially contributed to current concerns regarding the use of benzimidazoles for neuroangiostrongyliasis.

All of the animal studies that were reviewed had confirmed diagnoses of neuroangiostrongyliasis since they are experimentally infected, and only 1 of the 40 animal studies reported an adverse outcome [150]. Wang et al (2006) challenged each rabbit in their study with 400 L3s and administered single-dose albendazole (5 mg/kg). The magnetic resonance imaging,

histopathology, and inflammatory markers all indicated that albendazole had increased cerebral inflammation in these rabbits compared with the control groups. However, it should be emphasized that this is the only study that used rabbits to investigate the efficacy of benzimidazole anthelmintics and that this is the only animal study of albendazole that used more than 100 L3s to induce infection. Perhaps, a dose greater than 5 mg/kg/day of albendazole would be required to produce a significant effect against 400 L3s, considering how this was the only animal study to report an adverse outcome. Additionally, while Guilhon et al [143] reported thiabendazole therapy to be ineffective, other animal studies [124, 129-132] reported thiabendazole to be beneficial. Lämmle and Weidner [124] demonstrated the beneficial effects of fenbendazole, a commonly used veterinary benzimidazole anthelmintic.

Albendazole is currently the preferred anthelmintic for management of neuroangiostrongyliasis. Among the clinical reports with a presumptive diagnosis, only 1 reported an adverse outcome 24 hours post-initiation of albendazole monotherapy [145]. However, it is unlikely that the patient's condition would have become exacerbated after 24 hours of albendazole therapy, as discussed above in the article by Berkhout et al [147]. Similarly, among clinical reports of albendazole–corticosteroid cotherapy, only 1 reported the cotherapy to be ineffective [139]. Chotmongkol et al [139] conducted a single-centered, randomized, clinical trial to compare the efficacy of albendazole–prednisolone cotherapy vs prednisolone alone for resolving the duration of headaches and found no statistical difference in the duration of headaches between the 2 study groups ($P = .49$), deeming it ineffective.

Among clinical reports with a confirmed diagnosis, albendazole monotherapy appears 100% effective. The efficacy of albendazole–corticosteroid cotherapy similarly appears to be very effective (97.87%), with only 1 article reporting it to be ineffective [140]. Nevertheless, there are still concerns of initiating further cerebral inflammation from the dying larvae in the brain and associated complications. The FDA currently recommends the coadministration of a corticosteroid along with albendazole for helminths that are capable of migrating to the brain, such as in neurocysticercosis [168]. Additionally, many clinical reports have documented corticosteroid monotherapy to be beneficial for relieving the symptoms associated with neuroangiostrongyliasis, primarily the duration of headaches [169-173]. In contrast, few have reported corticosteroid monotherapy to be ineffective in severe cases [174]. Therefore, while the literature with a confirmed diagnosis of neuroangiostrongyliasis suggests no evidence that albendazole monotherapy causes cerebral inflammation, considering the potential benefit of relieving the symptoms and out of an abundance of caution, coadministration of a high-dose corticosteroid is recommended.

CONCLUSIONS

Based on the results provided in 144 articles (estimate of 1034 patients and 2561 animals) on the use of benzimidazole anthelmintics for the treatment of neuroangiostrongyliasis, 4.1% (6 of 144) were unspecific regarding the treatment aspects and thus considered inconclusive. Of the remaining articles, 90.5% (125 of 138) considered the use of benzimidazoles as beneficial (885 patients, 2530 animals), 4.3% (6 of 138) as being safe but ineffective (73 patients, 3 animals), and 5% (7 of 138) reported adverse outcomes (7 patients, 28 animals). Clinical reports with a confirmed diagnosis reported albendazole monotherapy to be 100% (9 of 9 articles) effective (743 patients, 479 animals), while the efficacy of albendazole–corticosteroid cotherapy was reported to be 97.8% (46 of 47 articles) effective (323 patients, 130 animals). These animal studies from 18 laboratories and clinical reports from 24 countries provide highly supportive evidence for the safe and effective use of benzimidazole anthelmintics, especially albendazole–corticosteroid cotherapy, for the management of neuroangiostrongyliasis.

Supplementary Data

Supplementary materials are available at *Clinical Infectious Diseases* online. Consisting of data provided by the authors to benefit the reader, the posted materials are not copyedited and are the sole responsibility of the authors, so questions or comments should be addressed to the corresponding author.

Notes

Acknowledgments. The authors thank Donna Ohora and Dr Supakit Wongwiwatthanakut for providing direction to this study, Dr Alex Cordova for translation of Spanish articles, Kirsten Snook for initial data collection, and the working group of the Clinical Subcommittee of the Hawaii Governor's Joint Task Force on Rat Lungworm Disease for their suggestions on preparing this manuscript. This work is dedicated to all of those who have fought and been affected by rat lungworm disease.

Financial support. This work was supported by the Hawaii State Legislature and the Daniel K. Inouye College of Pharmacy.

Potential conflicts of interest. All authors: No reported conflicts of interest. All authors have submitted the ICMJE Form for Disclosure of Potential Conflicts of Interest.

References

1. Wang QP, Lai DH, Zhu XQ, Chen XG, Lun ZR. Human angiostrongyliasis. *Lancet Infect Dis* 2008; 8:621-30.
2. Ji L, Yiyue X, Xujin H, et al. Study on the tolerance and adaptation of rats to *Angiostrongylus cantonensis* infection. *Parasitol Res* 2017; 116:1937-45.
3. Prociw P, Turner M. Neuroangiostrongyliasis: the “subarachnoid phase” and its implications for anthelmintic therapy. *Am J Trop Med Hyg* 2018; 98:353-9.
4. Pien FD, Pien BC. *Angiostrongylus cantonensis* eosinophilic meningitis. *Int J Infect Dis* 1999; 3:161-3.
5. Graeff-Teixeira C, da Silva AC, Yoshimura K. Update on eosinophilic meningoenzephalitis and its clinical relevance. *Clin Microbiol Rev* 2009; 22:322-48, Table of Contents.
6. Abongwa M, Martin RJ, Robertson AP. A brief review on the mode of action of antinematodal drugs. *Acta Vet (Beogr)* 2017; 67:137-52.
7. Kamanna K. Synthesis and pharmacological profile of benzimidazoles. In: Chemistry and applications of benzimidazole and its derivatives. London, UK: IntechOpen, 2019:51-69.
8. Ramírez T, Benítez-Bribiesca L, Ostrosky-Wegman P, Herrera LA. In vitro effects of albendazole and its metabolites on the cell proliferation kinetics and micronuclei frequency of stimulated human lymphocytes. *Arch Med Res* 2001; 32:119-22.

9. Ansdell V, Kramer KJ, McMillan JK, et al. Guidelines for the diagnosis and treatment of neuroangiostrongyliasis: updated recommendations. *Parasitology* **2021**; 148:227-33.
10. Ansdell V, Wattanagoon Y. *Angiostrongylus cantonensis* in travelers: clinical manifestations, diagnosis, and treatment. *Curr Opin Infect Dis* **2018**; 31:399-408.
11. Sotelo J, Jung H. Pharmacokinetic optimisation of the treatment of neurocysticercosis. *Clin Pharmacokinet* **1998**; 34:503-15.
12. Moher D, Liberati A, Tetzlaff J, et al. Preferred reporting items for systematic reviews and meta-analyses: the PRISMA statement. *PLoS Med* **2009**; 6:1-6.
13. Luessi F, Sollors J, Torzewski M, et al. Eosinophilic meningitis due to *Angiostrongylus cantonensis* in Germany. *J Travel Med* **2009**; 16:292-4.
14. Elghawy AA, Skopis M, Davis J, Bag-Ozbek A. Angiostrongyliasis infection masquerading as granulomatosis with polyangiitis: a case-based review. *Rheumatol Int* **2020**; 40:1171-6.
15. Hwang KP, Chen ER. Clinical studies on angiostrongyliasis cantonensis among children in Taiwan. *Southeast Asian J Trop Med Public Health* **1991**; 22:194-9.
16. Jitpimolmard S, Sawanyawisuth K, Morakote N, et al. Albendazole therapy for eosinophilic meningitis caused by *Angiostrongylus cantonensis*. *Parasitol Res* **2007**; 100:1293-6.
17. Lin JX, Li YS, Zhu K, et al. [Epidemiological study on group infection of *Angiostrongylus cantonensis* in Changle City]. *Zhongguo Ji Sheng Chong Xue Yu Ji Sheng Chong Bing Za Zhi* **2003**; 21:110-2.
18. Monteiro MD, de Carvalho Neto EG, dos Santos IP, et al. Eosinophilic meningitis outbreak related to religious practice. *Parasitol Int* **2020**; 78:78-81.
19. Nalini A, Ramakrishna A, Dekumoy P, et al. Severe form of radiculo-myeloneuropathy with meningo-encephalitis secondary to *Angiostrongylus cantonensis* infection: unusual corpus callosal lesions and serial magnetic resonance imaging findings. *Neuro India* **2013**; 61:414-8.
20. Ramirez-Avila L, Slome S, Schuster FL, et al. Eosinophilic meningitis due to *Angiostrongylus* and *Gnathostoma* species. *Clin Infect Dis* **2009**; 48:322-7.
21. Sinawat S, Yospaiboon Y, Sinawat S. Subretinal angiostrongyliasis-induced optic neuritis. *Clin Ophthalmol* **2013**; 7:977-9.
22. Zhang R-Y, Li L-S, Lin C-X, Cheng B-J, Lin J-X. Two cases of *Angiostrongylus cantonensis*. *Zhongguo Ji Sheng Chong Xue Yu Ji Sheng Chong Bing Za Zhi* **2005**; 23:1.
23. Edmar A, Slim G, Boumahni B, et al. Meningites a eosinophiles et angiostrongylose chez le nourrisson l'île de la Reunion: a propos de deux cas. *Med Mal Infect* **1999**; 29:480-2.
24. Li LS, Lin JX, Zhang RY. [Heavy infection of *Angiostrongylus cantonensis* due to swallowing raw slugs]. *Zhongguo Ji Sheng Chong Xue Yu Ji Sheng Chong Bing Za Zhi* **2006**; 24:460, 465.
25. Varghese B, Menon MK, Pratap T, et al. Eosinophilic meningitis: report of three cases from a hilly area in Kerala. *Ann Indian Acad Neurol* **2019**; 22:108-11.
26. Wang J, Zhang X, Yin C, et al. Clinical analysis on acute hepatic injury induced by albendazole in patients with *Angiostrongyliasis cantonensis*. *J Pathog Biol* **2008**; 3:209-11.
27. Wang Y. Treatment and nursing of 33 cases with *Angiostrongyliasis cantonensis*. *J Pathog Biol* **2009**; 4:3-4.
28. Yang D. Nursing experience of 57 patients with *Angiostrongylus cantonensis*. *Parasitoses Infect Dis* **2016**; 14:121-3.
29. Ali AB, Van den Enden E, Van Gompel A, Van Esbroeck M. Eosinophilic meningitis due to *Angiostrongylus cantonensis* in a Belgian traveller. *Travel Med Infect Dis* **2008**; 6:41-4.
30. Baheti NN, Sreedharan M, Krishnamoorthy T, Nair MD, Radhakrishnan K. Neurological picture. Eosinophilic meningitis and an ocular worm in a patient from Kerala, south India. *J Neurol Neurosurg Psychiatry* **2008**; 79:271.
31. Blair NF, Orr CF, Delaney AP, Herkes GK. *Angiostrongylus meningoencephalitis*: survival from minimally conscious state to rehabilitation. *Med J Aust* **2013**; 198:440-2.
32. Brummaier T, Bertschy S, Arn K, et al. A blind passenger: a rare case of documented seroconversion in an *Angiostrongylus cantonensis* induced eosinophilic meningitis in a traveler visiting friends and relatives. *Trop Dis Travel Med Vaccines* **2019**; 5:4-9.
33. Cattaneo C, Hoarau M, Valois S, et al. Tetraventricular hydrocephalus following eosinophilic meningitis due to *Angiostrongylus cantonensis* in a 14-month-old boy from Mayotte: a case report. *Open Forum Infect Dis* **2021**. Doi:10.1093/ofid/ofab031.
34. Chau TT, Thwaites GE, Chuong LV, Sinh DX, Farrar JJ. Headache and confusion: the dangers of a raw snail supper. *Lancet* **2003**; 361:1866.
35. Chen W, Zhong J, Chen H, Wu S, Ding L. Eosinophilic meningitis: 31 cases report. *China J Misdiagn* **2006**; 6:4667-8.
36. Chen DZ, Hong ZLIU, Control D, Kunming P. Characteristics of 44 patients with *Angiostrongyliasis cantonensis* in Kunming. *China Trop Med* **2011**; 11:1494-5.
37. Chiong F, Lloyd AR, Post JJ. Severe eosinophilic meningoencephalitis secondary to suspected neuroangiostrongyliasis with a good clinical outcome. *Case Rep Infect Dis* **2019**; 2019:4037196.
38. Dard C, Piloquet JE, Qvarnstrom Y, et al. First evidence of angiostrongyliasis caused by *Angiostrongylus cantonensis* in Guadeloupe, Lesser Antilles. *Am J Trop Med Hyg* **2017**; 96:692-7.
39. Andrade GC, Dias JRO, Maia A, et al. Intravitreal *Angiostrongylus cantonensis*: first case report in South America. *Arq Bras Oftalmol* **2018**; 81:63-5.
40. Diao Z, Yin C, Jin E. Images in clinical tropical medicine. Myelitis caused by infection of *Angiostrongylus cantonensis*. *Am J Trop Med Hyg* **2010**; 83:1176-7.
41. Diao Z, Jin E, Yin C. *Angiostrongylus cantonensis*: lesions in brain and spinal cord. *Am J Trop Med Hyg* **2010**; 82:519.
42. Diao Z, Wang J, Qi H, Li X, Zheng X, Yin C. Treatment of angiostrongyliasis using a combination of albendazole and dexamethasone: the results of a retrospective and comparative study. *Ann Trop Med Parasitol* **2011**; 105:65-9.
43. Evans-Gilbert T, Lindo JF, Henry S, Brown P, Christie CD. Severe eosinophilic meningitis owing to *Angiostrongylus cantonensis* in young Jamaican children: case report and literature review. *Paediatr Int Child Health* **2014**; 34:148-52.
44. Fischer PR. Houston, We have a problem: eosinophilic meningitis in children. *Infect Dis Alert; Atlanta* **2016**; 36:1-3.
45. Flerlage T, Qvarnstrom Y, Noh J, et al. *Angiostrongylus cantonensis* eosinophilic meningitis in an infant, Tennessee, USA. *Emerg Infect Dis* **2017**; 23:1756-8.
46. Foster CE, Nicholson EG, Chun AC, et al. *Angiostrongylus cantonensis* infection: a cause of fever of unknown origin in pediatric patients. *Clin Infect Dis* **2016**; 63:1475-8.
47. Graber D, Hebert JC, Jaffar-Bandjee MC, Alessandri JL, Combes JC. Formes graves de méningites à éosinophiles chez le nourrisson à Mayotte. A propos de 3 observations. *Bull la Soc Pathol Exot* **1999**; 92:164-6.
48. Guan H, Hoi C, Liying C, Chen L. Eosinophilic meningitis caused by infection of *Angiostrongylus cantonensis* in a traveler. *Chinese J Contemp Neurol Neurosurg* **2013**; 13:55-7.
49. Al Hammoud R, Naves SL, Murphy JR, Heresi GP, Butler IJ, Perez N. *Angiostrongylus cantonensis* meningitis and myelitis, Texas, USA. *Emerg Infect Dis* **2017**; 23:1037-8.
50. Han JH, Zhu YH, Ji WZ, Li Y. A clinical analysis on 28 cases with eosinophilic meningoencephalitis. *J Pathog Biol* **2006**; 1:2-3.
51. Hiraoka T, Cuong NC, Hamaguchi S, et al. Meningitis patients with *Angiostrongylus cantonensis* may present without eosinophilia in the cerebrospinal fluid in Northern Vietnam. *PLoS Negl Trop Dis* **2020**; 14:e0008937.
52. Kirsch S, Dekumyoy P, Löscher T, Haberl RL. A case of eosinophilic meningitis in Germany. *J Neurol* **2008**; 255:1102-3.
53. Kwon E, Ferguson TM, Park SY, et al. A severe case of *Angiostrongylus* eosinophilic meningitis with encephalitis and neurologic sequelae in Hawai'i. *Hawaii J Med Public Health* **2013**; 72:41-5.
54. Lammers AJ, Goorhuis A, van de Beek D, et al. Eosinophilia à deux: a brain nagging souvenir from the Philippines. *Infection* **2015**; 43:615-7.
55. Li H, Xu F, Gu JB, Chen XG. A severe eosinophilic meningoencephalitis caused by infection of *Angiostrongylus cantonensis*. *Am J Trop Med Hyg* **2008**; 79:568-70.
56. Lim JM, Lee CC, Wilder-Smith A. Eosinophilic meningitis caused by *Angiostrongylus cantonensis*: a case report and literature review. *J Travel Med* **2004**; 11:388-90.
57. Liu EW, Schwartz BS, Hysmith ND, et al. Rat lungworm infection associated with central nervous system disease. *MMWR Morb Mortal Wkly Rep* **2018**; 67:825-8.
58. Lv S, Zhang Y, Chen SR, et al. Human angiostrongyliasis outbreak in Dali, China. *PLoS Negl Trop Dis* **2009**; 3:e520.
59. Mansbridge CT, Norton NJ, Fox SM. Case report: protracted eosinophilic meningitis due to probable angiostrongyliasis. *Am J Trop Med Hyg* **2020**; 104:731-3.
60. McAuliffe L, Fortin Ensign S, Larson D, et al. Severe CNS angiostrongyliasis in a young marine: a case report and literature review. *Lancet Infect Dis* **2018**; 19:1-11.
61. Nguyen Y, Rossi B, Argy N, Zarrouk V, Fantin B, Lefort A. Méningite à éosinophiles due à *Angiostrongylus cantonensis*: premier cas français autochtone. *Rev Méd Interne* **2016**; 37:A220.
62. Nguyen Y, Rossi B, Argy N, et al. Autochthonous case of eosinophilic meningitis caused by *Angiostrongylus cantonensis*, France, 2016. *Emerg Infect Dis* **2017**; 23:1045-6.
63. Rai S, Madi D, Pai S, Baliga S. Unusual larva in the CSF and unique MRI findings in a case of eosinophilic meningitis. *J Clin Imaging Sci* **2014**; 4:76.
64. Rau C, Bialek R, Richter S, Lindner A. Kopfschmerzen nach aufenthalt in der Dominikanischen Republik. *Dtsch Med Wochenschr* **2006**; 131:1656-959.
65. Sinawat S, Trisakul T, Choi S, Morley M, Sinawat S, Yospaiboon Y. Ocular angiostrongyliasis in Thailand: a retrospective analysis over two decades. *Clin Ophthalmol* **2019**; 13:1027-31.
66. Thu HP, Huu DN, Thu TLT, Van LN. Case report: *Angiostrongylus cantonensis* meningoencephalitis in a 9-month-old baby in Vietnam. *Am J Trop Med Hyg* **2020**; 103:723-6.

67. Wang X, Huang H, Dong Q, et al. A clinical study of eosinophilic meningoencephalitis caused by angiostrongyliasis. *Chin Med J (Engl)* **2002**; 115:1312-5.
68. Wang J, Qi H, Diao Z, et al. An outbreak of *Angiostrongylus cantonensis* in Beijing. *J Parasitol* **2010**; 96:377-81.
69. Wang H, Lu L, She D, et al. Eating centipedes can result in *Angiostrongylus cantonensis* infection: two case reports and pathogen investigation. *Am J Trop Med Hyg* **2018**; 99:743-8.
70. Widder JR, Fallah S, Mondzelewski TJ. A case report of slug ingestion causing eosinophilic meningitis, papilledema, and pronounced motor weakness in a US marine. *Mil Med* **2020**; 185:317-21.
71. Ye W, Hu H, Zhang Y. The first case report of child angiostrongyliasis in Wenzhou. *温州医学院学报* **1999**; 29:11-3.
72. Xie M, Zhou Z, Guo S, Li Z, Zhao H, Deng J. Next-generation sequencing specifies *Angiostrongylus* eosinophilic meningoencephalitis in infants: two case reports. *Medicine* **2019**; 98:1-6.
73. Zhou Z, Barennes H, Zhou N, Ding L, Zhu YH, Strobel M. Épidémies de méningites à éosinophiles au Yunnan: aspects épidémiologiques, cliniques et thérapeutiques. *Bull Soc Pathol Exot* **2009**; 102:75-80.
74. Busse J, Gottlieb D, Ferreras K, Bain J, Schechter W. Pharmacological management of severe neuropathic pain in a case of eosinophilic meningitis related to *Angiostrongylus cantonensis*. *Case Rep Anesthesiol* **2018**; 2018:5038272.
75. Chotmongkol V, Wongitrat C, Sawadpanit K, Sawanyawisuth K. Treatment of eosinophilic meningitis with a combination of albendazole and corticosteroid. *Southeast Asian J Trop Med Public Health* **2004**; 35:172-4.
76. Ibraheem R, Oladele D, Mohammed S, Gobir A. Is this eosinophilic meningitis in a Nigerian child? *J Med Trop* **2016**; 18:113-5.
77. Malvy D, Ezzedine K, Receveur MC, et al. Cluster of eosinophilic meningitis attributable to *Angiostrongylus cantonensis* infection in French policemen troop returning from the Pacific Islands. *Travel Med Infect Dis* **2008**; 6:301-4.
78. Pai S, Madi D, Achappa B, Mahalingam S, Kendambadi R. An interesting case of eosinophilic meningitis. *J Clin Diagn Res* **2013**; 7:734-5.
79. Parameswaran K. Case series of eosinophilic meningoencephalitis from South India. *Ann Indian Acad Neurol* **2006**; 9:217-23.
80. Shah I, Barot S, Madvariya M. Eosinophilic meningitis: a case series and review of literature of *Angiostrongylus cantonensis* and *Gnathostoma spinigerum*. *Indian J Med Microbiol* **2015**; 33:154-8.
81. Yao Z, Du Q. Diagnosis and treatment of 42 angiostrongyliasis cases in Dali prefecture. *China Trop Med* **2011**; 11:430-1.
82. Ye F. Treatment and nursing for the 13 cases of Canton nematodiasis. *J Dali Univ* **2009**; 8:59-60.
83. Mattis A, Mowatt L, Lue A, Lindo J, Vaughan H. Ocular angiostrongyliasis—first case report from Jamaica. *West Indian Med J* **2009**; 58:383-5.
84. Chen CY, Kuo CC, Lo CP, Huang MY, Wang YM, Wang WY. Eosinophilic meningoencephalitis caused by *Angiostrongylus cantonensis*. *QJM* **2014**; 107: 573-5.
85. Tsai HC, Liu YC, Kunin CM, et al. Eosinophilic meningitis caused by *Angiostrongylus cantonensis*: report of 17 cases. *Am J Med* **2001**; 111:109-14.
86. Tsai HC, Chung LY, Chen ER, et al. Association of matrix metalloproteinase-9 and tissue inhibitors of metalloproteinase-4 in cerebrospinal fluid with blood-brain barrier dysfunction in patients with eosinophilic meningitis caused by *Angiostrongylus cantonensis*. *Am J Trop Med Hyg* **2008**; 78:20-7.
87. Wan KS, Weng WC. Eosinophilic meningitis in a child raising snails as pets. *Acta Trop* **2004**; 90:51-3.
88. Wang LC, Wang IH, Jou JR. Optic neuritis secondary to *Angiostrongylus cantonensis* infection. *Ocul Immunol Inflamm* **2006**; 14:189-91.
89. Chotmongkol V, Sawadpanitch K, Sawanyawisuth K, Louhawilai S, Limpawattana P. Treatment of eosinophilic meningitis with a combination of prednisolone and mebendazole. *Am J Trop Med Hyg* **2006**; 74:1122-4.
90. Howe K. A severe case of rat lungworm disease in Hawai'i. *Hawaii J Med Public Health* **2013**; 72:46-8.
91. Leone S, De Marco M, Ghirga P, Nicastri E, Esposito M, Narciso P. Eosinophilic meningitis in a returned traveler from Santo Domingo: case report and review. *J Travel Med* **2007**; 14:407-10.
92. Saltos N, Ghosh HK, Gan A. Eosinophilic meningitis (angiostrongylosis): a probable case. *Med J Aust* **1975**; 1:561-2.
93. Marichal ASM, Zulueta SE, Fajardo FL, López AM. Meningoencefalitis eosinofílica: a propósito de 5 observaciones. *Rev Cubana Med* **1997**; 36:29-35.
94. Ko RC, Chan SW, Chan KW, et al. Four documented cases of eosinophilic meningoencephalitis due to *Angiostrongylus cantonensis* in Hong Kong. *Trans R Soc Trop Med Hyg* **1987**; 81:807-10.
95. Koo J, Pien F, Kliks MM. *Angiostrongylus* (*Parastrongylus*) eosinophilic meningitis. *Rev Infect Dis* **1988**; 10:1155-62.
96. Buissoniere R, Matecki S. Les meningites a eosinophiles chez l'enfant en Nouvelle-Caledonie. Etude retrospective de 22 cas. *Arch Pediatr* **1997**; 105:4.
97. Oehler E, Ghawche F, Delattre A, Berberian A, Levy M, Valour F. *Angiostrongylus cantonensis* eosinophilic meningitis: a clinical study of 42 consecutive cases in French Polynesia. *Parasitol Int* **2014**; 63:544-9.
98. Souvignat S. Méningite à éosinophiles et angiostrongylose aux Comores, une réalité à ne pas sous-estimer. À propos de six nouveaux cas. *Bull la Société Pathol Exot* **2007**; 100:154-63.
99. Yang B, Yang L, Chen Y, Lu G. Magnetic resonance imaging findings and clinical manifestations in cerebral angiostrongyliasis from Dali, China. *Brain Behav* **2019**; 9:1-8.
100. Hayashi M. Studies on chemotherapy of parasite helminths (XXX); clinical and pathological changes in mice infected with *Angiostrongylus cantonensis* and treatment with mebendazole and betamethasone. *Japanese J Parasitol* **1987**; 36:80-7.
101. Kamath VR, Menon S, Renapurkar DM. Larvicidal effect of perbenzazole on experimental infection of *Angiostrongylus cantonensis* in mice. *Chemotherapy* **1987**; 33:445-7.
102. Geng Y-J, Huang D-N, Gao S-T, et al. Immunologic effect of albendazole on treatment of *Angiostrongylus cantonensis* infection. *Acta Parasitol Medica Entomol Sin* **2011**; 18:70-5.
103. Hwang KP, Chen ER. Larvicidal effect of albendazole against *Angiostrongylus cantonensis* in mice. *Am J Trop Med Hyg* **1988**; 39:191-5.
104. Lakwo TT, Ishih A, Terada M, Sano M. Effects of albendazole against larval and adult *Angiostrongylus cantonensis* in rats. *Parasitol Int* **1998**; 47:281-8.
105. Lan KP, Wang CJ, Lai SC, et al. The efficacy of therapy with albendazole in mice with parasitic meningitis caused by *Angiostrongylus cantonensis*. *Parasitol Res* **2004**; 93:311-7.
106. Luo YS, He J. Larvicidal effects of albendazole and mebendazole on larvae of *Angiostrongylus cantonensis* in rats. *广东药学院学报* **1995**; 11:161-3.
107. Wei Y, Hong Q, Chen D, et al. Permissibility of Mongolian gerbil for *Angiostrongylus cantonensis* infection and utility of this animal model for anthelmintic studies. *Parasitol Res* **2014**; 113:1687-93.
108. Feng F, Feng Y, Liu Z, et al. Effects of albendazole combined with TSII-A (a Chinese herb compound) on optic neuritis caused by *Angiostrongylus cantonensis* in BALB/c mice. *Parasit Vectors* **2015**; 8:1-8.
109. Feng Y, Feng F, Zheng C, et al. Tanshinone IIA attenuates demyelination and promotes remyelination in *A. cantonensis*-infected BALB/c mice. *Int J Biol Sci* **2019**; 15:2211-23.
110. Guo P, Zhang X, Gan M, et al. Research on the therapeutic effect of albendazole and dexamethasone against *Angiostrongylus cantonensis*. *Chinese J Zoonoses* **2008**; 24:159-62.
111. Li Y, Tang JP, Chen DR, et al. The use of albendazole and diammonium glycyrrhizinate in the treatment of eosinophilic meningitis in mice infected with *Angiostrongylus cantonensis*. *J Helminthol* **2013**; 87:1-11.
112. Tu WC, Lai SC. *Angiostrongylus cantonensis*: efficacy of albendazole-dexamethasone co-therapy against infection-induced plasminogen activators and eosinophilic meningitis. *Exp Parasitol* **2006**; 113:8-15.
113. Chen K-M, Wang C-P, Lai C-S. Albendazole and long-dan-cao co-therapy against *Angiostrongylus cantonensis*-induced matrix metalloproteinase-9 and eosinophilic meningitis. *Chung Shan Med J* **2006**; 17:063-70.
114. Chen KM, Lai SC. Biochemical and pathological evaluation of albendazole/thalidomide co-therapy against eosinophilic meningitis or meningoencephalitis induced by *Angiostrongylus cantonensis*. *J Antimicrob Chemother* **2007**; 59: 264-76.
115. He HJ, Lv ZY, Li ZY, et al. Efficacy of combined treatment with albendazole and baicalin against eosinophilic meningitis induced by *Angiostrongylus cantonensis* in mice. *J Helminthol* **2011**; 85:92-9.
116. Lai SC, Jiang ST, Chen KM, Hsu JD, Shyu LY, Lee HH. Efficacy of albendazole-GM6001 co-therapy against *Angiostrongylus cantonensis*-induced meningitis in BALB/c mice. *Acta Trop* **2005**; 93:267-73.
117. Lai SC. Chinese herbal medicine yin-chen-extract as an adjunct to anthelmintic albendazole used against *Angiostrongylus cantonensis*-induced eosinophilic meningitis or meningoencephalitis. *Am J Trop Med Hyg* **2006**; 75:556-62.
118. Lai SC, Chen K-M, Lee HH. Albendazole-banlangen co-therapy against *Angiostrongylus cantonensis*-induced eosinophilic meningitis. *Chung Shan Med J* **2007**; 18:57-67.
119. Lai SC, Chen KM, Chang YH, Lee HH. Comparative efficacies of albendazole and the Chinese herbal medicine long-dan-xie-gan-tan, used alone or in combination, in the treatment of experimental eosinophilic meningitis induced by *Angiostrongylus cantonensis*. *Ann Trop Med Parasitol* **2008**; 102:143-50.
120. Lam HYP, Liang TR, Jiang SJ, Peng SY. Albendazole-schisandrin B co-therapy on *Angiostrongylus cantonensis*-induced meningoencephalitis in mice. *Biomolecules* **2020**; 10:1-17.
121. Li ZY, Sun R, Li J, et al. Efficacy of albendazole combined with a marine fungal extract (m2-9) against *Angiostrongylus cantonensis*-induced meningitis in mice. *J Helminthol* **2012**; 86:410-7.

122. Shyu LY, Chang HH, Hsu JD, Lin DP, Teng YH, Lee HH. Curcumin alleviates eosinophilic meningitis through reduction of eosinophil count following albendazole treatment against *Angiostrongylus cantonensis* in mice. *Parasitology* **2012**; 139:358-65.
123. Hayashi M, Terada M, Ishii AI, Kino H, Sano M. Studies on chemotherapy of parasitic helminths (XIV) anthelmintic effect of mebendazole on *Angiostrongylus cantonensis* in rats. *Japanese J Parasitol* **1982**; 31:575-80.
124. Lämmler VG, Weidner E. Zur larviziden wirkung von anthelminthika gegen *Angiostrongylus cantonensis*. *Berl Münch Tierärztl Wochen* **1975**; 88:152-6.
125. Maki J, Kanda S. Higher sensitivity of the developing larvae of *Angiostrongylus cantonensis* than the adult worms to flubendazole and mebendazole. *Kitasato Arch Exp Med* **1992**; 65:131-6.
126. Maki J, Yanagisawa T. Studies on anthelmintic effects of flubendazole and mebendazole on the rat lungworm *Angiostrongylus cantonensis* in mice and rats. *J Parasitol* **1986**; 72:512-6.
127. Chuang CC, Chen CW, Fan CK, et al. *Angiostrongylus cantonensis*: apoptosis of inflammatory cells induced by treatment with mebendazole or/and interleukin 12 in mice. *Exp Parasitol* **2007**; 115:226-32.
128. Du WY, Liao JW, Fan CK, Su KE. Combined treatment with interleukin-12 and mebendazole lessens the severity of experimental eosinophilic meningitis caused by *Angiostrongylus cantonensis* in ICR mice. *Infect Immun* **2003**; 71:3947-53.
129. Cuckler AC, Egerton JR, Alicata JE. Therapeutic effect of thiabendazole on *Angiostrongylus cantonensis* infections in rats. *J Parasitol* **1965**; 51:392-6.
130. Maki J, Yanagisawa T. A comparison of the effects of flubendazole and thiabendazole on the larvae of *Angiostrongylus cantonensis*, *Trichinella spiralis*, *Diphyllobothrium erinacei* and *Hymenolepis nana* in mice. *Parasitology* **1983**; 87:525-31.
131. Nishimura K. Experimental studies on the chemotherapy of rat lungworm, *Angiostrongylus cantonensis*, in rats. *Chemotherapy* **1965**; 10:164-75.
132. Ottolenghi A, Weatherly NF, Kocan AA, Larsh JE Jr. *Angiostrongylus cantonensis*: phospholipase in nonsensitized and sensitized rats after challenge. *Infect Immun* **1977**; 15:13-8.
133. Kanda S, Maki J. In vitro observation on egg release by *Angiostrongylus cantonensis* from rats treated with flubendazole. *Kitasato Arch Exp Med* **1992**; 65:155-8.
134. Maki J, Tongu Y, Ishii A. Studies on alterations in acid phosphatase activity, body weight and ultrastructure of adult *Angiostrongylus cantonensis* in rats treated with flubendazole at a subcurative dose. *Trop Med* **1997**; 39:95-100.
135. Maki J, Yanagisawa T. Larvicidal effect of flubendazole on *Angiostrongylus cantonensis* in mice with various worm burdens. *J Helminthol* **1985**; 59:301-2.
136. Maki J, Yanagisawa T. Effect of flubendazole on the number of first-stage larvae of *Angiostrongylus cantonensis* released in the faeces of treated rats. *J Helminthol* **1990**; 64:87-95.
137. Kamath VR, Menon S, Bhopale MK, Deshpande VR, Renapurkar DM. Experimental chemotherapy of *Angiostrongylus cantonensis* infection in mice with flubendazole, levamisole, and their combination. *Folia Parasitol (Praha)* **1987**; 34:87-92.
138. Kliks MM, Kroenke K, Hardman JM. Eosinophilic radiculomyeloencephalitis: an angiostrongyliasis outbreak in American Samoa related to ingestion of *Achatina fulica* snails. *Am J Trop Med Hyg* **1982**; 31:1114-22.
139. Chotmongkol V, Kittimongkolma S, Niwattayakul K, Intapan PM, Thavornpitak Y. Comparison of prednisolone plus albendazole with prednisolone alone for treatment of patients with eosinophilic meningitis. *Am J Trop Med Hyg* **2009**; 81:443-5.
140. Batmanian JJ, O'Neill JH. Eosinophilic meningoencephalitis with permanent neurological sequelae. *Intern Med* **2004**; 34:217-8.
141. Scemama M, Chiron C, Georges P, Dulac O. [Radiculomyeloencephalitis caused by *Angiostrongylus cantonensis* in children]. *Arch Fr Pediatr* **1988**; 45:417-9.
142. Tseng Y-T, Tsai H-C, Sy CL, et al. Clinical manifestations of eosinophilic meningitis caused by *Angiostrongylus cantonensis*: 18 years' experience in a medical center in southern Taiwan. *J Microbiol Immunol Infect* **2011**; 44:382-9.
143. Guilhon J, Mishra GS, Barnabe MR. Activite de plusieurs nematocides sur *Angiostrongylus cantonensis* aux divers stades de son evolution, dans l'organisme du rat. *Competes Rendus I Acad des Sciences* **1973**; 276:857-60.
144. Bowden DK. Eosinophilic meningitis in the New Hebrides: two outbreaks and two deaths. *Am J Trop Med Hyg* **1981**; 30:1141-3.
145. Hidelaratchi MDP, Riffys MTM, Wijesekera JC. A case of eosinophilic meningitis following monitor lizard meat consumption, exacerbated by anthelminthics. *Ceylon Med J* **2005**; 50:84-6.
146. Bisseru B, Gill SS, Lucas JK. Human infection with rat lungworm *Angiostrongylus cantonensis* (Chen 1935) in West Malaysia. *Med J Malaya* **1972**; 26:164-7.
147. Berkhout A, Procvic P, Herbert A, Anthony LT, Nourse C. Two cases of neuroangiostrongyliasis: a rare disease because rarely considered or rarely diagnosed? *J Paediatr Child Health* **2019**; 55:1463-9.
148. Liu IH, Chung YM, Chen SJ, Cho WL. Necrotizing retinitis induced by *Angiostrongylus cantonensis*. *Am J Ophthalmol* **2006**; 141:577-9.
149. Graber D, Jaffar-Bandjee MC, Attali T, et al. Langlostrongylose chez le nourrisson à la Réunion et à Mayotte. À propos de trois méningites à éosinophiles dont une radiculomyeloencéphalite fatale avec hydrocéphalie. *Arch Pediatr* **1997**; 4:424-9.
150. Wang LC, Jung SM, Chen CC, Wong HF, Wan DP, Wan YL. Pathological changes in the brains of rabbits experimentally infected with *Angiostrongylus cantonensis* after albendazole treatment: histopathological and magnetic resonance imaging studies. *J Antimicrob Chemother* **2006**; 57:294-300.
151. Morton NJ, Britton P, Palasanthiran P, et al. Severe hemorrhagic meningoencephalitis due to *Angiostrongylus cantonensis* among young children in Sydney, Australia. *Clin Infect Dis* **2013**; 57:1158-61.
152. Epelboin L, Blondé R, Chamouine A, et al. *Angiostrongylus cantonensis* infection on Mayotte Island, Indian Ocean, 2007-2012. *PLoS Negl Trop Dis* **2016**; 10:1-18.
153. McBride A, Chau TTH, Hong NTT, et al. *Angiostrongylus cantonensis* is an important cause of eosinophilic meningitis in southern Vietnam. *Clin Infect Dis* **2017**; 64:1784-7.
154. Sawanyawisuth K, Chindaprasirt J, Senthong V, et al. Clinical manifestations of eosinophilic meningitis due to infection with *Angiostrongylus cantonensis* in children. *Korean J Parasitol* **2013**; 51:735-8.
155. Martínez-Delgado JF, González-Cortiñas M, Tápanes-Cruz TR, Ruiz-Méndez A. Meningoencefalitis eosinofílica en Villa Clara (Cuba). Estudio de 17 pacientes **2000**; 31:417-21.
156. Nguyen D, Dard C, Pasquier J, et al. Manifestations cliniques de l'angiostrongylose humaine en Martinique (2000-2017). *Méd Mal Infect* **2018**; 48:S108.
157. Jacob J, Tan G, Lange I, Saeed H, Date A, Jarvi S. In vitro efficacy of anthelmintics on *Angiostrongylus cantonensis* L3 larvae. *Parasitology* **2021**; 148:240-50.
158. Sydney Children's Hospital Network. Snail and slug ingestion: practice guideline. **2018**. https://www.schn.health.nsw.gov.au/_policies/pdf/2018-163.pdf. Accessed 30 December 2020.
159. Children's Health Queensland Hospital and Health Services. Paediatric guideline: snail and slug ingestion. **2019**. <https://www.childrens.health.qld.gov.au/wp-content/uploads/PDF/ams/gdl-01219.pdf>. Accessed 30 December 2020.
160. Hilo Medical Center. Treatment protocol for rat lungworm, angiostrongyliasis. **2020**. <https://www.hilomedicalcenter.org/wp-content/uploads/2020/02/Rat-Lungworm-for-ED-Doctors-2020.pdf>. Accessed 30 December 2020.
161. Jarvi SI, Jacob J, Sugihara RT, et al. Validation of a death assay for *Angiostrongylus cantonensis* larvae (L3) using propidium iodide in a rat model (*Rattus norvegicus*). *Parasitology* **2019**; 146:1421-8.
162. Page SW. Chapter 10, Antiparasitic drugs. In: Maddison JE, Page SW, eds. *Church DBBT-SACP*. 2nd ed. Edinburgh: W.B. Saunders, **2008**:198-260.
163. Bernard S, Herzel H. Why do cells cycle with a 24 hour period? *Genome Inform* **2006**; 17:72-9.
164. Klion AD, Massougbdji A, Horton J, et al. Albendazole in human loiasis: results of a double-blind, placebo-controlled trial. *J Infect Dis* **1993**; 168:202-6.
165. McCarthy JS, Moore TA. 42—drugs for Helminths. In: McCarthy JS, Moore TA, eds. *Bennett JE, Dolin R, Douglas B, Bennett's principles and practice of infectious diseases*. 8th ed. Philadelphia: W.B. Saunders, **2015**:519-27.e3.
166. Wilson CM. 296—antiparasitic agents. In: Long SSBT-P and P of PID. 4th ed. London: Elsevier, **2012**:1518-45.e3. <https://www.sciencedirect.com/science/article/pii/B9781437727029002981>.
167. LiverTox: Clinical and Research Information on Drug-Induced Liver Injury [Internet]. Bethesda, MD: National Institute of Diabetes and Digestive and Kidney Diseases, 2012. Thiabendazole [Preprint]. [Cited 2020 Jul 20]. Available from: <https://www.ncbi.nlm.nih.gov/books/NBK548194/>
168. US Food and Drug Administration. Prescribing information Albenza. **2009**. Available at: https://www.accessdata.fda.gov/drugsatfda_docs/label/2007/020666s004lbl.pdf. Accessed 1 September 2021.
169. Punyagupta S. Eosinophilic meningoencephalitis in Thailand: summary of nine cases and observations on *Angiostrongylus cantonensis* as a causative agent and *Pila ampullacea* as a new intermediate host. *Am J Trop Med Hyg* **1965**; 14:370-4.
170. Noskin GA, McMenamin MB, Grohmann SM. Eosinophilic meningitis due to *Angiostrongylus cantonensis*. *Neurology* **1992**; 42:1423-4.
171. Tiewcharoen S, Keerasuntonpong A, Eamsobhana P, Danpukdee K, Benjarassamerote S. Eosinophilic meningitis due to *Angiostrongylus cantonensis*. *Siriraj Hosp Gaz (Interdepartmental Conference)* **2002**; 54:797-802.
172. Senanayake SN, Pryor DS, Walker J, Konecny P. First report of human angiostrongyliasis acquired in Sydney. *Med J Aust* **2003**; 179:430-1.
173. Chotmongkol V, Sawanyawisuth K, Thavornpitak Y. Corticosteroid treatment of eosinophilic meningitis. *Clin Infect Dis* **2000**; 31:660-2.
174. Chotmongkol V, Sawanyawisuth K. Clinical manifestations and outcome of patients with severe eosinophilic meningoencephalitis presumably caused by *Angiostrongylus cantonensis*. *Southeast Asian J Trop Med Public Health* **2002**; 33:231-4.
175. Feng Y, Nawa Y, Sawanyawisuth K, Lv Z, Wu ZD. Comprehensive review of ocular angiostrongyliasis with special reference to optic neuritis. *Korean J Parasitol* **2013**; 51:613-9.