



A neonatal case of an elongated soft palate

Kana Ito¹⁾²⁾, Toshihiko Nakamura¹⁾, Daisuke Hatanaka¹⁾ and Hisaya Hasegawa³⁾

^{1)Department of Neonatology, Japanese Red Cross Musashino Hospital, Tokyo, Japan, ^{2)Department of Pediatrics, National Defense Medical College Hospital, Saitama, Japan, ^{3)Department of Neonatology, Tokyo Women's Medical University, Adachi Medical Center, Tokyo, Japan}}}

(Received April 26, 2022, accepted August 10, 2022)

Abstract

The development of stridor and periodic desaturation in a 2-day-old neonate born at term lead to the suspicion of upper airway obstruction. The patient underwent flexible fiberoptic laryngo-tracheo-bronchoscopy and was diagnosed as having an elongated soft palate and secondary mild pharyngomalacia. Early intervention with high PEEP therapy using nasal CPAP led to improvement in the patient condition.

Key words : elongated soft palate, flexible fiberoptic laryngo-tracheo-bronchoscopy, neonate, periodic breathing, high PEEP therapy

Introduction

We have sometimes encountered a neonate with symptoms of upper airway obstruction such as stridor and desaturation. Although there is a wide variety of conditions that can cause upper airway obstruction, such as laryngomalacia and glossoptosis, there are no specific symptoms for each. We report a very rare case of a baby diagnosed with an elongated soft palate by flexible fiberoptic laryngo-tracheo-bronchoscopy. Early examination led to successful conservative treatment.

Case report

A male baby was born at 37 weeks and 4 days of gestation by vacuum extraction because of decreased fetal heart rate. He has no family history or perinatal complications. He was admitted to the neonatal intensive care unit due to tachypnea and grunting and was diagnosed as having transient tachypnea of the newborn. He was treated with nasal continuous positive airway pressure (n-CPAP) for 23 hours.

From 60 hours after birth, stridor and periodic desaturations occurred after crying. He was treat-

ed once by mask ventilation for a hypoxic episode where his SpO₂ level dropped to 70%. Thereafter, he experienced periodic hypoxic episodes not only after crying but also while sleeping. On day 10, we found that his periodic desaturation seemed to be related to periodic breathing as indicated on electrocardiographic monitoring (Figure 1), but on auscultation, we found it to be obstructive apnea with absence of aeration for 5-10 seconds despite thoracic motion. This was followed by tachypnea. Based on these symptoms, the baby was considered to have an upper airway obstruction such as glossoptosis, and we expected that his airway could be kept patent by use of a shoulder roll. This treatment slightly reduced the range of decline in his SpO₂ level but did not change the frequency of the desaturation events.

On day 15, he underwent flexible fiberoptic laryngo-tracheo-bronchoscopy (FFB) under sedation, which revealed that his middle pharynx was mildly stenotic, and the posterior soft palate and uvula touched against the base of tongue during inhalation (Figure 2a). As a result when he fell asleep, the pharynx was completely obstructed. The patient was subsequently diagnosed as having

Corresponding author : Kana Ito, MD E-mail : mhks.1950@gmail.com

©2022 The Fukushima Society of Medical Science. This article is licensed under a Creative Commons [Attribution-NonCommercial-ShareAlike 4.0 International] license.
<https://creativecommons.org/licenses/by-nc-sa/4.0/>

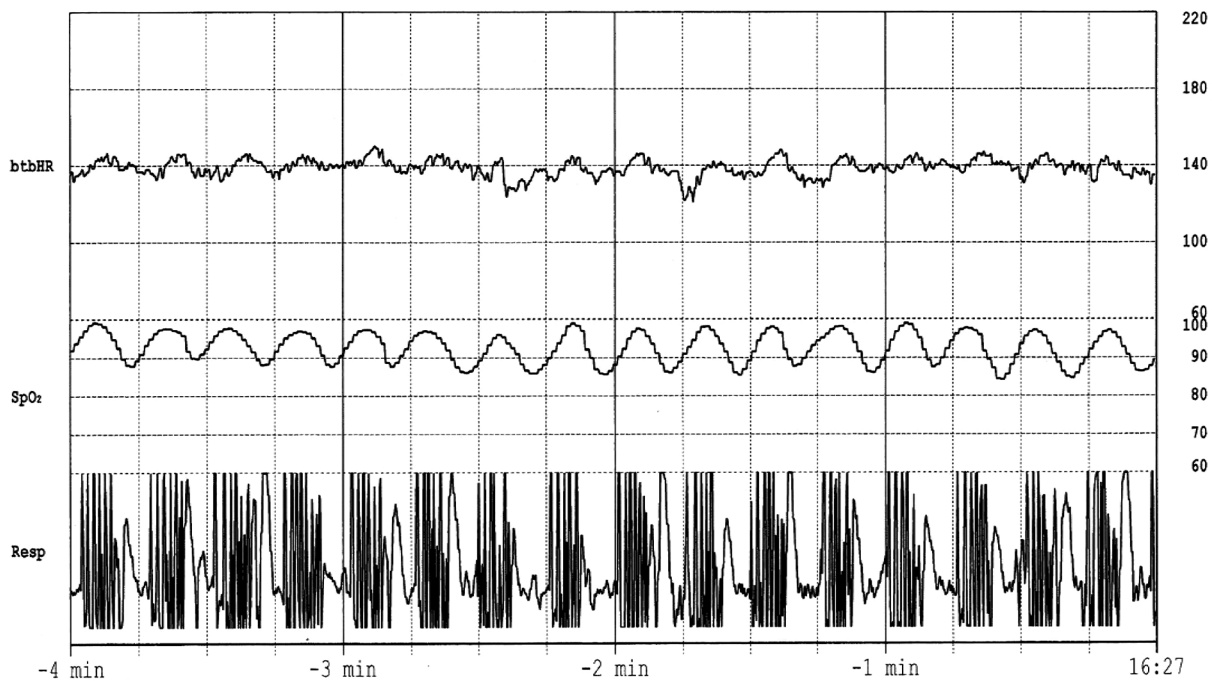


Fig. 1. Electrocardiographic monitoring appeared to indicate periodic breathing, but no aeration could be heard on auscultation.

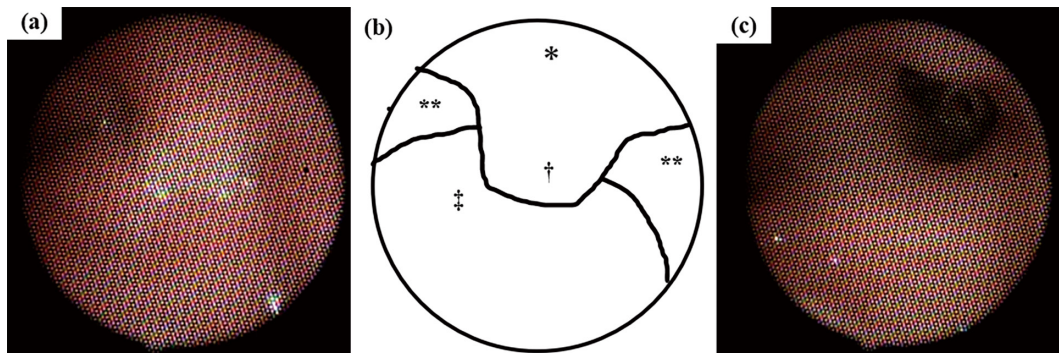


Fig. 2. Flexible fiberoptic laryngo-tracheo-bronchoscopy (FFB) image of the pharynx and a schema. (a) The first FFB revealed that the posterior soft palate and uvula was coming in contact with the base of the tongue, obscuring the posterior pharyngeal wall from view. (b) Since the image quality was insufficient, the schema is shown as an explanation of (a). *: soft palate, **: lateral pharyngeal band, †: uvula, ‡: base of tongue. (c) The second FFB following treatment revealed that the soft palate no longer touched the base of the tongue and the airway was more open than in (a). Both examinations were performed under sedation, and both images were taken during inhalation.

an elongated soft palate and secondary mild pharyngomalacia. No other abnormality was observed in the examination. A n-CPAP (Positive end-expiratory pressure; PEEP: 6 cmH₂O) was then instituted as high PEEP therapy, and this led to the gradual resolution of his symptoms.

N-CPAP was continued for about one month. On day 43, he underwent a second FFB under sedation as before, which showed no obstructive findings in the absence of pressure support (Figure 2c). He had no hypoxic episodes while free of respiratory

support for the next 2 weeks, and he was discharged on day 60.

Discussion

Elongated soft palate is a common feature of brachycephalic airway syndrome in "flat-faced" dog and cat breeds¹⁾. In animals, an elongated soft palate is defined as a closed soft palate extending beyond the tip of the epiglottis toward the airway, but no clear definition exists in humans. Upper airway

obstruction according to an elongated soft palate is presumably caused by anatomical obstruction with an abnormally long soft palate and functional obstruction due to immature pharyngeal muscles in the neonate. In addition, there have only been two cases of elongated soft palate diagnosed in neonates or infants with symptoms of upper airway obstruction²⁾. Although all such cases had chromosomal or genetic abnormalities, the present baby had no obvious malformation, and there were no other findings that would raise suspicion of genetic abnormalities. Patients with functional abnormalities of the pharynx or larynx may have feeding difficulties as well as stridor and hypoxemia³⁾, but the present baby had no feeding problems and was gaining weight well. Furthermore, including those of “elongated uvula”, most past cases were reported to have been treated surgically (e.g., with uvulopalatopharyngoplasty)^{4,5)}.

Uvulopalatopharyngoplasty is a surgical procedure to excise the uvula and soft palate and to resect a substantial amount of tissue from the lateral pharyngeal walls⁶⁾. Fortunately, our patient improved with high PEEP therapy as a conservative treatment, which is a commonly used treatment for upper airway obstructive diseases^{3,7)}.

As in this case, if there are no specific symptoms of upper airway obstruction, it can be difficult to make a definitive diagnosis based on the clinical course alone. Therefore, FFB should be performed as soon as possible so that treatment can be undertaken within the first few months of life.

Conclusion

We experienced a very rare case of a baby diagnosed with an elongated soft palate. It is important to perform FFB for the accurate assessment and identification of clinical conditions affecting the soft palate to facilitate early intervention.

Funding

None.

Consent

The authors confirm that consent for submission and publication of this case report including im-

ages and associated text has been obtained from the patient’s guardians.

In addition, approval was obtained from the hospital’s Ethics Committee.

Conflict of interest

None declared.

Acknowledgement

We are grateful to Rise Japan LLC corporation for carefully proofreading the manuscript.

Authorship

K.I. wrote the manuscript. H.H. performed laryngotracheal endoscopy. T.N. and D.H. provided conceptual advice. All authors read and approved the final manuscript.

References

1. Hara Y, Teshima K, Seki M, Asano K, Yamaya Y. Pharyngeal contraction secondary to its collapse in dogs with brachycephalic airway syndrome. *J Vet Med Sci*, **82** : 64-67, 2020.
2. Manfredi L, Marlin S, Fauroux B, Garabedian N, Couloigner V, Leboulanger N. Pycnodysostosis presenting as atypical stridor. *Eur Ann Otorhinolaryngol Head Neck Dis*, **133** : 87-90, 2016.
3. Wasa M, Hasegawa H, Yamada Y, Mizogami M, Kitamura R. Pharyngomalacia diagnosed by laryngo-tracheo-bronchoscopy in the neonatal intensive care unit. *Pediatr Int*, **63** : 1478-1482, 2021.
4. Shott SR, Cunningham MJ. Apnea and the elongated uvula. *Int J Pediatr Otorhinolaryngol*, **24** : 183-189, 1992.
5. Yoshimura G, Ikumoto H, Nishihori Y, Suga K, Uchiyama T, Matsuzaka K. A case of an elongated uvula associated with abnormal sensation during mastication and swallowing. *Jpn J Oral Maxillofac Surg*, **54** : 386-388, 2008.
6. Sheen D, Abdulateef S. Uvulopalatopharyngoplasty. *Oral Maxillofacial Surg Clin N Am*, **33** : 295-303, 2021.
7. Zwacka G, Scholle S, Kemper G, Rieger B. Nasal CPAP therapy for infants with congenital stridor. *Sleep Breath*, **2(4)** : 85-97, 1997.