



Contents lists available at ScienceDirect

## International Journal of Surgery Case Reports

journal homepage: [www.casereports.com](http://www.casereports.com)

# Diagnosis and operative management of a perforated de Garengot hernia



Alexi Bloom<sup>a</sup>, Flavio E. Baio<sup>a</sup>, Keemberly Kim<sup>c</sup>, Joseph S. Fernandez-Moure<sup>a,b,\*</sup>,  
Michael Reader<sup>a</sup>

<sup>a</sup> Houston Methodist Hospital Dept. of Surgery, 6550 Fannin Street, Houston, TX 77030, United States

<sup>b</sup> Department of Regenerative and Biomimetic Medicine, Houston Methodist Research Institute, 6670 Bertner Ave., Houston, TX 77030, United States

<sup>c</sup> Texas A&M College of Medicine, 8447 TX-47, Bryan, TX 77807, United States

## ARTICLE INFO

## Article history:

Received 23 August 2017

Received in revised form 5 October 2017

Accepted 5 October 2017

Available online 10 October 2017

## Keywords:

De Garengot's hernia

Appendicitis

Femoral hernia

Chronic lymphocytic leukemia

Strangulation

## ABSTRACT

**INTRODUCTION:** A de Garengot hernia, a femoral hernia containing the appendix, is a difficult diagnosis often made intra-operatively when the hernia sac is opened. It is a rare finding, and complications are more frequent with a de Garengot hernia.

**PRESENTATION OF CASE:** A 92 year-old female presented to the emergency department (ED) complaining of abdominal pain. A computed tomographic (CT) scan of the abdomen and pelvis demonstrated a hernia anterior to the inguinal ligament without strangulation. Two weeks later the patient returned to the ED with worsening abdominal pain in the right lower quadrant. Repeat CT scan demonstrated a 7 × 4 cm complex fluid collection in the right inguinal region, and the patient was taken to the operating room for exploration. The hernia sac was entered and found to contain the appendix with evidence of distal perforation. The appendix was taken out, and the hernia defect was repaired. The patient tolerated the procedure well.

**DISCUSSION:** Femoral hernias have a high risk of incarceration due to the tightness of the femoral canal (Talini et al. 2015 [4]). Due to anatomic location of the appendix, de Garengot hernias are most often seen on the right. Incarceration of the appendix is a clear etiology for appendicitis secondary to ischemia.

**CONCLUSION:** Full preoperative workup for a femoral hernia often fails to diagnose the presence of the appendix within the hernia. It is important to have a high clinical suspicion for a de Garengot's hernia in patients with incarcerated or strangulated right femoral hernias.

© 2017 The Authors. Published by Elsevier Ltd on behalf of IJS Publishing Group Ltd. This is an open access article under the CC BY-NC-ND license (<http://creativecommons.org/licenses/by-nc-nd/4.0/>).

## 1. Introduction

The presence of the appendix in a femoral hernia was first described by the Parisian surgeon Rene Jaques Croissant de Garengot in 1731 [1]. It is a difficult diagnosis and is often made intra-operatively when the hernia sac is opened. Finding the appendix within a femoral hernia is rare (less than 1% of surgically treated hernias), and it is even rarer to find an acutely inflamed or perforated appendicitis within the hernia sac (roughly 0.08–0.13%) [2]. Complications such as appendicular ischemia, necrosis and perforation causing peritonitis or local inflammation, abscess formation, and necrotizing fasciitis are more frequent with a de Garengot hernia. Increasing awareness of this condition will lead to prompt diagnosis, appropriate management and reduction of

possible morbidities. In this case study we present the diagnosis and management of a de Garengot hernia in a ninety-two year-old female who presented to our university hospital emergency department. This work has been reported in line with the SCARE criteria [6].

## 2. Case report

Herein, we describe and discuss our experience of a 92 year-old female with past medical history of hypertension, chronic atrial fibrillation, abdominal aortic aneurysm, left carotid aneurysm, and left atrial enlargement who presented to the emergency department (ED) complaining of generalized abdominal pain worst in the right lower quadrant. The abdominal pain had been bothering her for a month and worsening over time, limiting her activities of daily living. The patient had presented to the ED two weeks prior complaining of abdominal pain. Her physical exam at that time was not significant for any focal tenderness or bulge. A computed tomographic (CT) scan of abdomen and pelvis was performed at that time and demonstrated a hernia anterior to the inguinal ligament with

\* Corresponding author at: Houston Methodist Hospital Dept. of Surgery, 6550 Fannin Street, Houston, TX 77030, United States.

E-mail address: [joseph.fernandezmoure@uphs.upenn.edu](mailto:joseph.fernandezmoure@uphs.upenn.edu)

(J.S. Fernandez-Moure).

<sup>1</sup> Authors contributed equally to this work.

no signs of bowel or strangulation. On her following admission, the patient reported that her pain had returned and was progressively worsening overnight. Furthermore, she noticed increased bulging in the right inguinal area. She denied any nausea, vomiting, diarrhea, or constipation. On exam, patient was afebrile with rate controlled atrial fibrillation (heart rate 95). She was hypotensive with a blood pressure of 95/54 mmHg. White blood cell count was  $8000 \times 10^9$  per liter, and she was hyponatremic with sodium of 122 mEq/L. Of note, the patient also had moderate leukocyte esterase and few bacteria on admission urinalysis. Cultures eventually grew pan-susceptible *Escherichia coli*.

With concern for strangulation of her known femoral hernia, a repeat CT scan was performed, which demonstrated a  $7 \times 4$  cm complex fluid collection in the right inguinal region, small foci of air in the fluid collection, and extensive fat stranding (Fig. 1A–D). With evidence of a likely pelvic abscess in the region of her known femoral hernia, we immediately began resuscitation with normal saline, and took her to the operating room for exploration.

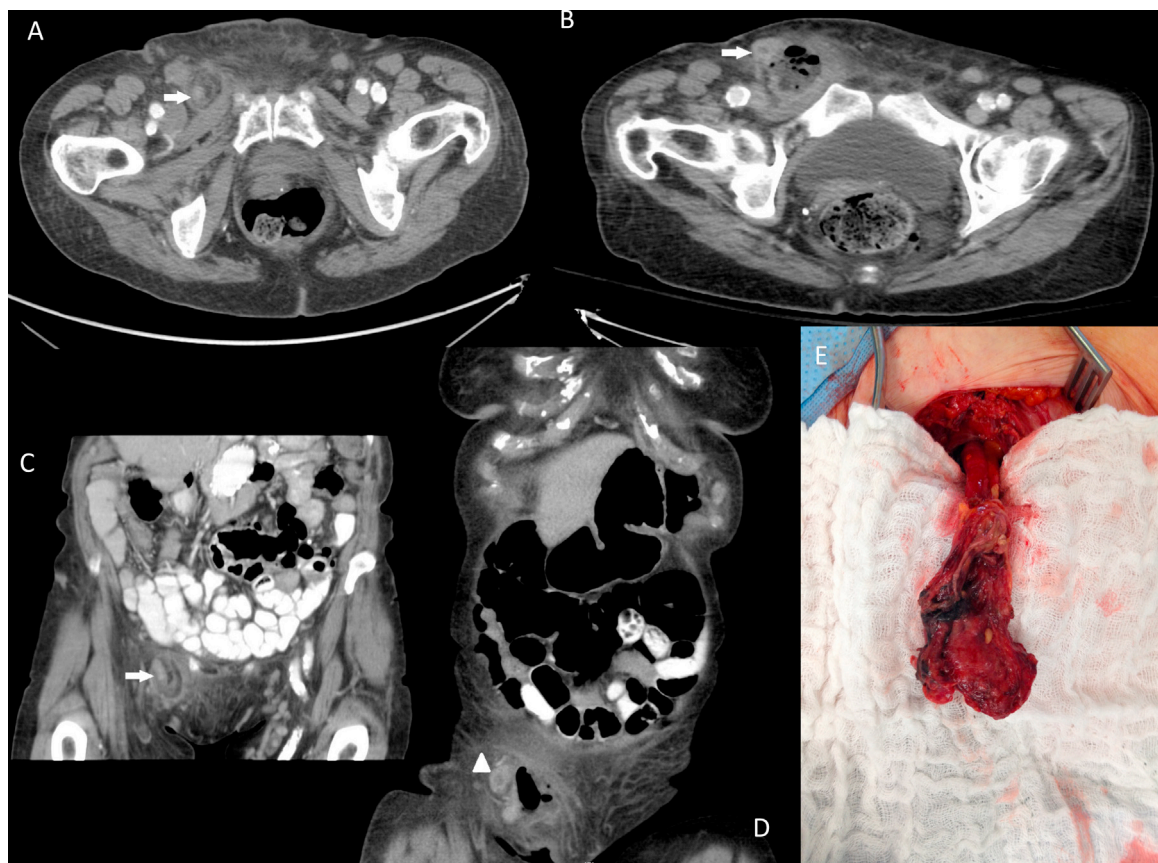
The patient was induced under general anesthesia, and Dr. Michael Reader performed the procedure in its entirety with the assistance of residents. An oblique incision was made overlying the inguinal ligament. The femoral canal was accessed through a sub-inguinal approach. The abscess cavity was incised and was found to contain a large amount of purulent, foul-smelling fluid. The hernia sac was entered and found to contain the appendix with evidence of distal perforation (Fig. 1E). The appendix was brought out through the hernia defect, ligated with an Endo-GIA stapler, and the mesoappendix was ligated using silk suture. The hernia defect was repaired by 0 Prolene interrupted sutures between Cooper's ligament and the iliopubic tract. The area was irrigated and packed with Betadine-soaked Kerlix.

Postoperatively the patient was taken to the surgical intensive care unit for high risk monitoring. She tolerated the procedure well and returned to her usual state of health within two months of the operation.

There was some concern for post-operative wound infection. She remained afebrile with a normal white count throughout the remainder of her hospitalization. Cultures of the right femoral abscess cavity grew *Bacteroides vulgatus*, *Prevotella buccae*, gram-negative rods, alpha Streptococcal species, and *Candida glabrata*. Final pathology of the appendix and hernia sac revealed soft tissue with fat necrosis and ischemic changes. Surprisingly, also noted on pathology was a small lymphocytic lymphoma involving a 1.4 cm lymph node. The patient initially received four days of vancomycin, ciprofloxacin, and metronidazole. She was then transitioned to ertapenem for her remaining five hospital days.

### 3. Discussion

First described over 150 years ago, the presentation of appendicitis within a femoral hernia is incredibly rare [3]. Fewer than one hundred cases have been reported in literature [4]. Incarceration or strangulation often tends to be the clinical presentation of a de Garengeot's hernia. [1]. Unlike the male predominant Amyand's hernia, where the appendix is within an inguinal hernia sac, de Garengeot hernias predominantly affect postmenopausal women [5]. Femoral hernias have an increased incidence in women and in general have a higher risk of incarceration due to the tightness of the femoral canal [4]. Due to the anatomic location of the appendix, de Garengeot hernias are most often seen on the right, and incarceration of the appendix is a clear etiology for appendicitis secondary to ischemia. This case is also particularly unique in that a focus



**Fig. 1.** Axial (A, B) pelvic and coronal (C, D) abdominal pelvic CT image of  $7 \times 4$  cm complex fluid collection in the right inguinal region, small foci of air in the fluid collection, and extensive fat stranding. (E) Femoral hernia sac containing the appendix with distal perforation.

of chronic lymphocytic leukemia (CLL) was discovered in the final surgical specimen.

A full preoperative workup, including a CT scan, often fails to diagnose the presence of the appendix within the hernia. A review of 36 patients with a de Garengot's hernia found that ultrasound was diagnostic in 20% and CT in 44% of cases [2]. Therefore, it is important to have a high clinical suspicion for a de Garengot's hernia in females with incarcerated or strangulated right femoral hernias. Our case showed progression of a non-incarcerated femoral hernia to one that contained an evident abscess. Although the patient failed to demonstrate any signs or symptoms of sepsis, her persistent abdominal pain and CT findings were sufficient to warrant operative exploration. The gold standard for a de Garengot's hernia is appendectomy and hernioplasty [1]. Because of prompt recognition of the problem at hand, the patient's condition did not deteriorate, which would have likely been the case had any further delay been undertaken. It is difficult to ascertain whether the incidentally found focus of CLL played a role in the pathophysiology of this patient's presentation and adds another level of complexity to the case.

#### 4. Conclusion

A full preoperative workup for a femoral hernia often fails to diagnose the presence of the appendix within the hernia. It is important to have a high clinical suspicion for de Garengot's hernia in patients with incarcerated or strangulated right femoral hernias. Treatment of a de Garengot hernia consists of emergent appendectomy and hernioplasty.

#### Conflicts of interest

None.

#### Funding

This research did not receive any specific grant from funding agencies in the public, commercial, or not-for-profit sectors.

#### Ethics approval

Not applicable.

#### Consent

Consent was obtained as a part of the institutional informed consent process. All relevant patient data has been de-identified and no face pictures are submitted.

#### Author contribution

AB, FB, KK, JSFM, and MR were equally responsible for drafting the manuscript, revising the manuscript, and creating the figures. All authors reviewed and approved the final version of the manuscript for submission.

#### Guarantor

JSFM assumes full responsibility for all aspects of the work.

#### References

- [1] T. Piperos, V. Kalles, Y. Al Ahwal, E. Konstantinou, G. Skarpas, T. Mariolis-Sapsakos, Clinical significance of de garengot's hernia: a case of acute appendicitis and review of the literature, *Int. J. Surg. Case Rep* 3 (3) (2012) 116–117.
- [2] V. Kalles, A. Mekras, D. Mekras, I. Papapanagiotou, W. Al-Harethee, G. Sotiropoulos, et al., De garengot's hernia: a comprehensive review, *Hernia* 17 (April (2)) (2013) 177–182.
- [3] J. Ramsingh, A. Ali, C. Cameron, A. Al-Ani, R. Hodnett, C. Chorushyj, De garengot's hernia: diagnosis and surgical management of a rare type of femoral hernia, *J. Surg. Case Rep.* 2014 (2) (2014).
- [4] C. Talini, L.O. Oliveira, A.C. Araújo, F.A. Netto, A.P. Westphalen, De garengot hernia: case report and review, *Int. J. Surg. Case Rep.* 8C (2015) 35–37.
- [5] K. Akbari, C. Wood, A. Hammad, S. Middleton, De Garengot's hernia: our experience of three cases and literature review, *BMJ Case Rep.* (2014) 2014.
- [6] R.A. Agha, A.J. Fowler, A. Saetta, I. Barai, S. Rajmohan, D.P. Orgill, for the SCARE Group, The SCARE statement: consensus-based surgical case report guidelines, *Int. J. Surg.* 34 (2016) 180–186.

#### Open Access

This article is published Open Access at [sciencedirect.com](https://www.sciencedirect.com). It is distributed under the [IJSCR Supplemental terms and conditions](#), which permits unrestricted non commercial use, distribution, and reproduction in any medium, provided the original authors and source are credited.