

CASE REPORT

Acute abdomen during pregnancy: appendicular decidualosis—a case report

Mossaab Ghannouchi^{1,*}, Karim Nacef¹, Mohamed Ben Khlifa¹, Kraim Iyed¹, Moez Boudokhan¹, Dhekra Toumi² and Olfa Zoukar²

¹Department of Surgery, Tahar Sfar Hospital, Mahdia, Tunisia and ²Department of Gynecology and Obstetrics, Centre de Maternité et Néonatalogie Monastir, Tunisia

*Correspondence address. Department of Surgery, Tahar Sfar Hospital, Mahdia, Tunisia. Tel: +21653881007; E-mail: mossaabgh@hotmail.com

Abstract

Despite the fact that it is rarely found in the appendix during pregnancy, ectopic decidual can, in some cases, cause the occlusion of the appendicular lumen by extrinsic compression due to the expansion of endometrial tissue or due to decidual polyp formation. This condition consequently leads to appendicular inflammation. We report the case of a 27-year-old primigravida woman, 32 weeks of gestation, who presented to our facility with a 2-day history of isolated right iliac fossa pain. The diagnosis of an acute appendicitis was suspected and a planned appendectomy was performed. Microscopical examination showed appendicular decidualosis.

INTRODUCTION

The circulating progesterone levels during pregnancy stimulate endometrial decidualization, which is an essential feature for the implantation of pregnancy. It is characterized by hypertrophy of stromal tissue, increased glandular secretion and vascular proliferation.

Rarely, can this cell transformation occur outside of the endometrium, and decidual cell groups could be found in the ovaries, uterus and cervix. A rare form of ectopic decidual can be located in the appendix and cause complication with an acute appendicitis. To date, only few cases of decidualosis resulting in acute appendicitis have been reported in the literature.

OBSERVATION

A 27-year-old primigravida woman, 32 weeks of gestation, with unremarkable medical and surgical history, presented to our facility with a 2-day history of isolated right iliac fossa pain.

No nausea, vomiting or urinary symptoms were reported and there were no similar previous episodes of pain. The body temperature was 38.4°. Abdominal palpation revealed tenderness in the right iliac fossa. The white blood cell count was 22 450/mm³ and the level of C-reactive protein (CRP) reached 67.7 mg/l. The urine analysis was normal. The abdominal ultrasonography confirmed a viable intrauterine pregnancy and did not show the appendix or any other abnormalities. Magnetic resonance imaging investigation was not available in our institution.

Given the suspicion for acute appendicitis, we decided to perform a planned appendectomy.

The intraoperative findings included inflamed appendix. No other peritoneal or pelvic pathologies were identified and a conventional appendectomy was performed.

A pelvic ultrasonography performed after surgery, showed normal fetal movements.

The patient was discharged on post-operative Day 2, and gave birth to a healthy boy 7 weeks later.

Received: September 4, 2021. Revised: September 29, 2021. Accepted: October 2, 2021

Published by Oxford University Press and JSCR Publishing Ltd. © The Author(s) 2021.

This is an Open Access article distributed under the terms of the Creative Commons Attribution License (<http://creativecommons.org/licenses/by/4.0/>), which permits unrestricted reuse, distribution, and reproduction in any medium, provided the original work is properly cited.

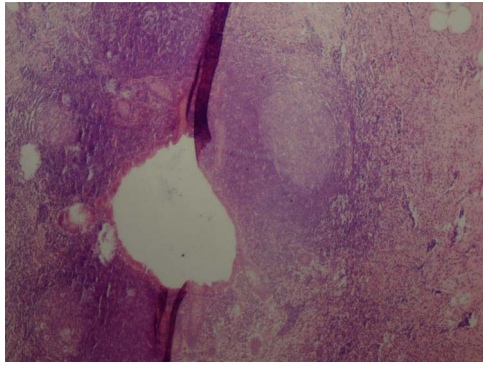


Figure 1: Constricted appendicular lumen.

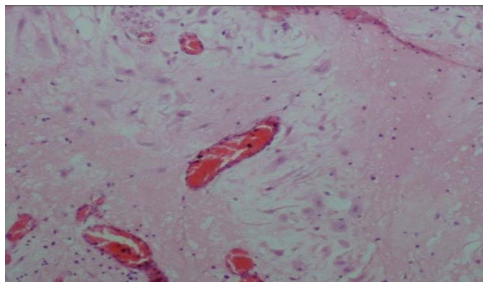


Figure 2: Decidual cells with abundant cytoplasm.

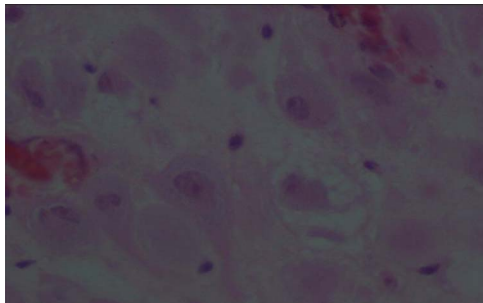


Figure 3: Large decidual cell with abundant eosinophilic cytoplasm and round nuclei with prominent nucleoli.

The pathologic examination showed an appendix of 6×1.5 cm with a constricted lumen suggesting appendiceal obstruction (Fig. 1). Microscopic examination showed subserosal decidualitis with large polygonal decidual cells, eosinophilic abundant cytoplasm and round nuclei with prominent nucleoli. A hyperplastic lymphoid reaction was found in the submucosa and mucosa (Figs 2 and 3).

DISCUSSION

The pathogenesis of ectopic decidua and precise mechanism reactions are not yet fully understood and it is controversial to decide whether it is a physiological reaction or rather a pathological process. Deciduosis may be a de novo development of decidua originated from submesothelial stroma, or a decidual transformation of a pre-existing endometriosis [1].

Commonly, ectopic decidua is a benign condition that is not responsible for any symptoms. It regresses within 4–6 weeks in the postpartum without any treatment but it may reappear in a subsequent pregnancy [1, 2].

However, in some cases it can cause abdominal pain, intraperitoneal hemorrhage, hydronephrosis or hematuria secondary to renal or pelvis involvement, it can rarely cause right iliac fossa pain or acute appendicitis [3]. In this case, appendicular transformation caused by decidualization can be explained by two theories. The first one is extrinsic compression of the appendiceal lumen by the expansion of endometrial tissue undergoing decidualization [4]. The second one, involving intraluminal decidua polyp formation [5]. The final common pathway of both mechanisms is increased pressure with a constricted appendicular lumen [6]. It can mimic acute appendicitis in pregnancy and be responsible for abdominal pain and leukocytosis.

Deciduosis of the appendix has been rarely reported in the literature. To date only few cases have been reported [1, 4, 6–8].

Regarding the differential diagnosis with malignant tumors, a morphological examination of the removed tissues is the 'gold standard'. Deciduosis is characterized by nodular architecture, composed of large cells with well-defined borders and eosinophilic cytoplasm [7]. Decidual cells are typically perivascular. They appear as large cells with an eosinophilic cytoplasm, and round nuclei with prominent nucleoli. Mitotic activity and/or nuclear atypia are absent. Immunohistochemistry staining is used when deciduosis presents pseudotumoral or infiltrative characteristics in order to exclude a peritoneal mesothelioma or a primary or metastatic peritoneal cancer [9].

Decidual cells are positive to vimentin and CD10. They also have nuclear receptors of progesterone and estrogens, but they are negative to cytokeratin and calretinin [10].

Treatment of appendicular deciduosis is surgery with standard follow up.

In conclusion, deciduosis of the appendix resulting in acute appendicitis is a rare pathology. Unlike other sites of ectopic deciduosis that can be managed expectantly, the treatment is appendectomy. Histological examination is mandatory in order to exclude a peritoneal mesothelioma or a primary or metastatic peritoneal cancer.

ACKNOWLEDGEMENTS

We thank the patient for her help in the preparation of this report.

STATEMENT OF ETHICS

The patient has given her written informed consent to publish her case (including publication of images).

CONFLICT OF INTEREST STATEMENT

The authors have no conflicts of interest to declare.

REFERENCES

1. Bolat F, Canpolat T, Tarim E. Pregnancy-related peritoneal ectopic decidua (deciduosis): morphological and clinical evaluation. *Türk Patoloji Derg* 2012;28: 56–60.
2. Erzurumluoğlu N, Sargan A, Özekinci S, Yıldız FR. Florid diffuse peritoneal deciduosis mimicking peritoneal carcinomatosis: a case report. *Haseki Tıp Bülteni* 2016;54:120–3.

3. Chai D, Wijesuriya R. Deciduosis of the appendix: diagnostic dilemma continues despite MRI evidence. *Ann R Coll Surg Engl* 2016;**98**:e200–e202.
4. Faucheron JL, Pasquier D, Voirin D. Endometriosis of the vermiform appendix as an exceptional cause of acute perforated appendicitis during pregnancy. *Colorectal Dis* 2008;**10**: 518–9.
5. Silvestrini IE, Marcial MA. Endometriosis of the appendix with decidual polyp formation: a rare cause of acute appendicitis during pregnancy. *P R Health Sci J* 1995;**14**: 223–5.
6. Murphy SJ, Kaur A, Wulschleger ME. Endometrial decidualization: a rare cause of acute appendicitis during pregnancy. *J Surg Case Rep* 2016;**2016**:rjw053.
7. Balta AL, Lubgane M, Orube I, Ziemele G, Vanags A, Gardovskis J, et al. Deciduosis of the appendix manifesting as acute abdomen in pregnancy. *Acta Chirurgica Latviensis* 2014;**14**:43–5.
8. Lebastchi AH, Prieto PA, Chen C, Lui FY. Appendiceal endometriosis in a pregnant woman presenting with acute perforated appendicitis. *J Surg Case Rep* 2013;**2013**:rjt104.
9. Markou GA, Goubin-Versini I, Carbunaru OM, Karatzios C, Muray JM, Fysekidis M. Macroscopic decidualosis in pregnancy is finally a common entity. *Eur J Obstet Gynecol Reprod Biol* 2016;**197**:54–8.
10. Adhikari LJ, Shen R. Florid diffuse peritoneal decidualosis mimicking carcinomatosis in a primigravida patient: a case report and review of the literature. *Int J Clin Exp Pathol* 2013;**6**:2615–9.