

A case report of limbic encephalitis in a metastatic colon cancer patient during first-line bevacizumab-combined chemotherapy

Laura Attademo, MD^a, Stefano De Falco, MD^a, Mario Rosanova, MD^a, Marcello Esposito, MD, PhD^b, Federica Mazio, MD^c, Francesca Foschini, MD^a, Antonio Santaniello, MD^a, Giovanni Fiore, MD^a, Elide Matano, MD^a, Fiore Manganeli, MD, PhD^b, Chiara Carlomagno, MD, PhD^{a,*}

Abstract

Rationale: Paraneoplastic limbic encephalitis (PLE) is one of the most common causes of neurologic paraneoplastic syndromes, with unclear pathogenesis. While several reports published in the last decades showed the occurrence of PLE in a variety of cancers, only a few cases have been associated with colon cancer.

Patient concerns: In February 2017, a 54-year-old man with clinical history of radically resected colon cancer started first line chemotherapy with FOLFOXIRI plus bevacizumab, after radiological diagnosis of multiple liver and bone metastases. During the third cycle of treatment, the patient developed psychomotor agitation and hallucinations followed by severe consciousness level reduction and cognitive impairment.

Diagnoses: Magnetic resonance imaging showed hyperintense signals in both hippocampal areas, insula and right cingulate gyrus on fluid attenuated inversion recovery, diffusion weighted imaging, and T2-weighted images, highly suggestive of limbic encephalitis. Other causes (brain metastases, toxicity of chemotherapeutic agents, and infections) were excluded.

Interventions: Empirical immunosuppressive treatment (high-dose immunoglobulins and corticosteroids) was administered and chemotherapy was resumed.

Outcomes: A slowly progressive improvement in neurological condition has been observed, even though radiological signs of limbic encephalitis are still evident.

Lessons: The present case highlights the complex diagnostic process of PLE, and the lack of a standard treatment. Moreover, the absence of correlation between PLE and tumor progression or tumor burden, and the opportunity of treating underlying neoplasm is discussed.

Abbreviations: CSF = cerebrospinal fluid, CT = computed tomography, DWI = diffusion weighted imaging, EEG = electroencephalography, FLAIR = fluid attenuated inversion recovery, MRI = magnetic resonance imaging, PLE = paraneoplastic limbic encephalitis, PNS = paraneoplastic neurological syndrome, PRES = posterior reversible encephalopathy syndrome.

Keywords: autoimmunity, colorectal cancer, limbic encephalitis, paraneoplastic syndromes

1. Introduction

Limbic encephalitis is one of the most common causes of neurologic paraneoplastic syndromes.^[1] Pathogenesis of paraneoplastic limbic encephalitis (PLE) is still unclear, but it seems to be related to an autoimmune process in which autoantibodies against neuronal and glial antigens produce a significant and progressive

impairment of the central nervous system.^[2] Typical symptoms of PLE are seizures, severe memory impairment, subacute cognitive dysfunction, anxiety, hallucinations, and depression. Frequently, PLE is associated with hypothalamic dysfunctions causing hyperthermia and somnolence. In 60% to 70% of cases, these symptoms precede diagnosis of malignancy; diagnosis of PLE generally follows the exclusion of other causes, such as infections, brain metastases, or metabolic disorders. Among PLE patients, about 50% have small-cell lung cancer, 20% testicular tumors, and 8% breast cancer; less frequently associated neoplasms are Hodgkin's lymphoma, thymoma, or teratomas.^[3] While several reports published in the last decades showed the occurrence of PLE in a variety of cancers, only a few cases have been associated with colon cancer. Herein, we report the case of a male patient with diagnosis of metastatic adenocarcinoma of the colon who presented sleep disturbance, hallucinations, and altered mental status during first-line chemotherapy plus bevacizumab. Electroencephalography (EEG) and central nervous system magnetic resonance imaging (MRI) confirmed the diagnosis of limbic encephalitis.

2. Case presentation

In July 2013, a 51-year-old man with clinical history of arterial hypertension and hemorrhagic stroke without permanent

Editor: N/A.

The authors report no conflicts of interest.

^a Department of Clinical Medicine and Surgery, ^b Department of Neurosciences, Reproductive Sciences and Odontostomatology, ^c Department of Advanced Biomedical Sciences, University Federico II, Naples, Italy.

* Correspondence: Chiara Carlomagno, Department of Clinical Medicine and Surgery, University Federico II, Via Sergio Pansini, 5, 80131, Naples, Italy (e-mail: chiara.carlomagno@unina.it).

Copyright © 2018 the Author(s). Published by Wolters Kluwer Health, Inc. This is an open access article distributed under the terms of the Creative Commons Attribution-Non Commercial-No Derivatives License 4.0 (CCBY-NC-ND), where it is permissible to download and share the work provided it is properly cited. The work cannot be changed in any way or used commercially without permission from the journal.

Medicine (2018) 97:9(e0011)

Received: 7 December 2017 / Received in final form: 2 February 2018 /

Accepted: 5 February 2018

<http://dx.doi.org/10.1097/MD.00000000000010011>

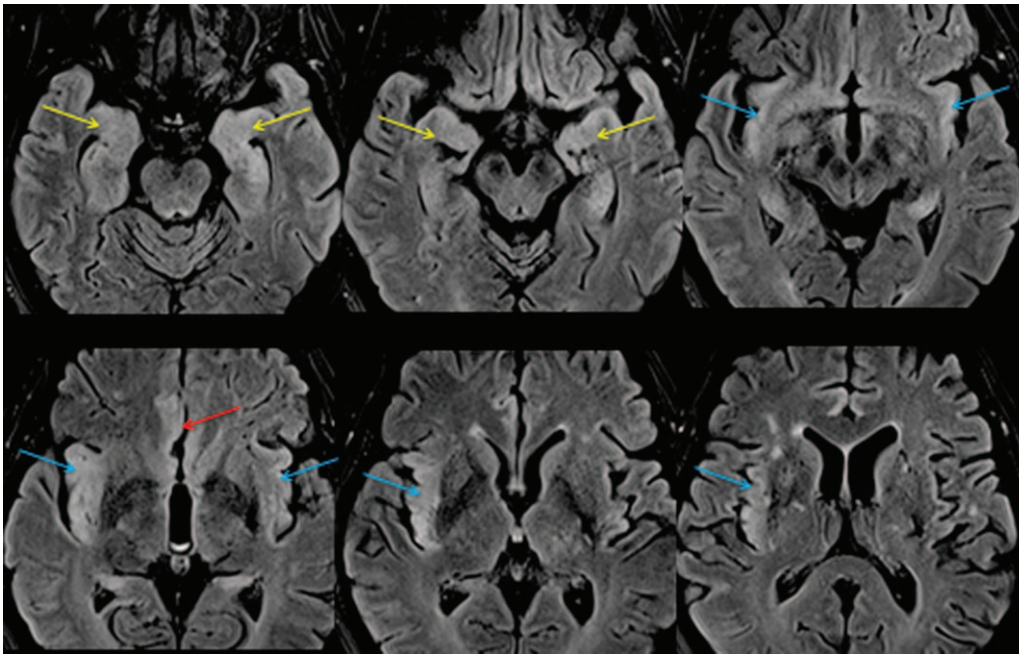


Figure 1. Mesial temporal lobes (yellow arrows), cingulate gyrus (red arrows), and insulae (blues arrows) involvement with asymmetric (right > left) cortical thickening and FLAIR hyperintensity.

sequelae received diagnosis of sigmoid cancer that was treated with radical surgery. Histology was: moderately differentiated (G2) adenocarcinoma infiltrating perivisceral fat tissue (pT3) with no metastatic lymph node among the 26 examined (pN0); mutation in exon 2 of KRAS gene (p.Gly12Cys) was detected. Radiological staging by full-body contrast enhanced computed tomography (CT) scan showed no distant metastases, and the patient started clinical and radiological follow-up. In January 2017, a contrast enhanced CT-scan showed multiple liver and bone metastases with a pathological fracture of the second lumbar vertebra, thus he was referred to the Division of Medical Oncology of the University Federico II of Naples (Italy). In February 2017, the patient underwent palliative radiotherapy for L2 spinal fracture and started treatment with Denosumab (plus calcium and vitamin D). On February 23, 2017 he started first-line chemotherapy with FOLFOXIRI (Leucovorin 200mg/m², 5Fluorouracil 3200mg/m² 46 hours continuing infusion, Oxaliplatin 85 mg/m², Irinotecan 165 mg/m²) plus Bevacizumab (5 mg/kg) i.v. day 1, every 14 days.

On April 3, 2017 (day 12 of the third cycle of treatment), the patient acutely developed neurological symptoms (psychomotor agitation and hallucinations), followed, 24 hours later, by severe consciousness level reduction and cognitive dysfunction with impaired orientation in space and time, loss of memory, speaking difficulties, along with bradykinesia, and lethargy. Patient was admitted to Medical Oncology division on April 4. On admission, the patient was barely responsive to verbal stimuli, blood pressure was 120/90 mmHg, pulse rate 92 bpm, temperature 37.6°C; complete blood count, and blood chemistry tests showed no major alteration. On April 6, the patient underwent contrast enhanced whole-brain MRI that showed hyperintense signals in both hippocampal areas, insulae and right cingulate gyrus on fluid attenuated inversion recovery (FLAIR) (Fig. 1), diffusion weighted imaging (DWI) (Fig. 2), and T2-weighted images: these radiological signs were highly suggestive of limbic encephalitis; signs of previous multifocal hemorrhagic stroke in left nucleo-capsular, left talamic and cerebellar regions, focal pontine brain ischemia, and chronic cerebral hypoperfusion

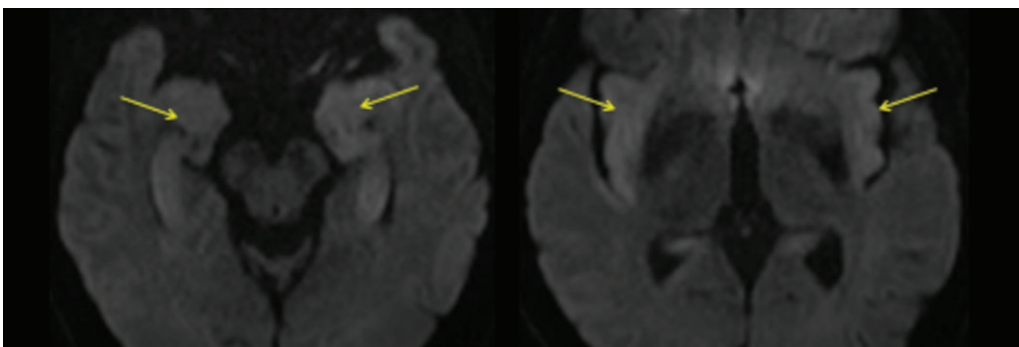


Figure 2. Increased DWI signal (B 1000) of mesial temporal lobes and insulae (yellow arrows).

were also detected. Cerebrospinal fluid (CSF) study was negative for bacterial/viral infections, with no significant biochemical alterations or cytological abnormalities. CSF and peripheral blood were also tested for onconeural antibodies (against Hu, Yo, Ri, amphiphysin, Ma2, and CV2) and no antibody was detected. EEG showed slowed background activity, and focal slow waves in right and left temporal lobes. Waiting for immunological analyses results, the patient received intravenous immunoglobulin (400 mg/kg/d for 5 days), with no benefit, and thereafter, high dose steroids (methylprednisolone 1 gr/d i.v. for 5 days), followed by maintenance with oral prednisone (25 mg/d). Further 2 contrast enhanced whole-brain MRIs performed 15 and 30 days after neurological symptoms onset showed persistent and stable signs of limbic encephalitis. A full-body contrast enhanced CT-scan performed on April 19, showed a partial remission of the neoplastic disease (reduction of the maximum diameter and necrosis of the liver metastases with no new lesion).

Despite immunosuppressive treatment, no substantial change in the neurological picture occurred during the first month after the diagnosis of limbic encephalitis, and only a mild cognitive improvement was observed. Four weeks after admission, the patient was discharged and referred to home health-care professionals.

After 3 months from limbic encephalitis onset, a slight further cognitive improvement was observed and patient could also perform some simple activities of daily living.

In June 2017, oncologic re-staging with full-body contrast enhanced CT-scan showed disease progression (new lung nodules and abdominal lymph-nodes, increased diameter of liver metastases), thus, the patient started second-line chemotherapy with FOLFOX (Leucovorin 200 mg/m², 5-Fluorouracil 400 mg/m² bolus, 5-Fluorouracil 2400 mg/m² 46 hours continuing infusion, Oxaliplatin 85 mg/m²) plus Bevacizumab (5 mg/kg) i.v. day 1, every 14 days.

After 6 cycles of chemotherapy, a stable disease has been achieved, and a slowly progressive improvement in neurological condition has been observed, even though radiological signs of limbic encephalitis are still evident.

At present, the patient partly recovered orientation in space and time, and improved speaking, although he still presents excessive drowsiness and general cognitive impairment.

The patient signed the consent to the treatment of personal data, according to the Italian privacy law.

3. Discussion

Paraneoplastic neurological syndromes (PNSs) are a group of rare disorders of unknown cause associated with cancer. Currently, it is thought that most or all paraneoplastic neurologic disorders are immune-mediated. The leading theory is that tumor begins to express antigens that are usually present on normal nervous system cells and for this reasons called "onconeural" antigens. The immune system identifies them as foreign and mounts an immune attack. However, the antibodies cross-react with antigens on the normal cells, causing death of neuronal or glial cells.^[2]

Limbic encephalitis is one of the most common PNSs and is characterized by the development of neuropsychiatric symptoms: personality changes, irritability, depression, seizures, memory loss, and sometimes dementia. However, recognizing the PLE is often difficult for the clinicians, due to differential diagnosis with brain metastases, toxicity of treatments, and other metabolic complications.

Four criteria are required for diagnosis of PLE: diagnosis of cancer within 4 years; signs and symptoms of limbic impairment;

exclusion of other causes of subacute encephalopathy; and EEG abnormalities (slow or sharp-wave temporal lobe activity) and/or characteristic MRI studies (increased signal activity on T2 or FLAIR-weighted sequences in the temporal lobes corresponding to inflammatory infiltrate) and/or CSF analysis (lymphocytic pleocytosis, increased protein concentration and the presence of oligoclonal bands by isoelectric focusing).^[3]

Onconeural antibodies are found in about 60% of PNSs, the most frequent being: anti-Hu, anti Yo, and anti-Ri. Positivity of onconeural antibodies in the serum or in the cerebrospinal fluid facilitates the diagnosis of PLE, but their absence does not exclude it.^[1]

In our patient, the diagnosis of LE was confirmed by MRI and EEG, even though no antibody was identified in serum or cerebrospinal fluid.

A few cases of PLE onset in patients with colorectal cancer have been reported in the literature.

Sio et al^[4] describe the story of a 53-year-old man who simultaneously developed a sensory neuropathy and a limbic encephalitis. The diagnosis of metastatic colon cancer was done during the diagnostic work-up for the neurologic symptoms. In this patient EEG was normal and, like as in our case, no autoantibodies in serum and cerebrospinal fluid were identified.

Similarly, Janati et al^[5] reported the case of a 77-year-old man who received diagnosis of limbic encephalitis before the identification of colonic adenocarcinoma. The patient was not suitable for radical surgery, and a diverting colostomy was performed to release abdominal pain and vomiting. After surgery, the patient's mood, behavior, and appetite improved markedly, but cognitive dysfunction remained essentially unchanged.

In the case reported by Adam et al,^[6] a 61-year-old woman presented fever, confusion, and abdominal pain with signs of peritonitis. A subtotal colectomy was performed with diagnosis of sigmoid colon adenocarcinoma. After surgery the patient remained febrile, somnolent, with left-sided facial paresis, ipsilateral hemiplegia, and partial motor seizures. MRI, EEG, CSF analysis were suggestive of limbic encephalitis; serum Yo antibodies were detected. The patient was treated with anti-epileptic drugs, but she remained ventilator-dependent in a permanent vegetative status. In our case, a slight, and progressive improvement of the neurological status was observed, not related to treatment with immunoglobulins or steroids or chemotherapy.

In 1997, Riva et al^[7] published a case series including a 67 years old man with diagnosis of limbic encephalitis and simultaneous radiologic identification of liver metastasis from a primary colon cancer radically resected 2 years before; anti-Hu antibodies in serum, diffuse slow activity at EEG, and T2 hyperintensity in anterior and middle third of left hippocampus at MRI were detected.

Finally, Tsukamoto et al^[8] reported the possible association between 2 PNSs (limbic encephalitis and a paraneoplastic cerebellar degeneration) arisen in a patient with symptoms of severe disequilibrium, memory loss, and weight loss. During the diagnostic work-up, the patient had received the diagnosis of an "in situ" adenocarcinoma in a colonic polyp. In this case the diagnosis was supported by EEG pattern, MRI abnormalities of temporal lobe, and immunohistochemical positivity for an antineuronal nuclear antibody in the patient's serum.

In all the reported cases,^[4-6] the neurological symptoms preceded the diagnosis of tumor, and in one of them they coincided with tumor progression;^[7] differently, our patient developed the PLE 4 years after the radical resection of the primary colon cancer and 2 months after the diagnosis of

metastases from colon neoplasm, while receiving a very active first-line chemotherapy by which a partial reduction of the tumor burden was obtained.

The treatment of PNS or PLE is not established. Giometto et al^[1] suggest that once a tumor/metastasis has been diagnosed in a patient presenting with PNS, it is of utmost importance to treat the tumor with chemotherapy, surgery, and/or radiation therapy, while it remains unclear whether immunosuppression (immunoglobulins or steroids) is effective against PNSs. It's important to remark that our patient was receiving chemotherapy for metastatic colorectal cancer when he developed neurological symptoms, and no radiological progression of the oncologic disease was observed at that time. Moreover, empiric treatment with high-dose immunoglobulins and corticosteroids was administered, with a slight and slow improvement of the symptoms.

In our patient, besides differential diagnosis with brain metastasis, infective meningoencephalitis, and metabolic disorder, also toxicity from chemotherapy or bevacizumab was considered. Irinotecan administration has been correlated with dysarthria,^[9] but not with other neurological symptoms, thus, it was excluded as causative factor in our case.

Bevacizumab can cause a neurological syndrome, known as PRES (posterior reversible encephalopathy syndrome) in less than 1% of patients. PRES is an acute encephalopathy presenting with headache, vomiting, visual disturbances, seizures, and typical MRI findings (hyperintense signals on T2-weighted images and FLAIR in the parieto-occipital lobes, in the posterior frontal cortical and subcortical white matter).^[10] In our patient, symptoms and neurological findings significantly differ from this scenario.

4. Conclusion

The present case primarily highlights the importance of diagnosing a PLE by radiology (pathognomonic signs) and

immunology (onconeural antibodies not always present), and of excluding other causes of limbic dysfunction. Furthermore, it points out that PLE lacks of a standard treatment and its onset doesn't necessarily correlate with tumor progression or with huge tumor burden. Finally, it remarks that the outcome of PLE can largely vary, thus the treatment of the underlying neoplasm has not to be withdrawn if the patient is clinically suitable to receive it, and able to give an informed consent to the therapy.

References

- [1] Giometto B, Grisold W, Vitaliani R, et al. For the PNS Euronetwork. Paraneoplastic neurologic syndrome in the PNS Euronetwork database: a European study from 20 centers. *Arch Neurol* 2010;67:330–5.
- [2] Darnell RB, Posner JB. Paraneoplastic syndromes involving the nervous system. *N Engl J Med* 2003;349:1543–54.
- [3] Gultekin SH, Rosenfeld MR, Voltz R, et al. Paraneoplastic limbic encephalitis: neurological symptoms, immunological findings and tumour association in 50 patients. *Brain* 2000;123(Pt 7):1481–94.
- [4] Sio TT, Paredes M, Uzair C. Neurological manifestation of colonic adenocarcinoma. *Rare Tumors* 2012;4:e32.
- [5] Janati A, Gray RP, Souheaver GT. A mental syndrome associated with colonic carcinoma: limbic encephalitis? *Psychosomatics* 1987;28:48–50.
- [6] Adam VN, Budinčević H, Mršić V, et al. Paraneoplastic limbic encephalitis in a patient with adenocarcinoma of the colon: a case report. *A J Clin Anesth* 2013;25:491–5.
- [7] Riva M, Brioschi AM, Marazzi R, et al. Immunological and endocrinological abnormalities in paraneoplastic disorders with involvement of the autonomic nervous system. *Ital J Neurol Sci* 1997;18:157–61.
- [8] Tsukamoto T, Mochizuki R, Mochizuki H, et al. Paraneoplastic cerebellar degeneration and limbic encephalitis in a patient with adenocarcinoma of the colon. *J Neurol Neurosurg Psychiatry* 1993;56:713–6.
- [9] De Marco S, Squilloni E, Vigna L, et al. Irinotecan chemotherapy associated with transient dysarthria and aphasia. *Ann Oncol* 2004;15:1147–8.
- [10] Gluske P, Ozcan C. Reversible posterior leukoencephalopathy syndrome and bevacizumab. *N Engl J Med* 2006;354:980–2.