

Trauma and reconstruction

Pneumoscotum: A rare complication of ruptured emphysema bullae

Issam Jandou^{a,b,*}, Dr Amine Moataz^{a,b}, Adnan ettanji^{a,b}, Dakir Mohammed^{a,b},
Adil Debbagh^{a,b}, Rachid Aboutaieb^{a,b}

^a University Hospital Center Ibn Rochd, Casablanca, Morocco

^b Faculty of Medicine of Casablanca, Morocco



ARTICLE INFO

Keywords:

Pneumoscotum
Subcutaneous emphysema
Necrotizing fasciitis
Pneumothorax drainage

ABSTRACT

Subcutaneous emphysema and pneumoscotum due to spontaneous pneumothorax is a rare clinical situation. We present the case of an 82 year old man who was admitted to the emergency department in state of respiratory distress and scrotum increased in size, painful and rapidly progressive installation. Clinical evaluation revealed scrotal emphysema associated with diffuse subcutaneous emphysema in the trunk, the face and both upper limbs. The treatment of this pathology is not yet standardized; antibiotic therapy and close monitoring are recommended.

Background

Pneumoscotum is an unusual case and a very scarce complication. The variety of possible etiologies for this condition includes air accumulation from intra-abdominal, retroperitoneal, or subcutaneous routes. Frequently following thoracic or abdominal procedures and rarely infection with gas-producing organisms or spontaneously in the context of emphysematous lung pathology.^{1,2}

The expanded study may reveal several etiologies which requires the need to exclude them before making the pneumoscotal diagnosis. In-depth investigation at the source is essential to eliminate life-threatening situations.³

Currently, the treatment of this pathology is not yet standardized; antibiotic therapy and close monitoring are recommended.

Case presentation

An 82-year-old man with chronic smoking who was followed for pulmonary emphysema. He presented to the emergency department with the complaint of scrotal swelling during the last 4 hours. Without any notion of trauma or previous infectious context.

The patient was conscious, hemodynamically stable, with a polypnea. His scrotum was very bilaterally inflated, non-erythematous, well transilluminated (Figs. 1 and 2). With the presence of generalized subcutaneous emphysema extended over the anterior thigh, abdominal

and thoracic anterior wall, both upper limbs with an extension towards the neck and the face (Fig. 2).

The abdominal and chest x-ray showed an emphysematous left lung with pneumothorax of the same side of 57%. CT chest to objectify a big ball of emphysema and pneumothorax of great abundance (Fig. 3).

The patient is referred to an intensive care unit for specialized care in which he has benefited from chest drainage and preventive antibiotic therapy.

However, the patient died of suffocating pneumothorax 5 h after hospitalization.

Discussion and conclusion

The pathways that enable air to arrive in the scrotum are diverse. The abdominal wall allows air to infiltrate the thoracic wall along with the subcutaneous fascial layer of Camper's fascia and a deep membranous layer of Scarpa fascia.

The air arrives inside the scrotum via three main routes⁴:

- (A) Intra-abdominal path: through the tunic of the vaginal
- (B) Retroperitoneal path: through the inguinal canal, and along the spermatic cord.
- (C) Subcutaneous path: direct extension of all the subcutaneous anti-space of the trunk and perineum.

Abbreviations: CT, computerized tomography.

* Corresponding author. University Hospital Center Ibn Rochd, Casablanca, Morocco.

E-mail addresses: jissam.iatros@gmail.com, jissam.iatros@gmail.com (I. Jandou).

<https://doi.org/10.1016/j.eucr.2020.101476>

Received 21 October 2020; Accepted 30 October 2020

Available online 30 October 2020

2214-4420/© 2020 Published by Elsevier Inc. This is an open access article under the CC BY-NC-ND license (<http://creativecommons.org/licenses/by-nc-nd/4.0/>).

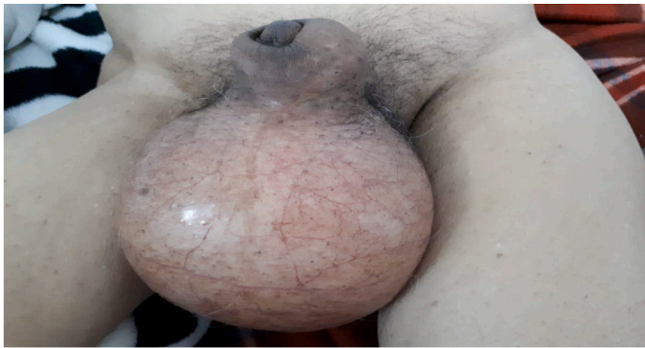

Fig. 1. Swollen scrotum noted.

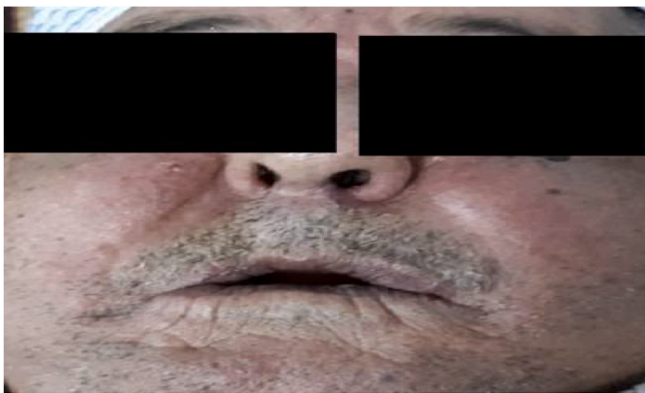

Fig. 2. Swelling of neck and face.

Etiology of primary pneumoscotum is multi-varied whose Scrotal and testicular abscess, Necrotizing fasciitis, epididymo-orchitis, Infarction, Autoerotic air injection...

Etiology of secondary pneumoscotum have several causes that can be classified according to their origins:

- Thoracic origin: pneumomediastinum, pneumothorax post-trauma or spontaneous blunt trauma, tracheal intubation pulmonary resection pneumothorax drainage.

- Retroperitoneal: retroperitoneum trauma, renal surgery, emphysematous pyelonephritis.
- Intra-abdominal/intraperitoneal: visceral perforation, abdominal trauma, colonoscopy, laparoscopy, liver or kidney biopsy.⁵

The diagnosis is often easy; palpation of a scrotal air sac confirms the diagnosis, transillumination is generally positive. Tomography (CT), and X-ray can detect the presence of air in the scrotum, and detailed and thorough questioning ensures in the majority of cases the etiological diagnosis.

The treatment of pneumoscotum in general that of its causal pathology. Although Broad-spectrum antibiotic therapy is not warranted in every case, outside of the infectious organisms is highly suspected or proven. In the case of pneumoscotum after intestinal perforation and a retroperitoneal abscess may be infected, and antibiotics are recommended in such cases, but the subcutaneous emphysematous pneumoscotum usually does not become infected and follow-up, without special antibiotic treatment or drainage, is sufficient.^{1,4}

The therapeutic aspiration has never shown a benefit in the management. On the other hand, it increases the risk of infection.

Spontaneous resolution has been reported in studies, and complete clearance of the pneumoscotum would generally occur within three to five days after treatment of the causal pathology.⁵

Pneumoscotum is a rare clinical case, although it is not an urgent situation that is important to identify the primary and secondary etiologies. The management should be supportive of an intervention directed at causal etiology.

Ethical approval and consent to participate

Not available.

Consent to publication

The consent to publish this information was obtained from study participants. We confirm that written proof of consent to publish study participants are available when requested and at any time.

Availability of data and material

The datasets in this article are available in the repository of the urology database, Chu Ibn-Rochd Casablanca, upon request, from the corresponding author.

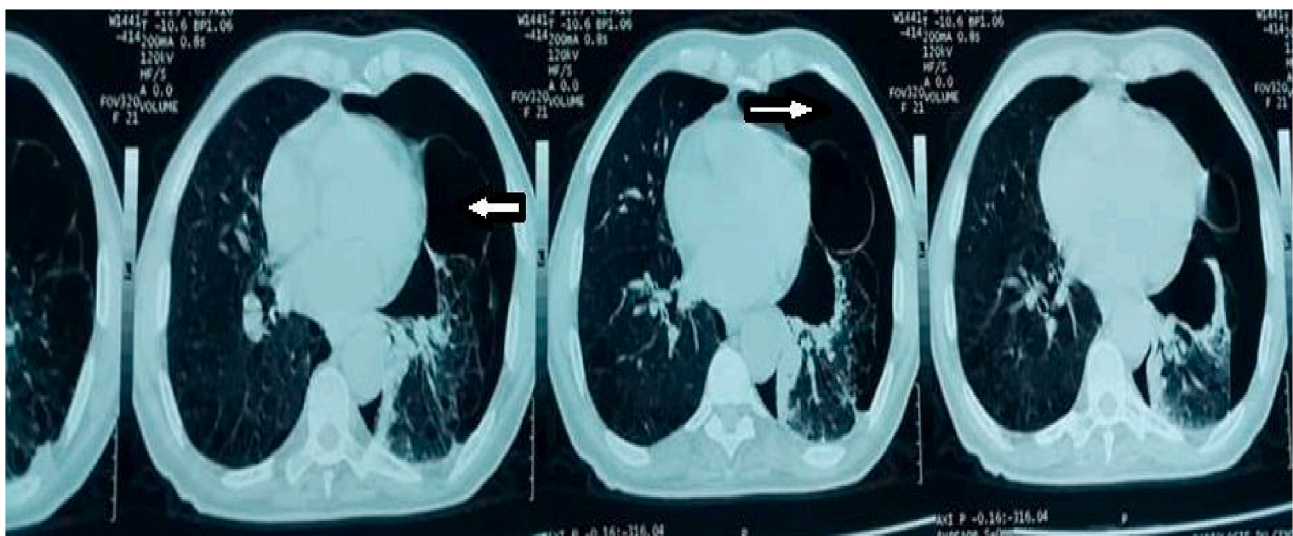


Fig. 3. CT demonstrates left pneumo-haemothorax with a ball of emphysema.

Funding

Not applicable.

Author's contributions

Dr. IJ, Dr. MG, Dr. YC, Dr. YL and Dr. AM analysed and performed the literature research, Pr. MD, Pr. AD, Pr. RA performed the examination and performed the scientific validation of the manuscript. Issam Jandou was the major contributors to the writing of the manuscript. All authors read and approved the manuscript.

Declaration of competing interest

The authors state that they do not have competing interests.

Acknowledgments

We thank Dr. Jihane El Habnouny for this contribution in writing and

editing the article.

References

1. Momeni Mehdi, Jahanshir Amirhosein, Karimialavijeh Ehsan. "Pneumomediastinum, pneumoperitoneum and pneumoscrotum following perforation of the pyriform sinus". Department of emergency medicine, Dr. Shariati hospital, Tehran University of medical sciences, Tehran, Iran. *Vis. J. Emer. Med.* 2019;15. <https://doi.org/10.1016/j.visj.2019.100558>.
2. ERCP-related duodenal perforation presenting as pneumoscrotum mohammad Saud Khana Faisal Jamalb Zubair Khana Abhinav Tiwaria Hermann Simoa Himani Sharmaa department of internal medicine, University of Toledo medical center, Toledo, OH, USA. *Case Rep. Gastroenterol.* 2018;12:1–6. <https://doi.org/10.1159/000485557>.
3. Willburger Johanna, Suter Basil, Wimmer Matthias, Kirchoff Philipp. Pneumoscrotum after colorectal surgery: a case report". *Clin. Case Rep.* 2018;6: 1485–1487. <https://doi.org/10.1002/ccr3.1594>.
4. Lostoridis E, Gkagkalidis K, Varsamis N, et al. Pneumoscrotum as complication of blunt thoracic trauma: a case report. *Case Rep. Surg.* 2013;2013:392869.
5. Dagur Gautam, Min Leea, Warrena Reese Imhofa, Khan Sardar. Critical manifestations of Pneumoscrotum. Department of physiology and biophysics; and bDepartment of urology, SUNY at stony brook, New York, N.Y., USA. *Curr. Urol.* 2015;9:62–66. <https://doi.org/10.1159/000442855>.