

# The role of expert focus echocardiography during the COVID-19 pandemic

Eleanor McPhail BSc  | Nishat Jahagirdar BSc | Nicola Walker BSc |  
Scott Harris BSc | Mark Monaghan PhD | Alexandros Papachristidis MD

Department of Cardiology, King's College Hospital NHS Foundation Trust, London, UK

## Correspondence

Eleanor McPhail, BSc, Department of Cardiology, King's College Hospital NHS Foundation Trust, London, UK.  
Email: [Eleanor.mcphail@nhs.net](mailto:Eleanor.mcphail@nhs.net)

## Abstract

**Background:** Focus Echocardiography has routinely been used to offer quick diagnosis in critical care environments, predominantly by clinicians with limited training. During the COVID-19 pandemic, international guidance recommended all echocardiography scans were performed as focus studies to limit operator viral exposure in both inpatient and outpatient settings. The aim of this study was to assess the effectiveness of eFoCUS, a focus scan performed by fully trained echocardiographers following a minimum dataset plus full interrogation of any pathology found.

**Methods:** All diagnostic echocardiograms, performed by fully trained echocardiographers during an 8-week period during the first UK COVID-19 wave, were included. The number of images acquired was compared in the following categories: admission status, COVID status, image quality, indication, invasive ventilation, pathology found, echocardiographer experience, and whether eFoCUS was deemed adequate to answer the clinical question.

**Results:** In 87.4% of the 698 scans included, the operator considered that the eFoCUS echo protocol, with additional images when needed, was sufficient to answer the clinical question on the request. Echocardiographer experience did not affect the number of images acquired. Less images were acquired in COVID-19 positive patients compared to negative/asymptomatic ( $38 \pm 12$  vs.  $42 \pm 12$ ,  $p = .001$ ), and more images were required when a valve pathology was identified.

**Conclusion:** eFoCUS echocardiography is an effective protocol for use during the COVID-19 pandemic. It provides sufficient diagnostic information to answer the clinical question but differs from standard focus/limited protocols by enabling the identification and interrogation of significant pathology and incidental findings, preventing unnecessary repeat scans and viral exposure of operators.

## KEYWORDS

echocardiography, FoCUS echocardiography

**Abbreviations:** 2D, two-dimensional; 3D, three-dimensional; ASE, American Society of Echocardiography; BSE, British Society of Echocardiography; EACVI, European Association of Cardiovascular Imaging; eFoCUS, Expert Problem oriented Focus Cardiac Ultrasound; FoCUS, Problem oriented Focus Cardiac Ultrasound; GLS, global longitudinal strain; IP, inpatient; PPE, personal protective equipment; TAPSE, tricuspid annular plane systolic excursion; TTE, transthoracic echocardiography

## 1 | INTRODUCTION

Problem-oriented focus cardiac ultrasound examination (FoCUS) or Point of Care echocardiography is widely recognized as a useful method of assessing cardiac function to support the clinical presentation of a patient in an emergency care setting.<sup>1,2</sup> There are several FoCUS echocardiography protocols developed by professional bodies, however these are usually performed by non-echocardiography specialists such as intensive care physicians, anesthetists, and other non-cardiologists who undergo a condensed training programme.<sup>1,3,4</sup> FoCUS scans tend to be performed bedside in critically ill patients who are generally technically challenging with ultrasound machines limited to two-dimensional (2D) assessment. All these factors carry a risk of overlooking significant abnormalities and misinterpretation<sup>2,5</sup> and should not replace comprehensive echocardiography.

Comprehensive echocardiography is a full study performed by a highly specialized, suitably trained and accredited sonographer or Cardiologist. The operator follows a minimum dataset<sup>6,7</sup> to produce a detailed and thorough examination of cardiac structure and function. If an abnormality is detected, the sonographer will need to have the skill and expertise to investigate further, using additional views, measurements, and advanced techniques such as three-dimensional (3D) and myocardial strain (GLS) assessment.

The COVID-19 pandemic prompted a change in the provision of the echocardiography service worldwide. The American Society of Echocardiography (ASE) as well as the European Association of Cardiovascular Imaging (EACVI) and the British Society of Echocardiography<sup>8-10</sup> released relevant guidance. The recommendation was for all scans to be performed as goal-directed FoCUS scans performed by specialist sonographers. A restricted protocol was thought to reduce the viral exposure time of the sonographer whilst providing the necessary echocardiographic information to facilitate clinical decision-making. Our department's policy expanded on this to create an expert FoCUS (eFoCUS) protocol, defined as a minimum dataset with full interrogation of an identified pathology aiming to reduce requests for repeat scans seeking additional diagnostic information. An expert was defined as an echocardiographer with full BSE TTE accreditation or an equivalent internationally recognized accreditation.

The aim of this study was to assess the effectiveness of eFOCUS echocardiography use in a pandemic, as its role as a replacement for comprehensive echocardiography remains unclear.

## 2 | METHODS

We conducted a prospective, observational study evaluating the results of eFoCUS in a large tertiary hospital during the peak of the COVID-19 Pandemic.

All patients who underwent transthoracic echocardiography (TTE) during an 8-week period between March 18 and May 13 2020 were included. Scans performed by professionals who did not have a rec-

ognized full transthoracic echocardiography accreditation and all non-diagnostic scans due to suboptimal image quality were excluded. Studies which followed a specified protocol such as research and patients under private care were also excluded. Therefore, the included studies were those performed for clinical purposes, were of interpretable image quality, and performed by expert professionals defined as accredited individuals in adult transthoracic echocardiography who had completed the local departmental competency sign off to independently scan and report.

eFOCUS scans were conducted following a departmental protocol, created from the BSE Level 1 protocol,<sup>4</sup> described in the Appendix. Any significant cardiac pathological findings were to be interrogated comprehensively based on BSE and ASE guidelines.<sup>6,7</sup> In line with BSE recommendations, images were recorded using a two second time clip.<sup>8</sup> If an eFoCUS scan was not sufficient to answer the clinical question, a full comprehensive study was performed and documented. Scans were performed using the Philips CVx, or Philips Affinity ultrasound machines with the X5-1 or S5-1 probes (Philips Healthcare, Andover, MA) or the GE E95 ultrasound machine with the M5SC-D probe (GE Healthcare, Amersham, UK). Image acquisition, interpretation and technical report were performed by an echocardiographer with full BSE TTE accreditation or an equivalent internationally recognized accreditation.

Prospectively collected data included: name of echocardiographer, patient age, admission status (inpatient [IP] or outpatient [OP]), ventilation status, COVID-19 swab result, main indication for the scan, specialty requesting the scan, pathology(ies) detected, number of images recorded, the quality of images and repeat scans.

The quality of images was graded on a four point scale by the performing echocardiographer: 1 = non-diagnostic (inadequate image quality for meaningful interpretation), 2 = suboptimal (inability to perform standard measurements), 3 = fair (ability to perform some standard measurements), 4 = good (ability to perform all standard measurements). The image quality was reported directly from the operator performing the scan.

The echocardiographic analysis was performed off-line according to current guidelines.<sup>8</sup> Left ventricular size and function were assessed by biplane end diastolic volume and ejection fraction respectively; if poor endocardial definition of two or more segments, then size and function were visually assessed. Right ventricular size and function were assessed by linear dimensions, TAPSE, or by visual assessment. Atrial size was determined by volume measurements or visual assessment. Valve stenosis and regurgitation were assessed as per ASE guidelines or by visual assessment.

In order to investigate a learning curve effect on the number of acquired images per echocardiographic study, the time in days from the first scan to each subsequent scan was calculated for each operator. In addition, to assess possible correlation between the level of experience of the operators and the number of images acquired in their scans, the sonographers were divided in two groups based on the time since their accreditation: low experience: 1-5 years, and high experience: >5 years since accreditation (inclusive of 4 and 10 sonographers, respectively).

**TABLE 1** Baseline characteristics

Age (years)	60.2 ± 16.4
Gender (male)	425 (60.9%)
<b>Admission status</b>	
Inpatients	574 (82.2%)
Outpatients	124 (17.8%)
<b>COVID-19 status</b>	
Negative swab or asymptomatic	433 (62.0%)
Symptomatic/awaiting swab	108 (15.5%)
Positive swab	157 (22.5%)
<b>Ventilation</b>	
Self-ventilating/NIV	579 (83.0%)
Invasive ventilation	119 (17.0%)

Statistical analysis was performed using SPSS for Windows (ver. 26.0, IBM Corporation Software Group, Somers, NY). Continuous variables are presented as mean ± SD. The continuous variables were tested for normal distribution based on histograms. Differences between independent samples of continuous variables were tested using the independent samples Student *t*-test or ANOVA. Categorical variables were tested with chi-square test and Fisher's exact test as appropriate and are presented as absolute values and percentages. The correlation between operators' experience in the eFOCUS protocol (days from the first scan) and number of acquired images per scan was tested with the Pearson's correlation coefficient. Statistical significance was considered for a two-tailed *p* value < .05.

The study was approved by the Hospital's Cardiovascular Audit Committee (Reference No: CV002-2020).

### 3 | RESULTS

In total, 879 TTEs were performed within the study period, out of which 181 scans were excluded, as were not performed by a fully accredited echocardiographer (*n* = 169), had technical issues (*n* = 5), performed on private patients (*n* = 4), followed research protocols (*n* = 2), or were undiagnostic due to inadequate image quality (*n* = 2). Hence, 698 echocardiograms were included in this study.

The baseline characteristics are shown in Table 1. The mean age was 60.2 ± 16.4 years and 60.9% were male. 574 were inpatients (82.2%) and 119 (17.0%) were invasively ventilated. 157 patients (22.4%) had a confirmed COVID-19 infection at the time of the scan, 108 (15.4%) had declared symptoms suggestive of COVID-19 and they were awaiting the swab result and 433 (61.8%) had a negative swab test or were asymptomatic. The indication for TTE and the image quality of the scans are shown in Figure 1.

In 501 echocardiograms (71.5%) a cardiovascular pathology was identified. Total 299 patients (42.7%) were found to have a cardiac chamber (left or right ventricular) pathology, 355 (50.7%) had a valvular pathology (graded as mild or more) and 179 (25.5%) had "other

pathology" identified. Other pathologies included pathology of the aorta, pericardial or pleural effusion, left ventricular outflow tract obstruction, congenital cardiac anomalies, elevated pulmonary artery systolic pressure, constrictive pericarditis and thrombus. The identified pathologies are shown in Figure 2.

As a validation test, five echocardiograms from each sonographer were randomly selected and they were reviewed by an experienced sonographer (>5 years since accreditation) blinded to the initial report. A variety of pathologies, including chamber and valve pathologies, were identified in 46 scans, whereas 24 scans were normal. The agreement in interpretation between the initial operator and the blinded reviewer was 100%.

Overall, in 612 cases (87.4%) the operator considered that the eFOCUS echo protocol, with additional images when needed, was sufficient to answer the clinical question on the request.

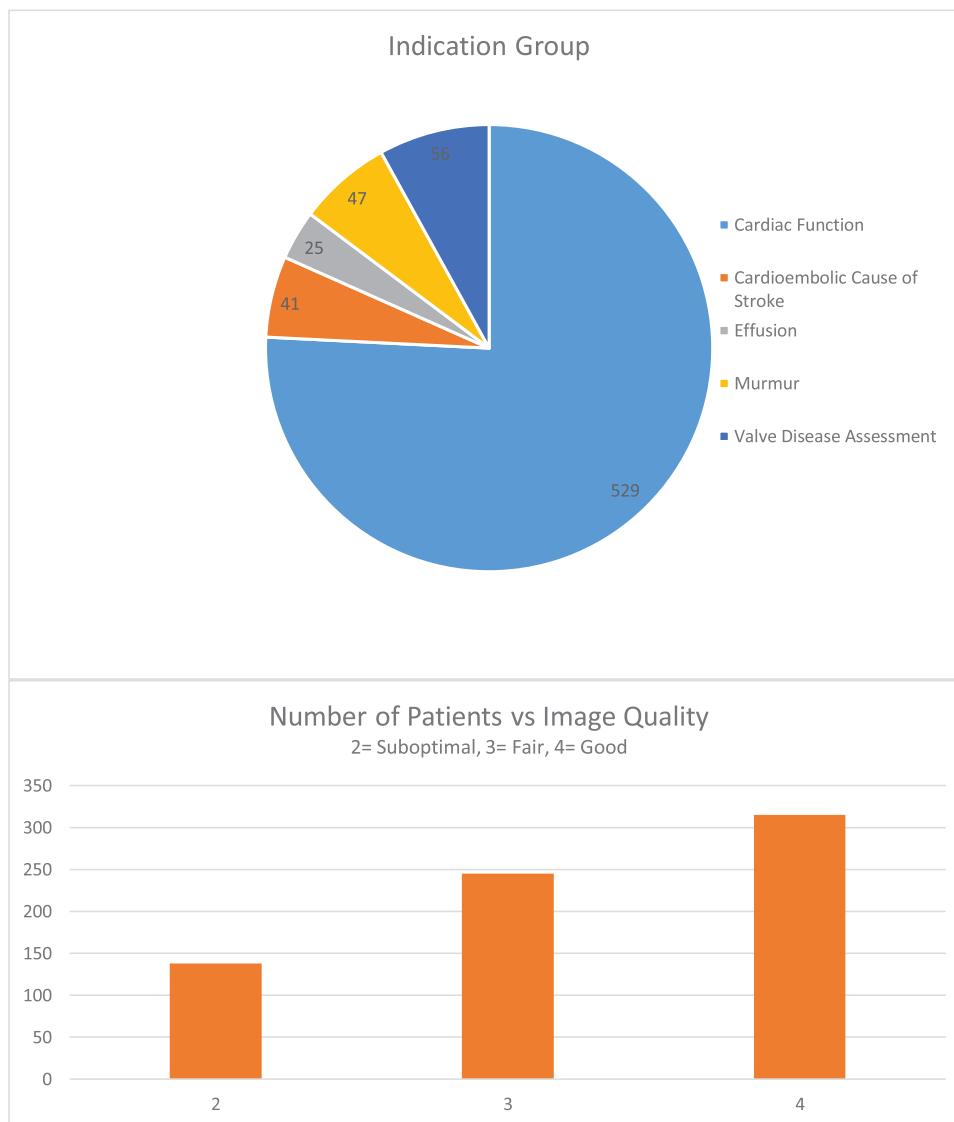
We sought to investigate if the number of acquired images per echocardiographic study were correlated to 1) patient admission status (inpatient vs. outpatient), 2) COVID status (negative swab and asymptomatic vs. symptomatic awaiting swab results vs. positive swab), 3) image quality of the TTE, 4) sonographer's experience (1–5 years vs. > 5 years), 5) indication for TTE (cardiac function; valve disease; murmur; effusion; cardiac source of emboli), 6) ventilation status, 7) whether FOCUS echo was considered adequate to provide a diagnosis or not, and 8) pathology identified.

The distribution of image quality (poor/fair/good) between mechanically ventilated and non-ventilated patients was 16.8%/34%/49.2% versus 34.5%/40.3%/25.2%, respectively (*p* < .001).

The results are presented in Table 2. More images were acquired in outpatients compared to inpatients (45 ± 14 vs. 41 ± 12, *p* = .001), on patients with negative or pending swab compared to those with positive swab test, and on patients who were not invasively ventilated (Table 2). Regarding the echocardiographic findings the operators obtained more images when investigated valve disease as opposed to cardiac function or effusions. The experience of operators did not impact on the number of echo images per scan. When the eFOCUS protocol was not considered adequate to answer the clinical question on request, more images were acquired by the operators. Finally, when the image quality was suboptimal, the operator acquired fewer images.

In addition, we explored whether the exposure of the operator to the specified eFOCUS protocol correlated with the number of the acquired TTE images. The experience was calculated in days since each operator's first scan in the protocol, and no correlation was found between the two (Pearson's product moment correlation coefficient *r* = .038; *p* = .319).

The COVID-19 status (negative/asymptomatic vs symptomatic awaiting results vs. positive) was correlated to the prevalence of cardiac pathologies identified on echo (78.2% vs. 87.4% vs. 89.3%; *p* = .006). The same applied when we looked at specifically ventricular pathology on echocardiograms (40.8% vs. 57.1% vs. 47.9%; *p* = .008). Finally, we examined the correlation of referrer specialty with the prevalence of abnormal findings on TTE. A cardiac pathology was more likely to be identified when the TTE was requested by Cardiologists (89.6%) as opposed to General practitioners (62.5%), emergency



**FIGURE 1** TTE indication and image quality

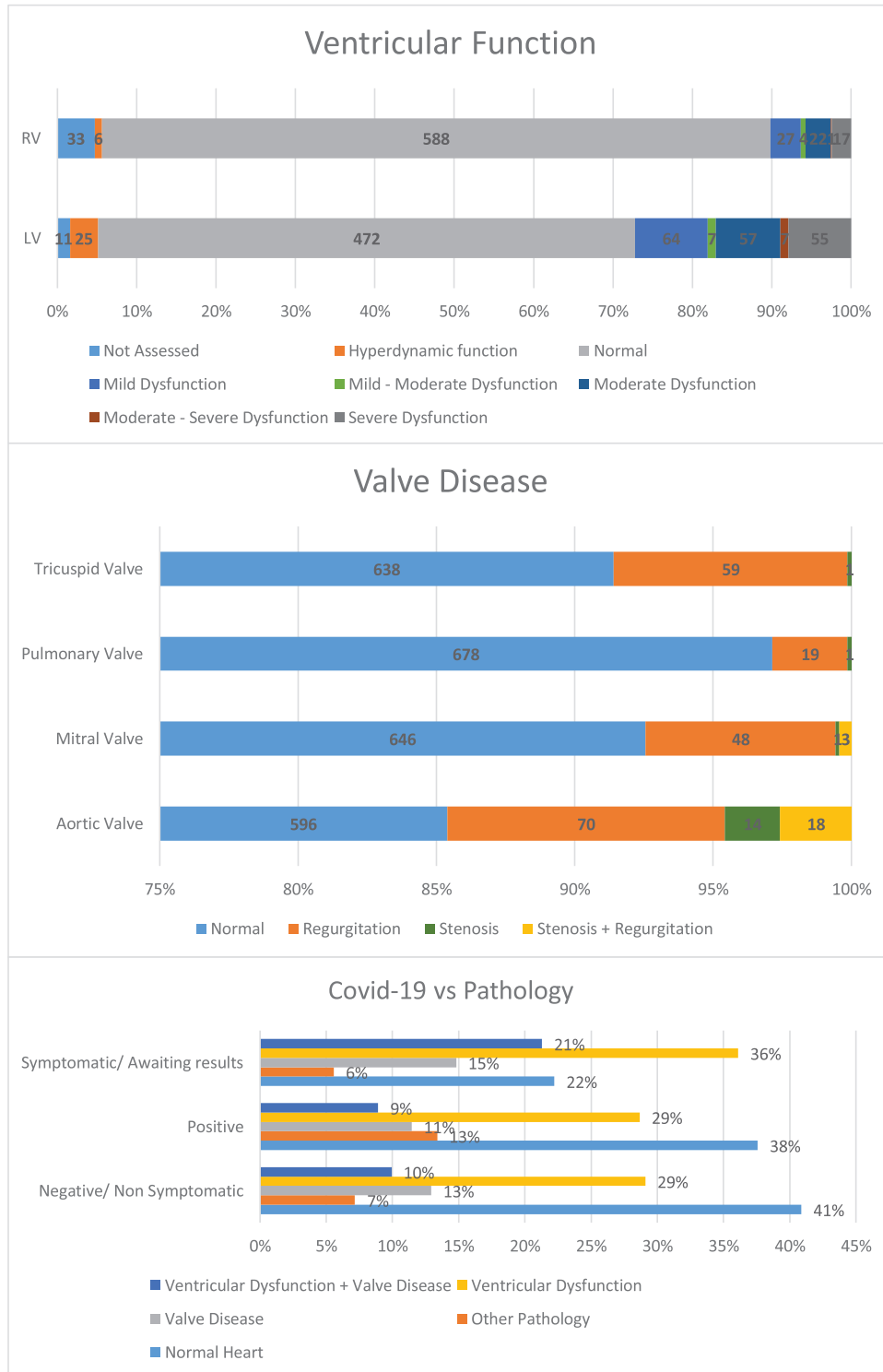
department physicians (84.6%) or non-cardiology specialists (78.5%);  $p = .008$ .

#### 4 | DISCUSSION

This study demonstrates that expert focus echocardiography by accredited operators was effective during the pandemic. Only nine patients required a repeat echo within the study period, and all requests were due to a change in clinical status or readmission. This is in contrast to a previous study by Hall et al.<sup>5</sup> where 40% of FICE echoes, performed by FICE accredited clinicians, were repeated with a comprehensive echo by a BSE/ESE accredited sonographer. They found there was no contradiction or significant findings missed with the FICE studies, however a comprehensive scan provided additional information in 68% of the repeated studies, including valve disease, infective endocarditis assessment and pulmonary artery pressure. All

focus echocardiograms in our study were performed by an operator with full TTE accreditation as opposed to FICE accredited operators, hence any pathology identified was interrogated fully at the time of the scan. This also allowed incidental findings to be identified, interrogated and reported, such as aortic pathology and pulmonary artery pressure at the same time. Thus, providing more diagnostic information than a standard focal scan. Josza et al,<sup>11</sup> yielded similar results having only one refuted scan. However, their mean number of images per focus scan was significantly lower than in our study. This could be due to their operators adhering to a specified minimum dataset such as Level 1, whereas our operators followed a minimum dataset plus full interrogation of an identified pathology as per comprehensive guidelines.

The number of images taken were higher in outpatients and asymptomatic inpatients, however the incidence of pathology was higher in the symptomatic/awaiting results and the COVID-19 positive groups. The lower number of images in symptomatic/awaiting results and



**FIGURE 2** Pathology detected

COVID positive groups, could be due to lack of confidence in the PPE issued and a concern over viral load. The ASE and BSE<sup>8,9</sup> both released statements suggesting the risk of healthcare workers, especially echocardiographers contracting COVID-19 was high, due to the close face to face nature of their work, however there is limited data on this. Usage of full PPE for COVID- positive patients is time consum-

ing and uncomfortable which could have also affected the number of images taken on these patients.<sup>12</sup> The number of images taken on ventilated patients were less than non-ventilated patients. This could have been due to the difficulty in obtaining images when the patients are in supine position and also be directly related to poorer image quality in ventilated patients.

**TABLE 2** Number of images per group categories

	Average number of images $\pm$ SD	p value
Admission status		.001
Inpatients	41 $\pm$ 12	
Outpatients	45 $\pm$ 14	
COVID status		.001
Negative/Asymptomatic	43 $\pm$ 12	
Symptomatic/Awaiting	43 $\pm$ 13	
Positive	39 $\pm$ 12	
Image Quality		<.001
Suboptimal	39 $\pm$ 11	
Fair	42 $\pm$ 11	
Good	44 $\pm$ 13	
Sonographer Experience		.26
Low (1–5 yrs)	41 $\pm$ 12	
High (>5 years)	42 $\pm$ 13	
Indication		<.001
Cardiac Function	41 $\pm$ 12	
Valve Disease	49 $\pm$ 16	
Murmur	44 $\pm$ 11	
Effusion	34 $\pm$ 11	
Cardiac Source of emboli	44 $\pm$ 9	
Invasive ventilation		<.001
No	43 $\pm$ 12	
Yes	38 $\pm$ 11	
eFOCUS echo adequate		<.001
No	53 $\pm$ 16	
Yes	41 $\pm$ 11	
Pathology identified		.042
No	41 $\pm$ 10	
Yes	44 $\pm$ 13	

Valve pathology required more images to be taken than ventricular pathology, pericardial effusions or other incidental findings. This can be explained due the inherent complexity of valve diseases and the local departmental and professional body guidelines for valve pathology investigation, which recommend a more comprehensive echocardiographic study.<sup>6,13</sup>

The experience of the operator did not affect the number of images recorded and there was no learning curve throughout the implementation of the expert focus echo protocol. This could suggest the protocol was well adhered to and the professional accreditations and local departmental sign off procedures work well to create consistent standards.

A cardiovascular pathology was diagnosed on 71.8% of scans performed, with Cardiologists and Emergency Medicine having the highest percentage of pathology found per number of referrals. During COVID-

19, the BSE, ESE, and ASE<sup>8–10</sup> all provided guidance for more stringent sanctioning criteria to reduce viral exposure to operators. The absence of a control group presents a limitation to this study as the expected percentage is unknown, therefore it is difficult to conclude if this high percentage is due to a higher sanctioning threshold.

This is a single centre study with the inherent limitations and bias. There is a thorough sign off process in our department and all operators in this study were fully accredited in TTE. Therefore, our results may not apply to less experienced operators such FICE operators. This was not a controlled study, hence no comparisons were made to full protocol echocardiograms. The time taken for the eFOCUS examinations was not assessed and therefore not quantified, though it is expected to be reflected by the number of images acquired. Finally, data regarding diastolic function were not recorded systematically as diastology did not fall into the scope of the focused protocol. However, this is something to be considered in future studies.

## 5 | CONCLUSION

In this study, an eFOCUS echocardiography protocol was applied by fully accredited operators and its efficiency was evaluated in 698 patients during the COVID-19 pandemic. The protocol was found to provide sufficient diagnostic information to answer the clinical question but differs from standard focus/limited protocols by enabling the identification and interrogation of significant pathology and incidental findings, preventing unnecessary repeat scans and viral exposure to operators. A change in practice was identified by the number of images taken in negative/asymptomatic group versus symptomatic/awaiting results and covid-19 positive patients, as operators acquired less images when the risk of exposure was higher.

## ACKNOWLEDGMENTS

The authors would like to thank the Echocardiography team at King's College Hospital for their echocardiographic skills and time uploading data for collection, without whom this research would not have been possible. This study received no funding or sponsorship from external sources, therefore there are no conflicts of interest. The study was approved by the Hospital's Cardiovascular Audit Committee (Reference No: CV002-2020)

## ORCID

Eleanor McPhail BSc  <https://orcid.org/0000-0001-6994-5975>

## REFERENCES

- Spencer K, Kimura B, Korcarz C, Pillikka P, Rahko P, Siegal R. Focused cardiac ultrasound: recommendations from the American Society of Echocardiography. *J Am Soc Echocardiogr*. 2013;26(6):567–581.
- Neskovic A, Edvardsen T, Galderisi M, et al. Focus cardiac ultrasound: the European Association of Cardiovascular Imaging viewpoint. *Eur Heart J Cardiovasc Imaging*. 2014;15(9):956–960.
- Resuscitation Council UK. FEEL - Focused Echocardiography in Emergency Life Support course. 2020; Available from: <https://www.resus.org.uk/information-on-courses/focused-echocardiography-in-emergency-life-support/>.

4. Hindocha R, Garry D, Short N, et al. A minimum dataset for a Level 1 echocardiogram: a guideline protocol from the British Society of Echocardiography. *Echo Res Pract.* 2020;7(2):G51–G56. <https://doi.org/10.1530/ERP-19-0060>.
5. Hall D, Jordan H, Alam S, Gilles S. The impact of focused echocardiography using the Focused Intensive Care Echo protocol on the management of critically ill patients, and comparison with full echocardiographic studies by BSE-accredited sonographers. *J Intensive Care Soc.* 2017;18(3):206–11.
6. Mitchell C, Rahko P, Blauwet L, et al. Guidelines for performing a comprehensive transthoracic echocardiographic examination in adults: recommendations from the American Society of Echocardiography. *J Am Soc Echocardiography.* 2019;32(1):1–64.
7. Wharton G, Allen J, Phillips H, et al. A minimum dataset for a standard adult transthoracic echocardiogram: a guideline protocol from the British Society of Echocardiography. *Echo Res Pract.* 2015;2(1):G9–G24.
8. Augustine D, Willis J, Robinson S, et al. *COVID-19 clinical guidance.* 2020. Available from: <https://www.bsecho.org/Public/Education/COVID-19-clinical-guidance.aspx>.
9. Kirkpatrick J, Mitchell C, Taub C, Kort S, Hung S, Swaminathan M. ASE statement on protection of patients and echocardiography service providers during the 2019 novel coronavirus outbreak. *J Am Coll Cardiol.* 2020;75(24):3078–3084.
10. Skulstad H, Cosyns B, Popescu B, et al. COVID-19 pandemic and cardiac imaging: EACVI recommendations on precautions, indications, prioritization, and protection for patients and healthcare personnel. *Eur Heart J Cardiovasc Imaging.* 2020;21(6):592–598. <https://doi.org/10.1093/ehjci/jeaa072>.
11. Jozsa C, Ussen B, Monteiro R, Bugcang R, Lloyd G, Bhattacharyya S. Impact of focused echocardiography on scan time and diagnostic quality in Patients with COVID-19? *J Am Soc Echocardiography.* 2020;33(11):1415–1416. <https://doi.org/10.1016/j.echo.2020.08.007>.
12. Zhang L, Wang B, Zhou J, Kirkpatrick J, Xie M. Bedside focused cardiac ultrasound in COVID-19 from the Wuhan epicenter: the role of cardiac point-of-care ultrasound, limited transthoracic echocardiography, and critical care echocardiography - Journal of the American Society of Echocardiography (doi.org). *J Am S Echocardiography.* 2020;33(6):676–682.
13. Baugartner H, Hung J, Bermejo J, et al. Echocardiographic assessment of valve stenosis: EAE/ASE recommendations for clinical prac-

tics' *European Journal of Echocardiography* 2009;10:1–23. <https://doi.org/10.1093/ejehocard/jen303>.

**How to cite this article:** McPhail E, Jahagirdar N, Walker N, Harris S, Monaghan M, Papachristidis A. The role of expert focus echocardiography during the COVID-19 pandemic. *Echocardiography.* 2022;39:701–707. <https://doi.org/10.1111/echo.15351>

## APPENDIX

### Expert Focus Protocol:

Images taken with a 2 s time strip, no ECG.

#### Parasternal Views:

PLAX  
 PLAX (color AV and MV)  
 PSAX – LV Level  
 PSAX – AV level (color AV, TV, PV. CW for TR)

#### Apical Views:

Apical 4 chamber view – (color MV, AV, TV, CW for AV and TR)  
 Apical 2 chamber view – (color MV)  
 Apical 3 chamber view – (color AV and MV)

#### Subcostal Views:

Standard Subcostal – effusion check  
 IVC Compliance

#### Pathology

If any pathology > mild grading identified via visual, Color/CW Doppler assessment then a full interrogation of that pathology must be conducted as per BSE/ASE comprehensive guidelines. Additional images and measurements should also be conducted when this is required to answer the clinical question, such as diastolic function. Pleural B-Lines were not assessed.

Adapted from: BSE Level 1 guidelines<sup>4</sup>