



Intracameral bleeding during femtosecond laser assisted cataract surgery: A case report

Anagha Heroor, Vikram Vaidee *

Anil Eye Hospital, Dombivli, India

ARTICLE INFO

Keywords:

Femto laser assisted cataract surgery
Docking
Intracameral bleeding

ABSTRACT

Purpose: To report a case of anterior chamber bleeding that was noted post completion of laser during femtosecond laser assisted cataract surgery (FLACS).

Observations: A 54 yr old woman with no ocular and systemic morbidity underwent Right Eye FLACS. Vacuum loss was noted due to patient's eye movements. Suction and Docking was achieved at the 2nd attempt, following which laser treatment was uneventful. An intracameral bleed was noted superiorly extending towards center of the anterior chamber. Cataract surgery with IOL implantation was uneventful. Post-operative course was uneventful.

Conclusions and importance: This is the first report in literature of intracameral bleeding during FLACS. It is essential to proceed with caution in patients with repeated vacuum loss due to a higher risk of developing intraocular bleeds.

1. Introduction

Spontaneous intracameral bleed has not been known to occur during FLACS. We present a patient with no ocular or systemic risk factors who developed anterior chamber bleeding post femtosecond laser after a single failed attempt at docking during FLACS.

2. Case report

A 54 yr old woman with no ocular and systemic morbidity underwent Right Eye FLACS for a grade 2 nuclear sclerotic cataract (Grade NUC – 2).¹ Left eye FLACS done 2 weeks back was uneventful. Preoperative biometry with IOL-Master 700 (Carl Zeiss Meditec, Jena, Germany) was as follows: Keratometry K1- 42.44@67 K2 – 43.09 @157 Axial length – 22.51 Anterior Chamber Depth – 2.63 Horizontal corneal diameter(WTW) – 11.8.

Under topical anesthesia, the patient was positioned beneath a femtosecond laser (Catalys AMO; Abbott Laboratories, Inc., Abbott Park, IL, USA). Suction ring was placed. Vacuum loss was noted before docking due to patient's eye movements. The second attempt was successful with total vacuum time of 1min 34 sec. Patient then underwent uneventful laser capsulorhexis (laser time 1.5 sec) and lens fragmentation (laser time 16.5 sec) with a total laser time of 18 sec. Total energy for

capsulotomy was 0.7 J and lens fragmentation was 2.8 J.

Intracameral bleed was noted while applying topical local anaesthetic drops in the waiting area prior to surgery. Patient was then shifted to the OPD. Anterior segment showed no subconjunctival haemorrhage, clear cornea and pupil was fully dilated. Anterior chamber haemorrhage extending from the superior angle at 12 o'clock towards the center of the anterior chamber was noted as shown in [Figures \(1-3\)](#). Rhexis and lens fragmentation was complete. Posterior segment was normal. Under topical anesthesia routine phacoemulsification with a single-piece hydrophobic acrylic monofocal intraocular lens of +25 D was implanted. Post-operative course was uneventful with vision 6/6 ([Fig. 4](#)). Gonioscopy done at 4 weeks showed normal angle structures.

3. Discussion

Femtosecond laser assisted cataract surgery has become popular as a safe, effective and high precision platform to perform the initial steps in cataract surgery.²⁻⁴ Spontaneous intracameral bleeding has not been reported post FLACS. One case of suprachoroidal haemorrhage has been reported post flacs.⁵ Macular haemorrhage has been documented post microkeratome and femtosecond laser.^{6,7}

Ocular and systemic risk factors for spontaneous intracameral bleeding includes history of trauma, glaucoma, ocular ischemia, by

* Corresponding author.

E-mail address: vaideevikram@gmail.com (V. Vaidee).

<https://doi.org/10.1016/j.ajoc.2022.101655>

Received 3 May 2022; Received in revised form 29 June 2022; Accepted 30 June 2022

Available online 8 July 2022

2451-9936/© 2022 The Authors. Published by Elsevier Inc. This is an open access article under the CC BY-NC-ND license (<http://creativecommons.org/licenses/by-nc-nd/4.0/>).

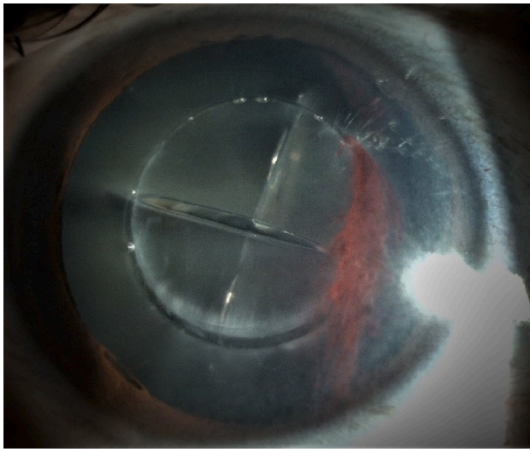


Fig. 1. Post Femto laser Intracamerular bleed (Diffuse).

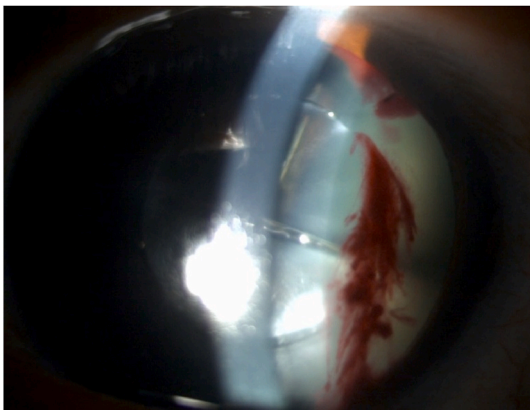

Fig. 2. Post Femto laser Intracamerular bleed (Slit).

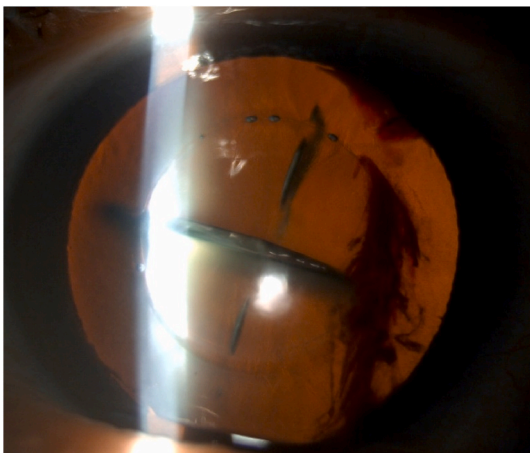


Fig. 3. Post Femto laser Intracamerular bleed (Retroillumination).

abnormalities of iris and angle structures, intraocular tumors, blood dyscrasias and systemic anticoagulant therapy.⁸⁻¹⁰ Our patient had a normal pre-operative anterior and posterior segment. There was no history of past trauma or any ocular morbidity. She was not on any systemic medications. She also had a normal uneventful cataract surgery in the other eye.

Applanation based systems for flacs have been shown to have higher intraocular pressure (IOP) as compared to Liquid Optical Interface

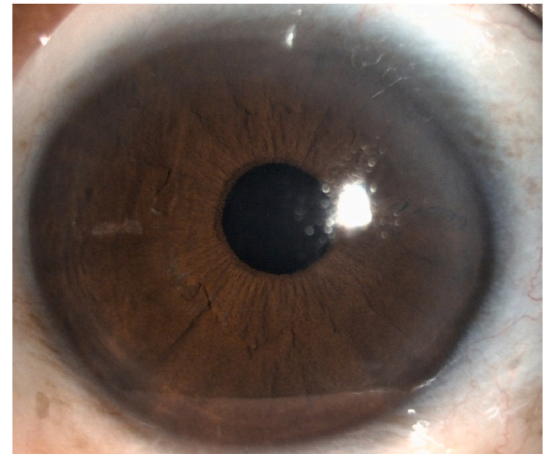


Fig. 4. Post operative Day 1.

systems (LOI). Iop fluctuations due to repeated undocking from the femtolaser could cause a rupture of the iris blood vessel in the angle. Manual compression force by the surgeon to achieve suction and Lens fragmentation gas have also been shown as possible factors for IOP fluctuations and small vessel bleeds.^{4,11,12} We have been using the catalys system which has been shown to have lower iop during suction and docking.¹³ Our patient had only a single vacuum loss before docking due to eye movement. The 2nd attempt was successful with uneventful laser capsulotomy and fragmentation. Surgeon performing laser was well versed with the system and compression force applied was noted to be the same as in all cases.

We believe a combination of repeat docking, eye movements, iop fluctuations and gas formation post fragmentation could have potentially led to small iris vessel rupture in the superior angle causing intracamerular bleeding post laser. It is essential to do a detailed slit lamp evaluation to assess the angle, pupil, lens status, gonioscopy and look for posterior segment haemorrhages. Reassure the patient and consider doing the surgery under topical anesthesia. Intraoperatively, wash the anterior chamber, look for rebleed, lens stability and proceed with routine cataract surgery.

4. Conclusion

Our report highlights the possibility of intracamerular haemorrhages occurring during FLACS. Non cooperative patients with repeated suction docking are at higher risk for flacs related intraoperative small vessel haemorrhages. We would recommend a high degree of caution while proceeding with laser in these patients.

Patient consent

Consent to publish this case report has been obtained from the patient in writing.

Authorship

All authors attest that they meet the current ICMJE criteria for Authorship.

Declaration of competing interest

The following authors have no financial disclosures: AH, VV.

Acknowledgements

Funding: No funding or grant support

References

1. Thylefors B, et al. A simplified cataract grading system. *Ophthalmic Epidemiol.* 2002; 9:83–95.
2. Palanker DV, et al. Femtosecond laser-assisted cataract surgery with integrated optical coherence tomography. *Sci Transl Med.* 2010;2.
3. Reddy KP, Kandulla J, Auffarth GU. Effectiveness and safety of femtosecond laser-assisted lens fragmentation and anterior capsulotomy versus the manual technique in cataract surgery. *J Cataract Refract Surg.* 2013;39:1297–1306.
4. Sperl P, et al. Intraocular pressure course during the femtosecond laser-assisted cataract surgery in porcine cadaver eyes. *Invest Ophthalmol Vis Sci.* 2017;58: 6457–6461.
5. Bozkurt TK, Miller KM. Suprachoroidal hemorrhage during femtosecond laser assisted cataract surgery. *Am. J. Ophthalmol. Case Reports.* 2016;4:45–46.
6. Principe AH, Lin DY, Small KW, Aldave AJ. Macular hemorrhage after laser in situ keratomileusis (LASIK) with femtosecond laser flap creation. *Am J Ophthalmol.* 2004; 138:657–659.
7. Ellies P, Pietrini D, Lumbroso L, Lebuissou DA. Macular hemorrhage after laser in situ keratomileusis for high myopia. *J Cataract Refract Surg.* 2000;26:922–924.
8. Spierer A, Desatnik H. Anterior chamber hemorrhage during cataract surgery in Lowe syndrome. *Metab Pediatr Syst Ophthalmol.* 1998;21:19–21.
9. Blanton FM. Anterior chamber angle recession and secondary glaucoma: a study of the aftereffects of traumatic hyphemas. *Arch Ophthalmol.* 1964;72:39–43.
10. Georgescu RD, et al. Hyphema-from the effect to the cause. December *Rom. J. Mil. Med.* 2017;7.
11. Williams GP, et al. Comparison of intra-ocular pressure changes with liquid or flat appplanation interfaces in a femtosecond laser platform, 2015 *Sci Rep.* 2015;51(5): 1–11.
12. Talamo JH, et al. *Optical Patient Interface in Femtosecond Laser-Assisted Cataract Surgery: Contact Corneal Appplanation versus Liquid Immersion.* 2013. <https://doi.org/10.1016/j.jcrs.2013.01.021>.
13. Schultz T, Conrad-Hengerer I, Hengerer FH, Dick HB. Intraocular pressure variation during femtosecond laser-assisted cataract surgery using a fluid-filled interface. *J Cataract Refract Surg.* 2013;39:22–27.