

Broken Intraluminal Needle in an Intravenous Drug User – A Case Report and Review

Akshay Seth¹, Nitish Bansal¹, Punit Tiwari², Saurav Jain³

Learning Point of the Article:

Intraluminal intravenous needle breakage should be dealt with like an emergency, as there is a risk of migration of the needle fragment to proximal sites in the body.

Abstract

Introduction: Intravenous injections are an everyday practice in the health-care sector and are also frequently abused by drug abusers. One rare complication of intravenous injections is venous intraluminal breakage of the needle, which is a matter of concern due to the possible embolization of needle fragments in the body.

Case Report: We report our case of an intravenous drug abuser with an intraluminal breakage of a needle presenting within 2 h of the incidence. The broken needle fragment was retrieved successfully at the local injection site.

Conclusion: Intraluminal intravenous needle breakage should be treated as an emergency, and a tourniquet should be applied as soon as possible.

Keywords: Intravenous, drug abusers, intraluminal needle breakage, needle retrieval.

Introduction

Intravenous injections are an everyday practice in the health-care sector and are also frequently abused among drug abusers. According to a 2019 report published by the Ministry of Social Justice and Empowerment of the Government of India, India has an estimated 8.5 lakh intravenous drug abusers [1]. A substantial proportion of them report risky injecting practices. About half reported reusing their needles and syringes, and about a third reported experiencing vein-related complications, ulcers, and abscesses at the injecting sites [1]. Intraluminal breaking of the needle is a rare complication that should be taken seriously because it could result in the embolization of needle fragments. We are reporting the case of a young man with a history of intravenous injection of heroin using a reused needle resulting in its breakage inside the lumen of the proximal forearm vein.

Case Report

A 28-year-old male, right-hand dominant, an intravenous drug abuser for the past 5 years, presented to the orthopedics emergency department of our hospital with a history of pain, redness, and swelling in his left proximal forearm from the past 2 h. The patient admitted to injecting heroin into his left proximal forearm vein with a multiple times reused syringe and that the needle broke while injecting the drug. Immediately, a tourniquet was applied at the level of the midarm by the patient himself to prevent embolization of the needle. Radiographs (AP and Lateral view) of the left forearm confirmed the presence of a broken needle in the mid-left proximal forearm (Fig. 1a and b). The patient was taken to the operation theater with the tourniquet applied. Intraoperative fluoroscopy was used to

Author's Photo Gallery



Dr. Akshay Seth



Dr. Nitish Bansal



Dr. Punit Tiwari



Dr. Saurav Jain

Access this article online

Website:
www.jocr.co.in

DOI:
<https://doi.org/10.13107/jocr.2023.v13.i03.3584>

¹Department of Orthopaedics, GMC, Patiala, Punjab, India,
²Department of Orthopaedics, MMUHSMC, Solan, Himachal Pradesh, India,
³Department of Orthopaedics, Aruna Memorial Hospital, Bathinda, Punjab, India.

Address of Correspondence:
Dr. Nitish Bansal,
Department of Orthopaedics, GMC, Patiala, Punjab, India.
E-mail: nitishbansal88@gmail.com

Submitted: 14/12/2022; Review: 29/01/2023; Accepted: February 2023; Published: March 2023

DOI: <https://doi.org/10.13107/jocr.2023.v13.i03.3584>

This is an open access journal, and articles are distributed under the terms of the Creative Commons Attribution-NonCommercial-ShareAlike 4.0 License <https://creativecommons.org/licenses/by-nc-sa/4.0/>, which allows others to remix, tweak, and build upon the work non-commercially, as long as appropriate credit is given and the new creations are licensed under the identical terms



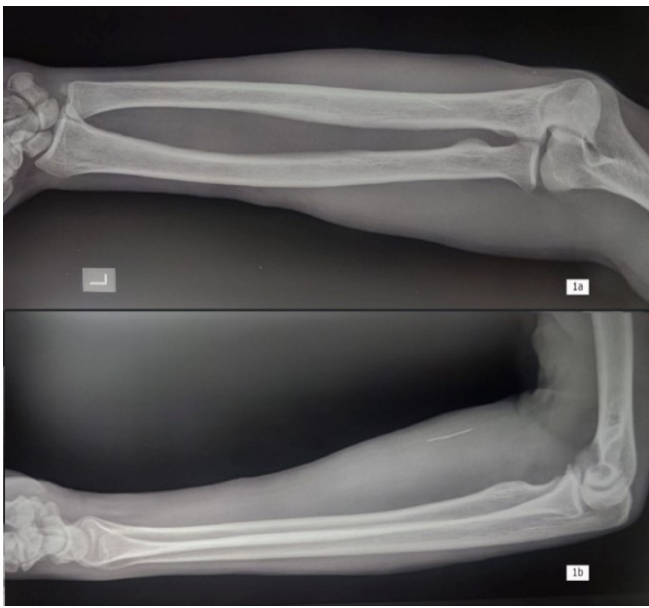


Figure 1: (a and b) Radiographs (anteroposterior and lateral views) of the left forearm confirming the presence of a needle in the proximal forearm.

identify the location of the needle fragment. Wound exploration was done after injecting local anesthesia around the suspected injection site (Fig. 2a), and an intact, slightly bent needle was seen in a superficial vein lumen (Fig. 2b). The needle was removed (Fig. 2c), and the damaged venous segment was suture ligated and resected.

Discussion

There are several instances reported of intraluminal breakage of the needle in intravenous drug abusers (Table 1). In a few cases, attempts were made to retrieve intraluminal broken needles, but the needles embolized to proximal sites in the body, including the heart and the lung [2, 3, 4, 5, 6, 7, 8, 9, 10, 11, 12, 13, 14, 15, 16, 17, 18]. There is not much literature that can be found on the successful retrieval of the needle at the injection site in intravenous drug abusers [14].

There is a lack of specific guidelines for needle retrieval. Leaving a needle as such can cause abscess formation [14] at the local site and, in extreme cases, can lead to endocarditis [8] and purulent pericarditis when embolized [10]. An attempt at removing the needle itself can sometimes lead to proximal migration of the needle during manipulation [4]. We strongly recommend that IV drug abusers be apprised of the risk of needle breakage, especially after repeated reuse of the needle, and the importance of a tourniquet application as soon as possible to prevent its migration proximally.

An important point that needs to be highlighted in our case

report is the patient's presentation time, which was within 2 h of the needle breakage. Early presentation makes the retrieval less complicated for the treating surgeon, as was the case with us. Late presentation risks the broken needle migrating in the body. Another critical point to highlight is the early application of a tourniquet by the patient himself immediately after the needle breakage, which prevented the proximal migration of the needle. Tourniquet use has been reported to be unsuccessful when applied late [4, 14].

Conclusion

Intraluminal intravenous needle breakage should be dealt with like an emergency, as there is a risk of migration of the needle fragment to proximal sites in the body. A tourniquet should be applied as soon as possible to avoid proximal migration of the needle.

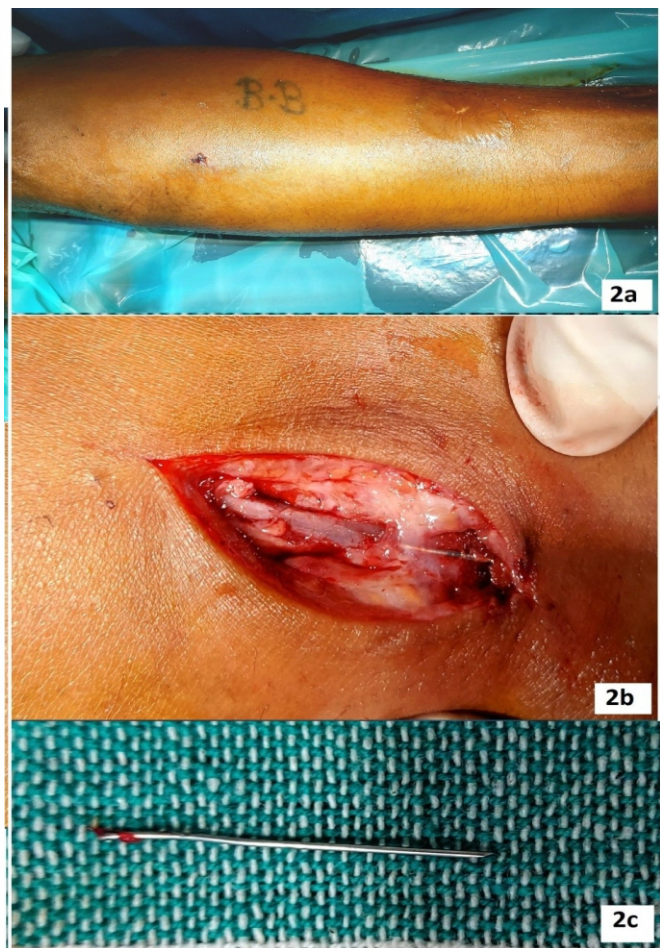


Figure 2: (a) Injection site on the proximal volar aspect of the forearm, (b) broken needle is seen in the lumen of the superficial vein, and (c) slightly bent and broken needle retrieved from the injection site.

Table 1: Summary of all reported cases

S No.	Author	Year	Number of cases	Age (years)	Site of injection	Site of migration of needle	Time of presentation from the time of needle breakage	Use of tourniquet	Treatment	Final outcome
1	Angelos et al. [2]	1986	1	36	Neck, region, Antecubital fossa	Lung parenchyma	3 days	*	Computed tomography of the thorax demonstrated bilateral cavitations consistent with multiple septic emboli, and the patient was put on IV antibiotics. Needles were left in situ, and the patient was discharged on oral antibiotics.	On follow-up after 1 year, the patient was asymptomatic.
2	Galdun et al. [3]	1987	1	33	Supraclavicular area	Right lower lung field	10 days	*	Needle left in-situ	*
3	Brunette and Plummer [4]	1988	2	30-39	Forearm Bilateral arms forearm	Lateral to Right hilum Lateral to Right hilum	Few hours 1 day	Two proximal tourniquets were applied by the attending doctor.	The patient was observed for 24 h and needle was left in-situ The patient was admitted to the hospital and was treated for bilateral upper extremity cellulitis with intravenous antibiotic therapy, splinting, and elevation. Needles in the forearm and the one lateral to the right hilum were left in situ.	On follow-up after 1 year, the patient was asymptomatic. On follow-up after 2 weeks, the patient was asymptomatic.
4	Gyrtrup et al. [5]	1989	1	32	Right Groin	Right Ventricle	Nine days	*	Thoracotomy/pericardial fluid drained. Needle removed	Lost to follow up.
5	Kulaylat et al. [6]	1993	1	37	Forearm	Right lower lung field	1 day	*	Local exploration was done, but the needle migrated to the lower lung field during the procedure	On follow-up after 10 months the patient was asymptomatic.
6	LeMaire et al. [7]	1998	1	31	*	Ventricular apex	2 years	*	The anterior, lateral, and diaphragmatic pericardial surfaces were excised through a median sternotomy. The abscess containing the needle was removed.	On follow-up (exact Duration of time not available) patient was asymptomatic.
7	Ngaage and Cowen [8]	2001	1	22	Groin	Right ventricle	2 years	*	The patient refused surgical removal	The needle is left embedded in the wall of the Right ventricle. The patient had three episodes of bacterial endocarditis.
8	Norfolk and Gray [9]	2003	23	19-42	Forearm-4 Groin-5 Antecubital fossa-3 Buttocks-2 Arms and Leg-5 Wrist-3 Hand-1	*	*	*	14 of the 23 broken needles were recovered, four through surgical intervention and ten through direct action by the individuals (removed the broken needle themselves because part of the needle was left protruding through the skin, two individuals reported having to push a completely embedded needle out through the skin to remove it and another reported removing a completely embedded needle with a razor blade). The remaining nine were not recovered and remained inside the body.	*
9	Steiner et al. [10]	2011	1	24	Left cephalic vein	Right ventricle	Few weeks (no exact data available)	*	Thoracocentesis, pericardiocentesis, and biopptome-assisted needle removal from the right ventricle followed by IV antibiotics for 6 weeks	*
10	Monroe et al. [11]	2012	2	28-28	Right Groin Right femoral vein	Right lung lower lobe Right lung middle lobe	Few hours 1 month	**	Needle left in situ. Wedge resection of pulmonary phlegmon with an embolized needle within the mass.	*
11	Thanavaro et al. [12]	2013	1	49	Neck, Both Legs	Protruding through the Right ventricular free wall into the Pericardial space	3 years	*	Median sternotomy with needle removal and Right ventricular perforation repair	*
12	Danek et al. [13]	2015	1	27	Cubital vein	Right ventricle apex	3 years	*	A conservative treatment strategy that included regular clinical follow-up and CT evaluation of needle position was used.	On follow-up after 1 year, the patient remained asymptomatic with no change in the position of the needle
13	Wilson et al. [14]	2015	1	30	Proximal forearm	Elbow joint	7 days	Tourniquet was applied by the attending doctor.	The needle migrated from the forearm to the elbow, and the needle was removed after local exploration.	*
14	Al-Sahaf et al. [15]	2016	1	39	Groin	Anterior chest wall adjacent to Right lung border	1 year	*	An anterior Thoracotomy was done, and the needle removed	*
15	Bompotis et al. [16]	2016	1	47	Neck	Right ventricle near the ventricular septum	4 days	*	Percutaneous removal of needle via the femoral vein	*
16	Fu et al. [17]	2017	1	40	Groin	Inferior wall of the right ventricle	20 days	*	The needle removed through open-heart surgery through a median sternotomy	*
17	Gladman [18]	2019	1	40	Groin	One needle in the Right external iliac vein and three within the groin	*	*	Needles left in situ.	The patient remained asymptomatic (exact time duration not available).
18	Levy et al. [19]	2019	1	27	Neck	Right ventricle	3 weeks	*	IV antibiotics for osteomyelitis of sternoclavicular joint and needle left in situ.	*

*Data unavailable

Table 1: Summary of all reported cases

Clinical Message

Intravenous drug abusers should be educated about safe injection practices and should be sensitized about reporting to the emergency as soon as there is needle breakage.

Declaration of patient consent: The authors certify that they have obtained all appropriate patient consent forms. In the form, the patient has given the consent for his/ her images and other clinical information to be reported in the journal. The patient understands that his/ her names and initials will not be published and due efforts will be made to conceal their identity, but anonymity cannot be guaranteed.

Conflict of interest: Nil **Source of support:** None



References

1. Ambekar A, Agrawal A, Rao R, Mishra AK, Khandelwal SK, Chadda RK. Magnitude of Substance use in India. New Delhi: AIIMS; 2019. Available from: <https://www.aiims.edu/en/national-drug-use-survey-2019.html> [Last accessed on 2023 Jan 28].
2. Angelos MG, Sheets CA, Zych PR. Needle emboli to lung following intravenous drug abuse. *J Emerg Med* 1986;4:391-6.
3. Galdun JP, Paris PM, Weiss LD, Heller MB. Central embolization of needle fragments: A complication of intravenous drug abuse. *Am J Emerg Med* 1987;5:379-82.
4. Brunette DD, Plummer DW. Pulmonary embolization of needle fragments resulting from intravenous drug abuse. *Am J Emerg Med* 1988;6:124-7.
5. Gytrup HJ, Andreassen KH, Pedersen JH, Mortensen LB. Central embolization of needle fragment following intravenous drug abuse. *Br J Addict* 1989;84:103-5.
6. Kulaylat MN, Barakat N, Stephan RN, Gutierrez I. Embolization of illicit needle fragments. *J Emerg Med* 1993;11:403-8.
7. LeMaire SA, Wall MJ Jr, Mattox KL. Needle embolus causing cardiac puncture and chronic constrictive pericarditis. *Ann Thorac Surg* 1998;65:1786-7.
8. Ngaage DL, Cowen ME. Right ventricular needle embolus in an injecting drug user: The need for early removal. *Emerg Med J* 2001;18:500-1.
9. Norfolk GA, Gray SF. Intravenous drug users and broken needles--a hidden risk? *Addiction* 2003;98:1163-6.
10. Steiner J, Dhingra R, Devries JT. Needle in the haystack: Purulent pericarditis from injection drug use. *Catheter Cardiovasc Interv* 2012;80:493-6.
11. Monroe EJ, Tailor TD, McNeeley MF, Lehnert BE. Needle embolism in intravenous drug abuse. *Radiol Case Rep* 2015;7:714.
12. Thanavaro KL, Shafi S, Roberts C, Cowley M, Arrowood J, Cassano A, et al. An unusual presentation of chest pain: Needle perforation of the right ventricle. *Heart Lung* 2013;42:218-20.
13. Danek BA, Kuchynka P, Palecek T, Cerny V, Hlavacek K, Lambert L, et al. Needle fragment embolism into the right ventricle: A rare cause of chest pain case report and literature review. *Wien Klin Wochenschr* 2016;128:215-20.
14. Wilson RJ, Crosby SN, Lee DH. Removal of a venous intraluminal needle: A case report. *J Hand Microsurg* 2015;7:170-2.
15. Al-Sahaf M, Harling L, Harrison-Phipps K, Bille A. An unusual case of needle embolus presenting with delayed spontaneous pneumothorax. *Ann Thorac Surg* 2016;102:e201-3.
16. Bompotis G, Karkanis G, Chatziavramidis A, Konstantinidis I, Dokopoulos P, Lazaridis I, et al. Percutaneous removal of a tiny needle fracture from the right ventricle of the heart in a drug abuser. *Vasc Endovascular Surg* 2016;50:575-8.
17. Fu X, Chen K, Liao X, Shen K. Case report: Surgical removal of a migrated needle in right ventricle of an intravenous drug user. *Subst Abuse Treat Prev Policy* 2017;12:51.
18. Gladman J. Pins and needles in the groin: An incidental finding of retained needle fragments in an intravenous drug user. *BMJ Case Rep* 2019;12:e226220.
19. Levy M, Hahn B, Aycock R. Needle embolization: Suspecting needle migration in intravenous drug abusers. *J Emerg Med* 2019.

Conflict of Interest: Nil
Source of Support: Nil

Consent: The authors confirm that informed consent was obtained from the patient for publication of this case report

How to Cite this Article

Seth A, Bansal N, Tiwari P, Jain S. Broken Intraluminal Needle in an Intravenous Drug User – A Case Report and Review. *Journal of Orthopaedic Case Reports* 2023 March;13(3):59-62.