

# Lumbar Artery Perforator Flap: Initial Experience with Simultaneous Bilateral Flaps for Breast Reconstruction

Nicholas T. Haddock, MD  
Sumeet S. Teotia, MD

**Background:** The lumbar artery perforator (LAP) flap is a useful alternative for patients who are not a candidate for breast reconstruction using the deep inferior epigastric perforator flap. Due to the positioning and concerns for prolonged ischemia time, bilateral breast reconstruction using LAP flaps is frequently performed in separate stages. We present our early experience performing simultaneous LAP flaps for bilateral breast reconstruction.

**Methods:** We performed a retrospective review of all patients who underwent breast reconstruction with LAP flaps from December 2018 to September 2019. Demographics, flap data, and complication data were collected. Surgical sequence is presented.

**Results:** A total of 30 simultaneous bilateral breast reconstruction were performed with LAP. We experienced 1 flap loss in an undiagnosed hypercoagulable patient. The average patient age was 52.7 years, and the average body mass index was 26.9. Most patients had a surgically absent abdominal donor site (66.7%). The average operative time was 510 minutes and ischemia time was 90.3 minutes. All flaps were performed using a composite deep inferior epigastric arterial/venous graft.

**Conclusions:** The LAP flap is an innovative, yet technically challenging, choice for autologous breast reconstruction. In our experience, simultaneous bilateral breast reconstruction using LAP flaps can be safely performed in a single surgical stage; however, we recommend caution and a coordinated team approach. With simultaneously performing bilateral LAP flaps, there is an inherent prolonged ischemia time and, thus, an increased possibility for vasospasm and intraoperative revisions. This experience represents the first series of bilateral LAP flaps performed simultaneously. (*Plast Reconstr Surg Glob Open* 2020;8:e2800; doi: [10.1097/GOX.0000000000002800](https://doi.org/10.1097/GOX.0000000000002800); Published online 18 May 2020.)

## INTRODUCTION

Breast reconstruction with autologous tissue continues to evolve. Most advancements have focused on limiting morbidity and recovery time and on improving the esthetic result. Much of the literature has focused on abdominally based perforator flaps, such as the deep inferior epigastric perforator (DIEP) flap. As techniques improve, we now offer alternative flaps and can more fully tailor the donor site choice to the individual undergoing breast reconstruction.

The lumbar artery perforator (LAP) flap has emerged as an additional option for breast reconstruction.<sup>1</sup> When more traditional donor locations, such as the DIEP flap, are not available, we consider both the profunda artery perforator (PAP) flap<sup>2</sup> and the LAP flap as often ideal secondary options. Many patients who undergo a cosmetic abdominoplasty continue to have truncal fullness. In these patients, the LAP flap is an excellent option. Additionally, with increased experience and modified techniques, success rates have approached those of other more commonly performed methods of autologous breast reconstruction.<sup>3</sup>

The LAP flap is typically harvested in the lateral decubitus or prone position. Due to the positioning and concerns for prolonged ischemia time, bilateral breast reconstruction using LAP flaps is frequently performed in 2 separate surgical stages. There are obvious drawbacks to this from a patient perspective, including an additional major surgery and prolonged time to complete reconstruction. We present our early experience performing simultaneous LAP

From the Department of Plastic Surgery, University of Texas Southwestern Medical Center, Dallas, Tex.

Received for publication October 16, 2019; accepted March 4, 2020.

Copyright © 2020 The Authors. Published by Wolters Kluwer Health, Inc. on behalf of The American Society of Plastic Surgeons. This is an open-access article distributed under the terms of the [Creative Commons Attribution-Non Commercial-No Derivatives License 4.0 \(CCBY-NC-ND\)](https://creativecommons.org/licenses/by-nc-nd/4.0/), where it is permissible to download and share the work provided it is properly cited. The work cannot be changed in any way or used commercially without permission from the journal.

DOI: [10.1097/GOX.0000000000002800](https://doi.org/10.1097/GOX.0000000000002800)

**Disclosure:** The authors have no financial interest to declare in relation to the content of this article.

flaps for bilateral breast reconstruction using a carefully coordinated team approach in a single stage.

## METHODS

We performed a retrospective review of a prospectively collected database of all breast reconstructions using LAP flaps from December 2018 to September 2019. Institutional review board approval was obtained. Patient demographics including age, body mass index, previous abdominal surgery, and history of radiation were included. Perioperative data included flap weight, pedicle length, composite graft length, ischemia time, total operative time, and length of stay. Postoperative complications included total flap loss, fat necrosis, lumbar hematomas, lumbar seromas, lumbar infections, and lumbar wounds. Fat necrosis was defined as any palpable area of firmness by the patient or any caregivers.

### Operative Technique and Sequence

The procedure begins in supine position, with chest preparation and harvest of bilateral deep inferior epigastric artery (DIEA) and vein (DIEV) composite grafts. Upon completion, the abdomen is closed in layers. The chest is packed and temporarily stapled closed. The patient is then repositioned in prone position. Hand-held Doppler is used to confirm perforator location,<sup>4-6</sup> and markings are modified as appropriate to mimic a posterior body lift. Simultaneous harvest is performed by the 2 authors from medial to lateral (Fig. 1). Perforator identification and dissection are performed as was previously presented.<sup>7</sup> Once the flaps are isolated on the perforators, the lateral lumbar region is partially closed over drains. One flap is harvested. On a separate back table, microsurgery is performed between the LAP flap and the DIEA/DIEV composite graft using a microscope (Fig. 2). Simultaneously, the donor site is rapidly closed with progressive tension sutures and in layers. The second LAP flap is then harvested, and the remaining donor site is closed. The patient is repositioned supine. During the repositioning, the second flap is also anastomosed to a

composite graft under the microscope on a back table. Once repositioned, the first flap is immediately anastomosed to the internal mammary vessels. If the second back table anastomosis is not completed, then the chest microsurgery is done with loupe magnification (Fig. 3). Once completed, the second flap is connected to the left internal mammary vessels. Inset then follows. Statistical analysis is performed with Excel (Microsoft, Redmond, WA) using *t* test and  $\chi^2$  test.

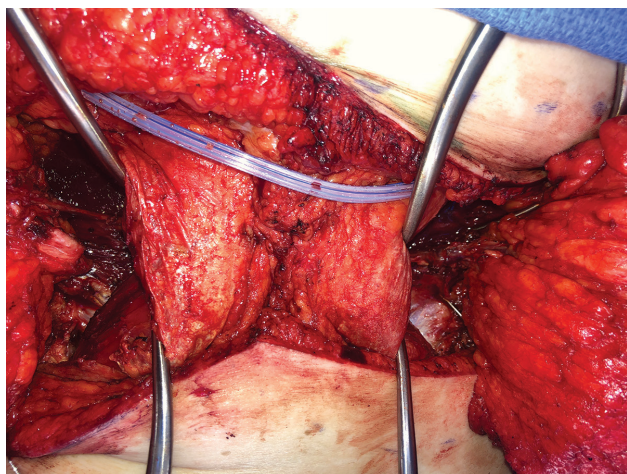
## RESULTS

We performed a total of 30 consecutive LAP flaps in the 1-year period in 15 patients. All 15 patients underwent simultaneous bilateral reconstruction. Three patients had LAP flaps as part of a multiflap procedure (with DIEP flaps or PAP flaps). Fourteen patients underwent delayed-immediate reconstruction, and one patient underwent immediate reconstruction.

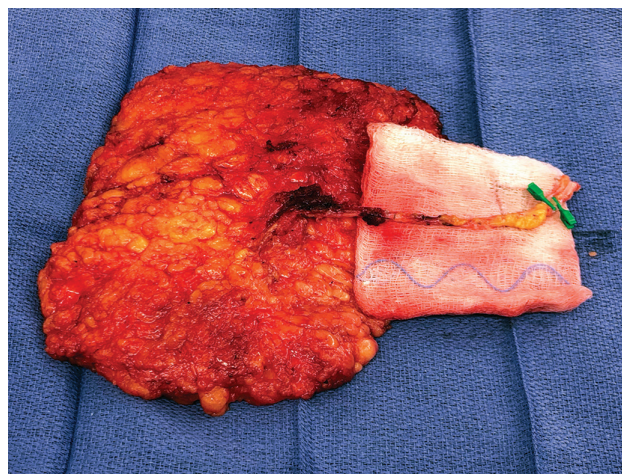
The average patient age was 52.7 years. The average patient body mass index was 26.8 (SD 4.6). Ten patients (66.7%) had a history of previous abdominoplasty or significant abdominal liposuction. Two patients had insufficient abdominal tissue for adequate body proportionate total breast reconstruction. The average harvest flap weight was 651 g (SD, 160; range, 426–1110 g).

Average LAP pedicle length was 4 cm (SD, 1.2; range, 2–8 cm). Composite grafts were used in all patients, and average length was 6 cm (SD, 1.2; range, 4–10 cm).

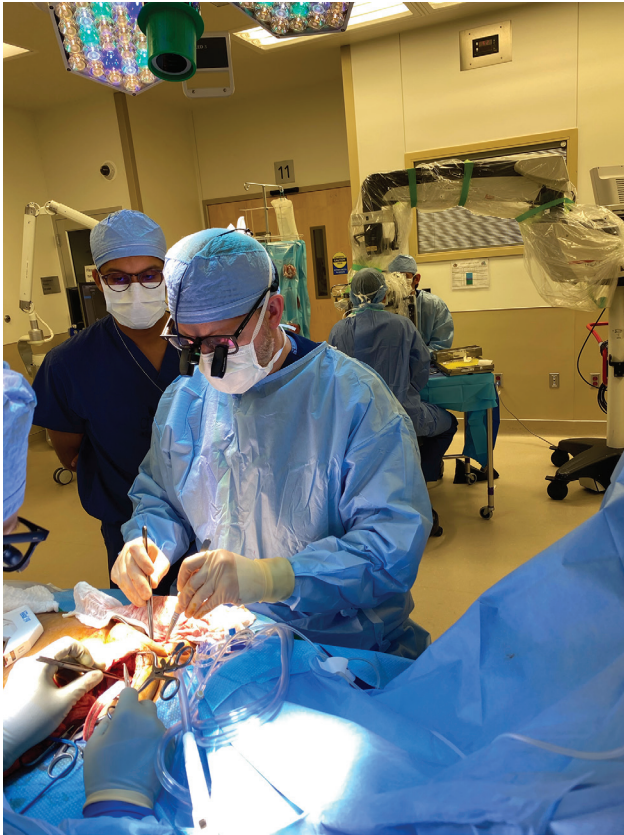Flap ischemia time averaged 90.3 minutes (SD, 33.5; range, 40–226 minutes). Given we harvest the flaps in sequence, we also evaluated the difference in ischemia time between the first and second harvested flaps (flap 1 average was 79.0 minutes, and flap 2 average was 99.2 minutes;  $P < 0.05$ ). There were 5 intraoperative arterial revisions. In 2 of these flaps, a vein was revised as well secondary to length discrepancy. There was an equal distribution of flaps requiring revision when evaluating sequence (first versus second harvested flaps, 3 versus 2). Revisions occurred equally at each anastomosis site (LAP to DIEA/DIEV 3 times and DIEA/DIEV to internal mammary 2



**Fig. 1.** Simultaneous perforator dissection of the LAP pedicle in prone position.



**Fig. 2.** LAP pedicle (4 cm) connected to a composite DIEA/DIEV graft (10 cm).

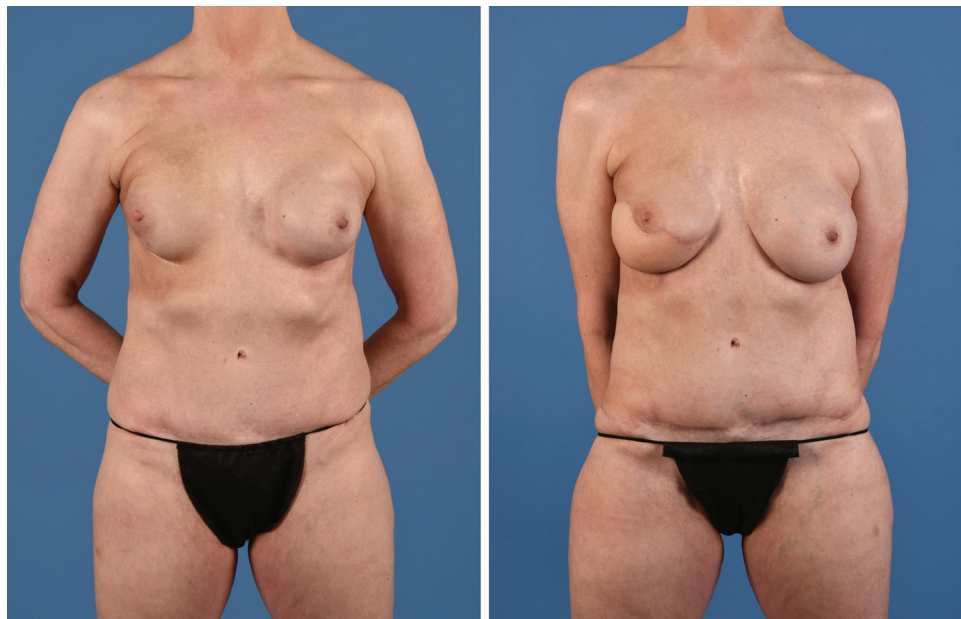

**Fig. 3.** Simultaneous microsurgery with the first LAP flap and DIEA/DIEV graft anastomosis to the internal mammary vessels under loupe magnification and the second LAP flap anastomosis to the DIEA/DIEV graft on a separate back table with the microscope.

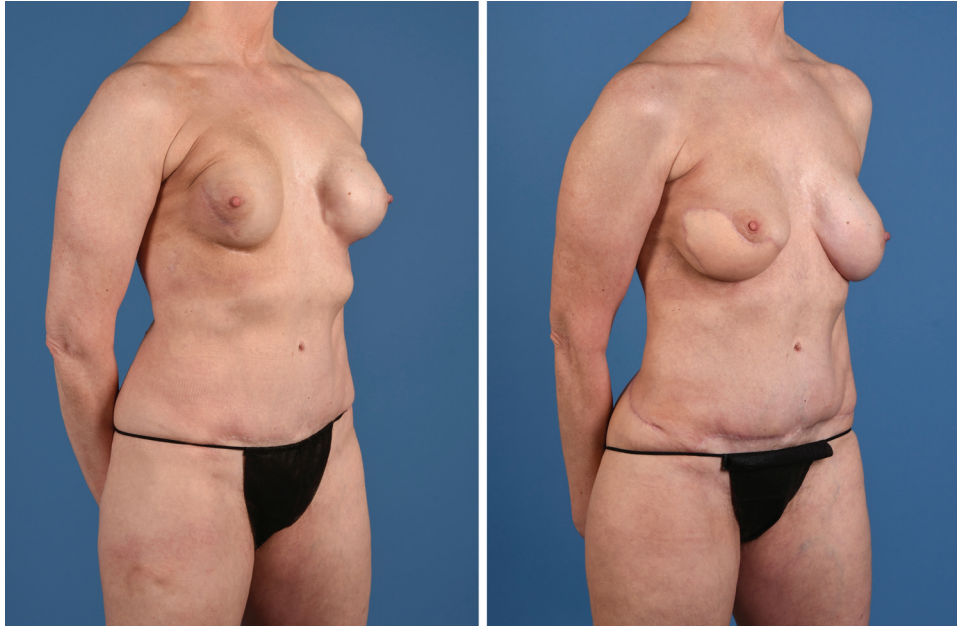
times). The total operative time for simultaneous bilateral LAP flaps was 509 minutes (SD, 73; range, 415–660 minutes), excluding the stacked flap patients. Interestingly, when excluding the stacked procedures (combined with bilateral DIEPs or PAPs), the average operative time was 510 minutes.

We experienced 2 flap losses (94.3% success). The first loss was on postoperative day 5, secondary to arterial thrombosis when systemic therapeutic heparin was converted to standard prophylactic dose. Before this, the patient was taken back to the operating room on postoperative day 2 with successful salvage of the same flap secondary to arterial thrombosis. The patient was ultimately found to have a hypercoagulable disorder (protein C). The second flap loss was on postoperative day 7. The patient had been discharged on postoperative day 3 with an uneventful hospital stay and was seen in clinic with bilateral viable flaps on postoperative day 6. She woke up the following day with an ischemic flap from arterial thrombosis. The mechanism of this delayed thrombosis is unclear, and at presentation to the hospital, it was not salvageable.

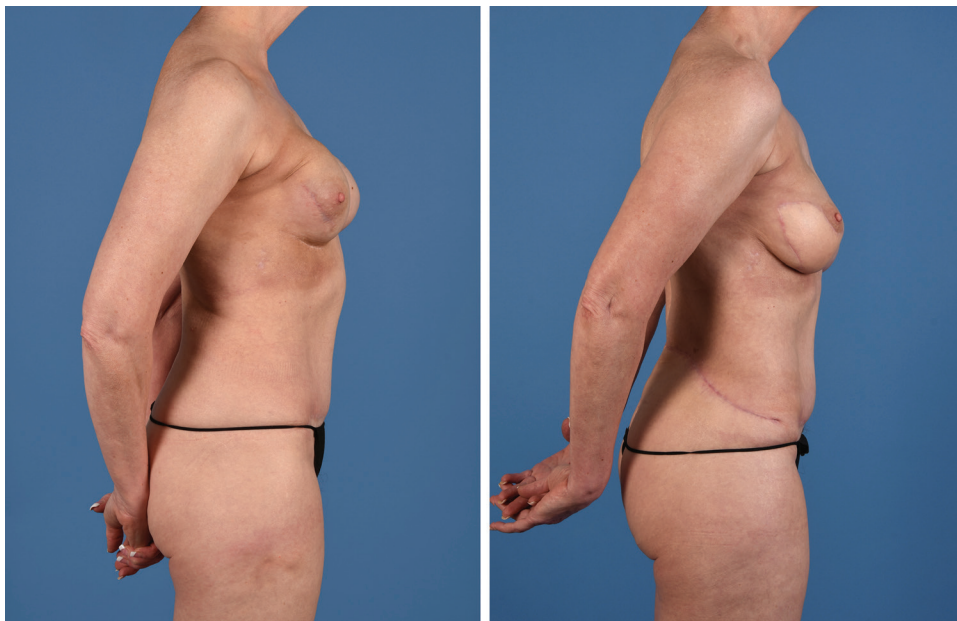
Length of stay was 3.4 days for all patients. Two patients requested to stay longer secondary to social reasons but were ready for discharge, and one patient stayed longer secondary to the flap loss. If these 3 patients were excluded, the average length of stay was 2.9 days. The stacked flaps had a length of stay of 3.0 days. There have been 4 donor site complications. There were 4 seromas, no hematomas, and no lumbar wounds. Two seromas occurred in patients who removed their own back drains. There were no deep venous thrombosis or pulmonary embolisms.



**Fig. 4.** Sixty-two-year-old woman who underwent bilateral nipple-sparing mastectomies and expander placement. She underwent subsequent radiation and developed a wound with a threatened expander on her right breast. She was reconstructed with simultaneous bilateral LAP flaps. Anterior view presented.



**Fig. 5.** Sixty-two-year-old woman following bilateral LAP flaps. Anterior oblique view presented.



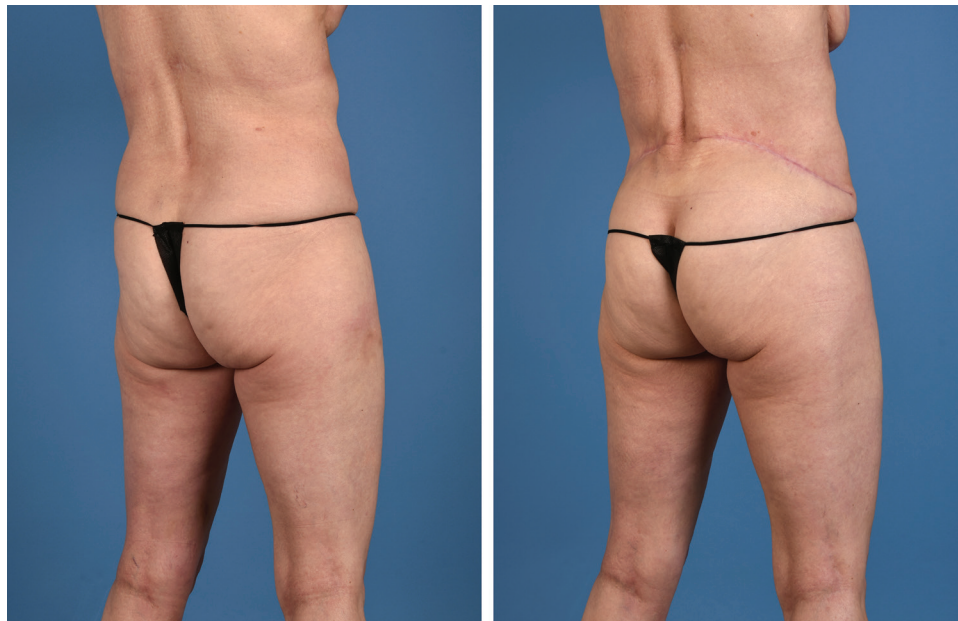**Fig. 6.** Sixty-two-year-old woman following bilateral LAP flaps. Lateral view presented.

## DISCUSSION

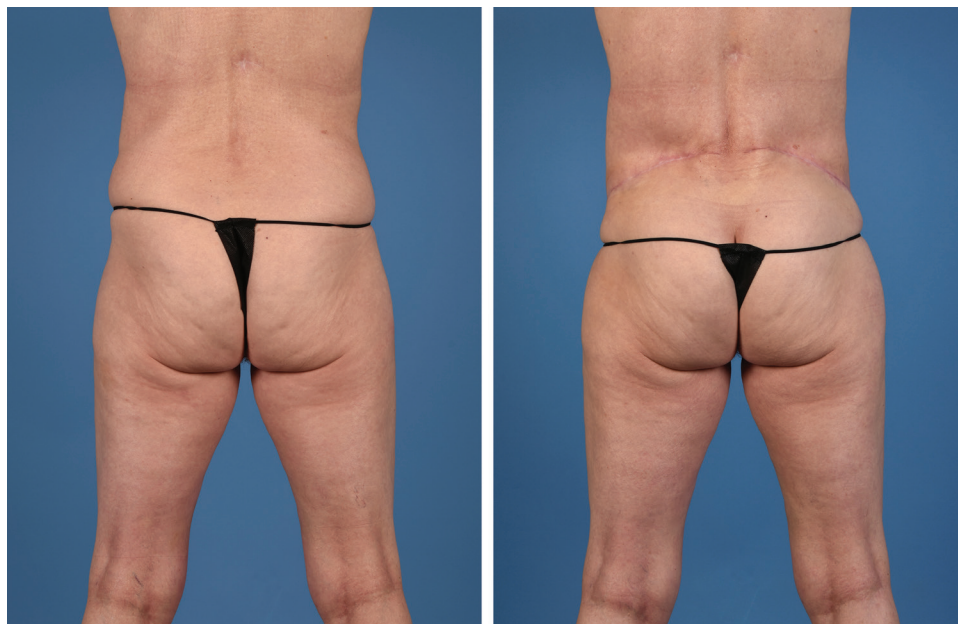
The LAP flap has become an important part of our armamentarium for breast reconstruction, but historically, there are 2 significant drawbacks to this flap. The first, and likely unavoidable, obstacle is that there is a required position change. While the flap can be harvested in lateral decubitus or prone position, it still requires a repositioning into supine position for microsurgery and optimal inset. This has been one of the reasons we have typically favored the PAP flap as our secondary option for autologous breast reconstruction in the past.

The second hurdle for reconstruction with LAP flaps is the typical staged approach for bilateral breast reconstruction. This increases the number of operations and the time to completion for patients undergoing bilateral breast reconstruction with LAP flaps. This appropriately conservative approach is secondary to the obvious concern over 2 simultaneously harvested, and thus, ischemic flaps.

Here we present our results using a carefully coordinated approach to simultaneously performing bilateral LAP flaps in a single surgical stage. For optimal results,



**Fig. 7.** Sixty-two-year-old woman following bilateral LAP flaps. Posterior oblique view presented.

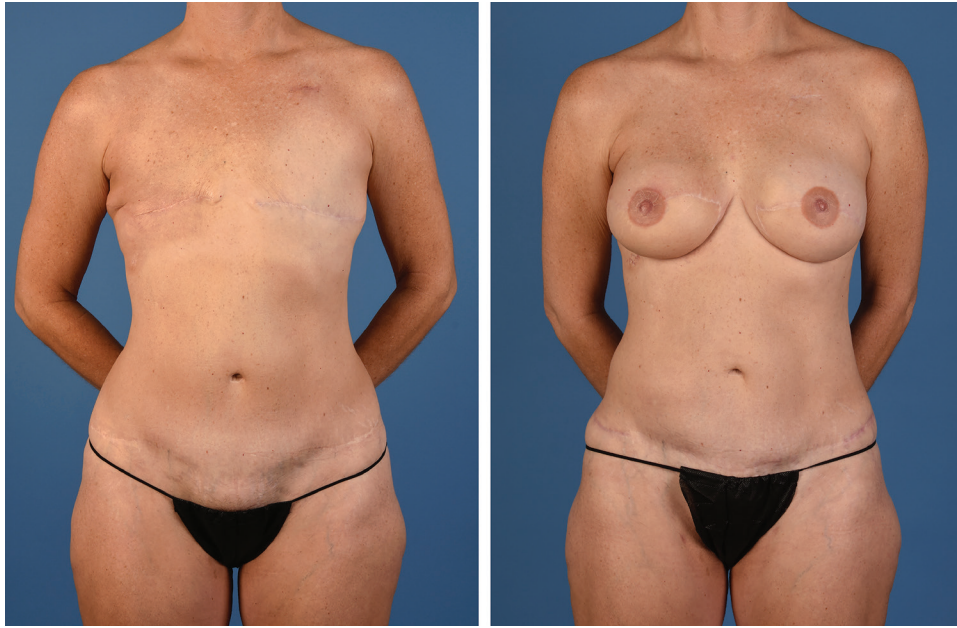

**Fig. 8.** Sixty-two-year-old woman following bilateral LAP flaps. Posterior view presented.

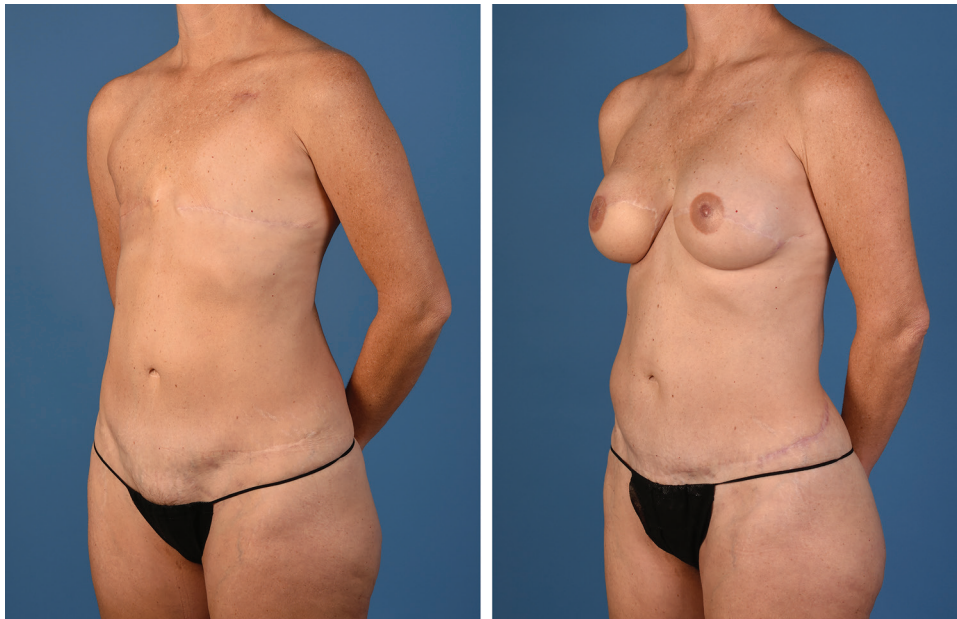
it is critical to utilize a co-surgery team<sup>8</sup> with excellent operating room staff who understands the process. The authors have focused on process analysis<sup>9</sup> and routinely strive to improve efficiency, outcomes, and satisfaction. This experience with process analysis has bettered our ability to orchestrate more complicated procedures, with simultaneous steps being performed safely and efficiently.

Interestingly, in this patient series, we had a relatively high rate of intraoperative revision (16.7%). While this is in-line with other reports on unilateral LAP flaps (17%–22%),<sup>3,10</sup> it is higher than most other reports for alternative

flap options: 3.4%,<sup>11</sup> 7.7%,<sup>12</sup> 8.3%,<sup>13</sup> 17%, and 27%.<sup>14</sup> This rate is significantly higher than our intraoperative revision rate with other flaps (10% total, 9.2% arterial, and 2.4% venous) ( $P < 0.05$ ). We hypothesize that this is possibly a result of the prolonged ischemia time of both the LAP flap (average 90.3 minutes in comparison to 46 minutes for DIEP flaps,  $P < 0.01$ ) and the composite graft, which is even longer ( $>2$  hours).<sup>15</sup> Our observation is that it takes longer for the vessel to return to pulsatile flow than other flap pedicles, and it is possible that this spasmodic phase lends to increased revision rates. Additionally, as with any



**Fig. 9.** Forty-nine-year-old woman presented for delayed bilateral breast reconstruction following bilateral mastectomies without reconstruction. She was treated with adjuvant radiation to the right breast. She was reconstructed with simultaneous bilateral LAP flaps. Anterior view presented.



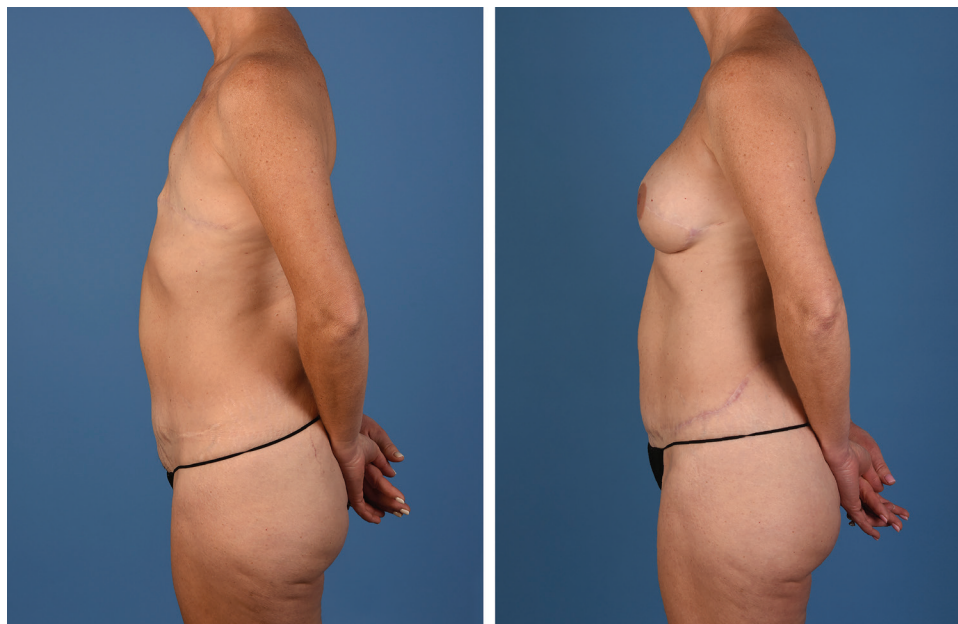
**Fig. 10.** Forty-nine-year-old woman following bilateral LAP flaps. Anterior oblique view presented.

new procedure, there is a learning curve and, admittedly, some of these revisions did not have thrombosis but likely were related to a tight fascia cuff that can accompany the LAP pedicle. This fascia must be released to avoid significant vasospasm.

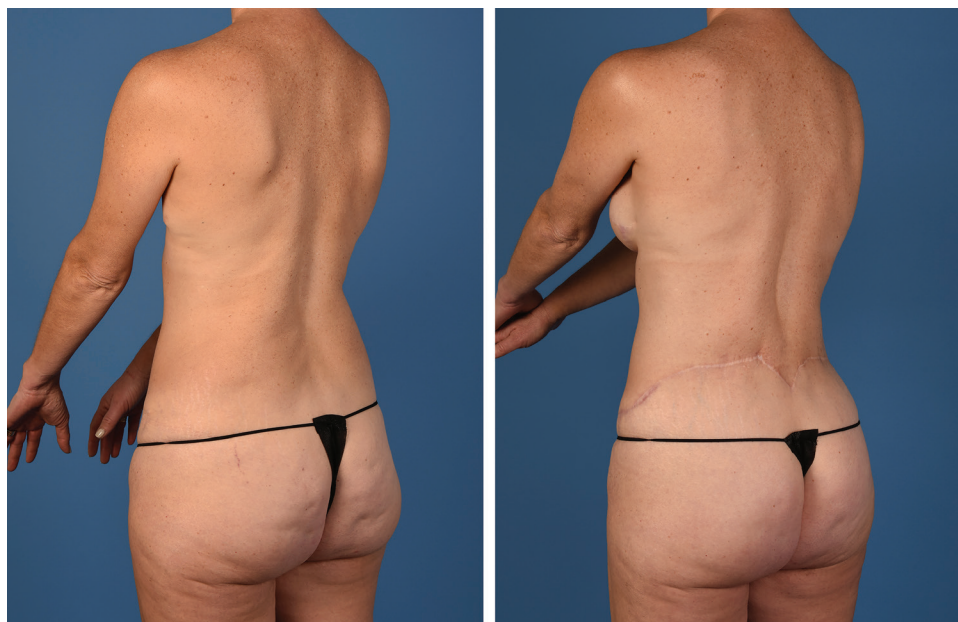There are 3 main maneuvers we perform in effort to limit this ischemia time, beginning with partial back closure before harvest of either LAP flap. Second, we

routinely have additional staff to help expedite the repositioning and the counting required with donor site closure. Microsurgery is routinely performed simultaneously so that once the patient is ready, a flap is connected to the mammary vessels.

Ischemia time has been shown to increase fat necrosis.<sup>16</sup> In our early experience with the LAP flap, we have found that it is a robust and forgiving flap, unlike the superficial



**Fig. 11.** Forty-nine-year-old woman following bilateral LAP flaps. Lateral view presented.



**Fig. 12.** Forty-nine-year-old woman following bilateral LAP flaps. Posterior oblique view presented.

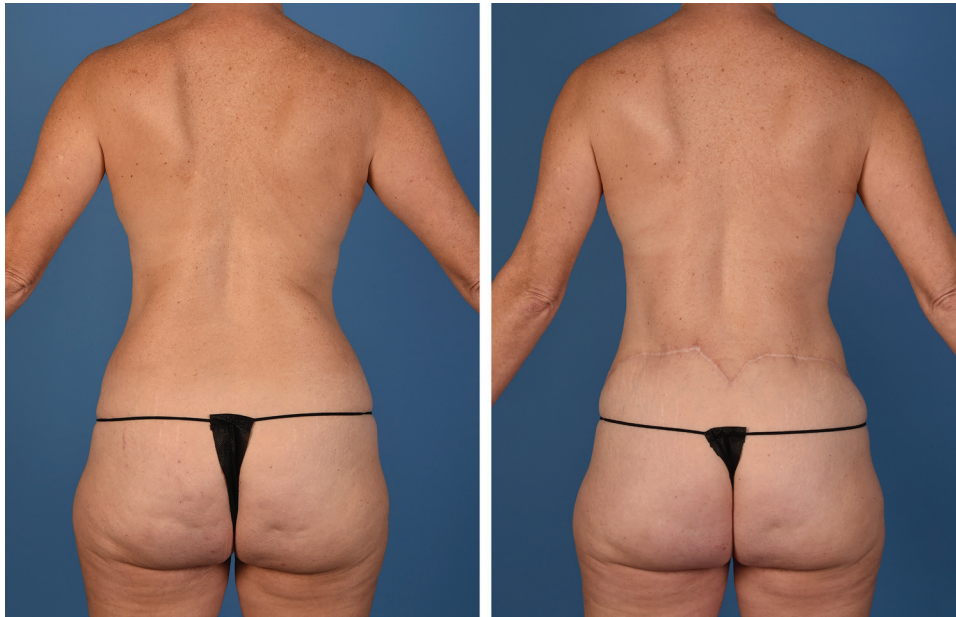inferior epigastric artery flap. We have had no observed fat necrosis in these patients despite the extended ischemia time. Complications from this flap and donor site are relatively minimal. We have experienced a higher rate of seroma, and back drains tend to stay in longer than in more traditional donor sites. In effort to lower this rate, we have started gentle postoperative compression on the donor site.

Others have commented on the benefits of the LAP flap when it comes to breast shape.<sup>3</sup> We agree that the flap design and the ability to add beveled fat mimics the

natural breast shape (Fig. 4–8). Patients can achieve excellent results with minimal inseting (Fig. 9–13).

### CONCLUSIONS

The LAP flap is an innovative, yet technically challenging, choice for autologous breast reconstruction. In our experience, simultaneous bilateral breast reconstruction using LAP flaps can be safely performed in a single surgical stage; however, we recommend caution and a coordinated team approach. We suggest a co-surgery model with a well-trained operative team to achieve



**Fig. 13.** Forty-nine-year-old woman following bilateral LAP flaps. Posterior view presented.

**Table 1. Patient and Flap Characteristics**

Patient	BMI	Timing	Flap Weight		Pedicle Length		Graft Length		Ischemia Time		Revision		Operative Time
			Left	Right	Left	Right	Left	Right	Left	Right	Left	Right	
1	21.9	Simultaneous	430	426	4	4	6.5	10	80	90	No	No	532
2*	25.8	Simultaneous	668	641	4	4	6.5	6.5	82	96	No	No	476
3	30.5	Simultaneous	660	600	4	4	6	6.5	123	91	No	Yes	471
4†	27.7	Simultaneous	530	640	4	4	6	6	92	78	No	No	566
5	22.8	Simultaneous	450	510	4	4	6	6	78	86	Yes	No	490
6†	23.5	Simultaneous	680	540	2	3	6	6	55	88	No	No	495
7	33.1	Simultaneous	650	520	6	6	6	6	40	226	No	No	615
8	23.2	Simultaneous	550	570	4	3	5	6	106	94	No	No	430
9	26.0	Simultaneous	680	690	4	4	4	5	91	53	No	No	610
10	26.4	Simultaneous	930	930	4	4	8	8	103	83	Yes	Yes	480
11	21.1	Simultaneous	750	660	4	4	6	7	96	67	Yes	No	454
12	32.3	Simultaneous	670	740	2	3	8	6	72	132	No	No	497
13†	28.4	Simultaneous	580	520	3	5	8	6	96	68	No	No	450
14	37.4	Simultaneous	1110	890	4	8	6	5	55	106	No	No	415
15	22.9	Simultaneous	680	710	4	4	6	6	85	128	No	No	660
Average	26.9			651		4		6		90.3		5	509
SD	4.7			160.0		1.2		1.2		33.5		16.7%	73

\*Immediate reconstruction.

†Stacked 4-flap procedure.

BMI, body mass index.

efficiency and success. With simultaneous bilateral LAP flaps, there is an inherent prolonged ischemia time and, thus, an increased possibility for vasospasm and intraoperative revisions. Ultimately, in centers of excellence for autologous breast reconstruction, simultaneously performed bilateral LAP flaps can be safe and be performed with high success rates.

*Nicholas T. Haddock, MD*

Department of Plastic Surgery  
 University of Texas Southwestern Medical Center  
 1800 Inwood Road  
 Dallas, TX 75390  
 E-mail: [Nicholas.Haddock@utsouthwestern.edu](mailto:Nicholas.Haddock@utsouthwestern.edu)

**REFERENCES**

1. de Weerd L, Elvenes OP, Strandenes E, et al. Autologous breast reconstruction with a free lumbar artery perforator flap. *Br J Plast Surg.* 2003;56:180–183.
2. Haddock NT, Gassman A, Cho MJ, et al. 101 consecutive profunda artery perforator flaps in breast reconstruction: lessons learned with our early experience. *Plast Reconstr Surg.* 2017;140:229–239.
3. Opsomer D, Stillaert F, Blondeel P, et al. The lumbar artery perforator flap in autologous breast reconstruction: initial experience with 100 cases. *Plast Reconstr Surg.* 2018;142:1e–8e.
4. Hamdi M, Craggs B, Brussaard C, et al. Lumbar artery perforator flap: an anatomical study using multidetector computed tomographic scan and surgical pearls for breast reconstruction. *Plast Reconstr Surg.* 2016;138:343–352.



5. Bissell MB, Greenspun DT, Levine J, et al. The lumbar artery perforator flap: 3-dimensional anatomical study and clinical applications. *Ann Plast Surg.* 2016;77:469–476.
6. Sommeling CE, Colebunders B, Pardon HE, et al. Lumbar artery perforators: an anatomical study based on computed tomographic angiography imaging. *Acta Chir Belg.* 2017;117:223–226.
7. Haddock NT, Dumestre D, Teotia SS. Lumbar artery perforator flap. *Plast Reconstr Surg Glob Open.* 2020. doi: 10.1097/GOX.0000000000002680 [Epub ahead of print].
8. Haddock NT, Kayfan S, Pezeshk RA, et al. Co-surgeons in breast reconstructive microsurgery: what do they bring to the table? *Microsurgery.* 2018;38:14–20.
9. Haddock NT, Teotia SS. Deconstructing the reconstruction: evaluation of process and efficiency in deep inferior epigastric perforator flaps. *Plast Reconstr Surg.* 2020;145:717e–724e.
10. Peters KT, Blondeel PN, Lobo F, et al. Early experience with the free lumbar artery perforator flap for breast reconstruction. *J Plast Reconstr Aesthet Surg.* 2015;68:1112–1119.
11. Pannucci CJ, Basta MN, Kovach SJ, et al. Loupes-Only microsurgery is a safe alternative to the operating microscope: an analysis of 1,649 consecutive free flap breast reconstructions. *J Reconstr Microsurg.* 2015;31:636–642.
12. Riot S, Herlin C, Mojallal A, et al. A systematic review and meta-analysis of double venous anastomosis in free flaps. *Plast Reconstr Surg.* 2015;136:1299–1311.
13. Shenaq SM, Klebuc MJ, Vargo D. Free-tissue transfer with the aid of loupe magnification: experience with 251 procedures. *Plast Reconstr Surg.* 1995;95:261–269.
14. Ehanire T, Singhal D, Mast B, et al. Safety of microsurgery under loupes versus microscope: a head-to-head comparison of 2 surgeons with similar experiences. *Ann Plast Surg.* 2018;80(6S Suppl 6):S340–S342.
15. Marre D, Hontanilla B. Increments in ischaemia time induces microvascular complications in the DIEP flap for breast reconstruction. *J Plast Reconstr Aesthet Surg.* 2013;66:80–86.
16. Lee KT, Lee JE, Nam SJ, et al. Ischaemic time and fat necrosis in breast reconstruction with a free deep inferior epigastric perforator flap. *J Plast Reconstr Aesthet Surg.* 2013;66:174–181.