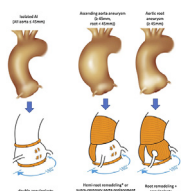


Dr Lansac has a financial relationship with Coroneo, Inc. All other authors reported no conflicts of interest.

The *Journal* policy requires editors and reviewers to disclose conflicts of interest and to decline handling or reviewing manuscripts for which they may have a conflict of interest. The editors and reviewers of this article have no conflicts of interest.



## REPLY: WHAT IS A GOOD ANNULOPLASTY FOR BICUSPID AORTIC VALVE REPAIR?

### Reply to the Editor:

We appreciate the interest in our recently published article<sup>1</sup> and welcome the evolving consensus about the importance of the annulus, sinotubular junction (STJ), and commissural orientation in bicuspid aortic valve (BAV) repair from multiple schools of aortic valve repair. As Jasinski and colleagues<sup>2</sup> published in their own series, circumferential annuloplasty (external ring, reimplantation tube, or suture) improves BAV repair stability and long-term outcomes. A symmetrical design of BAV repair with restoration of annulus-to-STJ ratio can be easily tailored to aorta phenotype: for root aneurysms, root remodeling repair utilizing 2 symmetrical sinuses with external subvalvular annuloplasty; for supracoronary aorta aneurysms or borderline dilated roots (40-45 mm) with right-left fusion, a hemi-remodeling root repair with sinus plication and external subvalvular annuloplasty; and for isolated aortic insufficiency (normal-sized aorta), a double subvalvular and STJ external ring annuloplasty with sinus plication. In all these cases, the annulus-to-STJ ratio and commissural orientations are addressed, as well as cusp repair techniques, according to the cusp lesions. Similarly, the reimplantation technique is an excellent way to treat both annular and STJ dilation.<sup>3</sup> However, the systematic use of the reimplantation technique in supracoronary aorta aneurysms or isolated aortic insufficiency repair (normal-sized aorta), which made up 53.8% of the BAV repair cases in our series, is questionable because it implies an unnecessary root replacement with coronary reimplantation with its inherent risks and significantly longer ischemic time.

Contrary to an external expansible annuloplasty ring or tube graft, which ensures a smooth repositioning of the commissures toward a symmetrical design without

direct interference with the leaflets, we remain cautious about using the internal HAART ring (BioStable Science & Engineering, Inc) to change commissural orientation to a symmetrical one, due to potentially placing direct tension along the leaflet insertion line by effect of the stiches surrounding the annulus below (rigid ring covered with polyethylene terephthalate) and above (polytetrafluoroethylene pledgets). Long-term leaflet pliability may be influenced by the sclerotic scarring process, with foreign material sandwiching the cusp insertion line. Internal placement of a rigid ring into an expansible root places all of the tension on the fixation suture with its inherent risk of dehiscence, as previously documented.<sup>4</sup> Although dilatation at the level of the annulus is addressed, it does not address the STJ or orientation at the tip of the commissures, both identified as risk factors of reoperation,<sup>1,5</sup> because the posts only go halfway up the interleaflet triangle, which is particularly a concern for isolated BAV repair. Long-term data with detailed analysis of outcomes for different BAV aorta phenotypes would be helpful.

These considerations enhance our need for a truly global evaluation of aortic valve repair, with patient-specific outcomes irrespective of the techniques used. This is the goal of the Heart Valve Society's AVIATOR Registry (<https://heartvalvesociety.org/Aortic/Registry/>), and we strongly encourage all teams to include their consecutive patients with aortic valve and root repair or replacement in this aortic database.

Nathanael Shraer, MD<sup>a</sup>

Pouya Youssefi, MD, PhD<sup>b</sup>

Emmanuel Lansac, MD, PhD<sup>c</sup>

<sup>a</sup>Department of Pediatric Cardiac Surgery  
Necker AHP Hospital  
Paris, France

<sup>b</sup>Department of Cardiac Surgery  
Royal Brompton and Harefield Hospital  
London, United Kingdom

<sup>c</sup>Department of Cardiovascular and Thoracic Surgery  
Pitié-Salpêtrière AHP Hospital  
Paris, France

## References

1. Shraer N, Youssefi P, Zacek P, Debauchez M, Leprince P, Raïsky O, et al. Bicuspid valve repair outcomes are improved with reduction and stabilization of sinotubular junction and annulus with external annuloplasty. *J Thorac Cardiovasc Surg.* 2022;1-14.
2. Jasinski MJ, Kosiorowska K, Gocol R, Jasinski J, Nowicki R, Bielicki G, et al. Bicuspid aortic valve repair: outcomes after 17 years of experience. *Eur J Cardiothorac Surg.* 2021;60:1053-61.
3. de Kerchove L, Boodhwani M, Glineur D, Vandyck M, Vanoverschelde J-L, Noirhomme P, et al. Valve sparing-root replacement with the reimplantation technique to increase the durability of bicuspid aortic valve repair. *J Thorac Cardiovasc Surg.* 2011;142:1430-8.

4. Mazzitelli D, Pfeiffer S, Rankin JS, Fischlein T, Choi Y-H, Wahlers T, et al. A regulated trial of bicuspid aortic valve repair supported by geometric ring annuloplasty. *Ann Thorac Surg*. 2015;99:2010-6.
5. Aicher D, Kuniyama T, Abou Issa O, Brittner B, Gräber S, Schäfers H-J. Valve configuration determines long-term results after repair of the bicuspid aortic valve. *Circulation*. 2011;123:178-85.

<https://doi.org/10.1016/j.xjon.2023.02.003>