

# Imaging as an alternate diagnostic modality in a presumptive case of abdominopelvic TB in a COVID-19 patient

Niranjana Subramanian , Haritha Sagili , Parvathi Naik, Jayalakshmi Durairaj

Obstetrics and Gynaecology,  
Jawaharlal Institute of  
Postgraduate Medical  
Education, Puducherry, India

## Correspondence to

Dr Niranjana Subramanian;  
niranjana3093@gmail.com

Accepted 11 February 2021

## SUMMARY

A 30-year-old, multiparous widow, with postpolio residual paralysis, presented with complaints of dull aching abdominal pain for 15 days. Ultrasound showed a mixed echogenic right adnexal mass with free fluid in the pelvis and abdomen. CT abdomen and pelvis revealed partially defined peripherally enhancing collection in lower abdomen and right adnexa suggestive of tubo-ovarian abscess. There was mild ileal wall thickening and few enlarged mesenteric lymph nodes. Ascitic fluid did not show acid fast bacilli and cultures were sterile. Extensive diagnostic laboratory work was done which was inconclusive. Diagnostic laparoscopy could not be performed due to non-availability of elective operation theatre in the COVID-19 pandemic. Presumptive extrapulmonary tuberculosis was clinically and radiologically diagnosed. She was started on daily anti tuberculosis treatment. This case shows us the importance of imaging as a diagnostic tool and as an alternative for laparoscopy in COVID-19 pandemic to diagnose abdomino-pelvic tuberculosis.

## BACKGROUND

Tuberculosis (TB) accounts for the highest rate of mortality by any infectious disease causing 1.5 million deaths in 2018 alone. India registered the second largest increase in new cases in 2018.<sup>1</sup> Pulmonary TB remains the most common presentation. Among the cases of extrapulmonary TB (EPTB), female genital TB (FGTB) is the second most common presentation. The incidence of FGTB is increasing among young women globally. Traditionally, TB is diagnosed by the identification of acid fast bacilli (AFB) or caseating granulomas. Imaging features are not pathognomonic in cases of abdominopelvic TB but may raise the suspicion of this chronic condition in the background of demographic origin of the patient, clinical history and examination. Ultrasound features suggestive of FGTB includes a thin endometrium, diffuse/variable thickening, endometrial fluid collection, endometrial and subendometrial calcification, vertical course of interstitial extent of tube, tubal fluid and free/loculated fluid in peritoneum, enlarged ovaries and follicles with echogenic rims.<sup>2</sup> CT scan can suggest a diagnosis of abdominal TB based on ascites, necrotic adenopathy short segment strictures and ileal wall necrosis.<sup>3</sup> Although several cases of FGTB are associated with abdominal TB, specific features of FGTB on a CT scan include pelvic mass, unilateral or bilateral adnexal mass(which maybe

solid/mixed echogenicity/cystic), tuboovarian abscess, ascites, thickening of peritoneum (which maybe nodulous thickening or smooth), adhesions and lymphadenopathy (which maybe necrotic).<sup>4</sup>

Laparoscopy plays an important role for the diagnosis of FGTB. Features suggestive of FGTB on laparoscopy include—tubercles on peritoneum, tubo-ovarian mass, caseous nodules, encysted ascitis, pelvic adhesions, hydrosalpinx, tobacco pouch appearance of tube and beaded tubes.<sup>5</sup>

## CASE PRESENTATION

A 30-year-old, widow, para 2 living 1, previous 2 caesarean sections with postpolio residual paralysis presented with dull aching abdominal pain for 15 days and breathlessness for 1 day. There was no history of fever, vomiting, altered bowel habits, loss of appetite/ body weight, jaundice, haemoptysis, cough with sputum or burning micturition. Her menstrual cycles were regular with normal flow. On examination, she was afebrile, no pallor/icterus and cardiovascular/respiratory system examination were normal. Abdomen was distended, felt doughy with minimal tenderness over periumbilical and right iliac regions. Vaginal examination revealed a healthy cervix and vagina, uterus was normal size, and right adnexal tender mass measuring 5×4 cm was felt. Ultrasound showed a 5×4 cm mixed echogenic right adnexal mass with free fluid in the pelvis, periumbilical, left lumbar regions and aspiration revealed straw coloured fluid. Left ovary was normal. Tubo-ovarian abscess with chronic pelvic inflammatory disease was suspected and patient was empirically started on antibiotics and analgesics with which the pain subsided.

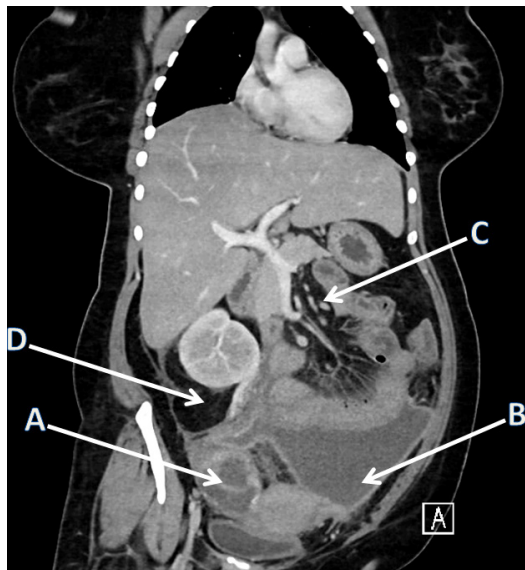
## INVESTIGATIONS

COVID-19 testing was done which turned out to be positive. Chest X-ray was carried out, which was normal. Ascitic fluid analysis had a high lactate dehydrogenase (LDH)—3737 U/L, glucose <10 mg%, total protein 5.3g/dL and albumin 2 g/dL. Serum ascites albumin gradient was 0.6, suggestive of exudate. Ascitic fluid sent for AFB staining was negative and culture in mycobacterium growth indicator tube were sterile. Tumour markers including carbohydrate antigen, carcinoembryonic antigen, human chorionic gonadotropin, LDH and alpha fetoprotein were negative. Contrast enhanced computed tomography (CECT) abdomen and pelvis revealed partially defined peripherally enhancing collection in lower abdomen measuring about 8×13×7.5 cm



© BMJ Publishing Group Limited 2021. No commercial re-use. See rights and permissions. Published by BMJ.

**To cite:** Subramanian N, Sagili H, Naik P, et al. *BMJ Case Rep* 2021;**14**:e241882. doi:10.1136/bcr-2021-241882

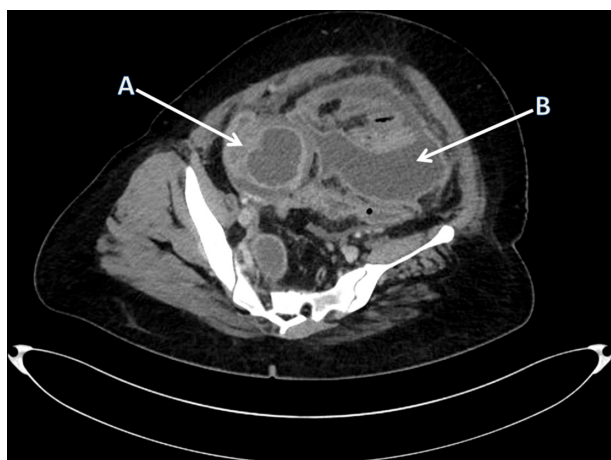

**Figure 1** CT image (coronal section) showing A: right tubo-ovarian mass, B: pelvic collection, C: mesenteric lymph nodes and D: abdominal free fluid.

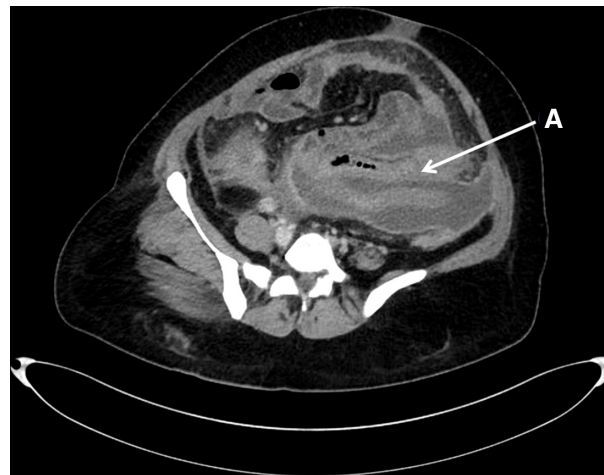(figures 1 and 2). Right adnexa showed peripherally enhancing lesion loculated collection 5 × 4 cm suggestive of tubo-ovarian abscess and left ovary was normal (figure 1). There was mild ileal wall thickening (figure 3), omental stranding, few enlarged mesenteric lymph nodes (figure 4) and appendix was not separately visualised. There was palisading of bowel in the umbilical region and chronic peritoneal thickening. All findings on CT were indicative of chronic pathology probably abdominopelvic TB. Mantoux was negative, erythrocyte sedimentation rate was 33 mm/hour and sputum for AFB was negative. Diagnostic laparoscopy for biopsy was deferred due to non-availability of elective operation theatre in the COVID-19 pandemic.

#### DIFFERENTIAL DIAGNOSIS

As there was a high clinical suspicion of TB, pulmonary medicine and TB expert opinion was sought. Presumptive EPTB was clinically and radiologically diagnosed and she was started on Anti Tuberculosis treatment (ATT) as per revised national TB



**Figure 2** CT scan (transverse section) showing, A: right tubo-ovarian mass and B: pelvic collection.



**Figure 3** CT scan (transverse section) showing A: bowel oedema

control programme (RNTCP) guidelines based on body weight for 6 months.

#### TREATMENT

Presumptive EPTB was clinically and radiologically diagnosed and she was started on ATT as per RNTCP guidelines based on body weight for 6 months. She had an uneventful COVID-19 infection and was discharged home on 11th day following admission and was advised repeat imaging after 8 weeks.

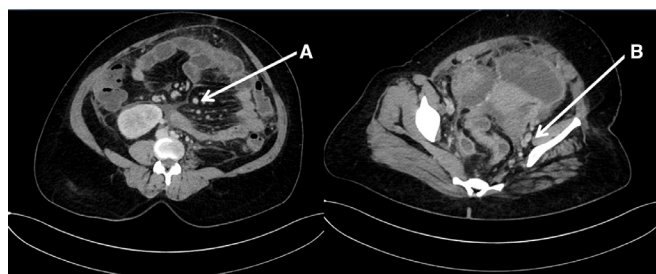
#### OUTCOME AND FOLLOW-UP

On a follow-up call after 2 weeks, the patient reported improvement in symptoms. After 2 months of starting ATT, the patient was reviewed and an ultrasound was done which showed resolution in tubo-ovarian abscess and ascites.

#### DISCUSSION

The incidence of FGTB is increasing among young women globally.<sup>2</sup> FGTB spreads from the lungs or other organs by haematogenous, lymphatic route or direct spread from adjacent organs. It may be sexually transmitted from a male partner with active genital TB. Further emerging evidence suggests that infection with COVID-19 might worsen the clinical outcomes of TB by impeding host immune response.<sup>6</sup>

The mean age of developing FGTB is younger in Asia than in western countries due to early age of marriage and child birth. FGTB may present with infertility, menstrual problems, unexplained abdominal pain or pelvic mass. Patients have systemic symptoms of fever, weight loss and night sweats. Ectopic pregnancy and cervical/vulval lesions are rare presenting features. A postmenopausal woman presenting with vaginal bleeding should



**Figure 4** CT scan (transverse section) showing A: mesenteric lymph nodes and B: pelvic lymph nodes.

also be evaluated. Rare presentations of FGTB include a cervical growth mimicking carcinoma cervix, vulval and vaginal ulcers. Our patient presented with an adnexal mass suggestive of tubo-ovarian abscess.

Index TB guidelines for EPTB released in 2017 advise to start antitubercular treatment only on confirmation with microbiology, histopathology or laparoscopic appearance suggestive of TB.<sup>3</sup> In our patient with a background of negative microbiological evidence for AFB however, clinical examination and CT abdomen and pelvis were strongly suggestive of TB. Given the patient demographic profile a presumptive diagnosis of abdominopelvic TB was taken into consideration and she was started on daily ATT as per RNTCP guidelines based on body weight for 6 months with which there was clinical and symptomatic improvement.

### Learning points

- ▶ Collecting samples for microbiology/histopathology or performing laparoscopy for confirmation of female genital tuberculosis is challenging in the COVID-19 pandemic.
- ▶ Non-invasive imaging studies can help in arriving at a diagnosis when used appropriately.
- ▶ Features of female genital tuberculosis and pelvic tuberculosis on imaging need to be extensively studied and standardised to eliminate the need for diagnostic laparoscopy.

**Contributors** Concept and design of report—by HS. Drafting the article—by NS. Providing critical revisions and improvements—PN. Final approval of article—JD.

**Funding** The authors have not declared a specific grant for this research from any funding agency in the public, commercial or not-for-profit sectors.

**Competing interests** None declared.

**Patient consent for publication** Obtained.

**Provenance and peer review** Not commissioned; externally peer reviewed.

This article is made freely available for use in accordance with BMJ's website terms and conditions for the duration of the covid-19 pandemic or until otherwise determined by BMJ. You may use, download and print the article for any lawful, non-commercial purpose (including text and data mining) provided that all copyright notices and trade marks are retained.

### ORCID iDs

Niranjana Subramanian <http://orcid.org/0000-0002-4400-1588>

Haritha Sagili <http://orcid.org/0000-0002-1372-7634>

### REFERENCES

- 1 Sharma JB, Sharma E, Sharma S, *et al*. Female genital tuberculosis: revisited. *Indian J Med Res* 2018;148:71.
- 2 Khurana A, Sahi G. OC14.04: ultrasound in female genital tuberculosis: a retrospective series. *Ultrasound Obstet Gynecol* 2013;42:28
- 3 Sharma SK, Ryan H, Khaparde S, *et al*. Index-TB guidelines: guidelines on extrapulmonary tuberculosis for India. *Indian J Med Res* 2017;145:448–63.
- 4 Sah SK, Shi X, Du S, *et al*. Ct findings and analysis for misdiagnosis of female pelvic tuberculosis. *Radiol Infect Dis* 2017;4:19–25.
- 5 Sharma JB, Roy KK, Pushparaj M, *et al*. Laparoscopic findings in female genital tuberculosis. *Arch Gynecol Obstet* 2008;278:359–64.
- 6 Crisan-Dabija R, Grigorescu C, Pavel C-A, *et al*. Tuberculosis and COVID-19: lessons from the past viral outbreaks and possible future outcomes. *Can Respir J* 2020;2020:1–10.

Copyright 2021 BMJ Publishing Group. All rights reserved. For permission to reuse any of this content visit <https://www.bmj.com/company/products-services/rights-and-licensing/permissions/>  
BMJ Case Report Fellows may re-use this article for personal use and teaching without any further permission.

Become a Fellow of BMJ Case Reports today and you can:

- ▶ Submit as many cases as you like
- ▶ Enjoy fast sympathetic peer review and rapid publication of accepted articles
- ▶ Access all the published articles
- ▶ Re-use any of the published material for personal use and teaching without further permission

### Customer Service

If you have any further queries about your subscription, please contact our customer services team on +44 (0) 207111 1105 or via email at [support@bmj.com](mailto:support@bmj.com).

Visit [casereports.bmj.com](http://casereports.bmj.com) for more articles like this and to become a Fellow