

# The safety and feasibility of guidezilla catheter in complex coronary interventions and an observational study

Jiaying Ma, MD, Lei Hou, MD, Juying Qian, MD, Lei Ge, MD, Feng Zhang, MD, Shufu Chang, MD, Rende Xu, MD, Qing Qin, MD, Junbo Ge, MD\*

## Abstract

The monorail Guidezilla™ guide extension catheter was designed to provide additional backup and facilitate device delivery in percutaneous coronary intervention (PCI) for complex coronary anatomy such as chronic total occlusion (CTO), extreme vessel tortuosity, diseased bypass grafts, and anomalous coronary arteries, among others.

The present retrospective, single-center study included 188 consecutive patients who underwent PCI using the Guidezilla catheter from March 2015 to August 2016. Study outcomes were rates of target lesion crossing success, procedural success, and complications.

The Guidezilla catheter was used most commonly in PCI of CTOs (45%) and heavy proximal calcification (37%), followed by tortuosity (10%), previously deployed proximal stents (4%), and coronary artery anomaly (4%). The right coronary artery (48%) was most commonly intervened followed by the left ascending (35%) and left circumflex (17%) arteries. Rates of target lesion crossing success and procedural success were both 99%, with one device-related periprocedural complication, namely proximal vessel dissection secondary to deep insertion which was successfully treated with stent implantation. Ninety percent of PCI were performed and completed successfully by radial access.

In a single center with experienced operators, the use of the Guidezilla guide extension catheter in PCI of complex coronary anatomy performed mostly via radial artery access appeared safe and efficacious, and greatly facilitated device delivery.

**Abbreviations:** CTO = chronic total occlusion, PCI = percutaneous coronary intervention, RCA = right coronary artery.

**Keywords:** chronic total occlusion, device delivery, percutaneous coronary intervention

## 1. Introduction

Complex coronary anatomy including extreme vessel tortuosity, chronic total occlusions (CTOs), or calcification often renders percutaneous coronary intervention (PCI) challenging and time consuming, with procedural success warranting excellent device support via larger size guiding catheters, buddy wires, strong-support wires, anchoring balloons, and deep insertion of the guiding catheter<sup>[1]</sup> commonly using a mother-child catheter.<sup>[2,3]</sup>

The Guidezilla™ guide extension catheter was designed to facilitate complex PCI by efficiently delivering interventional devices, including balloons and stents, when extra backup

support is required.<sup>[4]</sup> As a 5F child catheter used with a 6F mother guide catheter, Guidezilla offers support comparable to an 8F ordinary guide catheter thereby allowing to complete most complex cases via radial artery access. The present real-world study assessed effectiveness of the use of the Guidezilla catheter in PCI of complex lesions performed mainly via radial access.

## 2. Methods

### 2.1. Study design

After approval by the Ethics Committee at Zhongshan Hospital, Fudan University, China, the present study retrospectively analyzed data from 188 consecutive PCI cases using the Guidezilla™ guide extension catheter (Boston Scientific, Marlborough, MA) at said hospital from March 2015 to August 2016 by 5 experienced operators each with yearly PCI caseloads of over 500. Patient clinical characteristics, target lesion characteristics, indications for the use of the Guidezilla catheter (namely, coronary artery origin anomalies, heavy tortuosity, heavy calcification, proximal stent, and CTO), and rate of successful target lesion crossing (defined as successful balloon or stent crossing over the target lesion) and of procedural success (defined as successful stents implantation in targeted lesion area) were reviewed and analyzed. If multiple indications were present, the key one leading to Guidezilla catheter use was listed as primary. The Guidezilla catheter was used mainly when the stent could not cross the lesions even after high pressure balloon predilatation without the need to change the original guiding catheter, and occasionally to pick up the retrograde wire during CTO intervention.

Editor: Jacek Bil.

JM and LH are the first co-authors and contributed equally to this study.

Funding/support: This study was supported by the Emerging Frontier Project from the Shanghai Hospital Development Center (SHDC12014101).

The authors have no conflicts of interest to disclose.

Department of Cardiology, Zhongshan Hospital, Fudan University, Shanghai, China.

\* Correspondence: Junbo Ge, Department of Cardiology, Zhongshan Hospital, Fudan University, Shanghai, China (e-mail: ge.junbo@zs-hospital.sh.cn).

Copyright © 2017 the Author(s). Published by Wolters Kluwer Health, Inc. This is an open access article distributed under the terms of the Creative Commons Attribution-Non Commercial-No Derivatives License 4.0 (CCBY-NC-ND), where it is permissible to download and share the work provided it is properly cited. The work cannot be changed in any way or used commercially without permission from the journal.

Medicine (2017) 96:40(e8172)

Received: 23 March 2017 / Received in final form: 3 September 2017 /

Accepted: 5 September 2017

<http://dx.doi.org/10.1097/MD.00000000000008172>

**Table 1**  
**Patients clinical characteristics.**

Clinical characteristics	Numbers	Percentage
Mean age, y	65±10	
Sex (male)	153	81%
Diabetes	67	36%
Hypertension	127	68%
Hypercholesterolemia	58	31%
Smoking	49	26%
Previous coronary intervention	62	33%
Previous myocardial infarction	27	14%
Previous coronary artery bypass grafting	10	5%

**2.2. Statistical analysis**

Statistical analysis was performed using SPSS13.0 statistical software (SPSS Inc, Chicago, IL). Continuous variables are expressed as mean±standard deviation and were compared using the Student *t* test. Categorical variables are expressed as counts and percentages. *P*<.05 was considered statistically significant.

**3. Results**

Patient clinical and lesion characteristics are summarized in Tables 1 and 2, respectively. Thirty-eight percent of patients had undergone previous coronary revascularization by angioplasty, bypass grafting, or both, and 94% had complex type C lesions. As summarized in Fig. 1, CTOs accounted for 45% of indications for using the Guidezilla catheter, followed by heavy calcification (37%), tortuosity (10%), proximal stent (4%), and coronary origin anomalies (4%). The right coronary artery (RCA, 48%) was the most commonly intervened vessel followed by the left ascending artery (35%) and left circumflex artery (17%).

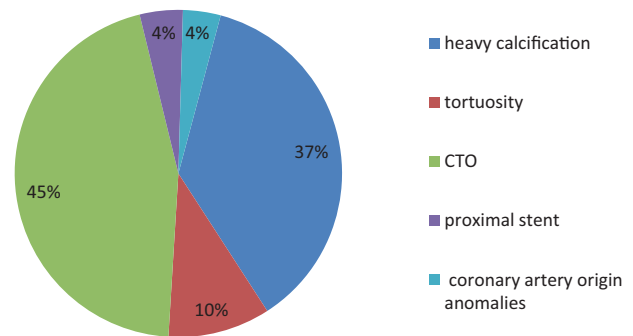
Most complex lesions (90%) were treated successfully via radial access with the Guidezilla catheter combined with 6 Fr mother-guide catheters (41% EBU, 25% SAL, 25% AL, and 9% JL); the other 10% of cases were via femoral access.

Rates of target lesion crossing success and procedural success were both 99%. The operators failed to manage microcatheters to cross a collateral artery in 2 CTO patients leading to target

**Table 2**  
**Target lesion characteristics.**

Target lesion characteristics	Number/percentage	
Lesion type	A	0/0%
	B	12/6%
	C	176/94%
Lesion length	≤20 mm	27/14%
	20–40 mm	51/27%
	>40 mm	110/59%
Target vessel	LAD	65/35%
	LCX	32/17%
	RCA	91/48%
Vessel diameter	<3.0 mm	49/26%
	3.0–4.0 mm	139/74%
Chronic total occlusion	LAD	26/30%
	LCX	10/12%
	RCA	49/58%

LAD=left ascending, LCX=left circumflex, RCA=right coronary artery.



**Figure 1.** Indications for Guidezilla use in complex coronary interventions.

lesion crossing failure. There was only 1 immediate periprocedural complication (proximal vessel dissection) caused by deep insertion of the Guidezilla catheter, which was successfully treated with stent implantation.

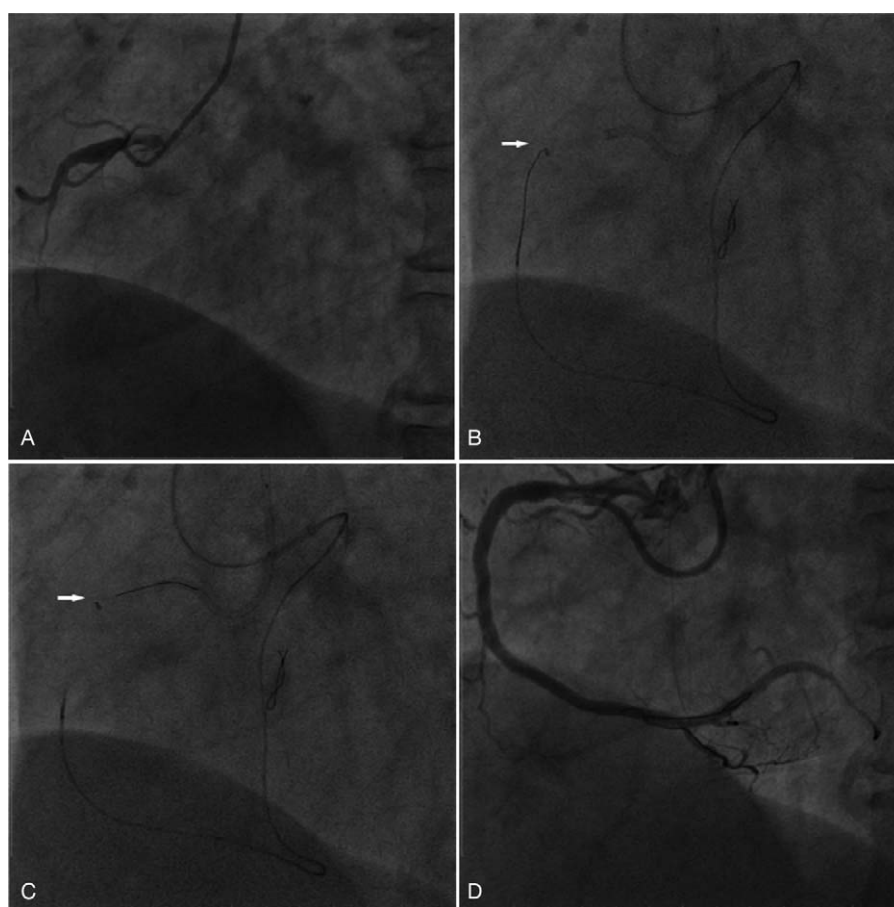
**4. Discussion**

The use of the Guidezilla guide extension catheter in complex PCI, which in the present single-center, observational study of 188 cases was mainly performed via radial artery access and predominantly for CTO and heavy calcification and in the RCA, appears safe with 1 immediate periprocedural complication, and efficacious with 99% target lesion crossing success and procedural success.

The transradial approach to coronary angiography, first reported in 1989, offers advantages over the traditional transfemoral approach including decreased incidence of access site complications, earlier ambulation, and improved patient comfort.<sup>[5–8]</sup> However, operators prefer the femoral access when dealing with complex coronary lesions (eg, CTO), which require more backup support and devices; also, the radial artery rarely can accommodate >6F catheters. The 5F monorail Guidezilla catheter was developed to provide additional backup and facilitate device delivery to cross target lesions in complex coronary interventions.<sup>[4,9,10]</sup> Combined with a 6F mother-catheter, Guidezilla can offer support comparable to an 8F ordinary guide catheter thereby allowing to complete most complex cases via radial access.

Previous studies documented safety and efficacy of the GuideLiner (Vascular Solutions, Minneapolis, MN) and Heart-rail II (Terumo Corp., Tokyo, Japan) catheters in complex coronary interventions.<sup>[11–14]</sup> Compared to the GuideLiner catheter, Guidezilla has larger inner diameter (1.42 vs 1.45 mm) and smaller outer diameter (1.70 vs 1.68 mm). In the study by Chan et al<sup>[15]</sup> of 54 consecutive cases, 58% were completed with a 5-in-6 catheter system and the rest with a 6-in-7 catheter system. In the present study of 188 PCI cases, 90% were completed with the 5-in-6 catheter system via radial access underscoring the excellent support provided by the Guidezilla catheter. However, PCI was performed by 5 experienced operators with yearly caseloads over 500; for less experienced operators, the use of larger size mother catheters or femoral artery access might be a better choice.

In CTO intervention, inability of balloon or stent to cross the occluded lesion accounts for about 10% of intervention failure.<sup>[16]</sup> Because the Guidezilla catheter can offer extra support for device advancement, its use is expected to increase the rate of



**Figure 2.** Illustration of the pick-up technique used in the retrograde approach. (A) Chronic occlusion in mid right coronary artery (RCA). (B) The retrograde guidewire reached the Guidezilla catheter tip (white arrow). (C) The retrograde guidewire entered into the antegrade catheter through the Guidezilla catheter (tip indicated by white arrow). (D) Final angiography result.

success of target lesion crossing in CTO intervention. In the present study, 58% of CTO cases were from RCA. Because in RCA CTO usual lack of suitable side branches for anchoring balloons render active support difficult, the greater support provided by the Guidezilla catheter allowed to efficiently deliver interventional devices to the target zone yielding a 98% procedural success rate among the 85 CTO cases. However, the operators failed to manage microcatheters to cross a collateral artery in 2 CTO patients leading to target lesion crossing failure.

Another application of the Guidezilla catheter in CTO interventions is the pick-up technique. Briefly, in the reverse controlled antegrade and retrograde subintimal tracking technique,<sup>[17,18]</sup> advancement of the Guidezilla catheter from the antegrade guide catheter shortens the distance between the re-entry site of the retrograde guidewire and the antegrade guiding catheter (Fig. 2), facilitating the advancement of the former into the latter thereby favoring procedural success.

Heavy calcification, another big challenge to the operator, increases the likelihood of procedural failure and complications in coronary intervention.<sup>[19,20]</sup> In the present study, 75 (37%) of 188 complex cases involved heavy calcification lesions and were completed successfully. Rotational atherectomy was used through radial artery access in 2 cases; the 1.25 and 1.5 mm burr can be used through the 6F catheter thereby easily achieving plaque modification in most cases.<sup>[21]</sup>

The 5 Fr Guidezilla catheter has disadvantages, such as its smaller inner diameter (1.45 mm) compared with larger guiding catheters. For example, a 2.0 mm monorail balloon and a Corsair catheter cannot be inserted together into a 5-in-6 Guidezilla catheter, and the microcatheter cannot be removed by using the trapping balloon method when the Guidezilla catheter is in place. In such a scenario, the operator should first remove the Guidezilla catheter and then use the trapping balloon method; because Guidezilla is a monorail catheter, it is very easy and fast to perform this procedure.

Caution is warranted not to twist the Guidezilla catheter during advancement over the guidewire because it might wind with the guidewire and injure the coronary artery, and to avoid forceful manipulation when inserting a 4.00 mm stent into the Guidezilla catheter because it may increase the risk of stent dislodgement.

## 5. Limitations

The findings of the present study are limited by its retrospective, single-center design with associated potential patient selection bias and influence by operator experience and interoperator technique variation. The study lacks a control group, which limits comparisons with alternate techniques. Larger, multicenter, randomized controlled studies are warranted.

## 6. Conclusions

In this single-center experience with experienced operators, the use of the Guidezilla catheter in PCI mainly via radial artery access for complex coronary anatomy, predominantly CTO, and heavy calcification appears effective and greatly facilitates device delivery.

## References

- [1] Di Mario C, Ramasami N. Techniques to enhance guide catheter support. *Catheter Cardiovasc Interv* 2008;72:505–12.
- [2] Ormiston JA, Dixon B, Webster MW, et al. 5 French guide catheters for percutaneous coronary intervention: a feasibility study in 100 consecutive patients. *Catheter Cardiovasc Interv* 2001;52:45–8.
- [3] Saeed B, Banerjee S, Brilakis ES. Percutaneous coronary intervention in tortuous coronary arteries: associated complications and strategies to improve success. *J Interv Cardiol* 2008;21:504–11.
- [4] Yew KL, Kang Z. Guidezilla guide extension catheter facilitated the delivery of long and bulky In.Pact Falcon drug-coated balloon for the treatment of chronic total occlusion lesion. *Int J Cardiol* 2015; 201:220–1.
- [5] Cox N, Resnic FS, Popma JJ, et al. Comparison of the risk of vascular complications associated with femoral and radial access coronary catheterization procedures in obese versus nonobese patients. *Am J Cardiol* 2004;94:1174–7.
- [6] Hildick-Smith DJ, Walsh JT, Lowe MD, et al. Coronary angiography in the fully anticoagulated patient: the transradial route is successful and safe. *Catheter Cardiovasc Interv* 2003;58:8–10.
- [7] Hou L, Wei YD, Li WM, et al. Comparative study on transradial versus transfemoral approach for primary percutaneous coronary intervention in Chinese patients with acute myocardial infarction. *Saudi Med J* 2010;31:158–62.
- [8] Saito S, Tanaka S, Hiroe Y, et al. Comparative study on transradial approach vs. transfemoral approach in primary stent implantation for patients with acute myocardial infarction: results of the test for myocardial infarction by prospective unicenter randomization for access sites (TEMPURA) trial. *Catheter Cardiovasc Interv* 2003;59:26–33.
- [9] Waggoner T, Desai H, Sanghvi K. A unique complication of the GuideZilla guide extension support catheter and the risk of stent stripping in interventional & endovascular interventions. *Indian Heart J* 2015;67:381–4.
- [10] Yew KL. Guidezilla guide extension catheter enhances the delivery of bioresorbable vascular scaffold in an anomalous coronary artery. *Int J Cardiol* 2016;223:239–41.
- [11] Cola C, Miranda F, Vaquerizo B, et al. The Guideliner catheter for stent delivery in difficult cases: tips and tricks. *J Int Cardiol* 2011;24:450–61.
- [12] Farooq V, Mamas MA, Fath-Ordoubadi F, et al. The use of a guide catheter extension system as an aid during transradial percutaneous coronary intervention of coronary artery bypass grafts. *Catheter Cardiovasc Interv* 2011;78:847–63.
- [13] Serajian A. Novel use of a GuideLiner catheter to visualize distal LAD after LIMA anastomosis in selective coronary angiography. *J Invasive Cardiol* 2012;24:E30–1.
- [14] Tunuguntla A, Daneault B, Kirtane AJ. Novel use of the GuideLiner catheter to minimize contrast use during PCI in a patient with chronic kidney disease. *Catheter Cardiovasc Interv* 2012;80:453–5.
- [15] Chan PH, Alegria-Barrero E, Foin N, et al. Extended use of the GuideLiner in complex coronary interventions. *EuroIntervention* 2015; 11:325–35.
- [16] Hoebers LP, Claessen BE, Dangas GD, et al. Contemporary overview and clinical perspectives of chronic total occlusions. *Nat Rev Cardiol* 2014;11:458–69.
- [17] Sianos G, Barlis P, Di Mario C, et al. European experience with the retrograde approach for the recanalisation of coronary artery chronic total occlusions. A report on behalf of the euroCTO club. *Euro-Intervention* 2008;4:84–92.
- [18] Sianos G, Karlas A. Tools & techniques: CTO – the retrograde approach. *EuroIntervention* 2011;7:285–7.
- [19] Zhang YJ, Zhu LL, Bourantas CV, et al. Impact of everolimus versus other rapamycin derivative-eluting stents on clinical outcomes in patients with coronary artery disease: a meta-analysis of 16 randomized trials. *J Cardiol* 2014;64:185–93.
- [20] Liu W, Zhang Y, Yu CM, et al. Current understanding of coronary artery calcification. *J Geriatr Cardiol* 2015;12:668–75.
- [21] Barbato E, Carrie D, Dardas P, et al. European expert consensus on rotational atherectomy. *EuroIntervention* 2015;11:30–6.