

Lower Limb Reconstruction – Fasciocutaneous Sural Flap*

Reconstrução de membro inferior – retalho fasciocutâneo sural

Antonio Lourenco Severo^{1,2} Eduardo Felipe Mandarinop Coppi^{1,2} Haiana Lopes Cavalheiro^{1,2}
 Alexandre Luiz Dal Bosco^{1,2} Danilo Barreto Filho^{1,2} Marcelo Barreto Lemos^{1,2}

¹Hospital São Vicente de Paulo, Passo Fundo, RS, Brazil

²Instituto de Ortopedia e Traumatologia de Passo Fundo, Passo Fundo, RS, Brazil

Address for correspondence Antonio Lourenco Severo, Hospital São Vicente de Paulo (HSVP-RS), Passo Fundo, RS, Brazil (e-mail: antoniolsevero@gmail.com).

Rev Bras Ortop 2019;54:128–133.

Abstract

Objective The present study aims to evaluate the use of the reverse-flow sural fasciocutaneous flap to cover lesions in the distal third of the lower limb.

Methods A total of 24 cases were analyzed, including 20 traumatic injuries, 3 sports injuries, and 1 case of tumor resection.

Results Among the 24 evaluated medical records, 16 patients were male, and 8 were female. Their age ranged from 6 to 75 years old. Most of the patients evolved with total healing of the flap ($n=21$). There was only one case of total necrosis of the flap in an insulin-dependent diabetic, high blood pressure patient, evolving to subsequent limb amputation. In two cases, there was partial necrosis and subsequent healing by secondary intention; one of these patients was a heavy smoker. Complications were associated with comorbidities and, unlike other studies, no correlation was observed with the learning curve. There was also no correlation with the site or size of the lesion to be covered.

Conclusion It is clinically relevant that the success rate of the reverse-flow sural fasciocutaneous flap technique was of 87.5%. This is a viable and effective alternative in the therapeutic arsenal for complex lower limb lesions.

Keywords

- ▶ surgical flaps
- ▶ sural nerve/transplantation
- ▶ fascia/transplantation
- ▶ leg injuries

Resumo

Objetivo Avaliar o uso do retalho fasciocutâneo sural de fluxo reverso na cobertura de lesões no terço distal dos membros inferiores.

Métodos Foram analisados 24 casos, 20 de origem traumática, três por lesões esportivas e um por ressecção de lesão tumoral.

Resultados Dos 24 prontuários avaliados, 16 eram homens e oito mulheres. A idade variou de seis a 75 anos. A maioria dos pacientes evoluiu com cicatrização total do retalho (21). Houve apenas um caso de necrose total do retalho em paciente diabético insulinodependente e hipertenso, evoluiu para posterior amputação do membro. Em dois casos, houve necrose parcial com posterior cicatrização por segunda intenção, um

* Work developed at the Hospital São Vicente de Paulo, Passo Fundo, RS, Brazil.

Palavras-chave

- ▶ retalhos cirúrgicos
- ▶ nervo sural/transplante
- ▶ fâscia/transplante
- ▶ traumatismos da perna

desses pacientes era tabagista pesado. As complicações foram associadas às comorbidades e, ao contrário do evidenciado por outros estudos, não houve correlação com a curva de aprendizado. Também não houve correlação com o local ou o tamanho da lesão a ser coberta.

Conclusão Tem-se como relevância clínica que a técnica de retalho fasciocutâneo sural de fluxo reverso usada obteve 87,5% de sucesso, e é uma opção viável e eficaz no arsenal terapêutico das lesões complexas dos membros inferiores.

Introduction

The coverage of the distal third of the leg is still a challenge for reconstructive surgery due to its limited distensibility and mobility, low blood supply, and lack of muscle tissue interposition between noble structures and the integument. These features make randomized grafts and flaps unsuitable for wounds in this region.¹⁻³

The use of microsurgical flaps and pedicle flaps based on the cutaneous perforating arteries of the leg, specifically reverse flaps, leads to the best outcomes. However, some patients require a more complex surgical technique.⁴

The sural fasciocutaneous flap, popularly called distal sural flap, has become one of the most important tools in the therapeutic armamentarium of reconstructive surgery for lesions in the distal third of the leg, ankle and foot, especially after publications from Masquelet et al.¹ It presents advantages, such as greater mobility and versatility, as well as the preservation of important arteries and muscles, in addition to mimicking the receiving area in texture, thickness, pigmentation, and flexibility. The possible complications are the same as other flaps: ischemia, with partial or total necrosis.^{2,5-7} As such, the present study aimed to evaluate the use of fasciocutaneous reverse-flow sural flap for distal lesions covering the lower limb.

Materials and Methods

This is a cross-sectional retrospective study approved by the Research Ethics Committee (CEP) from the Universidade de Passo Fundo, RS, Brazil, under the number 1,854,277. The medical records of the patients submitted to lower limb reconstructive surgery were evaluated, and only subjects submitted to the reverse-flow sural flap technique from August 2001 to December 2016 were included.

The variables collected from the medical records were age, gender, lesion location, diagnosis, date of surgery, comorbidities, and complications.

The dimensions of the flaps ranged from 2 × 3 to 8 × 8 cm², according to the size of the areas to be covered. The surgical technique used in all of the cases was based on the description by Masquelet et al.^{1,2}

- Spinal block
- Patient in prone position: cleansing and debridement of the receiving area.

- The flap is drawn at the junction of the gastrocnemius muscle heads. A line is drawn distally, following the assumed path of the pedicle to the rotational point of the flap, about 5 cm proximal to the extremity of the lateral malleolus.
- Gravitational venous drainage and tourniquet at the level of the proximal thigh.
- Surgical incision from the skin up to the sural fascia.
- The sural nerve, the superficial sural artery, and the saphenous vein are connected proximally, so the flap is elevated and includes the fascia up to the rotational point. During flap elevation, the small arteries originating from the fibular artery must be ligated.
- Rotation of the flap to the receiving area.
- Flap suture in the receiving area.
- The flap may be sensitized with an end-to-side neurotomy of the sural cutaneous nerve to the tibial nerve, as described by Viterbo et al.⁸
- The tourniquet is released, and the perfusion of the flap is assessed. If perfusion is weak, check for compression points and jamming of the pedicle.
- The donor area can be closed primarily, but most of the time a partial skin graft, removed from the thigh area ipsilateral to the flap, is required.
- The bandage must be carefully done to avoid compression in the pedicle area; in addition, the patient must be positioned as to not subject the posterolateral region of the leg to external pressure.
- Postoperative period: foods that can cause vasoconstriction, such as coffee, *guaraná*, chocolate, *chimarrão* (South Brazilian traditional tea), stuffed wafer, tea, and other xanthine-rich foods (since they are vasoconstrictors) are avoided for at least 1 month. Smoking is discouraged. An anticoagulant agent (enoxaparin sodium, 40 mg/day) was used for 3 days. Then, treatment with acetylsalicylic acid, 325 mg/day, was introduced and sustained for 30 days. Antibiotic therapy (cefazolin) was maintained for 48 hours postoperatively or per the discretion of the physician.

Results

From the 24 evaluated medical records, 16 (66.7%) patients were male and 8 (33.3%) were female. Their age ranged from 6 to 75 years old. The majority (83.3%) of the patients required a flap for cutaneous cover due to trauma sequelae (car accident); 3 cases (12.5%) were due to sports injuries (suture dehiscence in Achilles tendon reconstruction), and

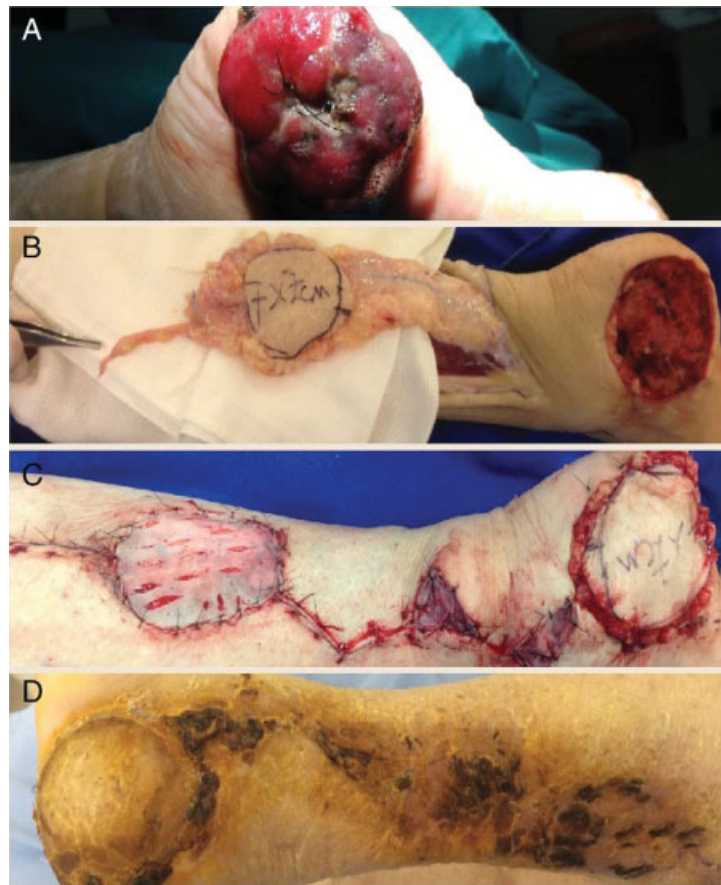


Fig. 1 A, ulcerated calcaneal injury (melanoma); B, fasciocutaneous flap dissected with neurovascular pedicle; C, flap in the recipient area and skin grafting in the donor area; D, late postoperative period.

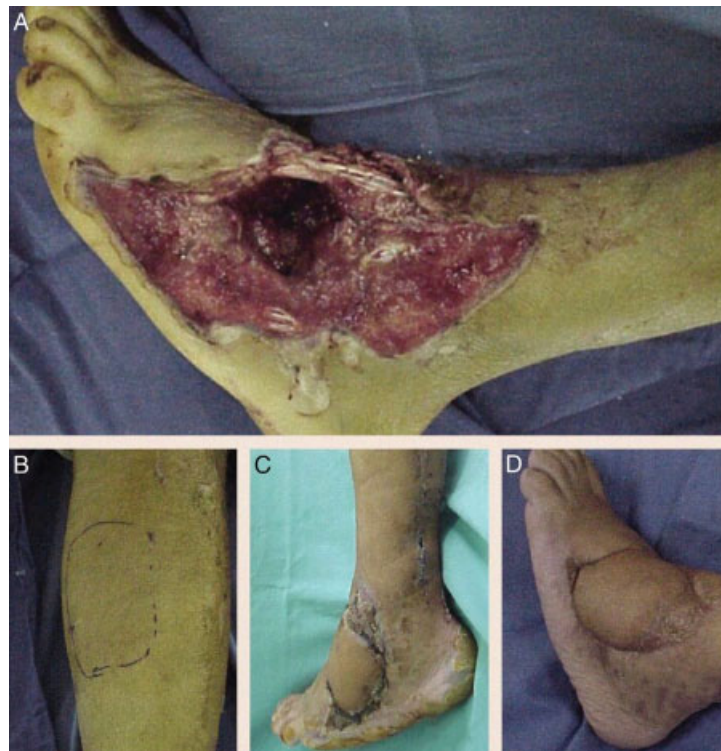

Fig. 2 Trauma by crushing. A, extensive lesion on the back of the foot with a critical area of 8 × 8 cm; B, donor area; C, receiving area after sural fasciocutaneous flap coverage; D, late postoperative period.

only 1 (4.2%) patient underwent a lower limb reconstruction after tumor resection.

Three patients presented associated comorbidities: diabetes mellitus (DM), smoking, and systemic arterial hypertension.

The most frequent sites of injury were the lateral malleolus (20.8%), the back of the foot, calcaneus (16.7%), and the Achilles tendon region (16.7%).

Most of the cases evolved with no complications (87.5%). Only 2 cases (8.3%) had partial necrosis with secondary intention healing, and 1 patient (4.2%) presented with total necrosis evolving to amputation.

The patient in ►Fig. 1, a 45-year-old woman who required a flap after tumor resection of a calcaneal melanoma, had a

successful application of the present technique. The patient in ►Fig. 2, a 40-year-old man who required a sural fasciocutaneous flap after trauma on the back of the foot had a favorable recovery with good healing. The variables age, gender, lesion location, diagnosis, date of surgery, and complications of each case are presented in ►Table 1.

Discussion

The main indications for reverse-flow sural fasciocutaneous flap are coverage of chronic skin ulcers, traumatic lesions (mainly secondary to open fractures), oncological resections, and lesions located at the posterior aspect of the heel and of

Table 1 Variables obtained at medical records from patients submitted to the surgical technique of reverse-flow sural flap from August 2001 to December 2016

Case	Age	Gender	Lesion location	Diagnosis	Surgery date	Complication
1	70	M	Medial malleolus	Distal tibial fracture	Oct/14	None
2	23	M	Back foot	Open fracture-dislocation of the ankle	May/2014	None
3	37	M	Distal third of the leg, anterior aspect	Open distal tibial fracture	Dec/2014	None
4	33	M	Distal third of the leg, anterior aspect	Open distal tibial fracture	Jul/2013	None
5	46	M	Lateral malleolus	Open fracture of the ankle	Mar/2012	None
6	18	M	Distal third of the leg, anterior aspect + lateral malleolus	Open fracture of the ankle	Feb/2011	None
7	6	F	Calcaneus	Loss of calcaneal substance	Jul/2010	None
8	39	M	Back foot	Open fracture-dislocation of the medial foot	Oct/2009	None
9	8	F	Lateral malleolus	Ankle injury	Oct/2009	None
10	7	F	Calcaneus	Open calcaneal fracture	Oct/2009	Partial flap necrosis
11	46	M	Medial malleolus	Open medial malleolus fracture	Apr/2009	None
12	60	M	Achilles tendon	Suture dehiscence	Jan/2013	None
13	14	M	Distal third of the leg, lateral aspect	Leg injury	May/2016	None
14	54	F	Achilles tendon	Suture dehiscence	Dec/2004	None
15	63	M	Distal third of the leg, anterior aspect	Distal tibial fracture	Nov/2004	None
16	22	M	Calcaneus	Calcaneal exposure	Sept/2004	None
17	45	M	Back foot	Open lateral malleolus fracture	Aug/2001	None
18	46	F	Lateral malleolus	Ankle fracture – suture dehiscence	Mar/2006	None
19	64	F	Lateral malleolus	Lateral malleolus fracture	Feb/2014	None
20a	45	F	Calcaneus	Calcaneal melanoma	Dec/2016	None
21b	75	M	Lateral malleolus	Open ankle fracture	Mar/2013	Total flap necrosis
22	46	F	Achilles tendon	Rupture—dehiscence	Apr/2016	None
23c	40	M	Back foot	Crushing injury	Feb/2007	None
24	55	M	Achilles tendon	Tibial and distal fibular fracture	May/2015	Partial necrosis

Source: Hospital São Vicente de Paulo, Passo Fundo, RS, Brazil.

a ►Fig. 1: Calcaneal melanoma. b ►Fig. 2: Bilateral open malleolar fracture evolving to total flap necrosis and subsequent amputation. c ►Fig. 3: Back foot crushing trauma.

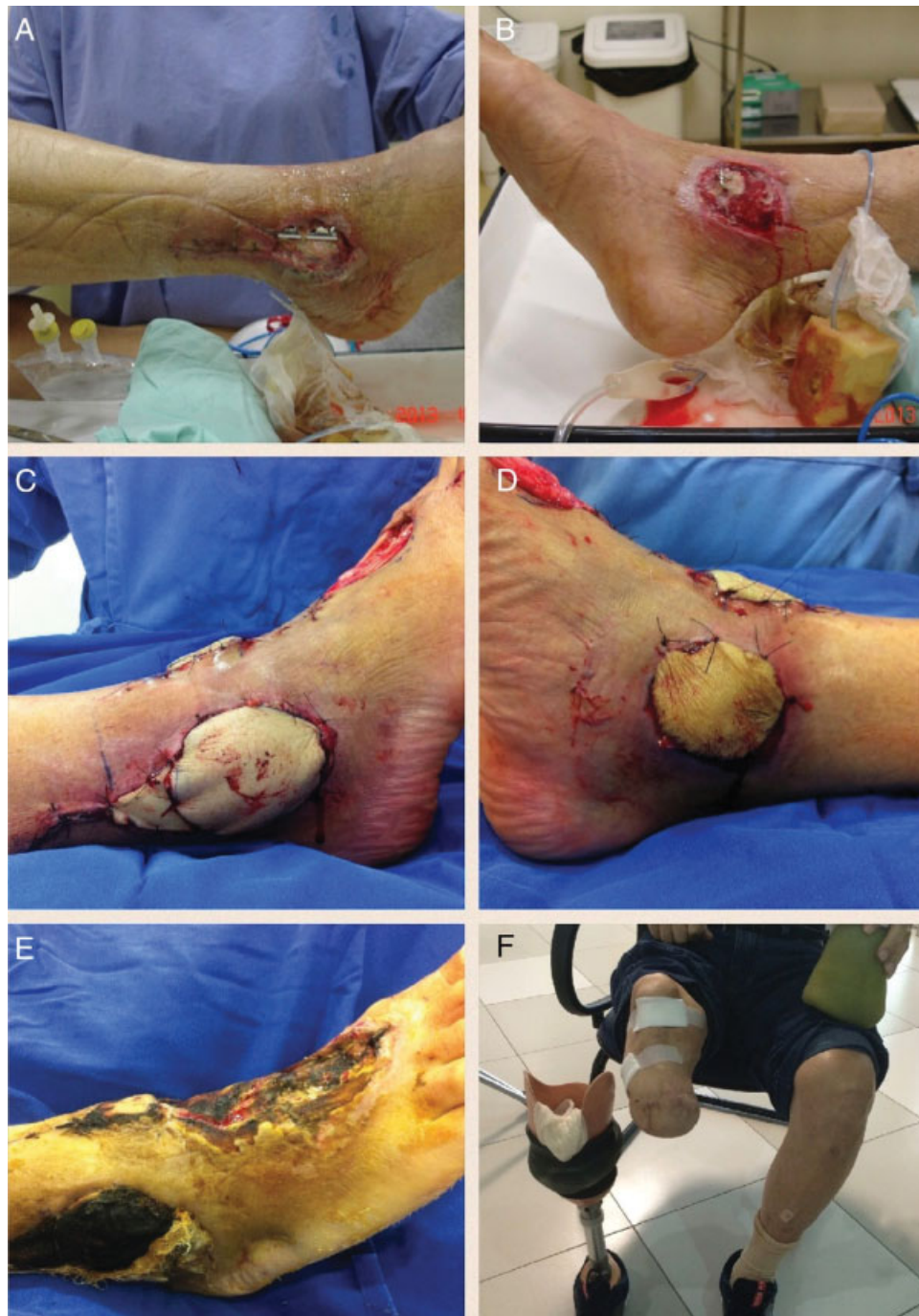

Fig. 3 Lateral (A) and medial (B) aspect of an open malleolus fracture. Infection in the bilateral operative wound led to the failure of the covering tissues. Reverse-flow sural fasciocutaneous flap for the lateral malleolus (C) and a pedal flap for the medial malleolus (D) were performed. Total necrosis of both flaps (E). Evolution for amputation (F).

the Achilles tendon, the lateral and anterior aspect of the ankle, the back of the foot, the lateral aspect of the hindfoot, and the lower third of the leg. Other indications, such as full heel coverage and medial aspect of the distal third of the leg, are considered relative because of the small distance to the rotational point, which may affect the vascular pedicle at attempts to reach these regions, compromising the flap.^{1-3,6}

Severo et al⁹ state that local pedicled flaps are preferred whenever there is enough vascular and tissue viability in the donor area for lesion filling.

The greater mobility and versatility of the reverse-flow sural flap, in addition to sparing important arteries, has shown increasing success rates and few complications. Studies performed > 10 years ago showed a higher rate of complications ($\leq 35\%$), with a significant reduction during the last 10 years ($\leq 12\%$).^{6,10-12} This fact was also reported by Vendramin et al,¹³ who found different complication rates after evaluating the outcomes from the same surgical team at different periods of the learning curve. These literature findings do not agree with the present study,

whose success rate was of 87.5%, since complications did not have any relation with the learning curve, as this technique was introduced in this service in 2001 and the complications occurred in 2009, 2013 and 2015. Both partial necrosis cases represented about 10% of the flap area, and complete lesion closure occurred by secondary intention.

The patient who progressed to total necrosis and subsequent limb amputation (–Fig. 3) had type 2, insulin-dependent diabetes, and hypertension. We believe that his complications may have occurred due to comorbidities, consistent with Severo et al⁹ and Parrett et al,¹⁴ who found a correlation between complications and comorbidities, such as diabetes, obesity, peripheral vascular disease, and smoking. The latter, however, would be the main isolated risk factor for complications of this flap.

Almeida et al¹⁰ found 25.3% of necrosis in 71 cases (21.1% partial and 4.2% total necrosis). The following year, Baumeister et al¹⁵ analyzed 70 patients with clinical comorbidities, mainly diabetes, and the rates of partial and total necrosis were, respectively, 17% and 18%. In the study by Belém et al,⁶ with 22 patients, 22% had partial necrosis, and 4.1% presented with total necrosis. Next, Garcia et al⁵ reported partial necrosis in only 1 patient (6.6%) from a total of 15 flaps. Dhamangaonkar et al¹⁶ reported 81 cases, with partial necrosis in just 9 patients (11.1%). Outcomes from the last two studies are similar to our findings.

Most patients from the present study were male, as in several other papers on surgical reconstructions of the lower limbs.^{1,4,16–18} This fact can be explained by the traumatic nature of most lesions and the higher involvement of male individuals in these incidents.

Conclusion

It is clinically relevant that the option of reverse-flow sural fasciocutaneous flap technique to cover lesions in the distal third of the lower limbs was safe, easy to perform and did not require a complex microsurgical technique. Therefore, with satisfactory results and a low rate of complications, it is an important option for the therapeutic arsenal in the surgical reconstruction of the lower limbs.

Conflicts of Interest

The authors have no conflicts of interest to declare.

References

- Masquelet AC, Romana MC, Wolf G. Skin island flaps supplied by the vascular axis of the sensitive superficial nerves: anatomic study and clinical experience in the leg. *Plast Reconstr Surg* 1992; 89(06):1115–1121
- Masquelet AC. Sural flap. In: Grabb's encyclopedia of flaps. 3rd ed. Philadelphia: Taylor & Francis; 2009
- Mandarano Filho LG, Bezuti MT, Penno RAL, Mazzer N, Barbieri CH. O retalho fasciocutâneo sural de base distal. *Rev Ortop Traumatol (B Aires)* 2010;2(01):12–18
- De Rezende MR, Rabelo NT, Benabou JE, Wei TH, Mattar Junior R, Zumioti AV, et al. Cobertura do terço distal da perna com retalhos de perfurantes pediculados. *Acta Ortop Bras* 2008;16(04):223–229
- Garcia AM. Retalho sural de fluxo reverso para reconstrução distal da perna, tornozelo, calcanhar e do pé. *Rev Bras Cir Plást* 2009; 24(01):96–103
- Belém LF, Lima JC, Ferreira FP, Ferreira EM, Penna FV, Alves MB. Retalho sural de fluxo reverso em ilha. *Rev Bras Cir Plást* 2007; 22(04):195–201
- Schaverien M, Saint-Cyr M. Perforators of the lower leg: analysis of perforator locations and clinical application for pedicled perforator flaps. *Plast Reconstr Surg* 2008;122(01):161–170
- Viterbo F, Trindade JC, Hoshino K, Mazzoni Neto A. End-to-side neurotaphy with removal of the epineurial sheath: an experimental study in rats. *Plast Reconstr Surg* 1994;94(07):1038–1047
- Severo AL, Scorsatto C, Valente EB, Lech OL. Retalhos para reconstrução de perdas musculocutâneas em membros inferiores: análise de 18 casos. *Rev Bras Ortop* 2004;39(10):578–589
- Almeida MF, da Costa PR, Okawa RY. Reverse-flow island sural flap. *Plast Reconstr Surg* 2002;109(02):583–591
- Turan K, Tahta M, Bulut T, Akgün U, Sener M. Soft tissue reconstruction of foot and ankle defects with reverse sural fasciocutaneous flaps. *Rev Bras Ortop* 2017;53(03):319–322
- Vendramin FS, Silva CS. Retalho sural estendido de pedículo distal. *Rev Col Bras Cir* 2004;31(04):248–252
- Vendramin FS. Retalho sural de fluxo reverse: 10 anos de experiência clínica e modificações. *Rev Bras Cir Plást* 2012;27(02):309–315
- Parrett BM, Pribaz JJ, Matros E, Przylecki W, Sampson CE, Orgill DP. Risk analysis for the reverse sural fasciocutaneous flap in distal leg reconstruction. *Plast Reconstr Surg* 2009;123(05):1499–1504
- Baumeister SP, Spierer R, Erdmann D, Sweis R, Levin LS, Germann GK. A realistic complication analysis of 70 sural artery flaps in a multi-morbid patient group. *Plast Reconstr Surg* 2003;112(01):129–140
- Dhamangaonkar AC, Patankar HS. Reverse sural fasciocutaneous flap with a cutaneous pedicle to cover distal lower limb soft tissue defects: experience of 109 clinical cases. *J Orthop Traumatol* 2014;15(03):225–229
- Yildirim S, Akan M, Aköz T. Soft-tissue reconstruction of the foot with distally based neurocutaneous flaps in diabetic patients. *Ann Plast Surg* 2002;48(03):258–264
- D'Avila F, Franco D, D'Avila B, Arnaut M Jr. Use of local muscle flaps to cover leg bone exposures. *Rev Col Bras Cir* 2014; 41(06):434–439