

Atypical MR lenticular signal change in infantile isovaleric acidemia

Nisar A Wani, Umer Amin Qureshi¹, Majid Jehangir², Kaiser Ahmad¹, Zahid Hussain¹

Departments of Pediatric Radiology, ¹Pediatrics and ²Radiology, Government Medical College, Srinagar, Jammu and Kashmir, India

Correspondence: Dr. Nisar A Wani, Department of Pediatric Radiology, Government Medical College, Srinagar, Jammu and Kashmir, India.
E-mail: ahmad77chinar@gmail.com

Abstract

Isovaleric acidemia (IVA) is an inborn error of branched chain amino acid metabolism that may manifest as acute neonatal metabolic acidosis or as chronic intermittent form with developmental delay or recurrent episodes of acute metabolic acidosis. Early diagnosis is the key to prevent morbidity and mortality. Brain imaging abnormalities are rarely described in IVA. We report a case of chronic intermittent IVA with acute presentation in a 4-month-old infant who presented with acute metabolic acidosis. Brain magnetic resonance imaging (MRI) revealed symmetric signal intensity changes in bilateral lentiform nuclei with an unreported T1-weighted (T1W) symmetric hyperintense ring-like appearance in bilateral putamen.

Key words: Basal ganglia; inborn error of metabolism; isovaleric acidemia; magnetic resonance imaging

Introduction

Isovaleric acidemia (IVA) is an inherited autosomal recessive metabolic disease caused by a defect in the metabolism of amino acid leucine.^[1] The disease may present as metabolically severe form in the initial 2 weeks of life with acute onset vomiting and lethargy, progressing to coma. The other manifestation may be a metabolically mild form of failure to thrive and/or delayed development/mental retardation.^[2] These patients as well as those who survive acute illness may develop acute intercurrent episodes of decompensation with stressors like infection, immunization, or fasting. Diagnosis is made by identifying elevated levels of isovaleric acid and its derivatives and their glycine and carnitine conjugates in plasma and urine of patients. Free isovaleric acid may increase several hundredfold in blood during acute decompensation, but is not readily seen in blood and urine as it is conjugated rapidly. Elevated levels

of isovalerylcarnitine in blood and isovalerylglycine in urine are the hallmarks of this disease regardless of the metabolic condition.^[2] Other methods of diagnosis based on isovaleryl CoA dehydrogenase (IVD) enzyme activity in the body cells and identifying DNA changes in the gene encoding IVD can confirm the disease.^[1-4] Brain imaging abnormalities in IVA have rarely been described. We report the magnetic resonance imaging (MRI) findings in a case of IVA seen as hyperintense signal intensity in basal ganglia on T1- and T2-weighted images.

Case Report

A breastfed 4-month-old female presented to our emergency room with decreased feeding, a generalized clonic seizure, lethargy, and acidotic breathing for 3 h. A product of third-degree consanguinity, she was born by term normal delivery with no significant perinatal event. Past history was significant for reflux and constipation. She had received immunization 1 week prior to illness. There were no sibling deaths. Her development was consistent with age. At admission, she had a vacant stare with a Glasgow Coma Score (GCS) of 7. Her heart rate was 120/min, respiratory rate 66/min, capillary refill time 2 s, and temperature 97.8°F. On anthropometric assessment, she was found to have failure to thrive with a weight of 3.8 kg, length 59 cm, upper segment/lower segment ratio 1.7:1, and head circumference

Access this article online

Quick Response Code:



Website:
www.ijri.org

DOI:
10.4103/0971-3026.178362

40 cm. Anterior fontanelle was at normal level. Blood sugar was 213 mg/dl. Complete blood counts, renal function and liver function tests were within normal limits. C-reactive protein was negative. Arterial blood gases were consistent with high anion gap severe metabolic acidosis (pH = 6.8, $\text{HCO}_3^- = 3$ mEq/l, $\text{pCO}_2 = 16$ mmHg, anion gap = 26). Serum chemistry showed a calcium level of 8.5 mEq/l, phosphorus 3.2 mg/dl, sodium 137 mmol/l, and potassium level of 4.5 mmol/l. Serum lactate was 3 mmol/l; hyperammonemia was not documented. Urine was 3+ for ketones on dipstick. Cerebrospinal fluid examination was normal. Patient was dilantinised and started on maintenance intravenous fluids containing dextrose 10% and antibiotics pending cultures which turned out to be sterile. After correction of metabolic acidosis with intravenous sodium bicarbonate, breathing and sensorium improved. Examination of CNS showed rigidity of all limbs with decreased movement of lower limbs, which improved over a period of time in the hospital. Rest of the systemic examination was unremarkable.

MRI of head was performed with 1.5 T (Siemens, Erlangen Germany) MR imager using inversion recovery (IR) T1-weighted (T1W) and T2-weighted (T2-W) sequences in various orthogonal planes. Diffusion-weighted imaging (DWI), susceptibility-weighted imaging (SWI), and magnetic resonance spectroscopy (MRS) were also performed. MRI brain revealed altered signal intensity in bilateral basal ganglia involving lentiform nuclei symmetrically with predominant involvement of putamen than globus pallidus. On T1W images, bilateral putamen and globus pallidi appeared to be involved with a peripheral hyperintense signal intensity rim and central low heterogeneous signal compared to white matter [Figure 1A and B]. Corresponding lentiform lesions showed predominant hyperintense signal intensity on T2W images with small, slightly hypointense signal in the center [Figure 2A and B] which was more clearly seen in axial images. DWI showed hyperintense signal intensity in bilateral lentiform nuclei on high diffusion-weighted (b value of 1000 s/mm²) images [Figure 3A] and hypointense signal on apparent diffusion coefficient ADC [Figure 3B]

compatible with restricted diffusion. ADC maps revealed low ADC value in the lentiform nuclei (0.9×10^{-3} mm²/s) than thalami (1.1×10^{-3} mm²/s). Restricted diffusivity area was slightly larger than the corresponding T2W-hyperintense signal intensity lesion and was distinctly more extensive than the hyperintense ring seen on T1W images in the bilateral lentiform nuclei. No convincing blooming was noticed on SWI (T2**) images in the lentiform nuclei in the corresponding T1W- and T2W-hyperintense signal intensity lesions [Figure 4]. MRS (at TE = 135 ms) of the lentiform lesions revealed a non-specific appearance of reduced N-acetylaspartate NAA peak and elevated choline peak with slightly elevated lactate peak [Figure 5]. There was no other significant abnormality of cerebellum, brainstem, or cerebral cortex on MRI brain.

Biochemical analysis of urine was done for possible inborn error of metabolism. Quantitative measurement of urinary organic acids by gas chromatography-mass spectrometry revealed 3-hydroxyisovaleric acid = 5.95, isovaleroglycine = 96.10, isovalerylglycine-(2) = 0.40 (all in the units of relative peak area to internal standard) with elevation factors of 7.44, 961, and 0.40 respectively. A diagnosis of IVA was made on the basis of biochemical analysis and clinical presentation of the child. Patient was put on low-protein, high-calorie diet after initial stabilization and is being followed for physical and mental development milestones.

Discussion

IVA is an inherited autosomal recessive metabolic disease caused by the deficiency of IVD.^[1] The enzyme catalyzes an early reaction in the metabolism of branched chain amino acid, namely leucine. Consequent to IVD deficiency, isovaleric acid and its other derivatives accumulate in the body. These metabolites may impart a peculiar sweaty feet smell to the body, which may aid in the diagnosis.^[1,2] IVA may present acutely in neonates with poor feeding,

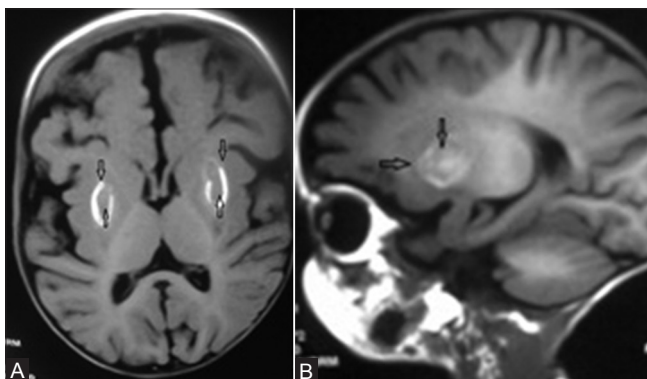


Figure 1 (A and B): T1W inversion recovery images at the basal ganglia level in axial (A) and sagittal (B) planes showing peripheral hyperintense signal intensity ring (downward arrow) in bilateral lentiform nuclei around heterogeneous low signal center (upward/backward arrow)

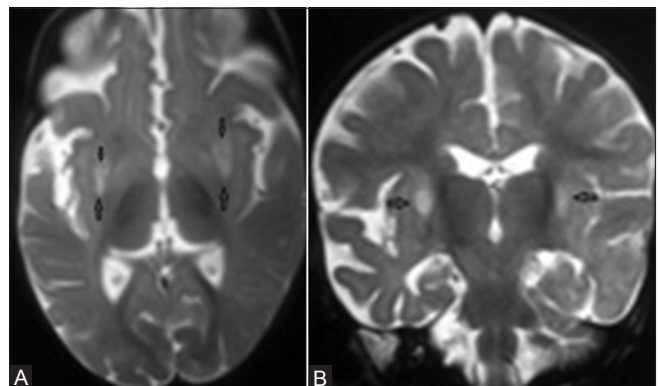


Figure 2 (A and B): T2W images at the level of basal ganglia in axial (A) and coronal (B) planes showing symmetric hyperintense signal intensity in bilateral lentiform nuclei (upward arrow) with small hypointense signal area toward the center (downward arrow)

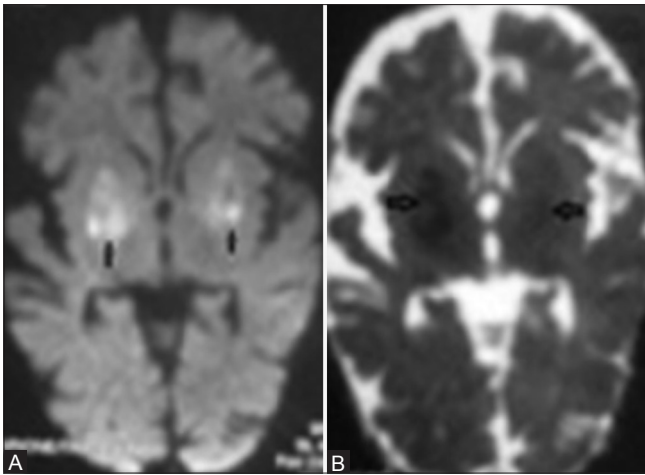


Figure 3 (A and B): Axial diffusion-weighted MRI at b value of 1000 s/mm² (A) at the level of basal ganglia shows hyperintense signal intensity in bilateral lentiform nuclei (arrow). ADC map (B) at the same level shows reduced ADC value in bilateral lentiform nuclei seen as hypointense signal (arrow)

vomiting, decreased level of consciousness, and seizures.^[2,4] Characteristic smell of dirty socks may be noticed in the body sweat or cerumen from ear during an acute crisis. Acidosis, hyperammonemia, hypo- or hyperglycemia, and hypocalcemia may be present.^[2,3] Acute decompensation in chronic-intermittent IVA patients beyond newborn period, also called catabolic episodes, may be triggered by infection or other stress and may be mistaken as diabetic ketoacidosis.^[4]

Although genetic mutations and biochemical changes with gas chromatography and mass/tandem spectrometry have been extensively described in IVA, imaging with computed tomography (CT) and MRI of brain is rarely reported.^[4,5] We came across a single report describing CT and MRI findings in a case of IVA which documented altered signal intensity on MRI in globus pallidus and brainstem. Changes in globus pallidi have been described as T1 and T2 relaxation time prolongation seen as symmetric T1W-hypointense and T2W-hyperintense signal intensity in the bilateral globus pallidus.^[5] We report signal intensity changes on MRI in the bilateral putamen and globus pallidi in a case of chronic-intermittent IVA in acute decompensated state. MRI brain revealed T1W-hyperintense signal (T1 shortening) and T2W- hyperintense signal (T2 prolongation) in bilateral lentiform nuclei, with indistinct blooming/signal loss on SWI and concomitant evidence of restricted diffusion. Involvement of putamen besides globus pallidus and T1W-hyperintense ring-shaped signal change in the lentiform nuclei differentiated basal ganglia lesions in our case from the one described in literature. The underlying cause of MRI signal alteration in basal ganglia can be presumed to be the metabolites accumulating due to IVD deficiency.^[3] Putamen and globus pallidus are highly vulnerable to generalized metabolic abnormalities due to their richness of mitochondria, blood supply, and neurotransmitters and their increased

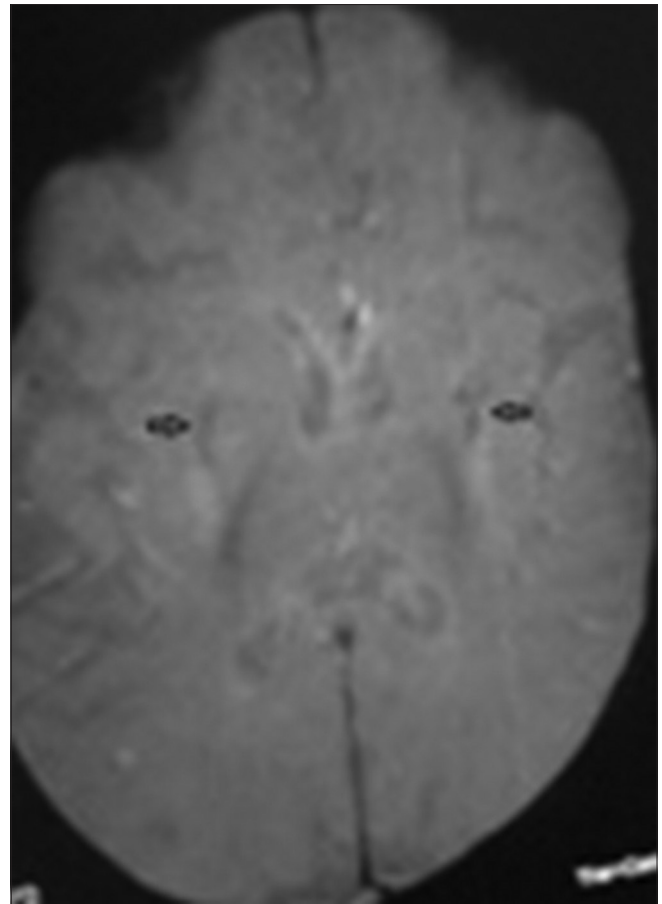


Figure 4: Susceptibility-weighted axial MRI (T2**) at the level of basal ganglia shows indistinct loss of signal/blooming (arrow) in the region of lentiform nuclei which is seen as hyperintense on T1W and T2W images

utilization of glucose and oxygen.^[6] Oxidative stress and reduced Na⁺ K⁺-ATPase activity could be caused by metabolites accumulating in IVA, including isovaleric acid, which can result in T2 prolongation and restricted diffusion due to cytotoxic edema.^[2,3] Acute hyperammonemia also is known to cause T2 prolongation and restricted diffusion in basal ganglia.^[6] We postulate oxidative stress due to accumulated metabolites to be responsible for reduced diffusivity seen in lentiform nuclei in our case. Oxidative stress and energy depletion could be substantiated by the presence of lactate in the MRS of lentiform lesion.

T1 relaxation time shortening of basal ganglia seen as hyperintense signal intensity on T1W MRI has been proposed to result from deposition of proteins, myelin breakdown products, blood, calcium or other minerals.^[6,7] We hypothesize that T1W shortening of lentiform nuclei in our case may possibly be related to protein and/or myelin breakdown product deposition resulting due to passage of isovaleric acid across the blood-brain barrier in acute crisis, as calcium, iron, and hemosiderin deposition was excluded by susceptibility-weighted MRI. Protein hydration layer within the cytoplasm of reactive astrocytes may result in T1

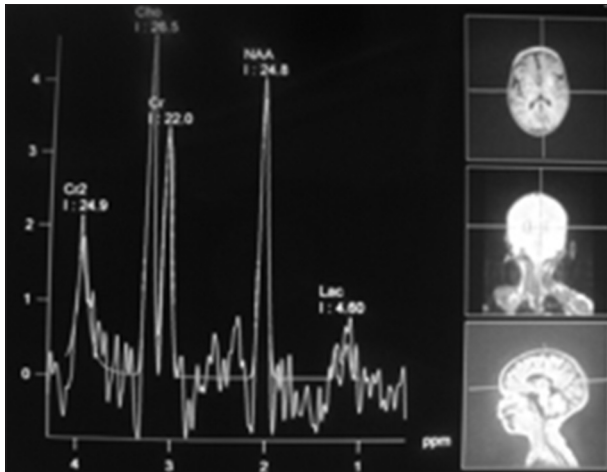


Figure 5: MRS at TE 135 ms of lentiform lesion showing elevated choline peak, reduced *N*-acetyl aspartate peak, and slight raised lactate level

relaxation time shortening and consequent T1W-hyperintense signal in the basal ganglia. Reactive astrocytes (gemistocytes) have been described to accumulate after acute insult and result in T1W-hyperintense signal in the basal ganglia.^[8]

Differential diagnoses of T1W-hyperintense signal intensity in bilateral basal ganglia include manganese deposition in acute hepatic decompensation of chronic liver disease, other causes of hyperammonemia like inborn errors of metabolism, manganese toxicity, and total parenteral nutrition.^[6-8] Hyperglycemia may also result in T1W-hyperintense signal in the basal ganglia.^[8] Hypoxic ischemic injury may involve basal ganglia and result in T1 relaxation time shortening in children. Neurofibromatosis 1 (the most common phakomatosis) may manifest as T1W- and T2W-hyperintense signal intensity lesions in bilateral globus pallidus.^[6,7]

Conclusion

Relevant medical history and laboratory investigations (wide anion gap metabolic acidosis, raised glycine and

carnitine conjugates of isovaleryl CoA) can help in making the correct diagnosis of IVA in a case of bilateral T1W-hyperintense signal intensity lesions involving lentiform nuclei.

Early diagnosis is the key to treatment in the form of restricted protein (specifically leucine) intake, high-calorie diet, and glycine and carnitine supplementation.^[3,4] Treatment effectiveness is assessed with serial assessment of body growth and mental development.

References

1. Tanaka K, Budd MA, Efron ML, Isselbacher KJ. Isovaleric acidemia: A new genetic defect of leucine metabolism. *Proc Natl Acad Sci U S A* 1966;56:236-42.
2. Vockley J, Ensenauer R. Isovaleric acidemia: New aspects of genetic and phenotypic heterogeneity. *Am J Med Genet C Semin Med Genet* 2006;142C: 95-103.
3. Grünert SC, Wendel U, Lindner M, Leichsenring M, Schwab KO, Vockley J, *et al.* Clinical and neurocognitive outcome in symptomatic isovaleric acidemia. *Orphanet J Rare Dis* 2012;7:9.
4. Cho JM, Lee BH, Kim GH, Kim YM, Choi JH, Yoo HW. Chronic intermittent form of isovaleric aciduria in a 2-year-old boy. *Korean J Pediatr* 2013;56:351-4.
5. Sogut A, Acun C, Aydin K, Tomac N, Demirel F, Aktuglu C. Isovaleric acidemia: Cranial CT and MRI findings. *Pediatr Radiol* 2004;34:160-2.
6. Hegde AN, Mohan S, Lath N, Lim CC. Differential diagnosis for bilateral abnormalities of the basal ganglia and thalamus. *Radiographics* 2011;31:5-30.
7. Lai PH, Chen C, Liang HL, Pan HB. Hyperintense basal ganglia on T1-weighted MR imaging. *AJR Am J Roentgenol* 1999;172:1109-15.
8. Shan DE, Ho DM, Chang C, Pan HC, Teng MM. Hemichorea-hemiballism: An explanation for MR signal changes. *AJNR Am J Neuroradiol* 1998;19:863-70.

Cite this article as: Wani NA, Qureshi UA, Jehangir M, Ahmad K, Hussain Z. Atypical MR lenticular signal change in infantile isovaleric acidemia. *Indian J Radiol Imaging* 2016;26:131-4.

Source of Support: Nil, **Conflict of Interest:** None declared.