

Hybrid Method of Transvertebral Foraminotomy Combined with Anterior Cervical Decompression and Fusion for Multilevel Cervical Disease

Yu YAMAMOTO,¹ Masahito HARA,² Yusuke NISHIMURA,¹
Shoichi HAIMOTO,¹ and Toshihiko WAKABAYASHI¹

¹Department of Neurosurgery, Nagoya University, Graduate School of Medicine,
Nagoya, Aichi, Japan;

²Department of Neurosurgery, Inazawa City Hospital, Inazawa, Aichi, Japan

Abstract

Transvertebral foraminotomy (TVF) combined with anterior cervical decompression and fusion (ACDF) can be used to treat multilevel cervical spondylotic myelopathy and radiculopathy; however, the radiological outcomes and effectiveness of this hybrid procedure are unknown. We retrospectively assessed 22 consecutive patients treated with combined TVF and ACDF between January 2007 and May 2016. The Japanese Orthopedic Association (JOA) score and Odom's criteria were analyzed. Radiological assessment included the C2-7 sagittal Cobb angle (CA) and range of motion (ROM). The tilting angle (TA), TA ROM, and disc height (DH) of segments adjacent to the ACDF were also measured. Adjacent segment degeneration, which includes disc degeneration, was evaluated. The mean postoperative follow-up was 41.7 months. All surgeries were performed at two adjacent segments, with ACDF and TVF of the upper and lower segments, respectively. The JOA scores significantly improved. There were no significant differences in the C2-7 CA, C2-7 ROM, TA, and TA ROM, but there was a statistically significant decrease in DH of the lower adjacent segment to ACDF. Progression of disc degeneration was identified in two patients, with no progression in the criterion of adjacent segment degeneration over the follow-up. The TVF combined with ACDF produced excellent clinical results and maintained spinal alignment, albeit with a reduction in DH. TVF was safely performed at the lower segment adjacent to the ACDF, although this might result in earlier degeneration. In conclusion, this hybrid method is less invasive and beneficial for reduction of the number of fused levels.

Key words: transvertebral foraminotomy, anterior cervical decompression and fusion, cervical spondylotic myelopathy, cervical spondylotic radiculopathy, multilevel cervical disease

Introduction

Usually, the majority of surgeons prefer an anterior approach for patients with the single-level spinal disorder; however, there is considerable controversy regarding multilevel disease. To reduce the number of fused segments, we have devised hybrid method of transvertebral foraminotomy (TVF) combined with anterior cervical decompression and fusion (ACDF).

Cervical spondylotic myelopathy (CSM) and cervical spondylotic radiculopathy (CSR) are classically treated with single or multiple ACDF,¹ multilevel corpectomy,² laminectomy, or laminoplasty.³

The ACDF has been shown to be an effective method for the treatment of CSM and CSR, providing direct decompression of the spinal cord or nerve root by removing intervertebral discs and osteophytes. However, ACDF sacrifices segmental mobility, and this fusion procedure leads to increased mechanical stress and functional overloading on the adjacent segment.^{4,5} Some investigators reported that this mechanical stress accelerates disc degeneration and spondylotic changes at the adjacent segments.^{6,7} Furthermore, multilevel cervical spinal fusion is associated with increased complications, such as pseudoarthrosis, implant failure, adjacent segment disease, and mortality.^{4,5,7–10}

More recently, less invasive techniques, such as anterior cervical foraminotomy and/or lateral multiple oblique corpectomies, have been reported with increasing frequency.^{2,11–14} Anterior cervical foraminotomy is a minimally-invasive surgical method for

Received October 6, 2017; Accepted December 25, 2017

Copyright© 2018 by The Japan Neurosurgical Society
This work is licensed under a Creative Commons Attribution-NonCommercial-NoDerivatives International License.

CSR, which preserves segmental mobility and may avoid fusion-related complications and morbidity.^{12,14)} Based on this evidence, we have adopted the use of transvertebral anterior cervical foraminotomy (TVF) for CSR, which was originally reported by Yamada et al.¹⁵⁾

To provide a less invasive treatment for multilevel spinal disorders, one senior author on this paper has begun using a hybrid method, combining one-level ACDF and adjacent level TVF to reduce the number of fused segments. However, TVF is a minimally-invasive surgical method; there are some concerns and potential problems, such as degeneration of TVF segment, which cause instability or kyphosis. Choi described a minor but statistically significant loss of disc height at TVF segment.^{12,13)} In addition to the concern about this degeneration due to TVF procedure itself, ACDF cause the adjacent segment degeneration, so the hybrid method of TVF and ACDF may have the potential to accelerate degenerative changes and subsequent adjacent segment disease at the TVF segment. In the absence of previous reports on this emerging surgical method, our aim was to retrospectively review our experience and investigate the effectiveness of this novel hybrid method.

Materials and Methods

Patient population

This retrospective study included 22 consecutive patients treated using the hybrid method of TVF combined with ACDF for two-level CSM and CSR at our institute, from January 2007 to May 2016. The study group comprised 15 males and seven females, with an average age of 55.8 years (range, 31–81 years), with a mean follow-up age of 41.7 months (range, 8–84 months). All cases presented

with neurological deficits arising from a combination of CSM and CSR, with corresponding findings on imaging studies. The TVF was indicated only for the level considered to be accounting for the CSR, defined as either unilateral nerve root or unilateral spinal cord compression, without cervical kyphotic deformity, spinal instability, or a large lesion associated with wide and bilateral spinal cord compression. The presented hybrid method was applied only for the cases with upper-level CSM and lower-level CSR. We excluded cases with upper-level CSR and lower-level CSM, or two-level CSM because we have adopted combination of transsural foraminotomy and ACDF or two-level ACDF for these cases, respectively.

Clinical evaluation

Clinical records were reviewed and clinical outcomes were evaluated with the Japanese Orthopedic Association (JOA) scores and Odom's criteria (Table 1). The recovery rate of the JOA scores was calculated based on the methods of Hirabayashi et al.¹⁶⁾

Radiological evaluation

For all patients, static and dynamic radiographs, high-resolution computed tomographic (CT) scans and magnetic resonance imaging (MRI) were obtained preoperatively and postoperatively. On a postoperative day 1, static radiographs and CT scans were obtained to assess the location of the interbody fusion cage and the trajectory of the foraminotomy. Follow-up static and dynamic radiographs of the cervical spine were subsequently taken to assess the following items on a regular basis through the outpatient clinic: the C2-7 sagittal Cobb angle (C2-7 CA) and range of motion (ROM) of the C2-7 CA, the tilting angle (TA), the ROM of the TA and the disc height (DH) of the upper and lower adjacent segments to the ACDF. The extent

Table 1 Classification

(a) Odom's criteria				
Excellent	Complete relief of symptoms			
Good	Intermittent discomfort, but no interference with daily activities			
Fair	Subjective improvement but impaired physical activity			
Poor	No improvement at all and worse			
(b) Grading system for cervical intervertebral disc degeneration				
Grades	Nucleus signal intensity	Nucleus structure	Distinction of nucleus and annulus	Disc height
I	Hyperintense	Homogenous, white	Clear	Normal
II	Hyperintense	Inhomogenous with horizontal band, white	Clear	Normal
III	Intermediate	Inhomogenous, gray to black	Unclear	Normal to decreased
IV	Hypointense	Inhomogenous, gray to black	Lost	Normal to decreased
V	Hypointense	Inhomogenous, gray to black	Lost	Collapsed

of disc degeneration was assessed on MRI using the grading system of Miyazaki et al. (Table 1).¹⁷⁾ The adjacent segment degeneration was defined by a 50% decrease in DH postoperatively, vertebral osteophytes formation >2 mm, an anterior or posterior vertebral slip >2 mm, and disc herniation with spinal cord or nerve root compression.^{4,18,19)}

Surgical technique

The standard ACDF procedure was used with an interbody fusion cage. The TVF was performed in the method described by Hara.^{15,20)} The surgical approach was always from the side of radiculopathy. All cases had surgery for two continuous levels, with ACDF performed at the upper level and TVF at the lower level. An anterior retropharyngeal approach was used, with dissection of the longus colli muscle on both sides for ACDF. A titanium box cage or

polyetheretherketone (PEEK) cage, filled with local vertebral bone fragments, was inserted into the disc space. Then, the TVF was performed by slightly moving the retractor caudally with only the ipsilateral longus colli muscle retracted. A 6 × 6 mm keyhole was created just lateral to the anterior longitudinal ligament and midpoint of the upper vertebra. The trajectory of the tunnel was oriented in the caudal direction, with the keyhole made progressively wider and deeper, without fracturing of the uncovertebral joint. The intervertebral foramen was widened while preserving the intervertebral disc material as much as possible. Once the dorsal aspect of the vertebral body was reached, osteophytes were carefully removed. The herniated disc was removed by resecting the posterior longitudinal ligament. Finally, successful decompression of the affected nerve root was confirmed by direct observation (Fig. 1).

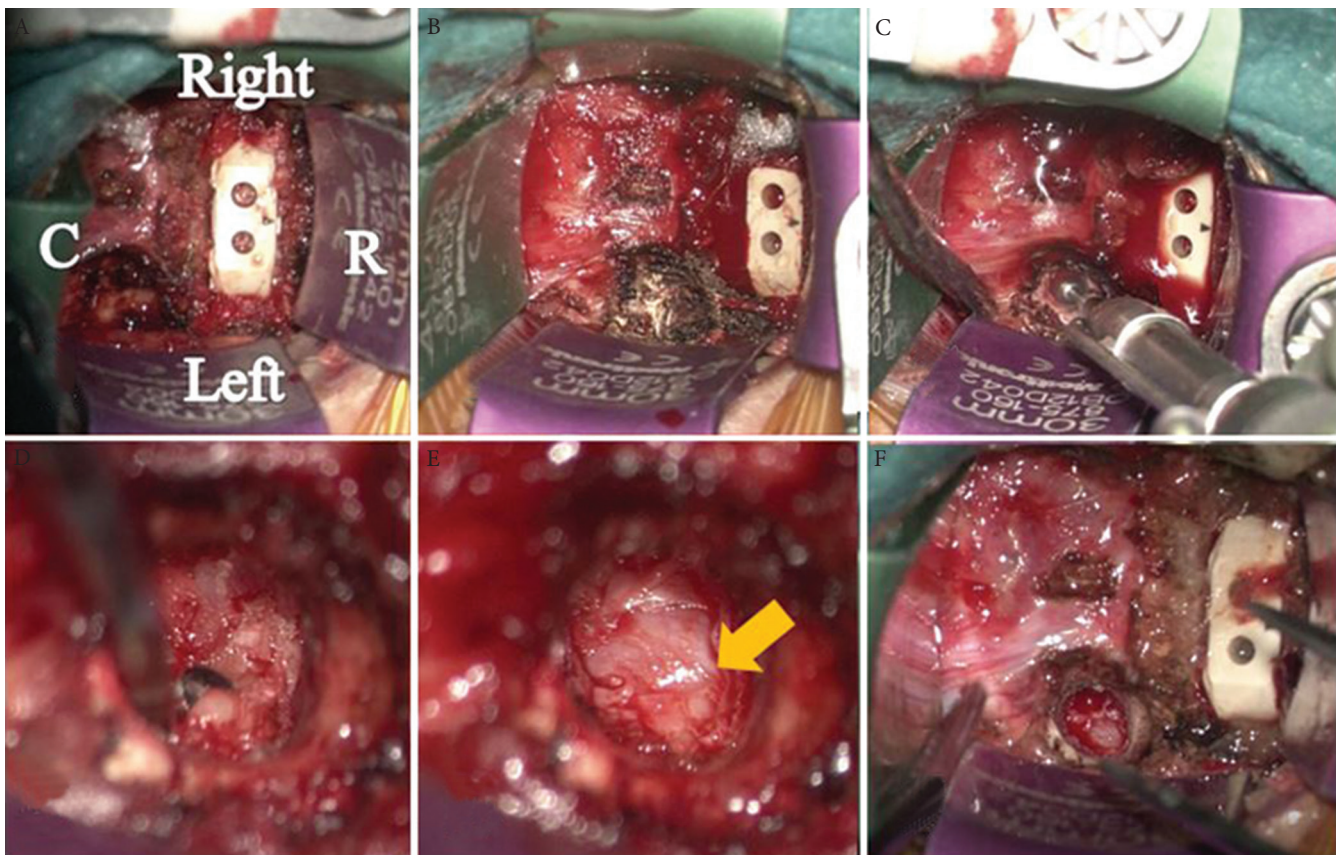


Fig. 1 Intraoperative pictures of the surgical field for anterior cervical decompression and fusion ACDF of the upper level and transvertebral foraminotomy (TVF) of the lower level. (R; rostral side, C; caudal side) (A) The ACDF procedure of the upper segment was completed with the self-retractor applied. (B) The starting point of drilling for the TVF at the lower level was confirmed and labeled by changing the direction of the microscope view, without needing to move the self-retractor. (C) A 6 × 6 mm drill hole was created at the caudo-lateral corner of the upper vertebra and the trajectory of the tunnel was oriented in a lateral and caudal direction to open the neural foramen. (D) The affected nerve root was decompressed using a micro curette. (E) Successful decompression of the affected nerve root (*arrow*) and restoration of CSF pulsation were confirmed after removal of the posterior longitudinal ligament and the herniated disc. (F) Final view of the surgical field after completion of all procedures.

Statistical analysis

All data were recorded as the mean \pm standard deviations (SD). Radiological data were analyzed using the paired *t*-test, with a *P*-value ≤ 0.05 considered statistically significant. All statistical analyses were performed using SPSS 22.0 statistics package (IBM Corporation, Armonk, NY).

Results

Patient demographics

Among the 22 patients, eight patients underwent ACDF at C4/5 combined with TVF at C5/6, 13 patients underwent ACDF at C5/6 combined with TVF at C6/7, and one patient underwent ACDF at C6/7 combined with TVF at C7/T₁. Therefore, the lower adjacent segment to the ACDF coincided with the level of TVF in all cases. The main cervical pathology

was disc herniation ($n = 9$), osteophyte secondary to cervical spondylosis ($n = 4$) and a combination of both lesions ($n = 9$) (Table 2).

Clinical outcome

Neurological symptoms improved immediately after surgery in all cases, with no surgical complications or postoperative neurological deficits resulting from adjacent segment disease. Based on Odom's criteria, clinical outcomes were excellent in nine patients, good in 10 patients, and fair in three patients, with no incidence of poor outcomes. The three patients with a fair outcome had developed significant motor weakness preoperatively secondary to spinal cord injury.

The JOA scores significantly improved from 13.8 ± 1.30 , preoperatively to 16.1 ± 0.83 at the final follow-up ($P < 0.01$), with an overall recovery rate of 70%.

Table 2 Outcomes

(a) Patient population ($n = 22$)			
Age (years)	55.8 (31–81)		
Sex (male:female)	15:7		
Average follow-up (months)	41.7 (8–84)		
	Number of patients		
ACDF levels			
C4/5	8		
C5/6	13		
C6/7	1		
TVF levels			
C5/6	8		
C6/7	13		
C7/T1	1		
Type of lesion at TVF segments			
Soft disc herniation	9		
Spondylotic osteophyte	4		
Soft disc with osteophyte	9		
(b) Radiographic results			
	Preoperative (mean \pm SD)	Final follow-up (mean \pm SD)	<i>P</i> -value**
C2-7 Cobb angle (CA)	9.6 \pm 10.6	10.9 \pm 9.3	0.7
Tilting angle (TA)			
Upper	0.6 \pm 3.6	0.7 \pm 3.9	0.87
Lower	2.8 \pm 4.1	3.5 \pm 5.0	0.37
ROM			
C2-7 CA	32.2 \pm 11.3	35.3 \pm 12.7	0.21
Upper	8.2 \pm 3.8	8.9 \pm 4.0	0.27
Lower	6.3 \pm 3.6	6.2 \pm 4.6	0.57
Disk height (DH)			
Upper	6.3 \pm 1.4	6.0 \pm 1.5	0.07
Lower	5.8 \pm 1.4	4.9 \pm 1.2	0.0002

*Upper: upper segment adjacent to the ACDF, lower: lower segment adjacent to the ACDF, coinciding with operated segments of TVF, **paired *t*-test. ACDF: anterior cervical decompression and fusion, ROM: range of motion, SD: standard deviation, TVF: transvertebral foraminotomy.

Radiological outcomes

The C2-7 CA changed from $9.6 \pm 10.6^\circ$ preoperatively to $10.9 \pm 9.3^\circ$ at final follow-up, and the ROM of the C2-7 CA changed from $32.2 \pm 11.3^\circ$ preoperatively to $35.3 \pm 12.7^\circ$ at final follow-up. Differences in C2-7 CA and ROM from preoperative baseline to the final follow-up were not statistically significant. The TA of the upper adjacent segment to the ACDF was changed from $0.6 \pm 3.6^\circ$ preoperatively to $0.7 \pm 3.9^\circ$ at final follow-up, while the TA of the lower adjacent segment increased from $2.8 \pm 4.1^\circ$ preoperatively to $3.5 \pm 5.0^\circ$ at final follow-up. There were no statistical differences in the TA of upper and lower adjacent segments between preoperative and final follow-up period. The ROM of the upper adjacent segments increased from $8.2 \pm 3.8^\circ$ preoperatively to $8.9 \pm 4.0^\circ$ at final follow-up, while the ROM of lower adjacent segments decreased from $6.3 \pm 3.6^\circ$ preoperatively to $6.2 \pm 4.6^\circ$ at final follow-up period. There were no significant differences in the ROM of upper and lower adjacent segments between preoperative and final follow-up period. The DH of the upper adjacent segment decreased from 6.3 ± 1.4 mm preoperatively to 6.0 ± 1.5 mm at final follow-up with a change in the DH of the lower adjacent segment from 5.8 ± 1.4 mm to 4.9 ± 1.2 mm. There was a statistically significant difference in the DH of the lower adjacent segment, but no significant difference in the DH of the upper adjacent segment. Based on the grading system of

Miyazaki et al., disc degeneration progressed in two patients, with the involvement of both the upper and lower adjacent segments to the ACDF in one case, and only the lower adjacent segment in the other case. However, there was no progression in the criterion of adjacent segment degeneration in either case (Table 3).

Illustrative case (Fig. 2)

A 46-year-old male presented with neck pain radiating into his right thumb and index finger as well as leg numbness. Neck and shoulder pain was exacerbated with neck extension. Physical examination revealed a positive Spurling's test, weakness of the right wrist extensor, increased patellar and Achilles tendon reflexes, bilaterally, and difficulty in ambulation. The MRI revealed a spinal cord compression at the level of C4/5 with a right foraminal stenosis at C5/6. Both compressions were deemed to be contributing to the patient's symptoms. The hybrid surgery of ACDF at the C4/5 level and TVF at the C5/6 level was successfully performed. His symptoms disappeared completely without detectable postoperative surgical complications.

Discussion

We achieved good clinical and radiological outcomes in the present study using the hybrid method for the treatment of single-level CSM and single-level CSR.

Table 3 Assessments of degeneration

	Upper segment		Lower segment	
	Preoperative	Final follow-up	Preoperative	Final follow-up
Number of cases on Miyazaki's grading system ($n = 22$)				
I, II	0	0	0	0
III	9	8	9	7
IV	13	14	13	15
V	0	0	0	0
Case of progression on Miyazaki's grading system				
Case 1 (grade)	(3)	(4)	(3)	(4)
Case 2 (grade)	(3)	(3)	(3)	(4)
Adjacent segment degeneration ($n = 22$)				
Postoperative 50% decrease of disc height	–	0	–	0
Plane radiographic degenerations*	1	1**	0	0
Spinal cord or nerve root compression on MRI	0	0	–***	0

*Vertebral osteophytes formation of more than 2 mm, anterior or posterior vertebral slip of more than 2 mm, **The same case with preoperative case, ***Affected segment.

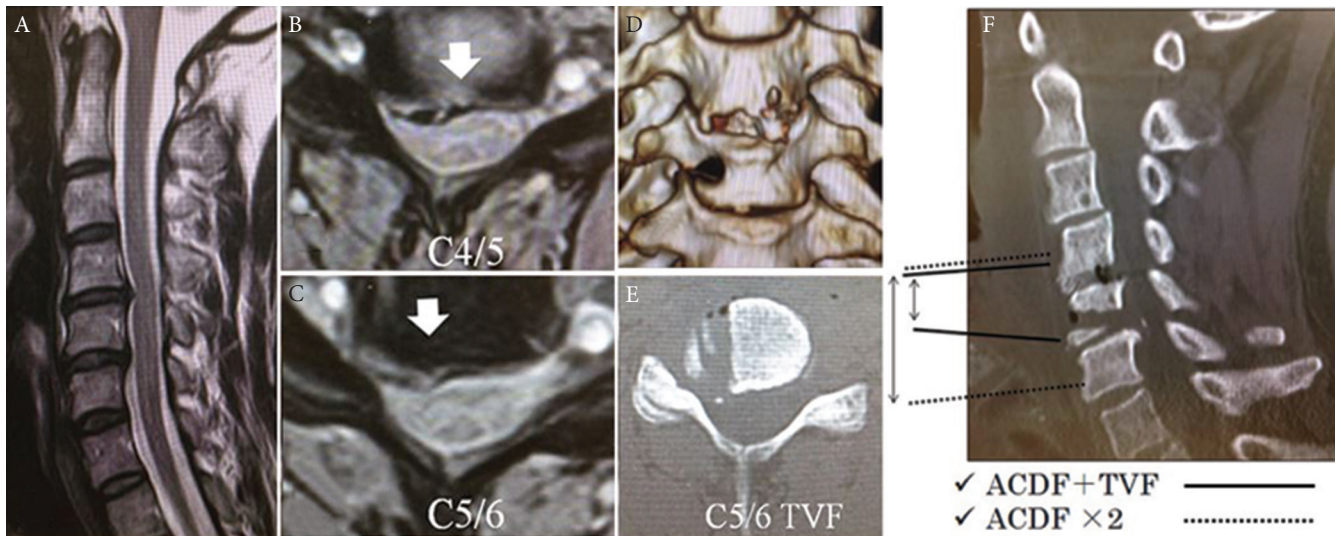


Fig. 2 (A)–(E): Case illustration of a 46-year-old male. The patient underwent successful anterior cervical decompression and fusion (ACDF) at C4/5 and transvertebral foraminotomy (TVF) on the right side at C5/6. Preoperative MRI [(A) T₂WI sagittal view, (B) and (C) T₂WI axial view] revealed a spinal canal stenosis at the C4/5 level and right foraminal stenosis at the C5/6 level. The combined ACDF at C4/5 and TVF at C5/6 were successfully performed. His symptoms disappeared completely, without detectable postoperative surgical complications. (F) Surgical field. The *dotted line* indicates the required range of exposure for two-level ACDF, with the *continuous line* indicates the exposure for a single-level ACDF and single-level TVF.

This combined technique provides several advantages in the treatment for multilevel cervical disease.

First, TVF makes it possible to reduce the number of fused segments. The number of fused segments should be as small as possible to reduce the risk of operative complications, especially pseudoarthrosis and adjacent segment disease.^{4,5,7–10} In the present study, there were no detectable surgical complications and no patients required redo surgery for pseudoarthrosis and adjacent segment disease. Although ACDF has been reported to be a highly successful procedure for CSM, Chien et al. reported a significant reduction in ROM in cases having two-level ACDF compared to those with single-level ACDF.²¹ They also described that the extent of reduction in ROM was correlating with the number of fused levels. In agreement with previous studies, we consider that reducing the number of fused segments could lower the risk of pseudoarthrosis, implant failure, and adjacent segment disease.^{4,7–10} Previous studies have revealed that fused segments increase biomechanical stress at adjacent levels,^{5,6} leading to acceleration of degenerative changes. In the present study, the reduction in DH of the lower adjacent segment to ACDF was statistically significant at final follow-up; however, the TA and TA ROM were well-maintained with no occurrence of adjacent segment disease. Preservation of the most part of disc materials, as well as anatomical structure of uncovertebral joint was considered to be attributable to maintained

cervical stability.^{22,23} Transsural foraminotomy is also a well-established and less invasive technique for CSR. However, transsural foraminotomy requires removal of uncovertebral joint.^{11,13} Uncovertebral joint should be preserved as much as possible because it works as a vital structure to maintain cervical stability.^{13,22,24} Therefore, we think that TVF is the most appropriate for CSR and safe surgical technique without causing spinal instability of the operated segment even as the operated segment coincided with the lower adjacent segment to ACDF. Although a small volume of vertebral body is drilled out in TVF, we have also reported preservation of biomechanical and radiological spinal stability after TVF.¹⁴ Given the results of our present study and previous reports, we conclude that TVF can be safely performed at the segment adjacent to the ACDF, though slow-progressive degeneration might occur over long-term follow-up.

Second, less soft tissue dissection is required for this hybrid method compared with a two-level ACDF. A two-level ACDF requires complete exposure of two-level disc spaces with three vertebral bodies, while the hybrid method needs exposure of a single-level disc space and two vertebral bodies (Fig. 2). More extensive dissection and retraction increase risk of postoperative hematoma, dysphagia, and recurrent laryngeal nerve palsy.^{8,10,25}

Third, the cost effectiveness of the hybrid method is obviously superior to two-level ACDF. Furthermore,

procurement of iliac bone is unnecessary because the amount of harvested local autograft is sufficient for a single-level ACDF.

An important aspect to obtain satisfactory result understands how to remove the compressive entity and contraindication of anterior cervical foraminotomy. Several different techniques of anterior cervical foraminotomy including transuncal foraminotomy have been advocated, most of which resulted in spontaneous unintentional bone fusion due to massive discectomy.¹¹⁾ Transuncal foraminotomy, the most widely-recognized anterior foraminotomy developed by Jho et al., required exposure of the vertebral artery and resection of the uncovertebral joint accompanied by potential risks of damage to the artery and the sympathetic chain as well as destabilization of the spine.^{13,24)} The modified anterior foraminotomy called TVF, which was described here overcome the shortcomings of Jho's transuncal foraminotomy since the drilling trajectory is placed more medially. Removal of osteophytes and disc herniations arising from the lateral corner of the disc space can be easily achieved through a drilling hole of only 6 mm in diameter under adequate microscopic magnification. As only a small amount of disc tissue is removed, the stability of the segment is maintained.

Although this study highlights the efficacy of our hybrid method for CSM and CSR, there are important limitations. Our analysis is based on a relatively small sample size and short-term follow-up period. We are planning comparative study between the hybrid method and multilevel ACDF or posterior cervical laminoplasty with or without foraminotomy.

In conclusion, the hybrid method of TVF combined with ACDF is less invasive and beneficial for reduction of the number of fused levels.

Acknowledgment

We are thankful to Dr. Hiroshi Yamada.

Conflicts of Interest Disclosure

None of the authors receive funding for this work. All authors who are members of the Japan Neurosurgical Society (JNS) have registered online self-reported COI disclosure statement forms through the website for JNS members.

References

- 1) Smith GW, Robinson RA: The treatment of certain cervical-spine disorders by anterior removal of the intervertebral disc and interbody fusion. *J Bone Joint Surg Am* 40: 607–624, 1958

- 2) Salvatore C, Orphee M, Damien B, Alisha R, Pavel P, Bernard G. Oblique *corpectomy* to manage cervical myeloradiculopathy. *Neurol Res Int* 2011: 734232, 2011
- 3) Sun Y, Li L, Zhao J, Gu R: Comparison between anterior approaches and posterior approaches for the treatment of multilevel cervical spondylotic myelopathy: A meta-analysis. *Clin Neurol Neurosurg* 134: 28–36, 2015
- 4) Kulkarni V, Rajshekhar V, Raghuram L: Accelerated spondylotic changes adjacent to the fused segment following central cervical corpectomy: magnetic resonance imaging study evidence. *J Neurosurg* 100: 2–6, 2004
- 5) Prasarn ML, Baria D, Milne E, Latta L, Sukovich W: Adjacent-level biomechanics after single versus multilevel cervical spine fusion. *J Neurosurg Spine* 16: 172–177, 2012
- 6) Carrier CS, Bono CM, Lebl DR: Evidence-based analysis of adjacent segment degeneration and disease after ACDF: a systematic review. *Spine J* 13: 1370–1378, 2013
- 7) Xu R, Bydon M, Macki M, et al.: Adjacent segment disease after anterior cervical discectomy and fusion: clinical outcomes after first repeat surgery versus second repeat surgery. *Spine* 39: 120–126, 2014
- 8) Veeravagu A, Cole T, Jiang B, Ratliff JK: Revision rates and complication incidence in single- and multilevel anterior cervical discectomy and fusion procedures: an administrative database study. *Spine J* 14: 1125–1131, 2014
- 9) Fraser JF, Härtl R: Anterior approaches to fusion of the cervical spine: a metaanalysis of fusion rates. *J Neurosurg Spine* 6: 298–303, 2007
- 10) Fountas KN, Kapsalaki EZ, Nikolakakos LG, Smisson HF, Johnston KW, Grigorian AA, et al.: Anterior cervical discectomy and fusion associated complications. *Spine* 32: 2310–2317, 2007
- 11) Jho HD: Microsurgical anterior cervical foraminotomy for radiculopathy: a new approach to cervical disc herniation. *J Neurosurg* 84: 155–160, 1996
- 12) Choi G, Lee SH, Bhanot A, Chae YS, Jung B, Lee S: Modified transcorporeal anterior cervical microforaminotomy for cervical radiculopathy: a technical note and early results. *Eur Spine J* 16: 1387–1393, 2007
- 13) Jho HD, Kim WK, Kim MH: Anterior microforaminotomy for treatment of cervical radiculopathy: part 1—disc-preserving “functional cervical disc surgery”. *Neurosurgery* 51: S46–S53, 2002
- 14) Umabayashi D, Hara M, Nakajima Y, Nishimura Y, Wakabayashi T: Transvertebral anterior cervical foraminotomy: midterm outcomes of clinical and radiological assessments including the finite element method. *Eur Spine J* 22: 2884–2890, 2013
- 15) Yamada H, Yamamoto H, Nakajima K, Nakajima M: [Anterior transvertebral key-hole microdiscectomy]. *Spine Surg* 10: 54–59, 1996 (Japanese)
- 16) Hirabayashi K, Miyakawa J, Satomi K, Maruyama T, Wakano K: Operative results and postoperative

- progression of ossification among patients with ossification of cervical posterior longitudinal ligament. *Spine* 6: 354–364, 1981
- 17) Miyazaki M, Hong SW, Yoon SH, Morishita Y, Wang JC: Reliability of a magnetic resonance imaging-based grading system for cervical intervertebral disc degeneration. *J Spinal Disord Tech* 21: 288–292, 2008
 - 18) Ishihara H, Kanamori M, Kawaguchi Y, Nakamura H, Kimura T: Adjacent segment disease after anterior cervical interbody fusion. *Spine J* 4: 624–628, 2004
 - 19) Hilibrand AS, Carlson GD, Palumbo MA, Jones PK, Bohlman HH: Radiculopathy and myelopathy at segments adjacent to the site of a previous anterior cervical arthrodesis. *J Bone Joint Surg Am* 81: 519–528, 1999
 - 20) Hara M: Anterior cervical root decompression for cervical radiculopathy: [Indication and limitation]. *Spine and Spinal Cord* 28: 782–790, 2015 (Japanese)
 - 21) Chien A, Lai DM, Wang SF, Hsu WL, Cheng CH, Wang JL: Comparison of cervical kinematics, pain, and functional disability between single- and two-level anterior cervical discectomy and fusion. *Spine* 41: E915–E922, 2016
 - 22) Kotani Y, McNulty PS, Abumi K, Cunningham BW, Kaneda K, McAfee PC: The role of anteromedial foraminotomy and the uncovertebral joints in the stability of the cervical spine. A biomechanical study. *Spine* 23: 1559–1565, 1998
 - 23) Chen TY, Crawford NR, Sonntag VK, Dickman CA: Biomechanical effects of progressive anterior cervical decompression. *Spine* 26: 6–13, 2001
 - 24) Hacker RJ, Miller CG: Failed anterior cervical foraminotomy. *J Neurosurg* 98: 126–130, 2003
 - 25) Apfelbaum RI, Kriskovich MD, Haller JR: On the incidence, cause, and prevention of recurrent laryngeal nerve palsies during anterior cervical spine surgery. *Spine* 25: 2906–2912, 2000
-
- Address reprint requests to:* Yu Yamamoto, MD, Department of Neurosurgery, Inazawa City Hospital, 100 Nazuka-cho, Inazawa, Aichi 492-8510, Japan.
e-mail: yu_yamamoto_yuhcho@yahoo.co.jp