

Ovarian cyst removal influences ovarian reserve dependent on histology, size and type of operation

Women's Health
January-December 2018: 1–5
© The Author(s) 2018
Reprints and permissions:
sagepub.co.uk/journalsPermissions.nav
DOI: 10.1177/1745506518778992
journals.sagepub.com/home/whe



Melanie Henes¹, Tobias Engler¹, Florin-Andrei Taran¹,
Sara Brucker¹, Katharina Rall¹, Birthe Janz²
and Barbara Lawrenz¹

Abstract

Previous publications suggest a reduction in the ovarian reserve following ovarian surgery. The influence of the underlying disease, histology, size of the ovarian cyst and type of procedure remains unclear. The aim of this study was to investigate the influence of an ovarian operation on the ovarian reserve, based on the anti-Müllerian hormone levels. The anti-Müllerian hormone values were determined by means of a standardized enzyme-linked immunosorbent assay. In total, 52 patients with one or more ovarian cysts of different histologic entities treated at the Department of Women's Health at the Women's University Hospital in Tübingen were included in the study. Anti-Müllerian hormone was determined before and after surgery. The patients were 28 (range = 18–40) years old on average. There was a statistically significant decrease in anti-Müllerian hormone from 3.94 ± 3.18 to 3.14 ± 2.57 ng/mL ($p = 0.001$). In 80.8%, the cysts were unilateral, and in over 90.4%, a complete cyst extirpation was performed. A statistically significant reduction was seen in follicular cysts (4.72 ± 3.84 to 3.76 ± 2.91 ng/mL; $p = 0.039$) and endometriosis cysts (2.55 ± 1.87 to 1.72 ± 1.39 ng/mL; $p = 0.024$). Also, the size of the cysts had an influence on the ovarian reserve, only larger ovarian cysts with a diameter of 5 cm or more showed a statistically significant reduction in anti-Müllerian hormone. Our data showed a significant decrease in anti-Müllerian hormone levels after surgery on the ovaries. If this results in a long-term reduced ovarian reserve or is merely a short-term reaction to the procedure needs to be clarified. However, concerning young women, the indication of surgery should be given cautiously as—at least temporarily—a reduction in the ovarian reserve can occur.

Keywords

Anti-Müllerian hormone, infertility, ovarian cyst, ovarian reserve, reproductive medicine, reproductive sciences

Date received: 24 May 2017; revised: 12 March 2018; accepted: 1 May 2018

Introduction

Ovarian cysts are a common finding in young women in their reproductive age. It is assumed that about 7% of women worldwide experience a symptomatic cyst during their lifetime.¹ Typically, simple, functional cysts are approached conservatively. However, symptoms, suspicious findings on ultrasound or a significant increase in size warrant an operative intervention. In addition, in cases in which a spontaneous remission is unlikely, as with organic ovarian cysts—that is, endometriosis or dermoid cysts—a surgical removal is the standard procedure. The gold standard is a laparoscopic ovarian cystectomy.²

Previous publications have shown a reduction in the ovarian reserve (OR) after an operative intervention on the ovaries.³ Still, the influence of the underlying cause,

¹Department of Gynecology and Obstetrics, University Hospital Tübingen, Tübingen, Germany

²University of Tübingen, Tübingen, Germany

Corresponding author:

Melanie Henes, Department of Gynecology and Obstetrics, University Hospital Tübingen, Calwerstrasse 7, 72076 Tuebingen, Germany.
Email: melanie.henes@med.uni-tuebingen.de



histology, size of cyst and operative procedure remains unclear. Therefore, there is no guideline when a surgical intervention is warranted and when a watch-and-wait approach is sufficient. In our study, the anti-Müllerian hormone (AMH) was used to evaluate the OR.

AMH is secreted by granulosa cells during the woman's fertile years. It reflects the remaining follicle pool and, therefore, is used as a marker for the OR. Its advantage over other fertility serum markers, such as follicle-stimulating hormone (FSH) or luteinizing hormone (LH), is its low variability throughout the menstrual cycle.⁴⁻⁶ Compared to the antral follicle count (AFC), which has a great inter-observer variability and dependency on the equipment, AMH is a more objective marker. Furthermore, it is a good marker for iatrogenic damage to the OR.⁷

The primary goal of this study was to investigate the influence of ovarian surgery on the OR. The AMH level acts as a surrogate marker for the primordial follicles in the ovaries and, thus, for the OR.

Methods

Serum samples of 52 patients were analyzed before and 1–2 weeks after a laparoscopic ovarian operation. All patients were recruited by our outpatient clinic and gave written informed consent. An approval from the ethics review board of the University Hospital Tübingen was obtained (ethics approval number 199/200BO2).

Inclusion criteria have been age between 18 and 40 years, no prior surgical intervention on the ovaries or fallopian tubes, a regular menstrual cycle, normal FSH and LH levels and the absence of malignancy in the postoperative histological examination. Patients with a history of endometriosis, sonographic findings suspicious for malignancy or a previous surgical procedure on the ovaries were excluded. Histologically, the following groups were distinguished:

- Dermoid cysts;
- Follicular cysts;
- Endometriosis cysts;
- Others such as cystadenomas.

The AMH was quantified using a standard enzyme-linked immunosorbent assay (ELISA; Beckman Coulter AMH Gen II, Brea, CA, USA; normal range=1–8 ng/mL) in duplicated samples. Levels <1 ng/mL were regarded as reduced and levels <0.4 ng/mL as strongly reduced OR. All patients were questioned about menstrual irregularities, lifestyle, obstetric data and contraception.

We calculated that a minimal total sample size of at least 45 patients would be necessary in a one-tailed test to demonstrate that the AMH is significantly reduced after surgery, with a statistical power of 95% and $\alpha=0.05$.

Statistical significance between groups was assessed by Student's t-test. To analyze the differences in a partial compared to a complete cyst removal, a between-within analysis of variance (ANOVA) was performed.

For statistical analysis, IBM SPSS 23 (IBM, Armonk, NY, USA) was used and $p < 0.05$ was considered statistically significant. For power calculation, we used G*Power 3.1.9.2 (Heinrich-Heine-Universität Düsseldorf).

Results

The median age was 28 (range=18–40) years. The mean number of children per women were 0.37 (0–3), and 15.3% of the patients had one to two miscarriages (mean=0.19 \pm 0.49). The median age at menarche was 13 (10–16) years.

The cysts occurred unilaterally in 80.8% (n=42) and bilaterally in 19.2% (n=10). In most patients, the cyst was completely removed (90.4%; n=47). Surgical fenestration of the cyst was performed in the other patients. There were 7 dermoid cysts (14%), 23 follicular cysts (44%), 8 endometriosis cysts (15%) and 14 other entities (27%). The AMH was on average 3.94 \pm 3.18 (0.06–14.65) ng/mL before surgery. A statistically significant reduction was shown to 3.14 \pm 2.57 (0.00–9.89) ng/mL ($p=0.001$) over all histologic entities (Figure 1; Table 1).

For an unilateral intervention, the mean reduction in the AMH was 0.54 ng/mL, and for a bilateral intervention, it was 1.91 ng/mL. The between-within-ANOVA shows a significant difference with the type of intervention ($p=0.019$).

A complete removal of the cyst reduced the AMH level from 3.88 \pm 2.86 to 3.14 \pm 2.54 ng/mL by 0.74 ng/mL. The operative fenestration reduced the level from 4.53 \pm 5.81 to 3.12 \pm 3.11 ng/mL by 1.41 ng/mL. It has to be kept in mind that the procedure of an operative fenestration was only performed in patients where a complete cyst removal would have impeded a complete loss of the ovary due to an unfavorable relation of the cyst size to the functional ovarian tissue. Only larger ovarian cysts with a diameter of 5 cm or more showed a statistically significant reduction in AMH from 3.87 \pm 3.02 ng/mL before to 2.75 \pm 1.98 ng/mL after the operation ($p=0.002$). In comparison, cysts smaller than 5 cm had a reduction in the AMH from 4.02 \pm 3.41 to 3.60 \pm 3.10 ng/mL ($p=0.193$; Figure 2).

Regarding the histological type, only follicular cysts (4.72 \pm 3.84 to 3.76 \pm 2.91 ng/mL; $p=0.039$) and endometriosis cysts (2.55 \pm 1.87 to 1.72 \pm 1.39 ng/mL; $p=0.024$) showed a significant drop in the AMH levels. Whereas dermoid cysts (3.75 \pm 3.18 to 3.18 \pm 3.06 ng/mL; $p=0.282$) and other cysts (3.56 \pm 2.36 to 2.91 \pm 2.03 ng/mL; $p=0.143$) showed no significant reduction in AMH (Figure 3). Indication for follicular cyst removal was only given in symptomatic patients.

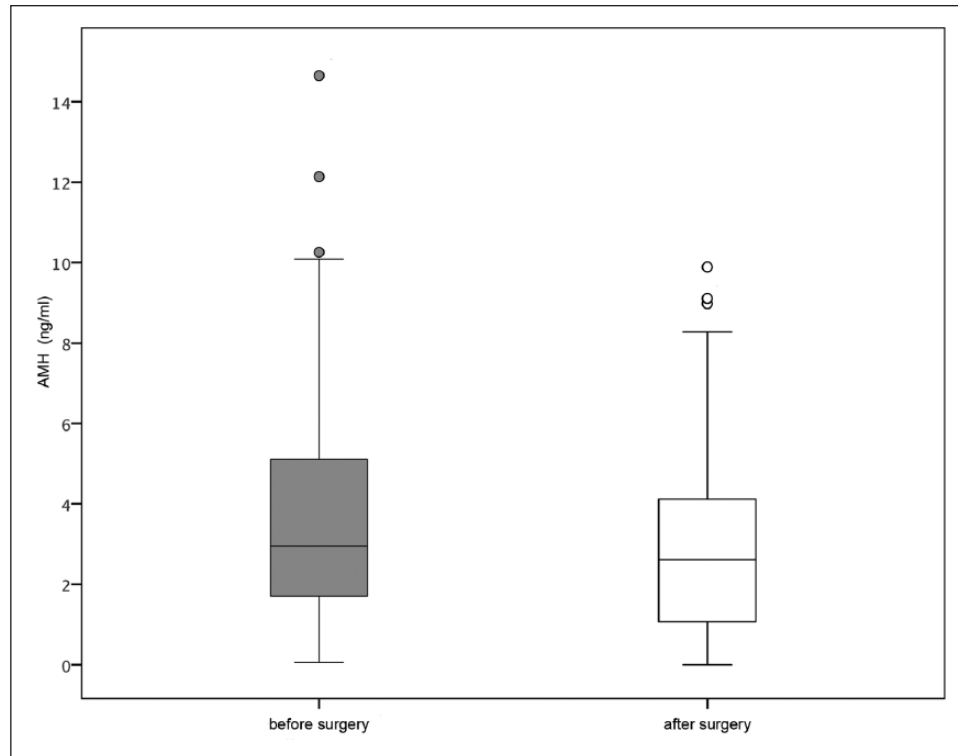


Figure 1. Box plot showing mean AMH levels before (gray) and after (white) surgery. Box plot explanation: upper horizontal line of box: 75th percentile; lower horizontal line of box: 25th percentile; horizontal bar within box: mean; upper horizontal bar outside box: 90th percentile and lower horizontal bar outside box: 10th percentile. Circles represent outliers.

Table. Mean levels of AMH before and after surgery divided into localization, size and histology.

	N	Mean AMH before surgery (ng/mL)	Mean AMH post surgery (ng/mL)	p value
Total	52	3.94 (\pm 3.18)	3.14 (\pm 2.57)	p=0.001
Localization				
Unilateral	42	3.88 (\pm 3.25)	3.34 (\pm 2.63)	p=0.032
Bilateral	10	4.21 (\pm 3.00)	2.30 (\pm 2.18)	p=0.001
Size				
>5 cm	28	3.87 (\pm 3.02)	2.75 (\pm 1.98)	p=0.002
<5 cm	24	4.02 (\pm 3.41)	3.60 (\pm 3.10)	p=0.193
Histology				
Follicular cysts	23	4.72 (\pm 3.84)	3.76 (\pm 2.91)	p=0.039
Endometriosis cysts	8	2.55 (\pm 1.87)	1.72 (\pm 1.39)	p=0.024
Dermoid cysts	7	3.75 (\pm 3.18)	3.18 (\pm 3.06)	p=0.282
Other cysts	14	3.55 (\pm 2.36)	2.91 (\pm 2.03)	p=0.143

AMH: anti-Müllerian hormone.

Discussion

Our study shows a significant decrease in OR after laparoscopic cystectomy, evaluated by means of AMH levels. We decided on AMH as a surrogate marker for OR, as it is independent from the menstrual cycle^{4,5} and seems not to be affected by the use of hormones.⁸ This has already been proven in earlier studies.^{3,6,7} The aim of this study was to

investigate the influence of histology and localization (unilateral or bilateral) on the OR.

First of all, we showed a statistically significant decrease in AMH over all patients with p=0.001. This has already been shown in a meta-analysis of Raffi et al.⁹ We also showed that a bilateral cystectomy was statistically associated with a significant reduction in AMH levels and therefore of OR. This fact was already shown in the work

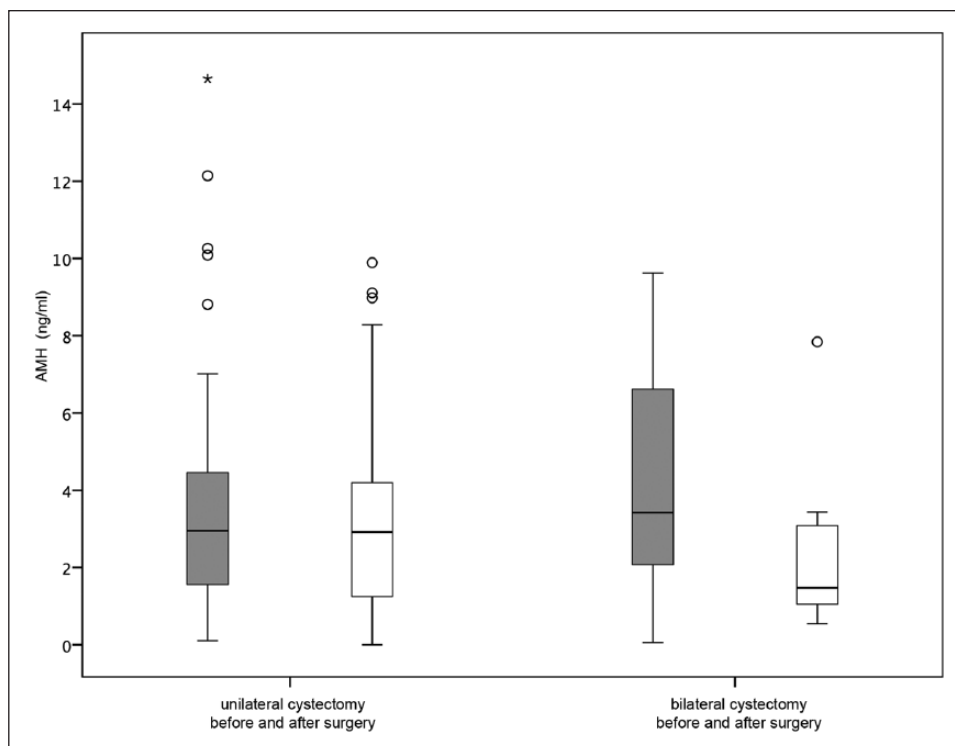


Figure 2. Box plot showing mean AMH levels before (gray) and after (white) surgery for unilateral and bilateral cystectomy.

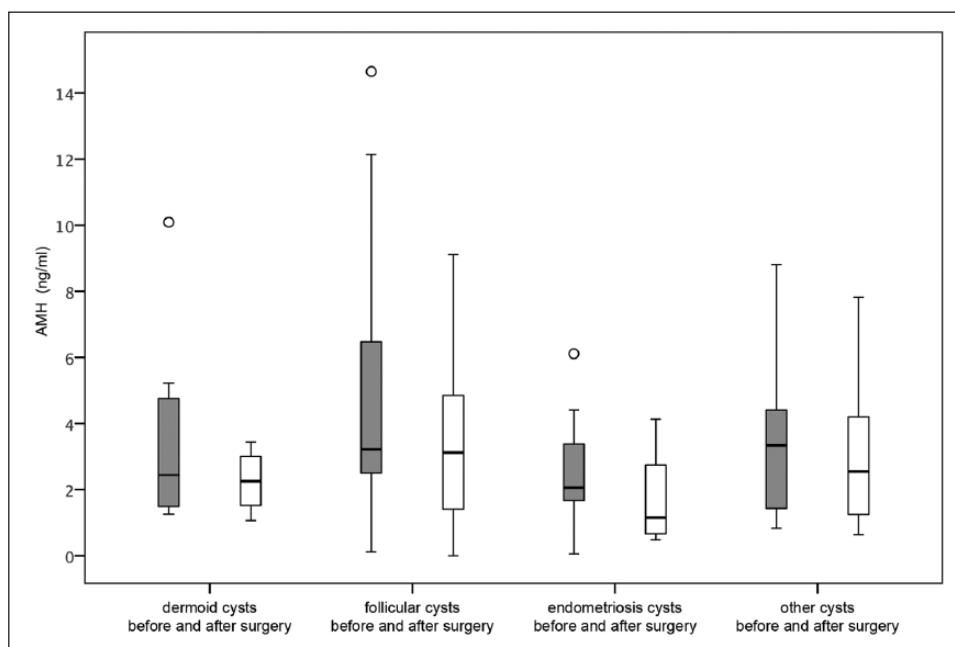


Figure 3. Box plot showing mean AMH levels before (gray) and after (white) surgery differentiated by histologic groups.

of Kwon et al.¹⁰ and in the study of Mehdizadeh Kashi et al.,¹¹ which especially focused on unilateral and bilateral endometriomas. This also applied to the size of the cysts in our study. If the diameter of the ovarian cyst was more than 5 cm, the decrease in the AMH was significantly

higher than in cysts with a diameter smaller than 5 cm. Again this was already shown for endometriomas by Mehdizadeh Kashi et al.¹¹ Chen et al.¹² described the greatest influence on OR when the cysts were bilateral and larger than 7 cm in patients with endometrioma.

All together, the potential reduction in fertility seems to be higher in bilateral cystectomy and larger cysts and therefore might be depended on the extent of the ovarian damage. A differentiation in histologic groups also showed a statistically significant reduction in OR for the endometriosis cysts and the follicular cysts. This influence on histology, especially of endometriosis cysts, has also been shown in other studies.

Another point to consider is the influence of the experience of the surgeon. A study by Muzii and colleagues^{13,14} found that the level of expertise is inversely correlated with an inadvertent damage of healthy ovarian tissue. At our hospital, all surgeons are part of our center of endometriosis and therefore very well experienced in laparoscopic surgeries; so, there should be only limited negative impact in this cohort.

In our study, AMH levels were only measured right before and in a range of 2 weeks after an operation. Other studies, for example, by Shebl et al.,¹⁵ in patients with polycystic ovary (PCO) syndrome and “ovarian-drilling” showed that AMH levels returned to their initial level 6 months after surgery,¹⁴ raising the question whether the AMH value reflects only the growing follicles and not the complete follicle pool. Another explanation to the recovering AMH could be the de novo synthesis of mitotically active germ cells replenishing the follicle pool.¹⁶ It therefore remains to be clarified whether the reduction in OR is due to a reduction in the ovarian tissue or a reaction to the operative procedure. This was not part of this study.

The relatively small number of patients and the heterogeneity limit somehow our findings, especially with regard to the significance in some subgroup analysis. But all together, our results go in line with other studies and meta-analysis and therefore underline the importance of a careful decision on surgical cyst resection in women in their reproductive age, especially in patients with functional cysts, as they might regress in many cases spontaneously. At our hospital, we are very cautious regarding resection of functional cysts; all of the included patients were symptomatic and refractory to conservative treatment. Every indication for a surgical procedure, especially in young women during their reproductive age, should be given carefully and organ preserving operation should be favored, as a reduction in the OR may occur. This is of immense importance, particularly in times of large-scale laparoscopic cystectomies with the accompanying criticism of overtreatment. Especially, young women with a potential desire to have children should be confronted with these findings and a non-surgical approach must be discussed—if possible.

Declaration of conflicting interests

The author(s) declared no potential conflicts of interest with respect to the research, authorship and/or publication of this article.

Funding

The author(s) received no financial support for the research, authorship and/or publication of this article.

References

1. Farghaly SA. Current diagnosis and management of ovarian cysts. *Clin Exp Obstet Gynecol* 2014; 41(6): 609–612.
2. Schindler A. Ovarialzysten—Diagnostik und Therapie. *Frauenarzt* 2005; 46: 132–134.
3. Chang H, Han S, Lee J, et al. Impact of laparoscopic cystectomy on ovarian reserve: serial changes of serum anti-Müllerian hormone levels. *Fertil Steril* 2010; 94: 343–349.
4. Visser JA, De Jong FH, Laven J, et al. Anti-Müllerian hormone: a new marker for ovarian function. *Reproduction* 2006; 131: 1–9.
5. Sowers M, McConnell D, Gast K, et al. Anti-Müllerian hormone and inhibin B variability during normal menstrual cycles. *Fertil Steril* 2010; 94: 1482–1486.
6. Chun S, Cho HJ and Ji YI. Comparison of early postoperative decline of serum anti-Müllerian hormone levels after unilateral laparoscopic ovarian cystectomy between patients categorized according to histologic diagnosis. *Taiwan J Obstet Gynecol* 2016; 55(5): 641–645.
7. Dewally D, Andersen CY, Balen A, et al. The physiology and clinical utility of anti-Müllerian hormone in women. *Hum Reprod Update* 2014; 20(3): 370–385.
8. Van Rooij IA, Broekmans FJ, Te Velde ER, et al. Serum anti-Müllerian hormone levels: a novel measure of ovarian reserve. *Hum Reprod* 2002; 17: 3065–3071.
9. Raffi F, Metwally M and Amer S. The impact of excision of ovarian endometrioma on ovarian reserve: a systematic review and meta-analysis. *J Clin Endocrinol Metab* 2012; 97: 3146–3154.
10. Kwon SK, Kim SH, Yun SC, et al. Decline of serum anti-Müllerian hormone levels after laparoscopic ovarian cystectomy in endometrioma and other benign cysts: a prospective cohort study. *Fertil Steril* 2014; 101(2): 435–441.
11. Mehdizadeh Kashi A, Chaichian S, Ariana S, et al. The impact of laparoscopic cystectomy on ovarian reserve in patients with unilateral and bilateral endometrioma. *Int J Gynaecol Obstet* 2017; 136(2): 200–204.
12. Chen Y, Pei H, Chang Y, et al. The impact of endometrioma and laparoscopic cystectomy on ovarian reserve and the exploration of related factors assessed by serum anti-Müllerian hormone: a prospective cohort study. *J Ovarian Res* 2014; 267: 108.
13. Muzii L, Marana R, Angioli R, et al. Histologic analysis of specimens from laparoscopic endometrioma excision performed by different surgeons: does the surgeon matter? *Fertil Steril* 2011; 95(6): 2116–2119.
14. Muzii L, Bianchi A, Crocè C, et al. Laparoscopic excision of ovarian cysts: is the stripping technique a tissue-sparing procedure? *Fertil Steril* 2002; 77(3): 609–614.
15. Shebl O, Sommergruber M, Ebner T, et al. Serum AMH levels in women with PCOS. In: *Proceedings of the annual meeting of the Austrian society of obstetrics & gynecology*, Dublin, 27 November 2009.
16. Johnson J, Canning J, Kaneko T, et al. Germline stem cells and follicular renewal in the postnatal mammalian ovary. *Nature* 2004; 428: 145–150.