

This is an Open Access article licensed under the terms of the Creative Commons Attribution-NonCommercial-NoDerivs 3.0 License ([www.karger.com/OA-license](http://www.karger.com/OA-license)), applicable to the online version of the article only. Distribution for non-commercial purposes only.

# Primary Gastrointestinal Diffuse Large B Cell Lymphoma Presenting with Cold Agglutinin Disease

Ahmet Emre Eskazan<sup>a</sup> Hamida Akmurad<sup>b</sup> Seniz Ongoren<sup>a</sup>  
Ozden Ozer<sup>c</sup> Burhan Ferhanoglu<sup>a</sup>

<sup>a</sup>Department of Internal Medicine, Division of Hematology, and <sup>b</sup>Department of Internal Medicine, Istanbul University Cerrahpasa Faculty of Medicine, and <sup>c</sup>Istanbul Pathology Group, Istanbul, Turkey

## Key Words

Diffuse large B cell lymphoma · Cold agglutinin disease · Gastrointestinal involvement

## Abstract

Cold agglutinin disease (CAD) is an autoimmune hemolytic anemia (AIHA) generally caused by IgM autoantibodies which exhibit maximal reactivity at 4°C. CAD can be idiopathic or secondary to some diseases and/or conditions. Only a minority of cases of secondary AIHA in non-Hodgkin's lymphoma (NHL) are associated with cold antibodies. Diffuse large B cell lymphoma (DLBCL) is the most common subtype of NHLs with a proportion of nearly 30% of all adult cases. 40% of patients with DLBCL have an extranodal disease or at least disease initially confined to extranodal sites. The most common extranodal site is the gastrointestinal tract. We present a patient with primary gastrointestinal DLBCL who presented with CAD and was treated with a CHOP-Rituximab regimen.

## Introduction

Autoimmune hemolytic anemia (AIHA) is a term used for anemias caused by destruction of erythrocytes by antibodies that are directed against membrane antigens of the patients' red blood cells (RBCs). Among all kinds of anemias, AIHA is an uncommon form. Even among the groups of hemolytic anemias, AIHA is not the most common variant and no more than 5–10 patients with AIHA per year are diagnosed [1]. The majority of AIHA cases are mediated by warm-reactive autoantibodies, i.e. antibodies displaying optimal reactivity with human RBCs at 37°C and which are usually of the IgG immunoglobulin class. In contrast, cold agglutinin disease (CAD) is generally caused by IgM autoantibodies which exhibit maximal reactivity at 4°C. CAD can be idiopathic or

secondary to some diseases and/or conditions (e.g. *Mycoplasma pneumoniae* infection, infectious mononucleosis, other viral infections or malignant diseases such as lymphoproliferative disorders). Only a minority of cases of secondary AIHA in non-Hodgkin's lymphoma (NHL) are associated with cold antibodies. In a cohort of 370 patients with NHL, 1.1% had cold reacting antibodies [2]. Diffuse large B cell lymphoma (DLBCL) is the most common subtype of NHLs with a proportion of nearly 25–30% of all adult cases [3]. 40% of patients with DLBCL have extranodal disease or at least disease initially confined to extranodal sites [4]. The most common extranodal site is the gastrointestinal tract. We present a patient with primary gastrointestinal DLBCL who presented with CAD.

### Case Report

A 46-year-old otherwise healthy female patient was admitted to the outpatient clinic of our hematology department with fatigue and anemia in November 2010. Before that she saw another physician and her hemoglobin (Hb) level was found to be 9.8 g/dl; a diagnosis of iron deficiency anemia was made and she was put on oral iron replacement therapy. Since her complaints did not resolve and her Hb level decreased to 4.8 g/dl, she was admitted to our institution. Physical examination revealed paleness in the mucous membranes and subicterus; no peripheral lymphadenopathy or organomegaly was detected. The interesting thing about her complete blood count was that her hematocrit (Hct) was discordant with her Hb level (Hb: 4.8 g/dl; Hct: 9%) and she had a high mean corpuscular volume of 115.7 fl, mean cell Hb of 64.3 pg and mean cell Hb concentration of 55.6 g/dl with automated counter. White blood cell and platelet counts were normal. Agglutination was seen in anticoagulated blood at room temperature and disappeared upon warming the blood to 37°C; repeating the complete blood count after warming the blood avoided this problem. Peripheral blood smear revealed RBC clumps. Her reticulocyte was as high as 16% and direct antibody (Coombs) test was positive, so AIHA and CAD was thought to be the diagnosis. Cold agglutinin test was found to be positive with a titer of 1/2,560 and cryoglobulinemia was excluded. In her blood chemistry lactate dehydrogenase was 520 U/l (normal 125–243), indirect bilirubin was 2.76 mg/dl and haptoglobin level was low. Serum protein electrophoresis and serum immunoglobulin levels were normal.

80 mg/day methylprednisolone with folic acid replacement therapy was initiated. Epstein-Barr virus, cytomegalovirus, herpes simplex virus, hepatitis B and C viruses as well as human immunodeficiency virus were serologically negative and serology for *Mycoplasma pneumoniae* was also found to be negative. She had no signs of arthritis, Raynaud phenomenon or any other rheumatological diseases. Thoracic and abdominal computed tomography (CT) was done in order to exclude lymphoproliferative disorders. Thoracic CT was normal whereas abdominal CT revealed increased wall thickness in a segment of the terminal ileum. There were also mesenteric and paraaortic lymphadenopathies 20 mm in diameter. A colonoscopy was performed, a mass in the lumen of terminal ileum was detected and a biopsy was taken (fig. 1). Histopathological evaluation of the biopsy specimen was consistent with DLBCL. Positron emission tomography-computed tomography (PET-CT) showed an increased uptake of F-18 fluorodeoxyglucose (FDG) in the terminal ileum (fig. 2). Bone marrow infiltration was detected and there were no complaints of B symptoms, so the patient was staged as IVAE disease with an international prognostic index score of 2. CHOP (cyclophosphamide 750 mg/m<sup>2</sup>/day D<sub>1</sub>, Adriamycin 50 mg/m<sup>2</sup>/day D<sub>1</sub>, vincristine 2 mg/day D<sub>1</sub> and methylprednisolone 80 mg/day D<sub>1–5</sub>) chemotherapy with Rituximab 375 mg/m<sup>2</sup>/day D<sub>1</sub> (R-CHOP) was initiated. After administering the chemotherapy, her Hb and Hct levels gradually increased and the hemolysis resolved in the following days; after the second course of R-CHOP she was discharged from the hospital.

### Discussion

AIHA may be associated with either IgG antibodies which react with the RBC surface at warm temperature or with (usually) IgM antibodies which react below body temperature. The latter are therefore named 'cold agglutinins'. Cold agglutinins are IgM

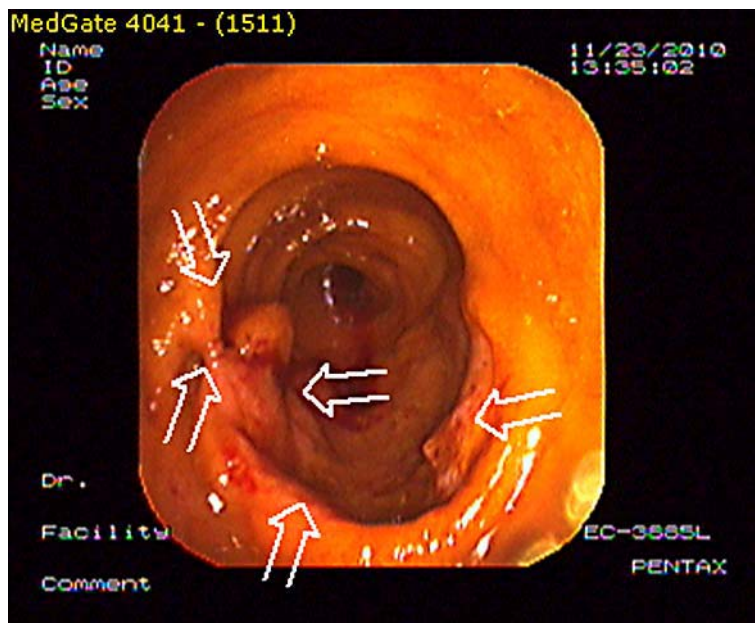
antibodies reacting with untreated adult red cells (anti-I) or reacting with fetal or cord red cells (anti-i). CAD accounts for 13–15% of cases of AIHA [5]. CAD can be primary or cold agglutinins are produced either in response to infection or secondary to neoplastic growth of a single B cell clone. Economopoulos et al. reviewed 370 patients with NHL and found that 23 (6.2%) had AIHA, 4 of whom (1.1%) had cold reacting antibodies [2]. Sallah et al. published characteristics of 16 patients with NHL and AIHA out of a cohort of 501 patients, of whom 3 had CAD and only 1 had a diagnosis of DLBCL [6]. 25 patients with high-grade NHL and AIHA were demonstrated in the literature, 22 of them had DLBCL [7]. Berentsen et al. found 76% of patients with chronic CAD to have underlying lymphoma and most of the cases were lymphoplasmacytic lymphoma, marginal zone lymphoma and small lymphocytic lymphoma/chronic lymphocytic leukemia [8]. About 3.5% of patients with CAD and indolent NHL progressed to DLBCL within a median observation time of 5 years. This was not the scenario in our patient because she did not have a diagnosis of low-grade lymphoma before the diagnosis of DLBCL was made.

DLBCL presenting with CAD is a rare entity. The association of CAD with extranodal presentations of NHL has been characterized [8]. Airaghi et al. published a patient with DLBCL with adrenal and renal involvement and CAD [9]. Another DLBCL patient with gastrointestinal involvement and CAD was published in the literature before [10], but he had extensive disease with gastrointestinal involvement and bone marrow infiltration with hemophagocytic syndrome and polyneuropathy, and the diagnosis was made postmortem. Our patient also had gastrointestinal involvement and bone marrow infiltration, but neither hemophagocytosis nor polyneuropathy was detected. Níáinle et al. published a DLBCL patient with nodal disease, bone marrow involvement and CAD [11], and a DLBCL case with isolated bone marrow involvement and cold agglutinins was described before [12]. Our patient had no nodal disease, only a mass in the terminal ileum, and although lymph nodes were detected by abdominal CT, they did not show FDG uptake on PET-CT. Since in secondary CAD the underlying disease should be promptly treated, we started R-CHOP in order to overwhelm the clinical picture.

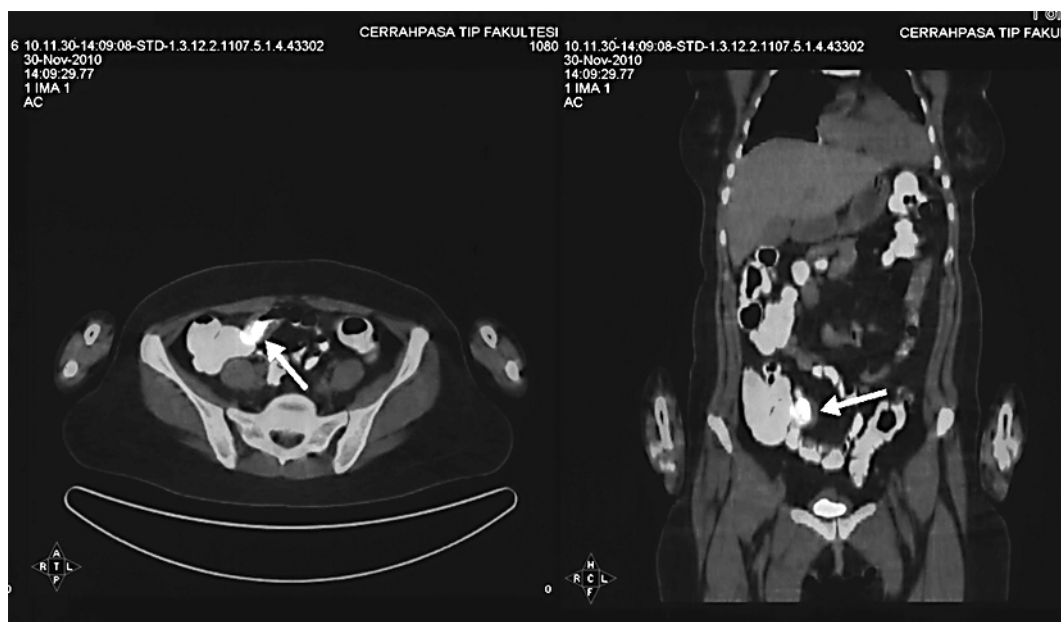
In conclusion, CAD accounts for 15% of cases of AIHA and most of the cases are chronic lymphocytic leukemia and lymphoma (most commonly low-grade NHLs). The association between CAD and DLBCL is rare, extranodal DLBCL with cold agglutinins is even rarer. Here we present a case of DLBCL with gastrointestinal and bone marrow involvement and CAD. To our knowledge, our case is the only reported case of CAD in a patient with primary gastrointestinal involvement of DLBCL.

#### Disclosure Statement

None of the authors has any conflict of interest to declare.



**Fig. 1.** Colonoscopy was performed and a mass in the lumen of the terminal ileum was detected.



**Fig. 2.** PET-CT showed an increased FDG uptake in the terminal ileum.

## References

- 1 Franco-Garcia E, Giraldo P, Bernal M, et al: Which are the true incidence rates of primary hematological disorders acquired in our population? *Sangre (Barc)* 1998;43:356–364.
- 2 Economopoulos T, Stathakis N, Constantinidou M, et al: Cold agglutinin disease in non-Hodgkin's lymphoma. *Eur J Haematol* 1995;55:69–71.
- 3 Stein H, Warnke RA, Chan WC, et al: Diffuse large B-cell lymphoma, not otherwise specified; in Swedlow SH, Campo E, Harris NL, Jaffe ES, Pileri SA, Stein H, Thiele J, Vardiman JW (eds): *WHO Classification of Tumours of Haematopoietic and Lymphoid Tissues*, ed 4. Lyon, IARC, 2008, pp 233–237.
- 4 Harris NL, Jaffe ES, Stein H, et al: A revised European-American classification of lymphoid neoplasms: a proposal from the International Lymphoma Study Group. *Blood* 1994;84:1361–1392.
- 5 Genty I, Michel M, Hermine O, et al: Characteristics of autoimmune hemolytic anemia in adults: retrospective analysis of 83 cases (in French). *Rev Med Interne* 2002;23:901–909.
- 6 Sallah S, Sigounas G, Vos P, et al: Autoimmune hemolytic anemia in patients with non-Hodgkin's lymphoma: characteristics and significance. *Ann Oncol* 2000;11:1571–1577.
- 7 Hauswirth AW, Skrabs C, Schützinger C, et al: Autoimmune hemolytic anemias, Evans' syndromes, and pure red cell aplasia in non-Hodgkin lymphomas. *Leuk Lymphoma* 2007;48:1139–1149.
- 8 Berentsen S, Ulvestad E, Langholm R, et al: Primary chronic cold agglutinin disease: a population based clinical study of 86 patients. *Haematologica* 2006;91:460–466.
- 9 Airaghi L, Greco I, Carrabba M, et al: Unusual presentation of large B cell lymphoma: a case report and review of the literature. *Clin Lab Haematol* 2006;28:338–342.
- 10 Takai K, Sanada M, Shibuya H: Anti-Pr2 cold agglutinin disease with polyneuropathy evolving to malignant lymphoma (in Japanese). *Rinsho Ketsueki* 1992;33:1231–1236.
- 11 Níainle F, Hayden PJ, Crosby P, et al: Concurrent arrangement of BCL1 and BCL6 with a single immunoglobulin locus in a case of diffuse large B-cell lymphoma. *Leuk Lymphoma* 2006;47:2655–2656.
- 12 Níainle F, Hamnvik OP, Gulmann C, et al: Diffuse large B-cell lymphoma with isolated bone marrow involvement presenting with secondary cold agglutinin disease. *Int J Lab Hematol* 2008;30:444–445.