

Received: 2015.04.26  
Accepted: 2015.05.10  
Published: 2015.05.31

ISSN 1941-5923  
© Am J Case Rep, 2015; 16:328-332  
DOI: 10.12659/AJCR.894463

## Primary Neuroendocrine Tumor (Carcinoid Tumor) of the Testis: A Case Report with Review of Literature

Authors' Contribution:  
Study Design A  
Data Collection B  
Statistical Analysis C  
Data Interpretation D  
Manuscript Preparation E  
Literature Search F  
Funds Collection G

ABCDEFG 1 **Sandeep Singh Lubana**  
BEF 1 **Navdeep Singh**  
AEF 2 **Hon Cheung Chan**  
ADE 3 **David Heimann**

1 Department of Internal Medicine, Icahn School of Medicine at Mount Sinai, Queens Hospital Center, Queens, NY, U.S.A.  
2 Department of Medical Hematology-Oncology, Icahn School of Medicine at Mount Sinai, Queens Hospital Center, Queens, NY, U.S.A.  
3 Department of Surgical Oncology, Icahn School of Medicine at Mount Sinai, Queens Hospital Center, Queens, NY, U.S.A.

**Corresponding Author:** Sandeep Singh Lubana, e-mail: [Sandeep\\_singh6517@yahoo.com](mailto:Sandeep_singh6517@yahoo.com)  
**Conflict of interest:** None declared

**Patient:** Male, 34  
**Final Diagnosis:** Primary neuroendocrine tumor of the testis  
**Symptoms:** Pain • swelling  
**Medication:** None  
**Clinical Procedure:** Radical orchiectomy  
**Specialty:** Oncology

**Objective:** Rare disease

**Background:** The term carcinoid (Karzinoide) was coined by German pathologist Oberndorfer in 1907. Primary testicular carcinoid tumors (TCT) are rare, constituting 0.23% of all testicular tumors. In this report we describe a case of primary TCT of the testis and present the results of an extensive literature review to cover all the aspects of carcinoid tumor, including the definition, classification, origin, presentation, diagnostic evaluation, management, prognosis, and follow-up.

**Case Report:** A 34-year-old male presented with chronic right scrotal swelling with recent onset of pain. Radical orchiectomy revealed a solid intratesticular tumor confined to the testis and epididymis, without lymphovascular invasion. Histology was consistent with neuroendocrine carcinoma. The tumor was staged as pT1 N0 M0 S2. Immunohistochemistry was positive for neuroendocrine markers. An extratesticular carcinoid tumor was ruled out. Urinary excretion of 5-hydroxyindoleacetic acid and Chromogranin A were within normal range.

**Conclusions:** It is important to follow serotonin levels since the elevated levels of serotonin can cause carcinoid heart disease. If metastatic lesions are not accessible for resection, a trial of octreotide therapy can be given. This case also adds to the rare reports in the literature of primary carcinoid tumors of the testis having low malignant potential. The literature review highlights new diagnostic and therapeutic interventions and stresses the importance of long-term follow-up due to evidence of delayed metastasis or recurrences and also due to emergence of new complications as a result of improved prognosis and prolonged survival.

**MeSH Keywords:** Carcinoid Heart Disease • Carcinoid Tumor • Hydroxyindoleacetic Acid • Orchiectomy


**Full-text PDF:** <http://www.amjcaserep.com/abstract/index/idArt/894463>



2069



3



23



## Background

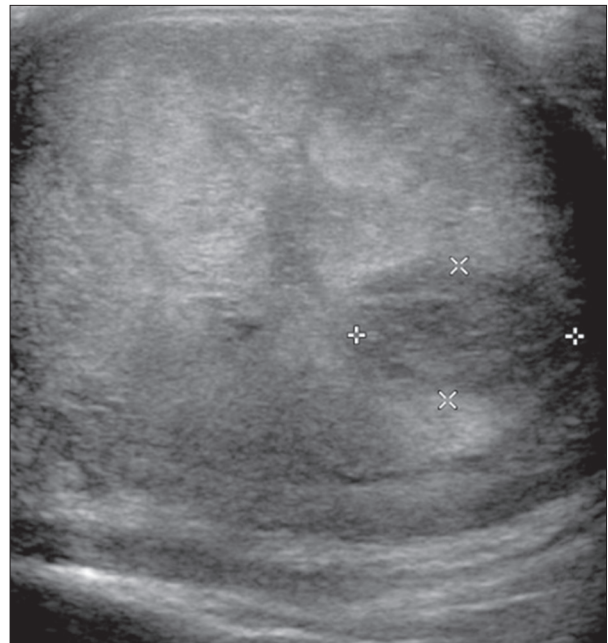
Neuroendocrine tumors were first described by Langhans in 1867 [1]. The term carcinoid (Karzinoide) was coined by German pathologist Oberndorfer in 1907. Cope in 1930 described the first case of metastatic carcinoid tumor metastasized from small bowel [2]. In 1954, Simon et al. reported the first case of primary testicular carcinoid [3]. Primary testicular tumors are rare, constituting 0.23% of all testicular tumors. Testicular carcinoid tumors (TCT) have a mean age at presentation of 46 years (10–83 years) [4]. Although since 1930 more than 60 cases of testicular carcinoid have been reported, it still remains a very rare diagnosis. In this report we describe a primary testicular carcinoid tumor of the testis and present an extensive literature review to cover all the aspects of carcinoid tumor including the definition, classification, origin, presentation, diagnostic evaluation, management, prognosis, and follow-up.

## Case Report

A 34-year-old man with no past medical history presented with right scrotal swelling for one year, with recent onset of pain. There was no history of testicular trauma, hematuria, undescended testis, systemic symptoms, or weight loss. There was no family history of testicular cancer. Physical examination revealed an enlarged tender mobile right testicular mass. Ultrasound showed an enlarged right testis, heterogeneous in echo texture (5×4.4×4.8 cm) with focal testicular parenchymal hypoechoic mass (1.7×1×1.6 cm) suspicious for neoplastic process (Figure 1).

Beta human chorionic gonadotropin [ $\beta$ -HCG] and alpha-fetoprotein [AFP] were normal with elevated lactate dehydrogenase (LDH) 401 (90–225) U/L. Staging computerized tomography (CT) did not show any evidence of metastasis or adenopathy. The patient underwent radical orchiectomy. Grossly, the right testicle and epididymis was covered by intensely fibrotic tunica vaginalis. The testicle was entirely occupied by the tumor (4.5×4.5×4 cm), with 90% necrosis. The tumor was confined to the testis and epididymis without lymphovascular invasion.

The histology was consistent with a well-differentiated neuroendocrine carcinoma. Histology revealed nests of monotonous tumor cells with relatively abundant eosinophilic cytoplasm, round to oval nuclei, distinct nuclear membrane with “salt and pepper”-like chromatin (Figure 2). Immunohistochemistry showed positive staining with chromogranin, synaptophysin (Figure 3), cytokeratin AE1/AE3, and CAM5.2 and negative for placental alkaline phosphatase, CD30,  $\beta$ -HCG, AFP, and epithelial membrane antigen. Ki-67 labelling index was <1% of tumor cells. Final diagnosis was carcinoid tumor localized within the testis. The cancer was classified as pT1 N0 M0 S2



**Figure 1.** Ultrasound showed enlarged right testis, heterogeneous in echotexture (5.0×4.4×4.8 cm) with a focal right testicular parenchymal hypoechoic mass-like area (1.7×1.0×1.6 cm)

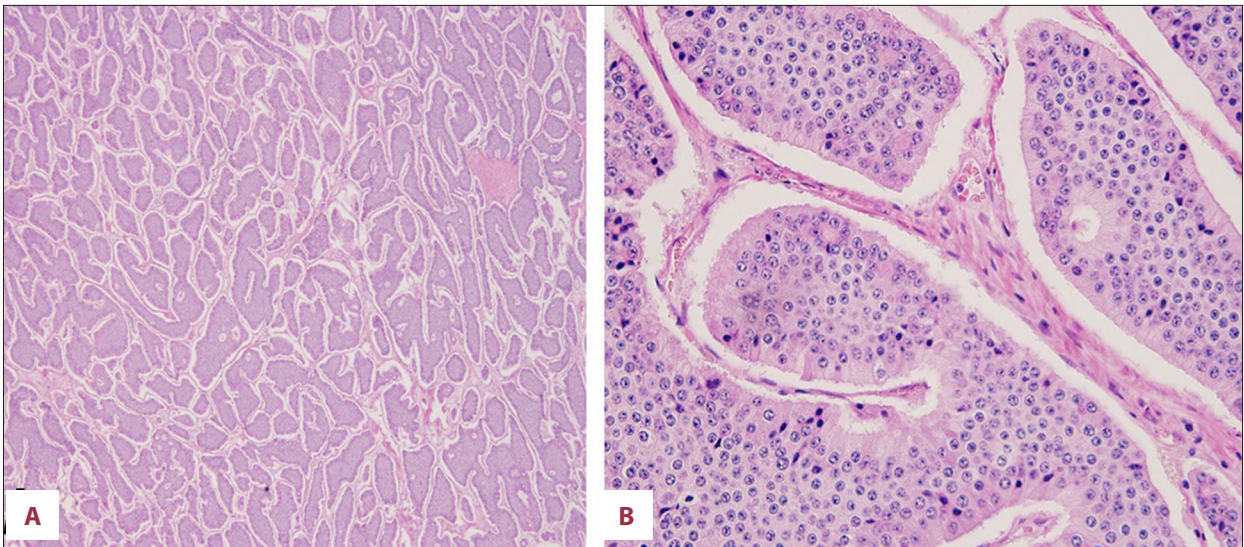
[LDH 401 U/L] as per the American Joint Committee on Cancer (AJCC) TNM staging for testicular cancers.

The possibility of an extratesticular carcinoid tumor was ruled out with negative esophagogastroduodenoscopy and colonoscopy. A nuclear octreotide scan showed focal radiotracer activity projecting over the scrotum (benign physiologic variant); however, an octreotide avid tumor could not be ruled out. The rest of the body demonstrated no evidence of octreotide avid tumor. Urinary excretion of 5-hydroxyindoleacetic acid (5-HIAA) and chromogranin A were within normal range.

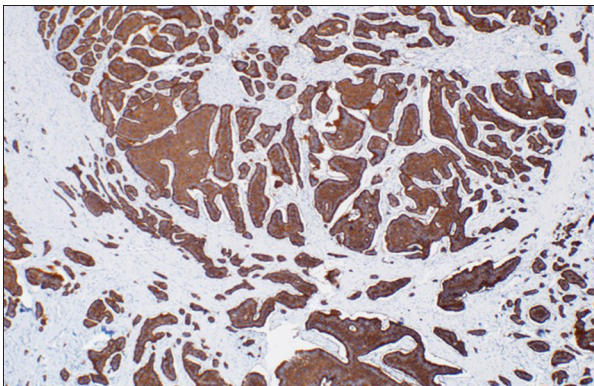
## Discussion

Carcinoid tumors are neuroendocrine tumors which arise from enterochromaffin/Kulchitsky cells. These cells are widely distributed throughout the body. However, the carcinoid tumors are uncommon outside the gastrointestinal tract (65%) and respiratory tract (25%) and are very rarely found in the testis, which could be primary or metastatic [5].

The neuroendocrine neoplasms are currently defined into 3 groups by WHO/ European Neuroendocrine Tumor Society (ENETS). The classification is based on the immunostaining of Ki-67 or mitotic count – Neuroendocrine Tumors G1 (NET) G1: Ki-67 <2%, NET G2: Ki-67 3–20%, NET G3: Ki-67 >20%. The term “carcinoid” is used for NET G1 [6].



**Figure 2.** (A): Low-power view (40×); Showing nests of tumor cells with surrounding abundant blood vessels. (B): High-power view (400×); Monotonous tumor cells with relatively abundant cytoplasm, distinct nuclear membrane with “salt and pepper”-like chromatin.



**Figure 3.** Positive synaptophysin staining of right testis in primary carcinoid tumor.

The histogenesis of pure testicular carcinoma has not been well established. It was described that testicular carcinoids typically occur in the background of teratoma (a germ cell neoplasm) giving the rationale that testicular carcinoid tumor can be of germ cell origin, which was further supported by immunohistochemistry and Florescence *in situ* hybridization (FISH) techniques used by Abbosh et al. They found that Isochromosome 12p and 12p overrepresentations were present in both the carcinoid tumor cells as well as in the cells of co-existing mature teratoma [7].

Teratoma can give rise to TCT by various mechanisms. The testicular carcinoid might be a component of teratoma with regression of rest of the elements. The other mechanism is the preferential development of Argentaffin cells in teratoma. However, Argentaffin cells are not found in the testis but germ cells can give rise to any cell type due to their totipotency [8].

The ovarian carcinoid tumor arising as a component [9] or as a malignant transformation [10] of mature cystic teratoma has been published. Based on this analogy similar mechanism is assumed to occur in primary TCT on literature review. However, carcinoid tumor has never been reported to be arising as a component or resulting from the malignant transformation of teratoma [11].

It is hypothesized that Leydig cells may be the origin of TCT due to their neuroendocrine features. Mai et al. demonstrated the presence of transitional cells expressing features of both the Leydig cells and carcinoid tumor cells in primary TCT. Also, one out of nine Leydig cell tumors in their study showed neuroendocrine differentiation. These findings supported that both carcinoid tumor cells and Leydig cells may have the same progenitor cell origin in the primary TCT [11].

The most common presentation of TCT is painless testicular enlargement, followed by testicular pain, hydrocele and very rarely cryptorchidism. The duration of symptoms can last as long as 240 months. The left testis is most commonly involved with only one report of bilateral involvement of testis [12]. When these tumors are associated with systemic symptoms (episodic wheezing, flushing, diarrhea) the term carcinoid syndrome is used.

Grossly the tumor appears solid with yellow to tan color with firm texture due to excessive desmoplasia. The calcifications can be seen. The average tumor size is 4.6 (1.0 to 9.5) cm. Microscopically, tumor cells are composed of monotonous polygonal-shaped cells with eosinophilic cytoplasm and finally dispersed chromatin within the uniform bland nuclei. The

neoplastic cells can be found to have different architectural arrangements but trabecular and insular patterns predominate. The necrosis can be seen in large size tumors. Mitotic figures are rarely seen [7,13].

The diagnosis should begin with physical examination of scrotum in a patient with chronic painless swelling. Doppler ultrasound is the initial test of choice. The diagnosis is made with help of tumor biomarkers, CT Scans, Magnetic Resonance Imaging (MRI), Nuclear medicine techniques like 111 In-Pentetreotide Scintigraphy, 131 MIBG (Metaiodobenzylguanidine) and endoscopy.

5-HIAA is a good initial test for diagnosis and has a high specificity (100%) but poor sensitivity (<35%). Plasma Chromogranin A (CgA) is the most accurate tumor biomarker among all the available markers. CgA has higher sensitivity (68%) but lower specificity (86%) for detecting carcinoid tumors than 5-HIAA. The CgA is useful in determining if the tumor is local or metastatic, syndromic or non-syndromic. Its level correlate very well with the extent of tumor burden, higher the levels worse the prognosis. The usefulness of CgA extends to assess the response to therapy. It has high accuracy than urinary 5-HIAA for detection of relapse in carcinoid tumors [14].

Patients with TCT very rarely can express features of carcinoid syndrome but only if there is metastasis to liver or lungs [15]. Therefore any patient presenting with symptoms of serotonin excess and testicular swelling must have 24hr urinary 5- HIAA prior to surgery [16]. Since it is difficult to suspect testicular carcinoid pre-operatively and 5 HIAA taken prior to surgery will serve as the baseline tumor marker if the tumor turns out to be carcinoid [17]. Platelet serotonin is the sensitive marker for detection of carcinoid tumor especially if the carcinoid tumors have low serotonin production. This makes platelet serotonin reliable tool for early diagnosis of the carcinoid tumor and also an excellent marker for detection of residual tumor following surgery [18].

It is important to meticulously investigate for primary since 10% of the TCTs have extratesticular primary. The diagnosis of primary TCT is made only after ruling out extratesticular primary since the morphological and histological appearance of the primary and metastatic TCT is same [12]. Staging CT scan is used for detecting metastasis. 111 In-Pentetreotide scintigraphy has a sensitivity of 80-90% to localize the tumor and can also be used to predict the response to octreotide therapy. 131-MIBG has a lower sensitivity than scintigraphy scan. Sensitivity in detecting the tumor can be increased to 95% by combining both the scans. When bone metastases are suspected bone scintigraphy should be used since it has a higher sensitivity (90-100%) than 111 In-Pentetreotide scintigraphy (sensitivity-50%) and 131 I-MIBG scan (sensitivity-20%). Video

capsule endoscopy is more advanced technique for identifying primary carcinoid tumor in the small bowel and thus early resection [5]. It is a reasonable small bowel imaging technique since carcinoid tumors are mostly found in ileum [4].

Radical orchiectomy is the treatment of choice. Carcinoid tumors in general have a very poor response to chemotherapy or radiotherapy. Symptomatic treatment should be given to the patients with carcinoid syndrome. Octreotide, a somatostatin analogue inhibits the release of hormones and neurotransmitters and thus causing symptomatic improvement in about 80% of the patients [5]. The slow release preparations of somatostatin analogues are available (Sandostatin LAR(R) Depot).

The octreotide has variable antiproliferative effect ranging from partial to complete regression of metastatic carcinoid tumor. Leong and Pasioka reported 2 cases of metastatic carcinoid tumors where octreotide was given for symptomatic treatment before the debulking surgery. Previously seen radiographic metastatic lesions were found to be regressed completely on laparotomy [19].

Because of improved prognosis and longer survival time due to advanced diagnostic and therapeutic techniques other late complications involving metastasis to skin and skeletal system and carcinoid heart disease (CHD) are reported [20,21]. Long term follow up is recommended since delayed metastasis has been reported even up to several years with one case of metastasis occurring after 17 years of initial diagnosis [8]. Multimodal approach can be tried where tumor recurrence is highly suspected. Since there are no standardized protocols for the follow up, annual physical examination and frequent Urinary 5HIAA is a reasonable approach. CgA is of particular importance when the 5 HIAA comes out to be normal in a patient after orchiectomy, since normal 5 HIAA does not exclude the presence of tumor recurrence or metastasis [4]. Sutherland et al. purposed 3 monthly follow up with 5 HIAA measurement for the first year and then annually [16]. Use of platelet serotonin is valuable in detecting residual tumor after resection [22]. If still there is any doubt of tumor recurrence or metastasis, 111 In-Pentetreotide scintigraphy can be used [4].

The carcinoid tumors in general have excellent prognosis due to their indolent course. Aggressiveness of the carcinoid tumors is directly proportional to the tumor size (>7.3 cm) and evidence of carcinoid syndrome [16]. Prognosis depends on the extent of tumor spread. 5 year survival rate for localized disease is 93% and for distant metastatic disease is 20–30% [5]. Only 3 deaths have been reported related to distant metastasis [12]. Since there is no effective therapy available for metastatic lesion(s) the prognosis is poor. So far there is only one case report where the metastatic lesion was removed by surgical therapy. No new metastases were found after 25months of follow up [23].

## Conclusions

This case adds to the rare reports in the literature of a primary carcinoid tumor of the testis having low malignant potential. Due to the advanced diagnostic and therapeutic modalities, the survival time has prolonged but long-term complications like CHD and bone and skin metastasis have emerged. Serotonin levels can be elevated even in the absence of carcinoid syndrome. The elevated levels of serotonin can cause CHD leading to reduced survival and poor quality of life; therefore, it is important to follow the hormone levels. High-risk cases (tumor size >7.3 cm, presence of carcinoid syndrome, poorly differentiated tumors and tumors with invasion) should be followed more closely for recurrence and development of metastasis.

## References:

1. Langhans T: Ueber einen drusenpolyp im ileum. *Virchows Arch*, 1867; 38: 559–60 [in German]
2. Cope Z: Metastasis of an argentaffin carcinoma in the testicle. *Br J Urol*, 1930; 2: 268–72
3. Simon HB, McDonald JR, Culp OS: Argentaffin tumor (carcinoid) occurring in a benign cystic teratoma of the testicle. *J Urol*, 1954; 72(5): 892–94
4. Stroosma OB, Delaere KP: Carcinoid tumours of the testis. *BJU Int*, 2008; 101(9): 1101–5
5. Zuetenhorst JM, Taal BG: Metastatic carcinoid tumors: a clinical review. *Oncologist*, 2005; 10(2): 123–31
6. Pavel M, Kidd M, Modlin I: Systemic therapeutic options for carcinoid. *Semin Oncol*, 2013; 40(1): 84–99
7. Abbosh PH, Zhang S, MacLennan GT et al: Germ cell origin of testicular carcinoid tumors. *Clin Cancer Res*, 2008; 14(5): 1393–96
8. Leake J, Levitt G, Ramani P: Primary carcinoid of the testis in a 10-year-old boy. *Histopathology*, 1991; 19: 373–75
9. Ting WH, Hsiao SM, Lin HH: Primary carcinoid tumor of the ovary arising in a mature cystic teratoma: a case report. *Wei MC. Eur J Gynaecol Oncol*, 2014; 35(1): 100–2
10. Guney N, Sayilgan T, Derin D, Ozcan D.: Primary carcinoid tumor arising in a mature cystic teratoma of the ovary: a case report. *Eur J Gynaecol Oncol*, 2009; 30(2): 223–25
11. Mai KT, Park PC, Yazdi HM, Carlier M: Leydig cell origin of testicular carcinoid tumour: immunohistochemical and electron microscopic evidence. *Histopathology*, 2006; 49(5): 548–49
12. Zavala-Pompa A, Ro JY, el-Naggar A et al: Primary carcinoid tumor of testis. Immunohistochemical, ultrastructural, and DNA flow cytometric study of three cases with a review of the literature. *Cancer*, 1993; 72(5): 1726–32
13. Mazzucchelli R, Morichetti D, Lopez-Beltran A et al: Neuroendocrine tumours of the urinary system and male genital organs: clinical significance. *BJU Int*, 2009; 103(11): 1464–70
14. Bajetta E, Ferrari L, Martinetti A et al: Chromogranin A, neuron specific enolase, carcinoembryonic antigen, and hydroxyindole acetic acid evaluation in patients with neuroendocrine tumors. *Cancer*, 1999; 86: 858–65
15. Robertson RG, Geiger WJ, Davis NB: Carcinoid tumors. *Am Fam Physician*, 2006; 74(3): 429–34
16. Neely D, Gray S: Primary carcinoid tumour of the testis. *Ulster Med J*, 2011; 80(2): 79–81
17. Sutherland RS, Wettlaufer JN, Miller GJ: Primary carcinoid tumor of the testicle: a case report and management schema. *J Urol*, 1992; 148(3): 880–82
18. Meijer WG, Kema IP, Volmer M et al: Discriminating capacity of indole markers in the diagnosis of carcinoid tumors. *Clin Chem*, 2000; 46: 1588–96
19. Leong WL, Pasioka JL: Regression of metastatic carcinoid tumors with octreotide therapy: two case reports and a review of the literature. *J Surg Oncol*, 2002; 79(3): 180–87
20. Shimura S, Uchida T, Shitara T et al: [Primary carcinoid tumor of the testis with metastasis to the upper vertebrae. Report of a case]. *Nihon Hinyokika Gakkai Zasshi*, 1991; 82(7): 1157–60 [in Japanese]
21. Sullivan JL, Packer JT, Bryant M: Primary malignant carcinoid of the testis. *Arch Pathol Lab Med*, 1981; 105(10): 515–17
22. Meijer WG, Kema IP, Volmer M et al: Discriminating capacity of indole markers in the diagnosis of carcinoid tumors. *Clin Chem*, 2000; 46(10): 1588–96
23. Fujita K, Wada R, Sakurai T et al: Primary carcinoid tumor of the testis with teratoma metastatic to the para-aortic lymph node. *Int J Urol*, 2005; 12(3): 328–31

This should be done by monitoring biochemical markers on a regular basis and in case of doubt, scintigraphy should be performed. The surgery should be performed if the metastatic lesion(s) is/are resectable and if not accessible for resection, a trial of octreotide therapy could be given due to its antiproliferative and antihormonal properties. It is important to exclude metastasis in case of testicular carcinoid tumor since the morphology and histology cannot distinguish the primary verses metastatic.

## Statement

There are no financial grants or funding sources to declare. There is no conflict of interest for the authors of this manuscript.