

The evaluation of the treatment for old osteoporotic vertebral compression fracture pain by percutaneous vertebroplasty

Peng Zhao, BS^a, Aifeng Guo, BS^a, Zhongjiang Tan, BS^a, Tianqiang Li, MD^a, Fei Zhao, BS^a, Jie Li, MD^{b,*}, Wenliang Yan, MD^{a,*}

Abstract

The aim of the present study was to evaluate the clinical effect of percutaneous vertebroplasty (PVP) in the treatment of old osteoporotic vertebral compression fracture (OVCF) pain.

A retrospective study was conducted on the clinical and imaging data of 31 patients with old OVCF treated by PVP from June 2010 to September 2011. Clinical efficacy was evaluated by the visual analog scale (VAS) scores, the Oswestry Disability Index (ODI), the Cobb angle, and vertebral kyphotic angle at pre-operation and post-operation 3 days, 3 months, and 12 months.

The VAS scores and ODI scores of 3 day, 3 month, and 12 month after PVP were significantly improved compared with those before operation ($P < .05$), but the Cobb angle and vertebral kyphosis angle were not significantly improved compared with those before operation ($P > .05$).

PVP can effectively relieve the pain caused by old OVCF, and the motor ability of the patients is improved obviously. However, the recovery of Cobb angle and vertebral kyphosis angle was not obvious.

Abbreviations: ODI = Oswestry Disability Index, OVCF = old osteoporotic vertebral compression fracture, PKP = percutaneous kyphoplasty, PVP = percutaneous vertebroplasty, VAS = visual analog scale.

Keywords: compression fracture, old fracture, pain, vertebroplasty

1. Introduction

According to the statistics of China Aging Research Center, in 2013, there were 202 million elderly people in China, including about 23 million >80 years.^[1] The increasing aging situation poses a great challenge to the social pension.^[2] Many of the old people have caused a compression fracture of the vertebral body

due to the osteoporosis.^[3] In addition, many patients have resulted in a compression fracture of the osteoporotic vertebral body due to long-term oral administration of the opioid, such as patients receiving organ transplant.^[4] The pain caused by the fracture seriously affected the daily activities and the quality of life of the old people, and increased the social burden. PVP can quickly relieve the pain caused by the fracture of the vertebral body, which is more prominent in the early improvement of the patient's ability to exercise.^[5] In 1984, Galibert et al used percutaneous vertebroplasty (PVP) to treat invasive hemangioma of cervical 2 vertebral body in the first time.^[6] After that, some scholars used this method to treat the vertebral compression fracture of the vertebral body.^[7] After several decades of development, the PVP has become the preferred method to treat the vertebral compression fracture of the osteoporotic vertebral body.^[8] However, there are few clinical reports about the use of PVP in the treatment of pain caused by old osteoporotic vertebral compression fracture (OVCF), and its clinical effect needs to be clarified. Therefore, we performed this study to evaluate the clinical effect of PVP in the treatment of old OVCF pain.

2. Materials and methods

2.1. Patients

Thirty-one patients (9 males and 22 females) with old OVCF were treated with PVP in our hospital from June 2010 to September 2011. All the included patients aged from 60 to 83 years (mean 67.5 years' old), and the course of disease was 3 to 12 weeks (mean 5.9 weeks). All patients had a history of intractable pain in the back of chest, waist, and back, with limited daily activity. All patients were confirmed to be a single segment

Editor: N/A.

PZ and AG contributed equally to this work.

The authors report no conflicts of interest.

All data generated or analyzed during this study are included in this published article [and its supplementary information files].

^aDepartment of orthopedics, Feixian People's Hospital, Linyi City, Shandong Province, ^bDepartment of Spine Surgery, the Second Hospital of Tangshan, Tangshan City, Hebei Province, China.

*Correspondence: Wenliang Yan, Department of orthopedics, Feixian People's Hospital, No. 71, Health Road, Feicheng Town, Linyi City 273400, Shandong Province, China (e-mail: yan_wenliang@126.com); Jie Li, Department of Spine Surgery, the Second Hospital of Tangshan, No. 21, Jianshebei Road, Lubei Strict, Tangshan City 063000, Hebei Province, China (e-mail: potatolijie@163.com).

Copyright © 2020 the Author(s). Published by Wolters Kluwer Health, Inc. This is an open access article distributed under the terms of the Creative Commons Attribution-Non Commercial License 4.0 (CCBY-NC), where it is permissible to download, share, remix, transform, and buildup the work provided it is properly cited. The work cannot be used commercially without permission from the journal.

How to cite this article: Zhao P, Guo A, Tan Z, Li T, Zhao F, Li J, Yan W. The evaluation of the treatment for old osteoporotic vertebral compression fracture pain by percutaneous vertebroplasty. *Medicine* 2020;99:27(e20479).

Received: 18 November 2019 / Received in final form: 2 April 2020 / Accepted: 29 April 2020

<http://dx.doi.org/10.1097/MD.00000000000020479>

old OVCF by x-ray computed tomography (CT) and magnetic resonance imaging. Vertebral body with fracture: T₁₁ 3 cases, T₁₂ 5 cases, L₁₁ 7 cases, L₂ 4 cases, L₃ 2 cases. Case inclusion criteria: the patient age was ≥ 60 years, generally in good condition, no serious cardiovascular and cerebrovascular diseases, the location of pain was consistent with the fracture site shown on plain radiography; the pain was severe but there were no symptoms of nerve compression or injury; the patient could lie prostrate for 1~2 hours and tolerate surgery; preoperative CT showed that the posterior wall of vertebral body was complete; single vertebral fracture. Exclusion criteria: fracture or dislocation of vertebral body complicated with spinal cord and nerve injury; coagulation dysfunction, allergy to bone cement, and so on; severe heart and lung diseases cannot tolerate surgery; examination confirmed pain caused by disc herniation and vertebral body or paravertebral tumor. This study had been approved by the medical ethics committee of Feixian People's Hospital. All patients in the study have signed an informed consent and agreed with publication of data.

2.2. Surgery

The patient were adopted in a prone posture, positioned and marked under the perspective of a C-arm x-ray machine. The surgical field skin was sterilized by iodine and alcohol and laid a sterile surgical sheet. After the local anesthesia along the puncture approach, a small incision was made by the sharp knife at the mark on the left surface, combined with C-arm fluoroscopy, needles were accurately inserted through bilateral pedicle of the injured vertebra, and punctured to the junction of anterior middle one-third interface of vertebral body under lateral fluoroscopy. Then the needles were removed from the trochar, a proper amount of bone cement was injected into the vertebral body through the puncture channel under the perspective of the C-arm x-ray machine. After the bone cement is solidified, the bone-penetrating needle was rotated and pulled out, and the sterile dressing at the puncture incision was bandaged and fixed.

2.3. Postoperative treatment and therapeutic evaluation

After the operation, the vital signs and the activities of the 2 lower limbs of the patients were closely observed, and the treatment of the prevention of infection and the like was given. The patient was bedridden for 1 day after the operation and got out of bed the second day after operation. The routine CT examination was performed after operation. The postoperative 3 days, 3 months, 12 months visual analog scale (VAS) scores, Oswestry disability index (ODI) scores, the Cobb angle, and vertebral kyphosis angle were counted and measured.

As previous described, the VAS scores and ODI scores were used to evaluate the back pain before operation and 3 days, 3 months, and 12 months after operation.^[9,10] The vertebral kyphotic angle was the angle between the upper and lower edge of the injured vertebrae (Fig. 1A), and the Cobb angle was the angle of the vertical line between upper edge of the upper vertebral body of the injured vertebrae and the lower edge of the next vertebral body of the injured vertebrae (Fig. 1B). All the measured results were measured by 3 doctors alone, and the average value was taken as the final result for analysis and study.

2.4. Statistical analysis

SPSS 19.0 statistical software was used for analysis (SPSS Inc, Chicago, IL). After performing repeated measures analysis of variance test, the differences in VAS scores, ODI scores index, Cobb angle, and vertebral kyphosis angle between pre-operation and post-operation 3 days, 3 months, and 12 months were compared and analyzed by Dunnett method. The clinical results were expressed by $\bar{x} \pm s$, and the test level was set to $\alpha = 0.05$.

3. Results

3.1. Base situation

All the patients underwent smooth operation; the operation time was 30 to 50 minutes, with an average of 46.3 minutes. Bone cement was injected with 3 to 4.5 mL, with an average of 3.6 mL. There was no nerve, spinal cord, and vascular injury during operation, and the muscle strength of lower extremity was normal after operation. There were no postoperative complications such as infection, embolism, and so on. The follow-up period ranged from 12 to 18 months, with an average of 14.4 months.

3.2. Pain improvement

The pain of the back and waist of the patients after operation was obviously relieved than that before operation. The mean scores of preoperative VAS and ODI scores were 7.6 ± 0.7 and 73.6 ± 7.3 , respectively. The mean scores of VAS at 3 days, 3 months, and 12 months after operation were 2.3 ± 0.5 , 2.2 ± 0.4 , 2.1 ± 0.3 , respectively. The mean scores of ODI at 3 days, 3 months, and 12 months after operation were 26.5 ± 4.7 , 25.5 ± 3.9 , and 24.4 ± 3.1 , respectively. The difference was statistically significant ($P < .05$) (Fig. 2A).

3.3. Imaging findings

The postoperative x-ray positive-side plate showed good filling of the bone cement (Fig. 1C and D). No refracture of the injured vertebral body and fracture of adjacent segments of the injured vertebral body, during a follow-up of 12 to 18 months. The preoperative Cobb angle and vertebral kyphosis angle were ($12.2^\circ \pm 1.0^\circ$) and ($10.1^\circ \pm 0.4^\circ$). The Cobb angle and vertebral kyphosis angle at 3 days, 3 months, and 12 months after operation were ($12.2^\circ \pm 1.0^\circ$), ($12.3^\circ \pm 1.0^\circ$), ($12.3^\circ \pm 1.0^\circ$) and ($10.1^\circ \pm 0.4^\circ$), ($10.1^\circ \pm 0.4^\circ$), ($10.2^\circ \pm 0.4^\circ$), respectively. There was no significant difference between postoperative and preoperative ($P > .05$) (Fig. 2B).

4. Discussion

The vertebral compression fracture is the most common complication of the osteoporosis of the spine, which could cause the pain of the fracture site and the loss of the vertebral body and could lead to the kyphosis of the spine in the later stage. The symptoms are mainly manifested as the pain of the fracture site and the limited day-to-day activity, which seriously affects the quality of life of the patient, and even leads to death. In some patients, the symptoms of pain were not relieved or further increased due to the nonformal conservative treatment, protracted course of the fracture, and the pain persisted. The last development is the compression fracture of the old osteoporotic vertebral body. The possible causes of long-term pain in the

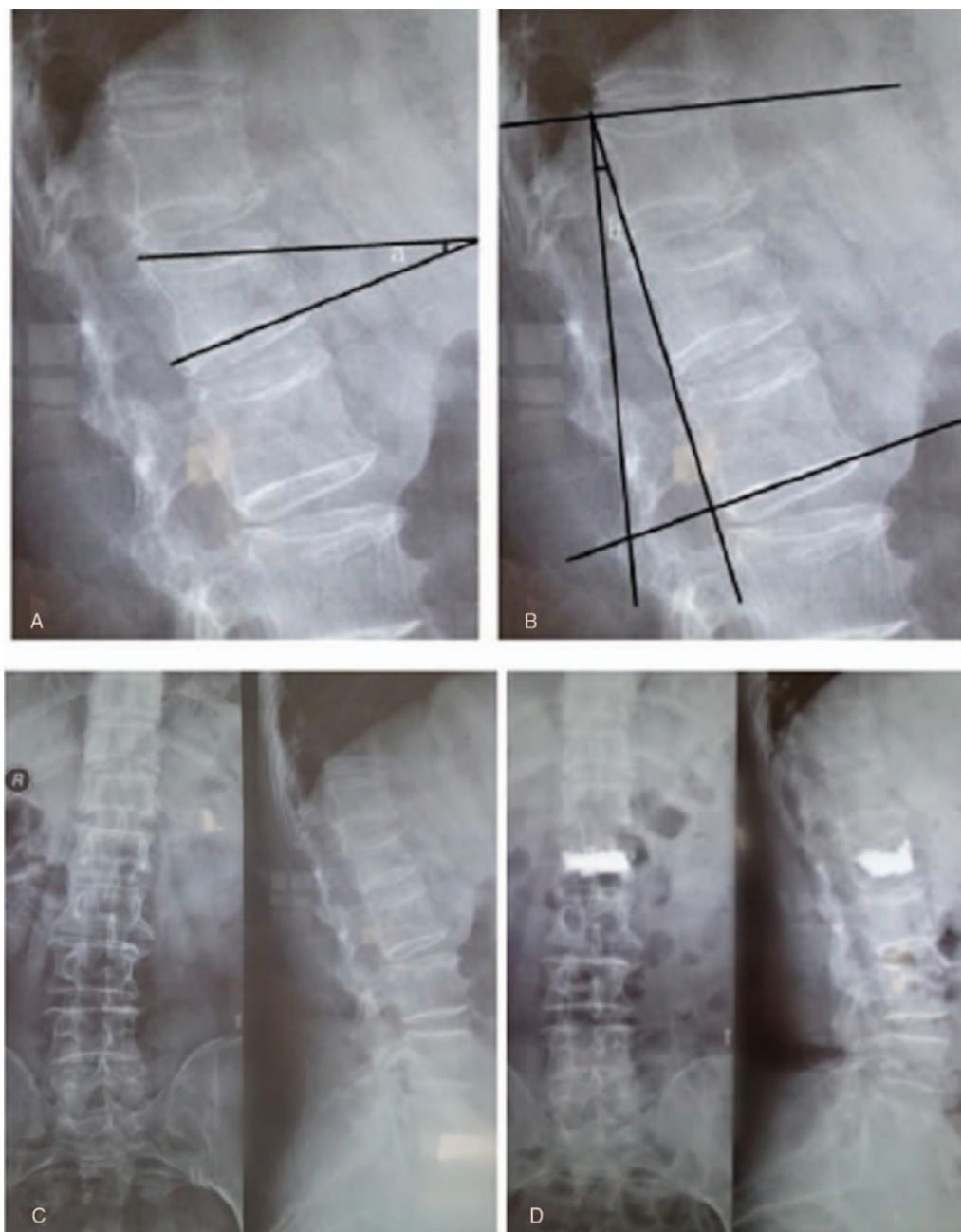


Figure 1. (A) Kyphotic angle; (B) the Cobb angle; (C) the preoperative x-ray slice shows the old OVCF of the lumbar 1 vertebral body; (D) the postoperative x-ray slice shows the lumbar 1 vertebral body is filled with the bone cement.

fracture site: long-term activity caused the fracture vertebral body to always been in a continuous compression state, and the fracture vertebral body is slightly displaced, which continuously stimulated the peripheral nerve in the vertebral body; the compressive stress of the vertebral body in the thoracolumbar vertebral segment was the largest, and more likely to caused persistent pain after the fracture; paravertebral muscle spasm. Early diagnosis and selection of reasonable surgical methods should be made to avoid the aggravation of kyphosis and spinal cord nerve injury caused by further compression of fracture vertebrae.^[11]

The purpose of the operation was to relieve the pain quickly, to eliminate the abnormal movement of fracture site, increase the

intensity of vertebral body, and restore the motor ability of patients as soon as possible. Because most patients were old and had poor tolerance, it was not appropriate to choose open surgery. Before the invention of PVP technology, long-term bed rest was the main treatment, but the following complications seriously affected the life span and quality of life of patients. With the development of the minimally invasive technique of the spinal surgery, the purpose of stabilizing the vertebral body, increasing the strength of the vertebral body and relieving the pain could be achieved by using the PVP technique.^[12,13] In our study, the VAS scores and ODI scores of 31 patients at 3 days, 3 months, and 12 months after PVP were significantly lower than those before operation ($P < .05$), and the pain was relieved and the

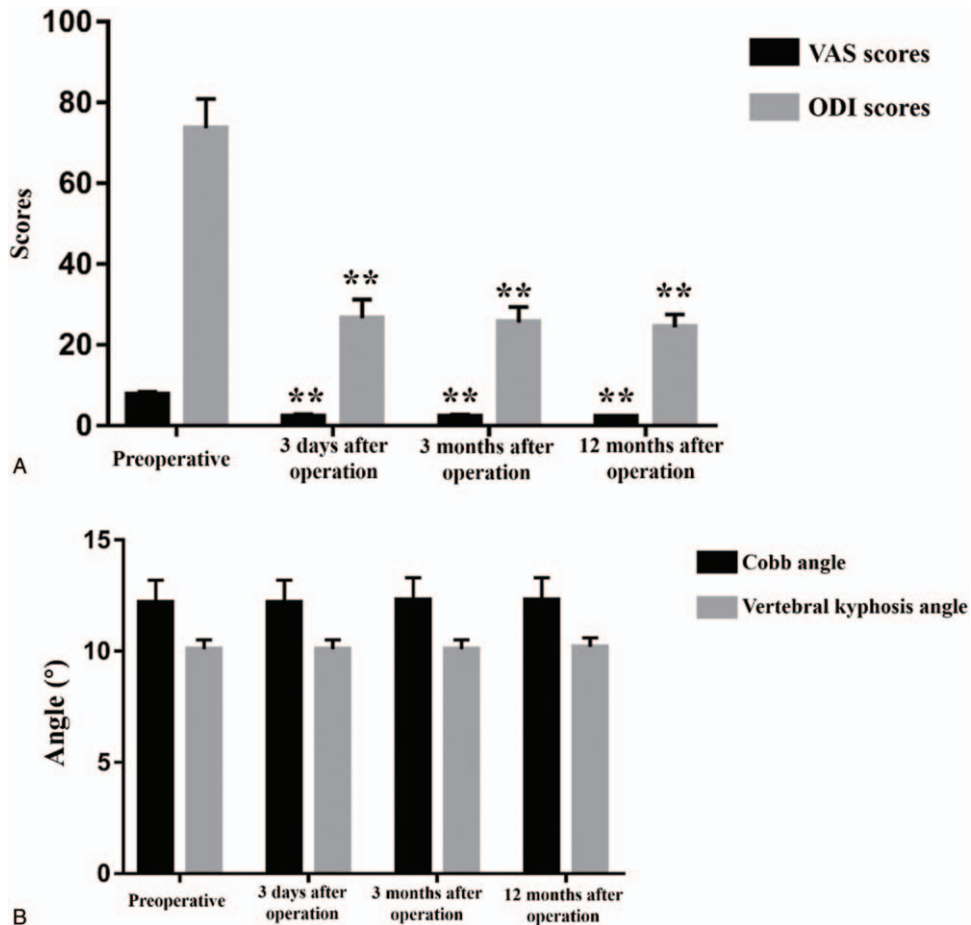


Figure 2. The changes and comparison of various indexes before and after operation. (A) The levels of VAS scores and ODI scores. (B) The angle of Cobb angle and Vertebral kyphosis angle. The data are expressed as $\bar{x} \pm s$. ** $P < .01$ vs preoperative group. ODI = Oswestry Disability Index, VAS = Visual Analog Scale.

exercise ability was enhanced. With respect to the analgesic mechanism of PVP, most of the scholars considered it possible to be related to the following:

1. mechanical stability: bone cement could improve the biomechanical properties of the spine, reduce the small displacement of the fracture, increase the stability and the strength of the vertebral body, and prevent the further compression of the vertebral body. All of the above factors could reduce the stimulation of the nerve endings in the vertebral body.
2. Thermal effect: the heat generated when bone cement solidified relieves pain by destroying its surrounding tissue and nerve endings.
3. Vascular effect: bone cement blocks the blood supply of local tissue and causes ischemic necrosis of nerve endings in the vertebral body.
4. Chemical toxicity: the toxic effect of bone cement itself on nerve cells. It has been reported that PVP had no significant advantage over nonsurgical treatment in relieving pain caused by fracture.^[14,15]

However, a large sample retrospective study of Chen et al^[16] on a national health-care patient database showed that the survival time of the bone cement treatment group was significantly longer than that of the nonoperative treatment

group. It could be seen that the PVP treatment for old OVCF was very necessary.

The most important risks and complications of PVP were bone cement leakage, but most of the leakage does not cause clinical symptoms.^[17] There were 5 cases of bone cement leakage in our study, but none of the clinical symptoms occurred, including 1 case of paravertebral blood vessel leakage and 4 cases of leakage of the leading edge of vertebral body. The incidence rate of leakage was 16.1% (5/31), which was lower than 55% to 79%^[18,19] reported in relevant literature; it may be related to the partial healing of the fracture vertebral body. Before operation, CT was performed to investigate the integrity of the posterior wall of the vertebral body, the direction of bone cement injection was closely monitored during the operation, high pressure perfusion and excessive pursuit of bone cement injection were strictly prohibited to prevent the leakage of bone cement to the back of the vertebral body. It has been reported in some literature^[20,21] that the infiltration of bone cement into the dura mater leads to motor dysfunction or spinal canal stenosis due to the infiltration of bone cement into the spinal vein. In addition to paravertebral and intraspinal leakage, the complications related to bone cement in other parts should not be ignored. Some scholars found that the incidence of asymptomatic bone cement pulmonary embolism after PVP was 4.6% and 6.8%.^[22,23] Therefore, we should closely observe the changes of the disease

after operation, improve the examination in time, and be alert to the occurrence of catastrophic complications. In this study, the consideration of perivertebral vascular leakage was related to the excessive pressure of bone cement during operation, and the consideration of anterior edge leakage of vertebral body was related to the formation of microfissures in the anterior edge of vertebral body caused by prone position during operation. In this study, the leakage of paravertebral vessels may be related to the excessive pressure of bone cement during operation, and the leakage of anterior edge of vertebral body may be related to the formation of microfissures in the anterior edge of vertebral body caused by prone position during operation.

Although the PVP is inferior to the percutaneous kyphoplasty (PKP) in the recovery of vertebral height and the correction of kyphosis,^[24,25] it is inappropriate to restore the compressed vertebral body to the normal height for the old OVCF. Because PKP might lead to new fractures and increase the risk of bone cement leakage. It has been reported that the vertebral height and posterior convex angle recovery after treatment with PKP in the old fracture group are less obvious than that in the fresh fracture group.^[26] In addition, the cost of treatment and the incidence of vertebral fracture in PKP group were higher than that in the PVP group,^[16] so the clinician should choose the surgical method reasonably according to the actual situation. There was no significant recovery in Cobb angle and kyphosis angle in all patients at 3 days, 3 months, and 12 months after PVP, but the pain symptoms and motor ability of all patients were significantly improved, and all of them achieved the effect of clinical cure.

5. Conclusion

In conclusion, for old OVCF pain, PVP is a safe and effective treatment that was very significant in pain relief and motor improvement. Therefore, the patients should be accepted vertebroplasty as soon as possible if they were with long-term low back pain, which were confirmed by imaging as old fracture and there was no surgical contraindication. However, the recovery of the Cobb angle and kyphosis angle were not obvious after PVP, so it was not beneficial to patients with severe vertebral compression and associated kyphosis. In this study, there were no new fractures occurred during the follow-up period; since the number of cases in our study is small and the follow-up time is short, it cannot be excluding the increased risk of new fracture of the vertebral body after PVP.

Author contributions

PZ and AFG participated in the design of this study, and they all performed the statistical analysis. PZ, AFG, ZJT, TQL, FZ and JL carried out the study and collected important background information. PZ drafted the manuscript. WLY reviewed and revised the manuscript. All authors read and approved the final manuscript.

References

- [1] Wang X, Chen P. Population ageing challenges health care in China. *Lancet* 2014;383:870.
- [2] Feng Z, Liu C, Guan X, et al. China's rapidly aging population creates policy challenges in shaping a viable long-term care system. *Health Aff (Millwood)* 2012;31:2764–73.

- [3] Ribot C, Pouillès JM. Postmenopausal osteoporosis: clinical characteristics in patients first vertebral crush fracture. Results of the GRIO National Multicenter Survey. *Groupe de Recherche et d'Information sur les Osteoporoses. Rev Rhum Ed Fr* 2011;60:427–34.
- [4] Sun Mingjie, Zhong Jiangbo, Song Hongliang, et al. Comparison of postoperative analgesia of three opioids combined with flurbiprofenol ester in internal fixation of lumbar fractures. *Chin J Orthop Surg* 2018;26:1098–102.
- [5] Alvarez L, Alcaraz M, Perez-Higuera A, et al. Percutaneous vertebroplasty: functional improvement in patients with osteoporotic compression fractures. *Spine (Phila Pa 1976)* 2006;31:1113–8.
- [6] Galibert P, Deramond H, Rosat P, et al. [Preliminary note on the treatment of vertebral angioma by percutaneous acrylic vertebroplasty]. *Neurochirurgie* 1987;33:166–8.
- [7] Jensen ME, Evans AJ, Mathis JM, et al. Percutaneous polymethylmethacrylate vertebroplasty in the treatment of osteoporotic vertebral body compression fractures: technical aspects. *AJNR Am J Neuroradiol* 1997;18:1897–904.
- [8] Mathis JM, Barr JD, Belkoff SM, et al. Percutaneous vertebroplasty: a developing standard of care for vertebral compression fractures. *AJNR Am J Neuroradiol* 2001;22:373–81.
- [9] Richards RR, An KN, Bigliani LU, et al. A standardized method for the assessment of shoulder function. *J Shoulder Elbow Surg* 1994;3:347–52.
- [10] Ostelo RW, Deyo RA, Stratford PW, et al. Interpreting change scores for pain and functional status in low back pain: towards international consensus regarding minimal important change. *Spine (Phila Pa 1976)* 2008;33:90–4.
- [11] Kim KT, Suk KS, Kim JM, et al. Delayed vertebral collapse with neurological deficits secondary to osteoporosis. *Int Orthop* 2003;27:65–9.
- [12] Kim DY, Lee SH, Jang JS, et al. Intravertebral vacuum phenomenon in osteoporotic compression fracture: report of 67 cases with quantitative evaluation of intravertebral instability. *J Neurosurg* 2004;100:24–31.
- [13] Cotten A, Boutry N, Cortet B, et al. Percutaneous vertebroplasty: state of the art. *Radiographics* 1998;18:311–20. discussion 320–313.
- [14] Buchbinder R, Osborne RH, Ebeling PR, et al. A randomized trial of vertebroplasty for painful osteoporotic vertebral fractures. *N Engl J Med* 2009;361:557–68.
- [15] Kallmes DF, Comstock BA, Heagerty PJ, et al. A randomized trial of vertebroplasty for osteoporotic spinal fractures. *N Engl J Med* 2009;361:569–79.
- [16] Chen AT, Cohen DB, Skolasky RL. Impact of nonoperative treatment, vertebroplasty, and kyphoplasty on survival and morbidity after vertebral compression fracture in the medicare population. *J Bone Joint Surg Am* 2013;95:1729–36.
- [17] Lin BJ, Li CC, Ma HI. Intradural cement leakage after percutaneous vertebroplasty. *Turk Neurosurg* 2015;25:940–2.
- [18] Li KC, Li AF, Hsieh CH, et al. Another option to treat Kummell's disease with cord compression. *Eur Spine J* 2007;16:1479–87.
- [19] Peh WC, Gelbart MS, Gilula LA, et al. Percutaneous vertebroplasty: treatment of painful vertebral compression fractures with intraosseous vacuum phenomena. *AJR Am J Roentgenol* 2003;180:1411–7.
- [20] Chen YJ, Tan TS, Chen WH, et al. Intradural cement leakage: a devastatingly rare complication of vertebroplasty. *Spine (Phila Pa 1976)* 2006;31:E379–82.
- [21] Hoehgegger M, Radl R, Leithner A, et al. Spinal canal stenosis after vertebroplasty. *Clin Radiol* 2005;60:397–400.
- [22] Choe DH, Marom EM, Ahrar K, et al. Pulmonary embolism of polymethyl methacrylate during percutaneous vertebroplasty and kyphoplasty. *AJR Am J Roentgenol* 2004;183:1097–102.
- [23] Duran C, Sirvanci M, Aydogan M, et al. Pulmonary cement embolism: a complication of percutaneous vertebroplasty. *Acta Radiol* 2007;48:854–9.
- [24] Liu JT, Liao WJ, Tan WC, et al. Balloon kyphoplasty versus vertebroplasty for treatment of osteoporotic vertebral compression fracture: a prospective, comparative, and randomized clinical study. *Osteoporos Int* 2010;21:359–64.
- [25] Boonen S, Wahl DA, Nauroy L, et al. Balloon kyphoplasty and vertebroplasty in the management of vertebral compression fractures. *Osteoporos Int* 2011;22:2915–34.
- [26] Li XF, Shen BH, Tan JW, et al. Percutaneous kyphoplasty for fresh and old vertebral compression fractures—a comparative study [Article in Chinese]. *Chin J of Clinical Physicians* 2013;7:632–6.