

# Proximal versus Distal Nerve Transfer for Biceps Reinnervation—A Comparative Study in a Rat’s Brachial Plexus Injury Model

Aleksandra M. McGrath, MD,  
PhD\*†

Johnny Chuieng-Yi Lu, MD‡

Tommy Naj-Jen Chang, MD‡

Frank Fang, MD‡

David Chwei-Chin Chuang, MD‡

**Background:** The exact role of proximal and distal nerve transfers in reconstruction strategies of brachial plexus injury remains controversial. We compared proximal with distal nerve reconstruction strategies in a rat model of brachial plexus injury.

**Methods:** In rats, the C6 spinal nerve with a nerve graft (proximal nerve transfer model, n = 30, group A) and 50% of ulnar nerve (distal nerve transfer model, n = 30, group B) were used as the donor nerves. The targets were the musculocutaneous nerve and the biceps muscle. Outcomes were recorded at 4, 8, 12, and 16 weeks postoperatively. Outcome parameters included grooming test, biceps muscle weight, compound muscle action potentials, tetanic contraction force, and axonal morphology of the donor and target nerves.

**Results:** The axonal morphology of the 2 donor nerves revealed no significant difference. Time interval analysis in the proximal nerve transfer group showed peak axon counts at 12 weeks and a trend of improvement in all functional and physiologic parameters across all time points with statistically significant differences for grooming test, biceps compound action potentials, tetanic muscle contraction force, and muscle weight at 16 weeks. In contrast, in the distal nerve transfer group, the only statistically significant difference was observed between the 4 and 8 week time points, followed by a plateau from 8 to 16 weeks.

**Conclusions:** Outcomes of proximal nerve transfers are ultimately superior to distal nerve transfers in our experimental model. Possible explanations for the superior results include a reduced need for cortical adaptation and higher proportions of motor units in the proximal nerve transfers. (*Plast Reconstr Surg Glob Open* 2016;4:e1130; doi: 10.1097/GOX.0000000000001130; Published online 13 December 2016.)

In reconstruction procedures after brachial plexus injury (BPI), nerve transfers performed near the lesion in the supra- or infraclavicular fossa are called “proximal nerve transfers” and those performed beyond the brachial plexus zone and near the neuromuscular junction are called “distal nerve transfers.” The past 3 decades have

seen a major shift from the traditional proximal nerve transfers to distal nerve transfers in reconstruction procedures after peripheral nerve injury.<sup>1-7</sup> The merits of these disparate strategies have been debated extensively, but relative superiority has not yet been clearly established.<sup>4-10</sup>

Proximal nerve transfer is technically demanding, requiring brachial plexus exploration and dissection within a scarred zone to identify available spinal nerves for grafts and/or transfers. In contrast, distal nerve transfer, a new strategy, generally involves an easier dissection in an uninjured zone, using portions of healthy motor/sensory nerves to neurotize target nerve(s) in the vicinity of the target muscle(s). Proximal nerve transfer allows for intraoperative diagnosis and surgical intervention. Distal nerve transfer provides surgical intervention only. For proximal nerve transfers, a

From the \*Department of Hand and Plastic Surgery, Norrland’s University Hospital, Umeå, Sweden; †Department of Surgical and Perioperative Sciences, Umeå University, Umeå, Sweden; and ‡Department of Plastic Surgery, Chang Gung Memorial Hospital, Chang Gung University, Taipei-Linkou, Taiwan.

Received for publication July 28, 2016; accepted September 20, 2016.

Copyright © 2016 The Authors. Published by Wolters Kluwer Health, Inc. on behalf of The American Society of Plastic Surgeons. All rights reserved. This is an open-access article distributed under the terms of the Creative Commons Attribution-Non Commercial-No Derivatives License 4.0 (CCBY-NC-ND), where it is permissible to download and share the work provided it is properly cited. The work cannot be changed in any way or used commercially without permission from the journal.

DOI: 10.1097/GOX.0000000000001130

**Disclosure:** The authors have no financial interest to declare in relation to the content of this article. This study was supported by a grant from the Ministry of Science and Technology, Taiwan, R.O.C. (NSC 101-2314-B-182A-033-MY3). The Article Processing Charge was paid for by the authors.

spinal nerve or more proximal nerve is usually a powerful donor with a large axon load and less need for cortical adaptation during rehabilitation,<sup>8</sup> but they usually require nerve grafts. Distal nerve transfers do not require nerve grafts, are technically easier to perform, and require less operative time and shorter regenerative distances. However, distal nerve transfers sacrifice some donor nerve function and provide fewer donor nerve axons.<sup>4,9</sup>

In light of the known advantages and disadvantages of the 2 strategies, we used an experimental rat model to compare the functional outcomes of proximal and distal nerve transfers.

## MATERIALS AND METHODS

Seventy-two male Sprague Dawley rats (10–12 weeks old) were used in accordance with the established principles for the care of research animals approved by the Chang Gung Memorial Hospital Animal Care Committee. All surgical procedures were performed aseptically under inhalational general anesthesia using isoflurane (FORANE, Baxter, San Juan, USA).

### Surgical Procedure for All Experimental Groups

#### First Stage: C5 and C7 Injury, Simulation of the BPI

Using an operating microscope (Leica, Biberach, Germany) the left brachial plexus was exposed using the posterior approach by dividing the trapezius and rhomboids. The C5 and C7 spinal nerves were divided, sparing the C6 and phrenic nerve. The wound was closed in layers.

#### Second Stage: Reconstruction of Biceps Function

Four days later, the rat's brachial plexus was accessed using the anterior approach by dividing pectoralis major and minor muscles. The supra- and infraclavicular brachial plexus was exposed. Division and retraction of the C5 and C7 were confirmed. The intact C6 spinal nerve was identified. All branches for shoulder abduction from C6 were divided, leaving an intact C6 spinal nerve and its distal continuation with the anterior division of the upper

trunk, lateral cord, and musculocutaneous nerve (MCN) to essentially reflect the elbow flexion as our study parameter (Fig. 1). The brachialis branch after the biceps branch was also cut and transferred back to the biceps muscle to avoid loss of regenerated axons (Fig. 1).<sup>11</sup>

Sixty rats were randomly divided into 2 groups: group A and group B.

**Group A (n = 30, Proximal Nerve Transfer Model).** One centimeter reverse nerve graft taken from a portion of the anterior division of the upper trunk was used as a model of proximal nerve transfer with nerve graft.

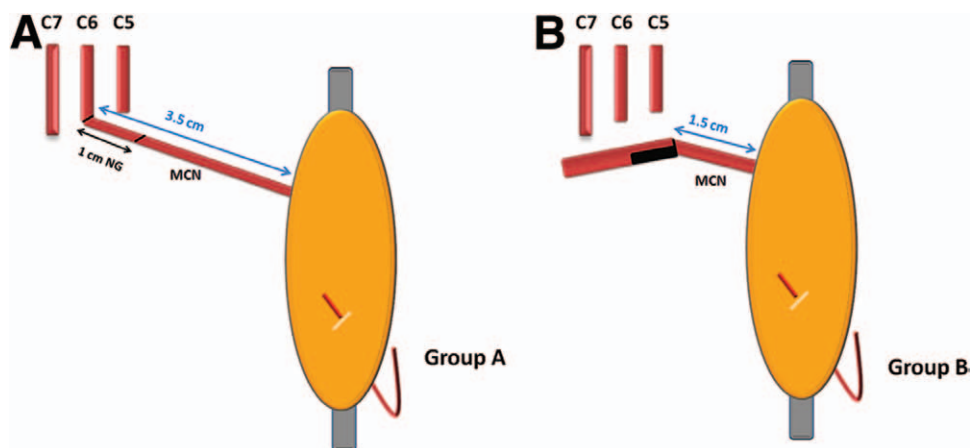
**Group B (n = 30, Distal Nerve Transfer Model).** The ulnar nerve was found in the axilla. Half of ulnar nerve (50%) was ligated with a single 8-0 nylon suture. The ulnar nerve was separated intraneurally 5 mm distal to the ligation point and then divided. The proximal 50% stump was then coapted to the nearby MCN which was divided 10 mm from its entry into the biceps muscle, in an end-to-end fashion with two 10-0 nylon sutures.

The distance between the proximal nerve graft coaptation and biceps muscle was 35 mm in group A. The distance between nerve coaptation and biceps muscle in group B was 15 mm, 20 mm shorter than that in group A.

After the operative procedure, the wound was closed in layers and the wrist was immobilized with a 3-0 nylon suture to the chest wall for 1 week. The right MCN and biceps muscle (nonoperative side) were used as the control group (group C). All experimental rats were assessed every 4 weeks until euthanasia at 16 weeks. Result analyses were performed at 4, 8, and 12 weeks on 6 rats each from groups A and B. At 16 weeks, the remaining group A and B cohorts contained 12 rats each.

#### Preliminary Study of the 2 Donor Nerves' Morphology

Twelve additional rats were randomly selected for comparison of donor nerve morphology. Samples of C6 spinal nerve (proximal donor) and of 50% ulnar nerve (distal donor) were taken just proximal to the transection site



**Fig. 1.** Schematic representation of the experimental rat models: A, proximal nerve transfer rat model; B, distal nerve transfer rat model. The distance between nerve coaptation and biceps muscle was 35 mm in group A and 15 mm in group B. The distance in group A was more than twice that in group B (2.3:1).

where nerve transfer was planned to be performed. Nerve specimens were embedded in epoxy resin and cut into 1- $\mu$ m-thick sections and stained with 2% toluidine blue. The selected sections were photographed under light microscope at 400 $\times$  magnification and enlarged digitally to 1,000 $\times$ . The number of axons was counted in randomly selected areas within each specimen. Axon counts, axon diameter, fiber diameter, and myelin thickness were measured with the help of Image-Pro Premier software (Media Cybernetics, Inc., Rockville, Md.). Data showed that there were no significant differences between the C6 and 50% ulnar nerve groups in any of the assessed parameters (Table 1), confirming similarity of donors for proximal and distal nerve transfers.

## Outcomes Evaluation

### Behavior Analysis: Grooming Test

As described by Bertelli and Mira,<sup>12</sup> a grooming test was performed by squirting water (1–3 mL) over the animal's face to elicit a grooming response. This was recorded with a digital video recorder and then analyzed by a blinded observer and assigned a score from 1 to 5. Animals were scored 5 points if the paw reached behind the ear, 3 points if the paw passed the snout but did not reach the eye, and 1 point if the paw moved but did not reach the snout. As all branches for shoulder abduction muscles from C6 were divided, the score reflects elbow flexion alone.

### Electromyography

General anesthesia was induced. The MCN and biceps muscle were exposed through the previous incision. About 10 mm of the nerve length from the biceps muscle was exposed. A hook electrode was placed into the distal biceps muscle and a ground electrode was placed subcutaneously. Two stimulating hook electrodes 2 mm apart were placed around the MCN. Stimulation was delivered for each trial by an electrical stimulator (Biopac System, BSL Software Installation Package, Windows, Goleta, Calif.) and fixed at 1 ms at a constant current between 10 mA and 10 A while the compound muscle action potentials (CMAPs) were recorded.

### Tetanic Muscle Contraction Force Measurement

The force of tetanic muscle contraction was assessed according to a previously described protocol.<sup>13</sup> First, the resting length of the biceps was determined. Then the distal biceps insertion was detached from radius and attached to the force displacement transducer (FT03 force displacement transducers, Grass Instruments, Quincy, Mass.) at resting length. In this position, shoulder, elbow, and wrist were immobilized with pins to prevent motion artifacts. A bipolar platinum electrode was used

to deliver stimulating current to the MCN at the same location as described for electromyography. The threshold stimulus was determined as a stimulus that produced a noticeable twitch of the biceps. Nerve stimulation was performed at different thresholds (1–10 times the initial threshold stimulus) using different voltages and frequencies (0.6–1.2 V and 1.0–60 Hz, respectively). The maximal tetanic contraction strength was measured at 1 and 60 Hz and recorded as grams/weight. The mean maximal isometric muscle contraction of the repeated muscle contraction forces (5 times with a pulse duration of 1.0 ms) was determined. The data for tetanic muscle contraction force were collected, controlled, and analyzed using MacLab systems (AD Instruments, Colorado Springs, Colo.).

### Biceps Muscle Weight

After the above measurements, animals were euthanized by intracardiac injection of pentobarbital. Under an operating microscope, the entire left and right biceps muscles were harvested by dividing its tendinous origins with bone. The muscle was weighed immediately and the results were expressed as left/right muscle weight ratios.

### Nerve Morphology Study

The biceps muscles were embedded in optimal cutting temperature compound and snap frozen in liquid nitrogen. Segments of MCN, 5 mm long, were obtained bilaterally just before its entry into the biceps muscle for recipient nerve study. The subsequent protocol for processing and analyzing nerve morphology was the same as described in the previous section.

### Muscle Morphology Study

Sections of left and right biceps muscles were cut at 16  $\mu$ m on a cryostat, fixed with 4% paraformaldehyde for 15 minutes, and blocked with normal serum. Sections were incubated with monoclonal primary antibodies raised against fast and slow myosin heavy chain protein (NCL-MHCf and NCL-MHCs, Novocastra, Peterborough, United Kingdom; both 1:20 dilution) for 2 hours at room temperature and coincubated with rabbit antilaminin antibody (Sigma, Poole, United Kingdom; 1:200 dilution). After rinsing in phosphate-buffered solution, secondary goat antirabbit and goat antimouse antibodies (Alexa Fluor 488 and Alexa Fluor 568, 1:200; Invitrogen, Rockford, Ill.) were applied for 1 hour at room temperature in the dark. The slides were cover slipped with Prolong antifade mounting medium containing 4'-6-diamidino-2-phenylindole (DAPI; Invitrogen, Rockford, Ill.). The staining specificity was confirmed by omission of primary antibodies.

### Statistical Analysis

The statistical analysis was performed using ANOVA with Tukey's post hoc test for all comparisons except for analyzing the differences between the donor nerves, C6 and 50% of ulnar nerve, where an unpaired *t* test was applied. All analyses were performed with GraphPad Prism (GraphPad Software Inc., La Jolla, Calif.). *P* value of less than 0.05 was considered significant.

**Table 1. Comparison of the 2 Donors: C6 and 50% Ulnar Nerve**

	C6	50% Ulnar Nerve	<i>P</i>
Axon count, mean ( $\pm$ SD)	3,087 ( $\pm$ 303)	3,535 ( $\pm$ 683)	0.1410
Fiber diameter ( $\mu$ ), mean ( $\pm$ SD)	5.47 ( $\pm$ 0.7)	4.79 ( $\pm$ 0.8)	0.8034
Axon diameter ( $\mu$ ), mean ( $\pm$ SD)	3.61 ( $\pm$ 0.5)	2.99 ( $\pm$ 0.6)	0.8269
Myelin thickness ( $\mu$ ), mean ( $\pm$ SD)	0.92 ( $\pm$ 0.17)	0.9 ( $\pm$ 0.17)	0.9244

## RESULTS

One of the animals from group A died during the second stage of surgery because of overdose of anesthetic. The remaining animals were uneventful during the course of the study.

Table 2 shows the results of all analyzed parameters at all evaluation times (4, 8, 12, and 16 weeks) for group A and B rats. For easy comparison, these complex data were also presented in individual figures (Figs. 2, 3).

### Muscle (Biceps) Function Study

Group A (proximal nerve transfer) demonstrated a trend of progressively improving results that were statistically significant between each time point for the following parameters: grooming test, CMAP, tetanic muscle contraction force, and muscle weight. Group B (distal nerve transfer) showed a statistically significant improvement in these parameters between 4 and 8 weeks only. There were no further significant differences between time points from 8 to 16 weeks.

### Final Outcomes at 16 Weeks (Table 3)

Grooming test at 16 weeks for group A showed a mean value of 4.36. The mean for group B was 3.583, a statistically significant inferior performance ( $P < 0.05$ ).

With respect to CMAPs, the mean value for the control group (nonoperated arms) was 5.06 mV, which was sig-

nificantly higher than the value observed for both experimental groups ( $P < 0.05$ ). The mean CMAP value for group A was 4.42 mV and for group B was 3.09 mV, which was significantly lower than the value for group A ( $P \leq 0.001$ ).

The mean biceps tetanic muscle contraction force was 59.97g for the control group (nonoperative arms), 57.73g for group A, and 40.36g for group B, which was significantly lower than the value for group A ( $P \leq 0.001$ ).

Mean biceps weight for group A was 85% of the non-operative side and for group B was 76.38%, which was significantly lower than the percentage value observed for group A ( $P \leq 0.01$ ).

### Nerve (MCN) Morphology Study

Regarding the recipient (MCN) nerve morphology study, group A showed statistically significant increases in axon counts between 4 and 8 weeks, but plateaued thereafter. Group B reached its peak number of axons at 4 weeks with a significant difference between groups A and B ( $1,409 \pm 260$  vs  $3,738 \pm 597$ ;  $P \leq 0.001$ ) and then it declined (Table 2; Fig. 3).

At 16 weeks, mean axon counts for groups A and B were 2,450 and 3,050, respectively (control, nonoperated arm, was 1,459). Both were statistically significantly higher than the counts in nonoperative arms ( $P \leq 0.001$ ), but the count in group A was significantly lower than that in

**Table 2. Different Outcomes at Different Times of Survival**

	4 wk	8 wk	12 wk	16 wk	P
Grooming test, mean ( $\pm$ SD)					
Group A	1.63 ( $\pm$ 0.8)	3.18 ( $\pm$ 1.25)	3.81 ( $\pm$ 1.16)	4.36 ( $\pm$ 0.67)	4 vs 8 wk, $P \leq 0.01$ ; 4 vs 12 wk, $P \leq 0.001$ ; 4 vs 16 wk, $P \leq 0.001$ ; 8 vs 16 wk, $P \leq 0.05$
Group B	2.72 ( $\pm$ 0.46)	3.16 ( $\pm$ 0.83)	3.25 ( $\pm$ 0.75)	3.58 ( $\pm$ 0.51)	4 vs 16 wk, $P \leq 0.05$
CMAP (operative/nonoperative), mean ( $\pm$ SD)					
Group A	31.74 ( $\pm$ 1.97)	54.27 ( $\pm$ 9.51)	73.42 ( $\pm$ 14.58)	86.06 ( $\pm$ 5.27)	4 vs 8 wk, $P \leq 0.01$ ; 4 vs 12 wk, $P \leq 0.001$ ; 4 vs 16 wk, $P \leq 0.01$ ; 8 vs 16 wk, $P \leq 0.001$
Group B	35.28 ( $\pm$ 9.79)	70.26 ( $\pm$ 8.75)	75.57 ( $\pm$ 11.53)	68.4 ( $\pm$ 11.7)	4 vs 8 wk, $P \leq 0.001$ ; 4 vs 12 wk, $P \leq 0.001$ ; 4 vs 16 wk, $P \leq 0.001$
Tetanic muscle contraction (operative/nonoperative), mean ( $\pm$ SD)					
Group A	37.64 ( $\pm$ 4.18)	57.92 ( $\pm$ 17.74)	64.96 ( $\pm$ 15.22)	93.12 ( $\pm$ 5.99)	4 vs 12 wk, $P \leq 0.05$ ; 4 vs 16 wk, $P \leq 0.001$ ; 8 vs 16 wk, $P \leq 0.01$ ; 12 vs 16 wk, $P \leq 0.05$
Group B	45.48 ( $\pm$ 2.71)	68.8 ( $\pm$ 11.74)	74.36 ( $\pm$ 6.69)	70.96 ( $\pm$ 6.65)	4 vs 8 wk, $P \leq 0.001$ ; 4 vs 12 wk, $P \leq 0.001$ ; 4 vs 16 wk, $P \leq 0.001$
Biceps muscle weight (operative/nonoperative), mean ( $\pm$ SD)					
Group A	48.90 ( $\pm$ 4.85)	63.78 ( $\pm$ 13.66)	76.76 ( $\pm$ 20.31)	85.00 ( $\pm$ 4.31)	4 vs 12 wk, $P \leq 0.014$ ; 4 vs 16 wk, $P \leq 0.001$ ; 8 vs 16 wk, $P \leq 0.01$
Group B	50.20 ( $\pm$ 5.72)	66.42 ( $\pm$ 4.56)	68.12 ( $\pm$ 3.41)	76.3 ( $\pm$ 6.88)	4 vs 8 wk, $P \leq 0.001$ ; 4 vs 12 wk, $P \leq 0.001$ ; 4 vs 16 wk, $P \leq 0.001$ ; 8 vs 16 wk, $P \leq 0.05$
Nerve morphology					
Group A	1,409 ( $\pm$ 260)	2,481 ( $\pm$ 323)	2,685 ( $\pm$ 763)	2,450 ( $\pm$ 399)	4 vs 8 wk, $P \leq 0.01$ ; 4 vs 12 wk, $P \leq 0.001$ ; 4 vs 16 wk, $P \leq 0.01$
Group B	3,738 ( $\pm$ 597)	3,117 ( $\pm$ 426)	2,882 ( $\pm$ 261)	3,050 ( $\pm$ 482)	4 vs 12 wk, $P \leq 0.05$



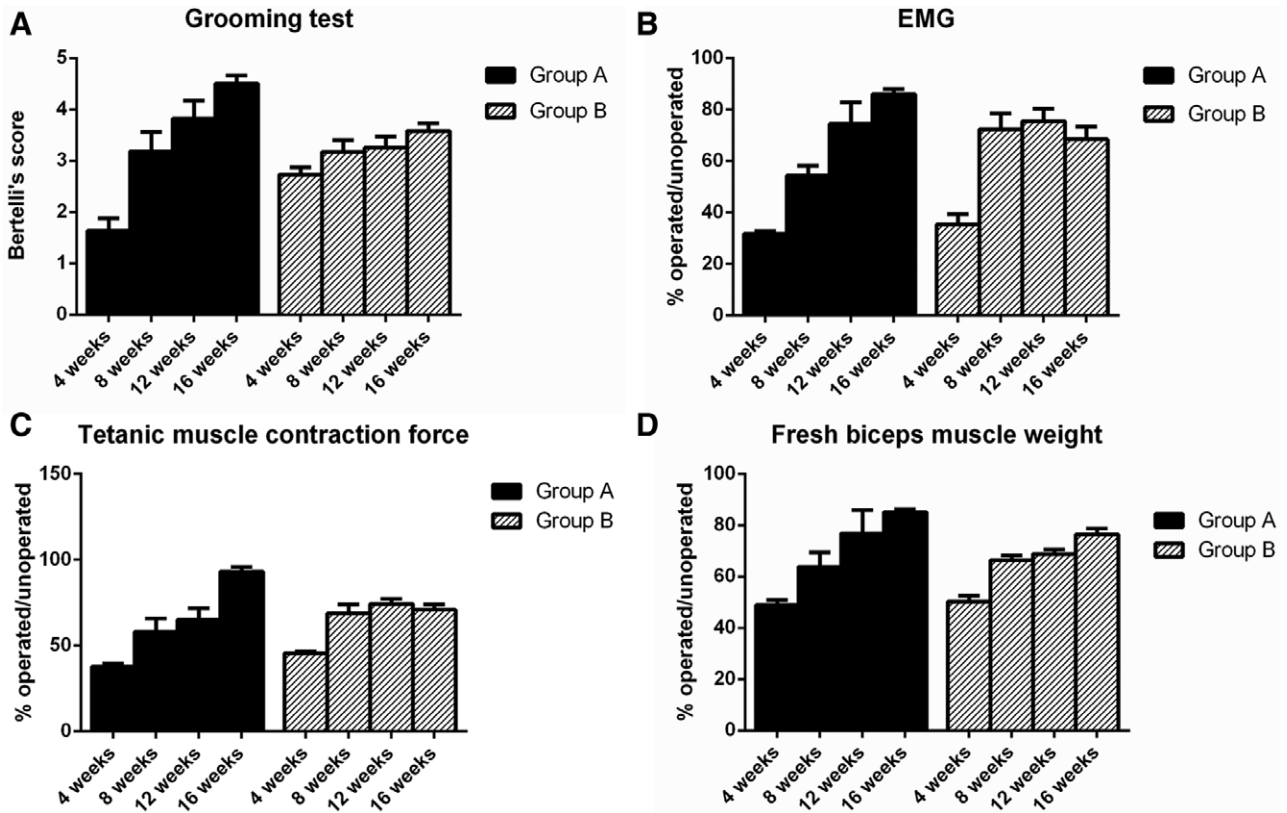


Fig. 2. Comparison of grooming test (A), electromyography (B), biceps tetanic muscle contraction force (C), and biceps muscle weight (D).

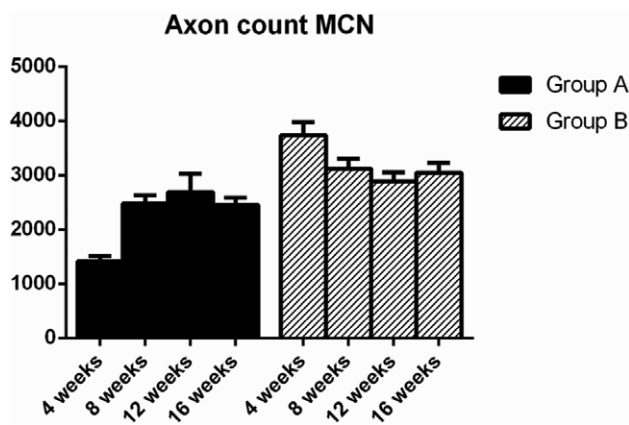


Fig. 3. Axon counts at different time points between groups A and B.

group B ( $P < 0.05$ ; Table 4). The 2 coaptation sites with the interposition of nerve graft in group A was considered the main factor causing its lower axon counts because of delayed arrival and loss of axons.<sup>14,15</sup> The mean axon diameters for myelinated axons in the control MCN, group A, and group B were 4.81, 2.28, and 2.55  $\mu\text{m}$ , respectively (Table 4). Both experimental rat groups were significantly smaller than the nonoperative group ( $P \leq 0.001$ ). Myelin thickness was 1.0  $\mu\text{m}$  for control arms, 0.93  $\mu\text{m}$  for group A, and 0.79  $\mu\text{m}$  for group B. There was no significant difference among the control and experimental groups,

suggesting that the myelin sheath reached similar maturation. Mean fiber diameter for the nonoperated group was 6.86  $\mu\text{m}$ , whereas groups A and B measured 4.16 and 4.14  $\mu\text{m}$ , respectively (Table 4). Thus, the control group had significantly greater diameter than both groups A and B ( $P \leq 0.001$ ), but there was no significant difference between groups A and B.

## DISCUSSION

Simulating human brachial plexus reconstruction in a rat model is challenging. Our study design aimed to eliminate as many obstacles as possible. For the nerve graft, we chose 1-cm length because it is impossible to reproduce a longer graft in the rat model for proximal nerve transfer.<sup>16</sup> For the interval between injury (first stage) and reconstruction (second stage), we chose 4 days as an acute BPI to facilitate dissection, simplify identification of spinal nerves, and avoid sequelae of chronic denervation.

With regard to the distance from the donor nerve transection site to the end organ (biceps muscle), the main concern with this study is the appropriateness of the animal model to a human scenario of BPI. In this study, the distance noted in group A (35 mm) was 20 mm longer than the distance noted in group B (15 mm), more than twice (2.3:1) the distance noted in group A. We tried to make this difference in distance between the 2 groups as large as possible, to have it as closely analogous to the difference between proximal and distal nerve transfers in humans as possible. Our rat model is probably more similar to the

**Table 3. Results of Biceps Muscle at 16 Weeks**

	Control (Nonoperative Limb)	Group A	Group B	P
Grooming test (Bertelli's score), mean (±SD)	5	4.36 (±0.67)	3.58 (±0.51)	Group A vs B, $P \leq 0.05$
CMAP (mV), mean (±SD)	5.06 (±0.62)	4.42 (±0.77)	3.09 (±0.34)	Group A vs B, $P \leq 0.001$ ; group A vs control, $P \leq 0.05$ ; group B vs control, $P \leq 0.001$
Tetanic muscle contraction (g), mean (±SD)	59.97 (±12.64)	57.73 (±7.14)	40.36 (±7.73)	Group A vs control, $P \leq 0.05$ ; group B vs control, $P \leq 0.001$
Biceps muscle weight (%; operative/nonoperative), mean (±SD)	100	85 (±4.31)	76.38 (±6.88)	Group A vs B, $P \leq 0.01$

**Table 4. Results of Morphology of the MCN at 16 Weeks**

	Control (Nonoperative Arm)	Group A	Group B	P
Axon counts, mean (±SD)	1,459 (±217)	2,450 (±399)	3,050 (±482)	Group A vs control, $P \leq 0.001$ ; group B vs control, $P \leq 0.001$ ; group A vs B, $P \leq 0.05$ ; group B vs C, $P \leq 0.05$
Axon diameter, mean (±SD)	4.81 (±0.6)	2.28 (±0.19)	2.55 (±0.27)	Group A vs control, $P \leq 0.001$ ; group B vs control, $P \leq 0.001$ ; group C vs control, $P \leq 0.001$
Myelin thickness, mean (±SD)	1.00 (±0.19)	0.93 (±0.2)	0.79 (±0.09)	
Fiber diameter, mean (±SD)	6.86 (±0.77)	4.16 (±0.35)	4.14 (±0.34)	Group A vs control, $P \leq 0.001$ ; group B vs control, $P \leq 0.001$ ; group C vs control, $P \leq 0.001$

infant obstetric brachial plexus palsy patients<sup>17,18</sup> in terms of nerve regenerative capacity and distance.

We divided all C6 branches for shoulder abduction, leaving the C6 spinal nerve, anterior division of upper trunk, lateral cord, and MCN in continuity to isolate elbow flexion in the study. We also divided MCN after the biceps branch and transferred back to the biceps muscle to avoid loss of regenerated axons.

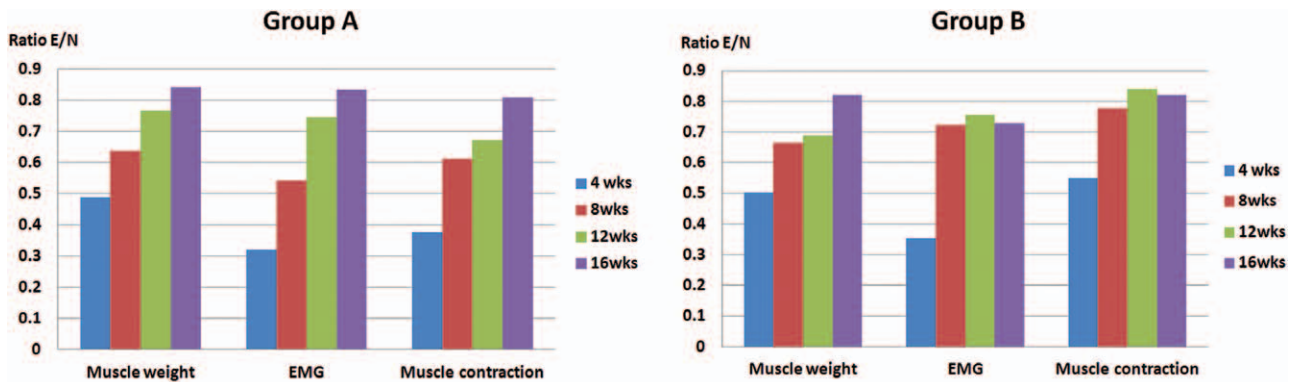
Based on previous studies,<sup>19</sup> we hypothesized that the donor nerves in this study, C6 versus 50% of ulnar nerve, are equal in power based on axon counts and nerve morphology. With donor nerve morphology and axonal numbers essentially equal, it is reasonable to assume that the results are reflective of the difference in proximal versus distal nerve transfers. At 16 weeks, all experimental rats' MCN showed higher axon counts (2,450 [±399] in group A and 3,050 [±482] in group B) compared with control (nonoperated side; 1,459 [±217]). This is consistent with previous findings describing that the number of axons sprouting in the distal stump will outnumber those in proximal stump up to 5:1.<sup>20</sup>

Fox et al<sup>21</sup> transected and repaired the rat's sciatic nerve with and without nerve graft. They found that the number of myelinating axons rose between 1 and 3 months and then plateaued. In our study, axon count reached a peak at 12 weeks (group A) and 4 weeks (group B) after which it plateaued. This observation may be analogous to the trend described by Fox et al.<sup>21</sup> Increased sprouting does not necessarily translate into improved regeneration. More immature axons and misdirection of axons can potentially lead to poor functional results.<sup>22–25</sup> This is a possible explanation for the inferior outcome parameters in group B as compared with group A, despite the higher axon counts.

Two major contributing factors potentially explain the superior outcomes of group A. First, less cortical adaptation was required in group A rats. The C6 spinal nerve transfer presumably reflects a more similar central nervous sensorimotor representation. Group A underwent a more natural rehabilitation because of the advantage of using the native nerve to restore the native function of the injured nerve. Clinically, in adult BPI, after a distal nerve transfer reconstruction, a specialized rehabilitation protocol with induction exercise<sup>4</sup> aiming at inducing activity-dependent adaptive changes of the central nervous system to generate the nonnative function is required to achieve good outcome.

Secondly, it is possible that there are a higher proportion of motor units in C6 (group A) than in the 50% ulnar nerve (group B) donor nerves.<sup>26,27</sup> These factors could explain the better outcomes in the proximal nerve transfer group despite the lower number of axons and greater regeneration distance.

As seen in Figure 4 and individually in Figure 2, group A demonstrated a trend of progressively improving results, statistically significant between each time point for the parameters of grooming test, CMAPs, tetanic muscle contraction force, and muscle weight. Group B showed a statistically significant improvement in these parameters only between 4 and 8 weeks. After the 8-week time point, group B results reached a plateau. An analogous situation can be observed clinically in facial palsy reconstruction by functioning muscle transplantation, innervated by cross-face nerve graft versus masseter nerve. Cross-face nerve graft–innervated gracilis provides superior result, usually reaching maturation in the third year of follow-up, with a spontaneous and synchronous smile.<sup>28</sup> In contrast, masseter nerve–innervated gracilis muscle



**For all measured parameters , it shows with time**

- An increasing trend for proximal nerve transfer, but
- A flat trend for distal nerve transfer

**Fig. 4.** A combined figure from Figure 2 showed an increasing trend for proximal nerve transfer group for all measured parameters, but a plateau for distal nerve transfer group after week 8.

reconstruction provides quicker result within 6–12 months, but with less natural and synchronous movement as time goes by.<sup>29</sup> Similar situations can also be found in obstetric brachial plexus palsy reconstruction. Further studies to investigate this phenomenon, including fMRI,<sup>30</sup> to confirm the existence of proximal nerve transfers, which will progressively improve when time passes, is warranted.

### CONCLUSIONS

Our experimental model showed that the recovery after a proximal nerve transfer was superior to that achieved with a distal nerve transfer. Progressive functional gains and improvement in nerve and muscle physiologic parameters are characteristics of the proximal nerve transfer cohort. Possible explanations for the better results include reduced need for cortical adaptation and the likelihood of higher proportions of motor units in the proximal nerve transfer rats.

**David C. Chuang, MD**

Department of Plastic Surgery  
Chang Gung Memorial Hospital  
Taipei-Linkou  
Taiwan

E-mail: dccchuang@gmail.com  
Office: micro.cgmh@gmail.com

### ACKNOWLEDGMENTS

The authors thank research assistants of Plastic and Reconstructive Surgery, Chang Gung Memorial Hospital, Taoyuan, and Ms. Pei-Ju Chen and Ms. Yi-Ching Liu for their professional and continuous technical assistance throughout this study.

### REFERENCES

1. Oberlin C, Béal D, Leechavengvongs S, et al. Nerve transfer to biceps muscle using a part of ulnar nerve for C5-C6 avulsion of the brachial plexus: anatomical study and report of four cases. *J Hand Surg Am.* 1994;19:232–237.

2. Tung TH, Mackinnon SE. Nerve transfers: indications, techniques, and outcomes. *J Hand Surg Am.* 2010;35:332–341.
3. Ray WZ, Chang J, Hawasli A, et al. Motor nerve transfers: a comprehensive review. *Neurosurgery* 2016;78:1–26.
4. Chuang DC. Brachial plexus injuries: adult and pediatric. In: Neligan P, ed. *Plastic Surgery*. 3rd ed. Philadelphia, PA: Saunders Elsevier; Volume VI, 2013:789–816.
5. Mackinnon SE, Novak CB. Nerve transfers. New options for reconstruction following nerve injury. *Hand Clin.* 1999;15:643–666, ix.
6. Flores LP. Comparative study of nerve grafting versus distal nerve transfer for treatment of proximal injuries of the ulnar nerve. *J Reconstr Microsurg.* 2015;31:647–653.
7. Zuckerman SL, Eli IM, Shah MN, et al. Radial to axillary nerve neurotization for brachial plexus injury in children: a combined case series. *J Neurosurg Pediatr.* 2014;14:518–526.
8. Hems T. Nerve transfers for traumatic brachial plexus injury: advantages and problems. *J Hand Microsurg.* 2011;3:6–10.
9. Garg R, Merrell GA, Hillstrom HJ, et al. Comparison of nerve transfers and nerve grafting for traumatic upper plexus palsy: a systematic review and analysis. *J Bone Joint Surg Am.* 2011;93:819–829.
10. Yang LJ, Chang KW, Chung KC. A systematic review of nerve transfer and nerve repair for the treatment of adult upper brachial plexus injury. *Neurosurgery* 2012;71:417–429; discussion 429.
11. Rodriguez A, Chuang DC, Chen KT, et al. Comparative study of single-, double-, and triple-nerve transfer to a common target: experimental study of rat brachial plexus. *Plast Reconstr Surg.* 2011;127:1155–1162.
12. Bertelli JA, Mira JC. Behavioral evaluating methods in the objective clinical assessment of motor function after experimental brachial plexus reconstruction in the rat. *J Neurosci Methods* 1993;46:203–208.
13. Tzou CH, Chuang DC, Chang TN, et al. The impact of different degrees of injured c7 nerve transfer: an experimental rat study. *Plast Reconstr Surg Glob Open* 2014;2:e230.
14. Welin D, Novikova LN, Wiberg M, et al. Survival and regeneration of cutaneous and muscular afferent neurons after peripheral nerve injury in adult rats. *Exp Brain Res.* 2008;186:315–323.
15. Jonsson S, Wiberg R, McGrath AM, et al. Effect of delayed peripheral nerve repair on nerve regeneration, Schwann cell function and target muscle recovery. *PLoS One* 2013;8:e56484.

16. Wang L, Jiang Y, Lao J, et al. Contralateral C7 transfer to lower trunk via the prespinal route in the repair of brachial plexus injury: an experimental study in rats. *J Plast Reconstr Aesthet Surg*. 2014;67:1282–1287.
17. Chuang DC, Mardini S, Ma HS. Surgical strategy for infant obstetrical brachial plexus palsy: experiences at Chang Gung Memorial Hospital. *Plast Reconstr Surg*. 2005;116:132–142; discussion 143.
18. Lauretti L, Pallini R, Romani R, et al. Lower trunk of brachial plexus injury in the neonate rat: effects of timing repair. *Neurol Res*. 2009;31:518–527.
19. Santos AP, Suaid CA, Fazan VP, et al. Microscopic anatomy of brachial plexus branches in Wistar rats. *Anat Rec (Hoboken)*. 2007;290:477–485.
20. Mackinnon SE, Dellon AL, O'Brien JP. Changes in nerve fiber numbers distal to a nerve repair in the rat sciatic nerve model. *Muscle Nerve* 1991;14:1116–1122.
21. Fox IK, Brenner MJ, Johnson PJ, et al. Axonal regeneration and motor neuron survival after microsurgical nerve reconstruction. *Microsurgery* 2012;32:552–562.
22. Cuppini R, Ambrogini P, Sartini S, et al. The role of sensory input in motor neuron sprouting control. *Somatosens Mot Res*. 2002;19:279–285.
23. Yen LD, Bennett GJ, Ribeiro-da-Silva A. Sympathetic sprouting and changes in nociceptive sensory innervation in the glabrous skin of the rat hind paw following partial peripheral nerve injury. *J Comp Neurol*. 2006;495:679–690.
24. Xu QG, Midha R, Martinez JA, et al. Facilitated sprouting in a peripheral nerve injury. *Neuroscience* 2008;152:877–887.
25. English AW. Enhancing axon regeneration in peripheral nerves also increases functionally inappropriate reinnervation of targets. *J Comp Neurol*. 2005;490:427–441.
26. Wood MD, Kemp SW, Weber C, et al. Outcome measures of peripheral nerve regeneration. *Ann Anat*. 2011;193:321–333.
27. Irintchev A. Potentials and limitations of peripheral nerve injury models in rodents with particular reference to the femoral nerve. *Ann Anat*. 2011;193:276–285.
28. Chuang DC. Free tissue transfer for the treatment of facial paralysis. *Facial Plast Surg*. 2008;24:194–203.
29. Chuang DC, Lu JC, Anesti K. One-stage procedure using spinal accessory nerve (XI)-innervated free muscle for facial paralysis reconstruction. *Plast Reconstr Surg*. 2013;132:117e–129e.
30. Romeo M, Vizioli L, Breukink M, et al. A functional magnetic resonance imaging paradigm to identify distinct cortical areas of facial function: a reliable localizer. *Plast Reconstr Surg*. 2013;131:527e–533e.