

## Case Report

## A case of pure gelastic seizures due to hypothalamic hamartoma with a benign course☆

T.D. Gosavi<sup>a,b,\*</sup>, M.C. Walker<sup>a</sup><sup>a</sup> Dept. of Clinical and Experimental Epilepsy, National Hospital of Neurology and Neurosurgery, London, UK<sup>b</sup> National Neuroscience Institute and Singapore General Hospital, Singapore

## ARTICLE INFO

## Article history:

Received 21 November 2016

Received in revised form 31 May 2017

Accepted 11 June 2017

Available online 16 June 2017

## Keywords:

Gelastic seizures

Hypothalamic hamartoma

Benign outcome

## ABSTRACT

Hypothalamic hamartoma is a potentially complex entity with diverse clinical manifestations. We report a case of gelastic seizures associated with a hypothalamic hamartoma, which followed a benign course. A 31-year-old woman with episodes of laughter was referred for diagnostic evaluation. Her initial MRI and EEG were reported as normal. However, her episodes of laughter were typical of gelastic seizures from history and video review. Repeat MRI revealed a small HH. She declined any medical treatment and was medication free until last follow-up. This benign course of HH-associated epilepsy, not necessitating treatment, to our knowledge, has not been previously reported.

© 2017 The Authors. Published by Elsevier Inc. This is an open access article under the CC BY-NC-ND license (<http://creativecommons.org/licenses/by-nc-nd/4.0/>).

## 1. Introduction

Hypothalamic hamartoma (HH) may have diverse clinical manifestations. Its hallmark association is with gelastic seizures, often with other seizure types, cognitive-behavioral issues and occasionally precocious puberty. We report a case of pure gelastic seizures from childhood, associated with a hypothalamic hamartoma in a now 31-year-old woman, which followed a benign course.

## 2. Case report

A 31-year-old right-handed woman presented with episodes of brief mirthless laughter, which she had since she was a baby. Over the years, they had become less frequent, less intense and briefer.

Prior to these episodes, she gets a sinking feeling like a “feeling of dread” in her neck and chest. Within seconds, she has a mirthless laughter during which she remains conscious. During more prolonged episodes, she may also weep. During the episode, she has trouble breathing, occasionally gets flushed, is unable to swallow and her speech is interrupted. Each episode currently lasts a second or two, but, in the past, they have lasted up to 2 to 3 min. She currently has about one attack per day, usually within an hour of waking.

The gelastic seizures, apart from being brief are also mild, in the sense that she is able to disguise her laughter on most occasions. The

attacks were more frequent in the past, with clusters of 6–7 attacks per day, and had woken her from sleep. During her childhood, her parents used to ask her to stop doing it as they thought it was a behavioral mannerism.

Prior to her referral to us, she had an MRI of her brain, which was reported as normal. She had EEGs, and on two occasions she had the episodes of laughter without any obvious change in the EEG. The interictal EEG demonstrated occasional sharp theta waves particularly over the left temporal region but no unequivocal epileptiform activity. She was given trials of treatment with levetiracetam and lamotrigine but without benefit, hence these were discontinued. The patient preferred to be on no medications due to the benign nature of her episodes.

Although our patient did not have a detailed neuropsychological evaluation, she did not complain of any cognitive deficits and hence never had a formal neurocognitive assessment done. She is educated to the university level and is currently working in a local government job without any issues.

A video of episodes were entirely typical for gelastic seizures, with brief episodes of mirthless laughter during which she looked distressed. A repeat MRI revealed a very small, 5 mm, area of signal abnormality in the midline just postero-superior to the tuber cinereum and above the mammillary bodies which was hyperintense on T2 and FLAIR sequences, consistent with a very small HH (Fig. 1). A diagnosis of gelastic seizures secondary to a HH was made.

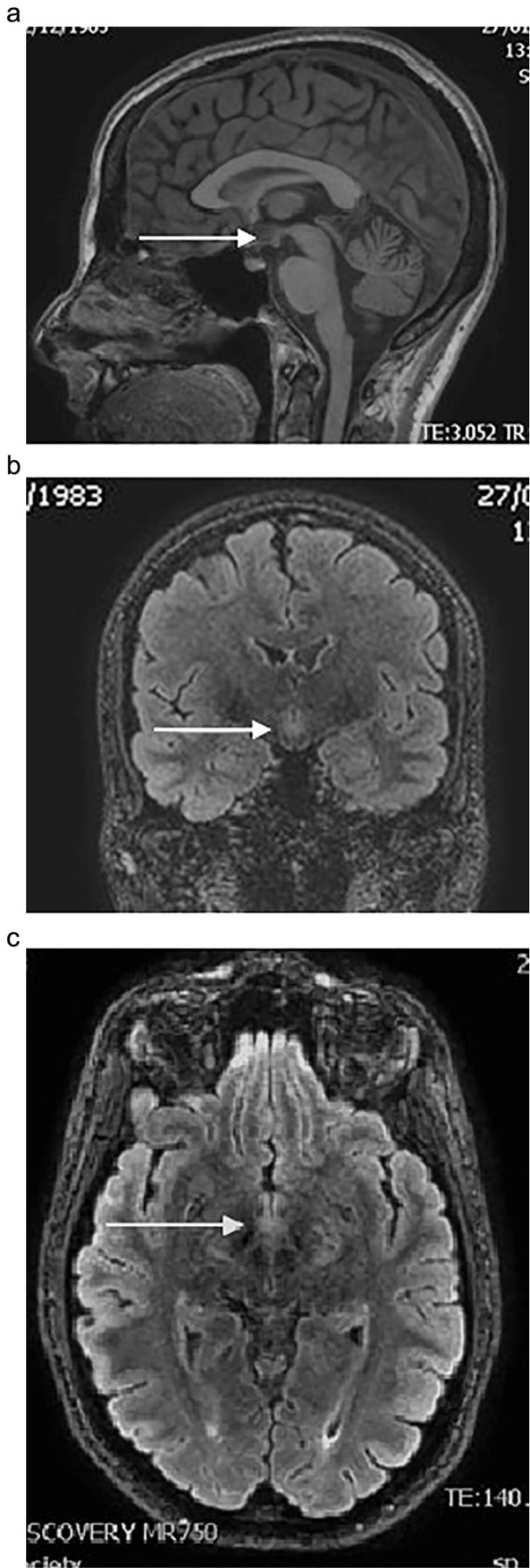
## 3. Discussion

Hypothalamic hamartomas are rare, congenital malformations that present with diverse clinical features, including precocious puberty, drug-resistant seizures, cognitive and behavioral impairment and

☆ The work described has not been published previously.

\* Corresponding author at: Dept. of Clinical and Experimental Epilepsy, National Hospital of Neurology and Neurosurgery, 33 Queen Square, London, UK.

E-mail addresses: [tushar.gosavi.divakar@singhealth.com.sg](mailto:tushar.gosavi.divakar@singhealth.com.sg) (T.D. Gosavi), [m.walker@ucl.ac.uk](mailto:m.walker@ucl.ac.uk) (M.C. Walker).



**Fig. 1.** a: T1 sagittal image showing the HH which appears as a slight hypointense lesion above mammillary bodies. b: T2 FLAIR coronal image showing the HH which appears hyperintense. c: T2 transverse images showing the HH.

developmental delay especially in pediatric populations [1]. Our case is unusual because of the benign course of the epilepsy. The benign course here implies a benign phenotype. The seizure severity and frequency have improved over the years. Associated features like precocious puberty, cognitive-behavioral issues, and other seizure types are lacking. She is off antiseizure medications and yet living a productive life.

The semiology of our patient's gelastic seizures was typical for that associated with hypothalamic hamartomas. Gelastic seizures in adults can also be associated with temporal and frontal lobe epilepsies [2]. A mirthless laughter with preserved consciousness is typical of gelastic seizures associated with HH. Amongst non-HH related gelastic seizures, mirthless laughter occurs more so with frontal lobe epilepsy than with temporal lobe epilepsy. This is because the frontal lobe structures control the motor aspect of laughter whereas the temporal lobe structures are associated with the emotional element [3]. Our patient also had other typical features of HH-associated gelastic seizures, including autonomic symptoms such as flushing, tachycardia and altered respiration [4]. Hypothalamic hamartomas are also associated with dacrytic seizures [5]. Interestingly, as in our patient, gelastic and dacrytic components could be seen in a single seizure as has been previously reported [6].

The seizures associated with HH are often considered to have a progressive element. Pure gelastic seizures are a hallmark of seizures with HH in pediatric population, but in adults with HH, the seizures often become more elaborate with auras and behavioral arrest as common features [7]. In a study of 100 patients with HH, seizures of this kind were labeled as gelastic plus type. These gelastic plus type seizures included focal seizures with impaired awareness should be substituted for complex partial, generalized tonic clonic, tonic, epileptic spasms, simple focal and atonic seizures in that order of frequency [8]. However, our patient had pure gelastic seizures despite 30 years of epilepsy (mostly on no treatment). This contrasts with the observation that the longer the duration of epilepsy, the higher the incidence of gelastic-plus type seizures [8]. Hamartoma diameter of greater than 1 cm is associated with gelastic-plus seizure types [9], and the small size of the hamartoma in our patient may explain this discrepancy.

Mild forms of epilepsy, though not common, have been reported in association with HHs. In a case series, one of the nineteen patients was reported to have less severe epilepsy. Surprisingly this particular patient did not have gelastic seizures but only drop attacks and atypical absences [9].

During gelastic seizures, the interictal and ictal EEG is often normal or may show only non-specific abnormalities. This fact might contribute to the diagnostic difficulty of these episodes [10]. Although, interictally, cortical spikes can be recorded on scalp EEG, their origin is likely from the subcortical structures near the hamartoma with late spread to the cortex [11]. Intrinsic hypothalamic epileptogenesis as the origin of gelastic seizures has been documented with hypothalamic electrode placements [12]. Gelastic plus type seizures may have more varied EEG patterns and can occasionally be mislocalized to temporal lobes which could result in an unwarranted temporal lobectomy.

The majority of patients with hypothalamic hamartomas and epilepsy have some degree of cognitive impairment as well as mood and behavioral issues. Hypothalamic hamartoma volume [13], presence of precocious puberty, number of antiseizure drugs and anatomical classification of HH are associated with cognitive decline [14]. In addition, it has been proposed that the gelastic plus type seizures, if frequent, could contribute to the cognitive and behavioral issues [15]. But to complicate the matter of understanding factors responsible for cognitive impairment, in a series of six patients with HH, three had no cognitive or behavioral disturbances despite all having gelastic plus type seizures. But all these three patients had smaller HHs making it likely that any of the factors mentioned above, independently, could play a role in cognitive disturbances [16]. Our patient had none of the predisposing factors, which might explain the absence of cognitive and behavioral manifestations.

Hypothalamic hamartomas, by virtue of their near normal hypothalamic tissue, are isointense to mildly hypointense on T1 and are iso- to

hyperintense on T2 weighted images. They do not grow in size. They are classified as either parahypothalamic or intrahypothalamic depending on their location. It has been observed that the pedunculated parahypothalamic hamartomas are more likely to be associated with precocious puberty and sessile intrahypothalamic ones are associated with gelastic seizures [17]. Increased size and contact with the pituitary stalk are other factors associated with precocious puberty [18]. Our patient had an intrahypothalamic sessile, small HH, supporting the absence of a history of precocious puberty and the presence of gelastic seizures.

The surgical treatment of HHs has evolved. Newer minimally invasive methods like stereotactic laser ablation [19] and stereotactic radiofrequency thermocoagulation [20] have shown promising results in patients with HH.

#### 4. Conclusion

We report a unique case of HH with a benign outcome, not requiring any form of treatment, which to our knowledge has never been previously reported. The small size of the HH and intrahypothalamic sessile hamartoma probably account for lack of precocious puberty, while the former together with lack of exposure to antiseizure medications accounts for lack of cognitive–behavioral symptoms. Pure gelastic seizures can occur in adults although gelastic plus type seizures more often occur.

Importantly, our case also highlights the relevance of recognizing the association of gelastic seizures with HH, which can be easily overlooked, on routine MRI scans, as they may be small with minimal signal change on conventional sequences.

#### Conflict of interest

None of the authors has any conflict of interest.

#### References

- [1] Berkovic SF, Arzimanoglou A, Kuzniecky R, Harvey AS, Palmini A, Andermann F. Hypothalamic hamartoma and seizures: a treatable epileptic encephalopathy. *Epilepsia* 2003;44:969–73.
- [2] Kovac S, Diehl B, Wehner T, Fois C, Toms N, Walker MC, et al. Gelastic seizures: incidence, clinical and EEG features in adult patients undergoing video-EEG telemetry. *Epilepsia* 2015;56(1):e1–5.
- [3] Wild B, Rodden FA, Grodd W, Ruch W. Neural correlates of laughter and humour. *Brain* 2003;126:2121–38.
- [4] Cerullo A, Tinuper P, Provini F, Contin M, Rosati A, Marini C, et al. Autonomic and hormonal ictal changes in gelastic seizures from hypothalamic hamartomas. *Electroencephalogr Clin Neurophysiol* 1998;107:317–22.
- [5] Brenningstall GN. Gelastic seizures, precocious puberty and hypothalamic hamartoma. *Neurology* 1985;35:1180–3.
- [6] Kahane P, Munari C, Minotti L. The role of hypothalamic hamartoma in the genesis of gelastic and dacrystic seizures. In: Tuxhorn I, Hothausen H, Boenigk K, editors. *Paediatric epilepsy syndromes and their surgical treatment*. London: John Libbey; 1997. p. 447–61.
- [7] Oehl B, Brandt A, Fauser S, Bast T, Trippel M, Schulze-Bonhage A. Semiologic aspects of epileptic seizures in 31 patients with hypothalamic hamartoma. *Epilepsia* 2010;51:2116–23.
- [8] Pravizi J, Le S, Foster BL, Bourgeois B, Riviello JJ, Prenger E, et al. Gelastic epilepsy and hypothalamic hamartomas: neuroanatomical analysis of brain lesions in 100 patients. *Brain* 2011;134:2960–8.
- [9] Mullatti N, Selway R, Nashef L, Elwes R, Honavar M, Chandler C, et al. The clinical spectrum of epilepsy in children and adults with hypothalamic hamartoma. *Epilepsia* 2003;44:1310–9.
- [10] Sturm JW, Andermann F, Berkovic SF. “Pressure to laugh”: an unusual epileptic symptom associated with small hypothalamic hamartomas. *Neurology* 2000;54:971–3.
- [11] Leal AJ, Passao V, Calado E, Vieira JP, Silva Cunha JP. Interictal spike EEG source analysis in hypothalamic hamartoma epilepsy. *Clin Neurophysiol* 2002;113:1961–9.
- [12] Fukuda M, Kameyama S, Wachi M, Tanaka R. Stereotaxy for hypothalamic hamartoma with intractable gelastic seizures: technical case report. *Neurosurgery* 1999;44(6):1347–50.
- [13] Prigatano GP, Wethe JV, Gray JA, et al. Intellectual functioning in presurgical patients with hypothalamic hamartoma and refractory epilepsy. *Epilepsy Behav* 2008;13:149–55.
- [14] Ali S, Moriarty J, Mullatti N, David A. Psychiatric comorbidity in adult patients with hypothalamic hamartoma. *Epilepsy Behav* 2006;9:111–8.
- [15] Kuzniecky R, Guthrie B, Mountz J, Bebin M, Faught E, Gilliam F, et al. Intrinsic epileptogenesis of hypothalamic hamartomas in gelastic epilepsy. *Ann Neurol* 1997;42:60–7.
- [16] Striano Salvatore, Striano Pasquale, Sarappa Chiara, Boccella Patrizia. The clinical spectrum and natural history of gelastic epilepsy–hypothalamic hamartoma syndrome. *Seizure* 2005;14:232–9.
- [17] Arita K, Ikawa F, Kurisu K, Sumida M, Harada K, Uozumi T, et al. The relationship between magnetic resonance imaging findings and clinical manifestations of hypothalamic hamartoma. *J Neurosurg* 1999;91:212–20.
- [18] Freeman JL, Coleman LT, Wellard RM, Kean MJ, Rosenfeld JV, Jackson GD, et al. MR imaging and spectroscopic study of epileptogenic hypothalamic hamartomas: analysis of 72 cases. *Am J Neuroradiol* 2004;25:450–62.
- [19] Wilfong AA, Curry DJ. Hypothalamic hamartomas: optimal approach to clinical evaluation and diagnosis. *Epilepsia* Dec 2013;54(Suppl. 9):109–14.
- [20] Kameyama S, Shirozu H, Masuda H, Ito Y, Sonoda M, Akazawa K. MRI-guided stereotactic radiofrequency thermocoagulation for 100 hypothalamic hamartomas. *J Neurosurg* May 2016;124(5):1503–12.