



Contents lists available at ScienceDirect

International Journal of Surgery Case Reports

journal homepage: www.casereports.comGallbladder perforation: A rare complication of enteric fever[☆]Mahendra Singh^{a,*}, Lovekesh Kumar^a, Rashpal Singh^a, Aaron K. Jain^b, Snehal K. Karande^b, Arjun Saradna^a, U. Prashanth^a^a Department of Surgery, Vardhaman Mahavir Medical College and Safdarjung Hospital, New Delhi, India^b Department of Surgery, Hindu Rao Hospital, New Delhi, India

ARTICLE INFO

Article history:

Received 23 December 2012

Received in revised form

27 November 2013

Accepted 5 December 2013

Available online 12 December 2013

Keywords:

Gallbladder

Perforation

Enteric fever

ABSTRACT

INTRODUCTION: Gallbladder perforation is a rare complication of acute calculous cholecystitis in adults. Perforation of gallbladder due to enteric fever is extremely rare condition. Pre-operative diagnosis is rarely made and mortality is high.

PRESENTATION OF CASE: We report a case of acalculous gallbladder perforation following enteric fever in a 14-year-old boy, who presented as acute abdomen and responded very well after emergency laparotomy and cholecystectomy.

DISCUSSION: Enteric fever is common in tropics and a common cause of bowel perforation. Acute cholecystitis is a rare complication of typhoid and gallbladder perforation is extremely rare complication. Ultrasound and CT lack specificity to detect gallbladder perforation. Diagnosis is usually made intra-operatively. Cholecystectomy is treatment of choice in such cases and provides good result.

CONCLUSION: Gallbladder perforation secondary to enteric fever requires a high degree of clinical suspicion. In typhoid endemic region, it should be considered as a differential diagnosis in patient presenting with a history of prolonged fever and signs of peritonitis. Early diagnosis and immediate surgical intervention are very important in reducing the morbidity and mortality. Cholecystectomy is the choice with a good outcome.

© 2013 The Authors. Published by Elsevier Ltd on behalf of Surgical Associates Ltd. All rights reserved.

1. Introduction

Gallbladder perforation is a rare entity in surgical practice.^{1,2} It has been reported in adults following an episode of acute calculous cholecystitis.^{1,2} Perforation of acalculous gallbladder in association with enteric fever is extremely rare, especially in children.^{1,2} Pre-operative diagnosis is difficult and mortality rate is high.² We report a rare case of enteric perforation of acalculous gallbladder in a 14-year-old boy, who presented with acute abdomen and responded very well after immediate surgical intervention.

2. Presentation of case

A 14-year-old boy presented with history of diffuse abdominal pain since three days and not passing flatus and motion since 2 days. He was having high grade, continuous fever since 2 weeks. There was no relevant past medical history. On general examination, patient was looking very toxic. He was having tachycardia

(120/min), tachypnoea and fever. Blood pressure was 80/50 mmHg. Abdominal examination revealed abdominal distension, muscle guarding, generalized abdominal tenderness and sluggish bowel sounds. Haemoglobin was 8 g/dl, platelets count was 96,000/ μ l and WBC count was 1600/ μ l (Neutrophil 64%, lymphocyte 28%). Peripheral smear showed normocytic, normochromic red blood cells with mild anisocytosis, severe leukopenia and mild thrombocytopenia. Liver function test, kidney function test and coagulation profile were in normal range. The Widal test was highly positive for *Salmonella typhi*. An erect abdominal radiograph revealed multiple air-fluid levels and there was no free gas under the diaphragm. Abdominal ultrasonography demonstrated hepatosplenomegaly and gross ascites with fine internal echoes, suggestive of perforation.

Provisional diagnosis of enteric perforation of small bowel was made. After resuscitation, patient was explored by midline incision. Peritoneal cavity was containing 2l of bilious fluid and bowel loops were appeared to be normal. On further exploration, gallbladder appeared to be grossly inflamed and there was a single perforation of around 1 cm in size at the fundus (Figs. 1 and 2). We looked carefully for gallstones in gallbladder, cystic duct and peritoneal cavity but not found. Common bile duct appeared to be normal. Cholecystectomy was done and pelvic drain was placed after through peritoneal lavage. Post-operatively, intra-venous ceftriaxone and gentamicin were administered for 7 days. There was an uneventful recovery and patient was discharged on 9th

[☆] This is an open-access article distributed under the terms of the Creative Commons Attribution-NonCommercial-No Derivative Works License, which permits non-commercial use, distribution, and reproduction in any medium, provided the original author and source are credited.

* Corresponding author at: 478-B, First Floor, Hardevpuri, Gautam Nagar, New Delhi 110049, India. Tel.: +91 9654739092.

E-mail address: dr.mahi118@gmail.com (M. Singh).

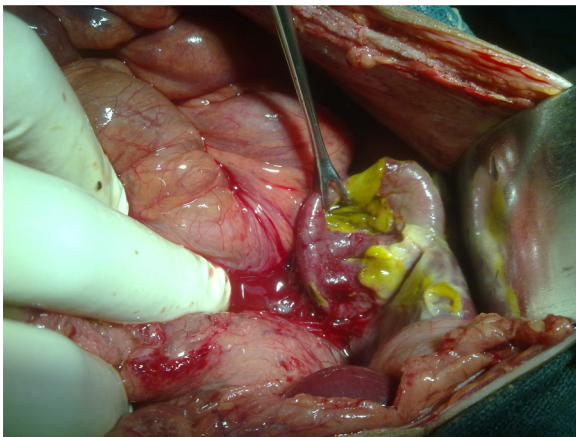


Fig. 1. Intra-operative view of gallbladder.

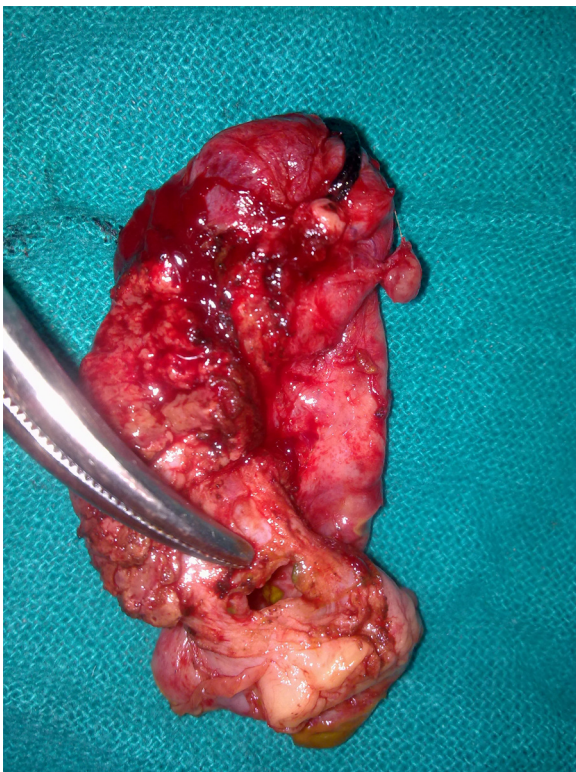


Fig. 2. Perforation at fundus of gallbladder.

post-operative day. Culture of bile and peritoneal fluid were positive for *Salmonella typhi* and *Escherichia coli* respectively. Histological examination revealed acute inflammatory infiltrate and transmural necrosis of gallbladder.

3. Discussion

Enteric fever is caused by *Salmonella typhi*, *S. paratyphi* A, and rarely by *S. paratyphi* B and C.³ It is common in developing countries due to poor water quality and sanitation.³ Recent estimates suggest 27 million cases worldwide and more than 200,000 deaths.³ It is an acute systemic disease consisting of fever, malaise, transient rash, hepatosplenomegaly, abdominal discomfort and pancytopenia.^{3,4} It is an intracellular infection involving the reticuloendothelial

system, particularly bone marrow, liver and spleen.⁴ Bacterial count in bone marrow is 10 fold higher in compare to blood.⁴ Bone marrow examination may show marked phagocytosis of platelets, leukocytes, and red blood cells.⁴ This phagocytosis may contribute to the pancytopenia in enteric fever.⁴ Typhoid is a common cause of bowel perforation in tropics.⁵ Acute cholecystitis is a rare complication of typhoid and gallbladder perforation is extremely rare.⁶ Incidence of gallbladder perforation is around 3–10% and mortality rate is high around 12–16%. Mortality rate is high in gallbladder perforation in compare to bowel perforation.^{1,7,8} Gali et al. reported 2 cases of gallbladder perforation due to enteric fever in two boys aged 13 years and 16 years.⁹ Our patient was from tropic and was having fever, abdominal discomfort, anaemia, leukopenia, hepatosplenomegaly and Widal positivity, all suggestive of enteric infection.

Roslyn et al. observed that gallbladder perforation is more common in older age group.¹⁰ In elderly, perforation usually occurs in setting of cholelithiasis associated with obstruction leading to raised intra luminal pressure.^{10,11} Perforation appeared to be result of compromised blood supply and least vascularised fundus is the most common site.^{10,11}

In contrast, acalculous cholecystitis without obstruction is unlikely to result in perforation.^{10,11} In young patients, perforation is often associated with acute acalculous cholecystitis due to acute infections like pneumonia, viral influenza and enteric fever.^{6,7,11} Perforation in such cases is likely to be result of intense inflammation coupled with acute infection and existence of an immuno-compromised state leading to uncontrolled infection and thrombosis of the blood vessels.^{6,7,11} Our patient probably developed gallbladder perforation due to ischaemia of gallbladder wall due to acute intense inflammation. Torsion of gallbladder is also reported as a rare cause of gallbladder perforation. Torsion is more common with abnormally long mesentery leading to rotational instability. It thought to occur more frequently in the elderly due to the loss of visceral fat and elasticity with older age, thus permitting the gallbladder to hang freely.¹²

Ultrasound and CT lack specificity to detect gallbladder perforation.^{2,13} Cholecystectomy is treatment of choice in such cases and provides good result.^{1,2,5} Here, patient showed rapid recovery following cholecystectomy. In our case, laparoscopy was not performed due to unavailability of it in our emergency set-up. Fluoroquinolones or ceftriaxone (1–2 g/day) would be optimal choices in the treatment of such cases.¹⁴ In uncomplicated enteric fever, antibiotics are given for 5–7 days. In complicated cases, antibiotics are given for 7–14 days depending on condition of patient.^{2,14} In our case, antibiotics were given for 7 days.

Our case is unusual because patient was a child, with no prior history suggestive of gallbladder disease, had no known medical co-morbidity and showed absence of gall stones on ultrasound and surgery.

4. Conclusion

Gallbladder perforation secondary to enteric fever requires a high degree of clinical suspicion, especially in this age group. In typhoid endemic region, it should be considered as a differential diagnosis in patient presenting with a history of prolonged fever and signs of peritonitis. Early diagnosis and immediate surgical intervention are very important in reducing the morbidity and mortality associated with this condition. Cholecystectomy is the choice with a good outcome.

Conflict of interest statement

The authors have no conflicts of interest.

Funding

None.

Ethical approval

Written informed consent was obtained from the patient's guardian for publication of this case report and accompanying images. A copy of the written consent is available for review by the Editor-in-Chief of this journal on request.

Contribution

Mahendra Singh: Assisting surgeon and preparation of manuscript.

Lovekesh Kumar: Chief operating surgeon.

Rashpal Singh: Assisting surgeon.

Aaron K. Jain & Snehal K. Karande: Helped in preparation of manuscript.

Arjun Saradna & U. Prashanth: Helped in management of patient.

References

1. Roslyn JB, Usuttill RW. Perforation of gallbladder: a frequently mismanaged condition. *Am J Surg* 1979;**137**:307–12.
2. Menakuru SR, Kaman L, Behera A. Current management of gall bladder perforations. *ANZ J Surg* 2004;**74**:843–6.
3. Buckle GC, Fischer Walker CL, Black RE. Typhoid fever and paratyphoid fever: systematic review to estimate global morbidity and mortality for 2010. *J Global Health* 2012;**2**(June (1)):10401.
4. Wain J, Bay PVB, Vinh H. Quantitation of bacteria in bone marrow from patients with typhoid fever: relationship between counts and clinical features. *J Clin Microbiol* 2001;**39**(4):1571–6.
5. Ugwa BT, Yiltok SJ, Kidmas AT, Opaluwa AS. Typhoid intestinal perforation in north central Nigeria. *West Afr J Med* 2005;**24**:1–6.
6. Jaramillo Samaniego JG. Acalculous acute cholecystitis during the course of typhoid fever in children. *Rev Gastroenterol Peru* 2001;**21**(January–March (1)):36–41.
7. Babb RR. Acute acalculous cholecystitis: a review. *J Clin Gastroenterol* 1992;**15**:238–41.
8. Wig JD, Chowdhary A, Talwar BL. Gallbladder perforations. *Aust N Z J Surg* 1984;**54**:531.
9. Gali BM, Ali N, Agbese GO, Duna VD, Dawha SD, Ismai GI, et al. Gallbladder perforation complicating typhoid fever: report of two cases. *Niger J Med* 2011;**20**(January–March (1)):181–3.
10. Roslyn JJ, Thompson JE, Darvin H. Risk factors for gallbladder perforation. *Am J Gastroenterol* 1987;**82**:636–40.
11. Essenhigh DM. Perforation of the gall-bladder. *Br J Surg* 1968;**55**:175–8.
12. Shaikh AA, Charles A, Domingo S, Schaub G. Gallbladder volvulus: report of two cases and review of the literature. *Am Surg* 2005;**71**:87.
13. Martinaz A, Cancers J, Perez C. Postoperative acute cholecystitis: sonographic diagnosis. *Eur J Radiol* 1985;**5**:35.
14. Sanchez-Vargas FM, Abu-El-Hajja MA, Gomez-Duarte OG. Salmonella infections: an update on epidemiology, management, and prevention. *Travel Med Infect Dis* 2011;**9**(November (6)):263–77.

Open Access

This article is published Open Access at sciedirect.com. It is distributed under the [IJSCR Supplemental terms and conditions](#), which permits unrestricted non commercial use, distribution, and reproduction in any medium, provided the original authors and source are credited.