

# The effect of transcatheter bronchial artery embolization in five patients with bronchial artery aneurysm

Le-Jun Fu<sup>1</sup>, Yu Sun<sup>1</sup>, Yong Fan<sup>2</sup>, Song Jin<sup>1</sup>

<sup>1</sup>Department of Radiology, Huanhu Hospital of Nankai University, Tianjin, China

<sup>2</sup>Department of Radiology, General Hospital of Tianjin Medical University, Tianjin, China

Adv Interv Cardiol 2020; 16, 3 (61): 330–335  
DOI: <https://doi.org/10.5114/aic.2020.99269>

## Abstract

**Introduction:** Due to its rarity and the lack of animal models for this disease, the etiology of bronchial artery aneurysm (BAA) is poorly understood.

**Aim:** To investigate the effect of transcatheter artery embolization (TAE) with coils, spherical polyvinyl alcohol (PVA), and gel foam in patients with BAA.

**Material and methods:** From June 2015 to November 2018, 5 patients diagnosed with BAA with massive hemoptysis after undergoing bronchial arteriography and receiving TAE therapy in the Department of Interventional Radiology were enrolled in this study. Post-embolization angiography was used to demonstrate total occlusion of the BAAs and bronchiectatic engorged vessels. The patients' follow-up was conducted 1–16 months after TAE.

**Results:** All 5 patients were cured by the TAE treatment, during which PVA, coils, and gel foam were applied. The patients also received successful TAE via a microcatheter. Hemoptysis disappeared in all patients. No special or severe complications occurred, and no patient experienced a recurrence during the follow-up.

**Conclusions:** Overall, TAE is the best choice for patients with hemoptysis and BAA due to its effectivity and reliability. Thorough and complete embolization of the bleeding arteries is the key to successful treatment. Though PVA and coils are the most common materials for embolization, gel foam strips can also be applied.

**Key words:** hemoptysis, bronchial artery, transcatheter artery embolization, therapeutic, spherical polyvinyl alcohol, gel foam.

## Summary

Transcatheter artery embolization is a treatment with minimal invasiveness and high effectiveness for patients with bronchial artery aneurysm. Polyvinyl alcohol, gel foam, and coils are good choices for embolization, which is a new method combining a variety of materials and successfully replacing the use of the traditional method in these cases.

## Introduction

Bronchial artery aneurysm (BAA) is a rare condition found in less than 1% of all selective bronchial arteriography patients [1]. Since the first case of BAA was described, approximately 60 cases have been reported. Due to its rarity and the lack of animal models for this disease, its etiology is poorly understood. It has been speculated that increased bronchial arterial flow and weakening of the vessel wall may lead to BAA. It is most commonly associated with bronchiectasis and other less commonly seen factors, including hypertension, chronic obstructive pulmonary disease, vasculitis, chronic bronchopulmona-

ry infection, tuberculosis, and trauma. However, many patients with BAA do not have any history of the above-mentioned conditions, which causes difficulty in identifying the disease. Nevertheless, in patients diagnosed with BAA, its clinical manifestation depends on the location of the aneurysm and whether it has ruptured. When the aneurysm has ruptured, the most common symptom is chest pain, followed by hemoptysis, back pain, epigastric pain, and shock. However, if the aneurysm remains intact, BAA is usually identified incidentally upon thoracic scanning because it does not have any specific manifestations.

## Corresponding author:

Yong Fan, Department of Radiology, General Hospital of Tianjin Medical University, 300052 Tianjin, China, e-mail: [fanyong\\_fy1239@163.com](mailto:fanyong_fy1239@163.com)

**Received:** 15.04.2020, **accepted:** 9.05.2020.

Bronchial artery aneurysm is always found in patients with hemoptysis. The disease is life-threatening when it ruptures, as the massive bleeding presents hemoptysis. Therefore, patients with BAA should be treated early [2]. In comparison to the surgical treatment approach, transcatheter artery embolization (TAE) is a method that is effective, invasive, and the first choice for BAA. Many embolization materials are used in this approach, including gelatin sponges, steel coils, polyvinyl alcohol (PVA), and n-butyl-cyanoacrylate (NBCA). Each patient has a different disease situation, so the most suitable embolization material must be chosen carefully.

## Aim

Herein, we report 5 cases of BAA with hemoptysis diagnosed via digital subtraction angiography (DSA) and successfully treated by TAE combined with the utilization of PVA, gel foam, and coils.

## Material and methods

### Patients

From June 2012 to November 2014, 5 patients with hemoptysis and BAA that were diagnosed in our hospital were included in this study. The patients' general information and symptoms are listed in Table I. They comprised 2 men and 3 women ranging in age from 20 to 69 years (mean: 49). One patient had two BAAs, and 4 had bronchiectasis. Moreover, 1 patient had been diagnosed with pulmonary heart disease for 3 years, and another was cryptogenic.

### The embolization procedure

All patients signed informed consent for the interventional therapy before the interventional operation, and the study protocol was approved by our institutional Ethics Committee board. Each patient was laid flat on the operating table during the therapeutic intervention. Their electrocardiogram, blood pressure, oxygen saturation,

and heart rate were closely monitored, and an oxygen mask was used to keep their respiratory passages open.

After completing the skin disinfection and local anesthesia, the right femoral artery was punctured with a needle using a modified Seldinger technique, followed by the placement of a 4 or 5 Fr arterial sheath. Then, a 5F × 100 cm Cobra 2 or Cobra 3 catheter (Bloomington, Cook or Miami, Cordis Johnson & Johnson) was placed at the bronchial artery trunk and passed over a 0.035-in hydrophilic-coated guide wire guided by fluoroscopy. Arteriography was performed to clarify the lesions' blood supply and determine any involvement of the spinal artery branch. If such involvement was detected, we observed the spinal artery's opening position and the vascular distribution. A microcatheter was inserted into the distal bronchial artery via super-selective catheterization beyond the spinal artery opening. After repeating the angiography to confirm there were no spinal artery branches, further arterial embolotherapy was performed. A contrast agent was injected and presented the tortuous bronchial artery, its branches, the saccular cast, and extravasation of the contrast medium. The target artery was catheterized with a 3F microcatheter and coaxially introduced through a 5F cobra catheter.

Despite difficulty in guiding the microcatheter into the end of the outflow artery, we performed the procedure with 300–500 μm of spherical PVA to occlude the distal tortuous bronchial artery. In the case of spinal ischemia, the tip of the microcatheter had to be crossed over the spinal artery branch with adequate distance in the bronchial artery. Then, gel foam was injected through the microcatheter to occlude the main trunk, and coils were inserted to embolize the proximal end of the bronchial artery, after which the blood flow disappeared. A post-procedural angiogram showed complete occlusion without any evidence of endoleaks.

A combined treatment of PVA, gel foam, and coils to embolize the outflow arteries was indicated in the treatment of BAAs with suitable anatomic features. After the

**Table I.** Clinical and radiologic characteristics of bronchial artery aneurysm patients

Patient no.	Age/gender	Cause	Symptom	Diagnostic tool	Number of aneurysms	Ruptured	Technique succeeded	Treatment	Hemoptysis volume	Outcome
1	58/F	Bronchiectasis	Hemoptysis	Fluoroscopy	2	No	Yes	BAE/Coils 35 + gel foam	500 ml/day	Success
2	21/M	Infection	Hemoptysis	Fluoroscopy	1	Yes	Yes	BAE/PVA + gel foam	100 ml/day	Success
3	69/M	Bronchiectasis	Hemoptysis	Fluoroscopy	1	No	Yes	BAE/PVA + 11 coils	200 ml/day	Success
4	54/F	Bronchiectasis cor pulmonale	Hemoptysis	Fluoroscopy	1	No	Yes	BAE/PVA + 12 coils + gel foam	200 ml/day	Success
5	32/F		Hemoptysis	Fluoroscopy	1	No	Yes	BAE/PVA + 8 coils + gel foam	200 ml/day	Success

patients received the TAE treatment, an anti-inflammatory or antifungal treatment was performed in those with pulmonary infections in accordance with the results of their bacterial and blood cultures. Case no. 5 was treated with coils because the aneurysm was close to the origin of the bronchial artery and the microspheres presented an easy outflow to the aneurysm, further causing mis-embolization.

## Results

### General description of the bronchial artery aneurysms

All patients' bronchial arteries were slim and tortuous but long enough that the microcatheter could be placed deeply. Then, the appropriate PVA and gel foam were injected to occlude the subdivision of the bronchial arteries so that hemoptysis would not reoccur. After angiography, no BAA cast appeared, and total occlusion of the bronchial artery was demonstrated in all 5 cases. Follow-up by telephone was performed at an average of 6 months (range: 1–16 months), and no hemoptysis reoccurred.

### Description of two cases

Case 1: A 58-year-old woman with a diagnosis of bronchiectasis presented with recent hemoptysis and was admitted to our hospital, in which TAE was performed (Figure 1). The left angiogram of the left bronchial artery showed that it had a co-trunk with the esophageal arteries, a giant sacular cast at the origin of the left bronchial artery (somewhere between the fourth and fifth ribs), and several tortuous bronchial arteries. Subsequently, a microcatheter was advanced to a tortuous artery under fluoroscopic guidance, and we injected the gel foam to distally embolize the bronchiectatic arteries. Then, 29 steel coils (2/3 mm\*20 mm, 2 mm/4 mm\*40 mm, and 3 mm\*30 mm) were used to occlude the BAA and arteries. The right bronchial arteriography also showed several engorged and tortuous arteries; thus, we used the same method, injecting three steel coils and the gel foam to occlude the afferent artery to stop the bleeding. The post-artery angiography showed no definite enhancement of the aneurysm, and the patient's hemoptysis disappeared.

Case 2: A 21-year-old student was admitted to the emergency room with sudden hemoptysis of approximately 100 ml total volume after several days of experiencing a pulmonary infection. After treatment with drugs over the following 2 days, the patient continued to have intermittent hemoptysis; hence, we chose to perform the TAE treatment (Figure 2). The bronchial arteries were delicate. A 5F Cobra 2 catheter was placed at the origin of the bilateral bronchial artery. Then, catheters were placed in the left bronchial artery. The angiography showed a sacular cast at the end and presented an outflow of contrast agents. We inserted a microcatheter in the afferent

artery of the BAA and injected PVA microparticles to occlude the arteries. The post-angiography showed occlusion of the target arteries and no contrast filling of the aneurysm. Several days later, the patient was discharged.

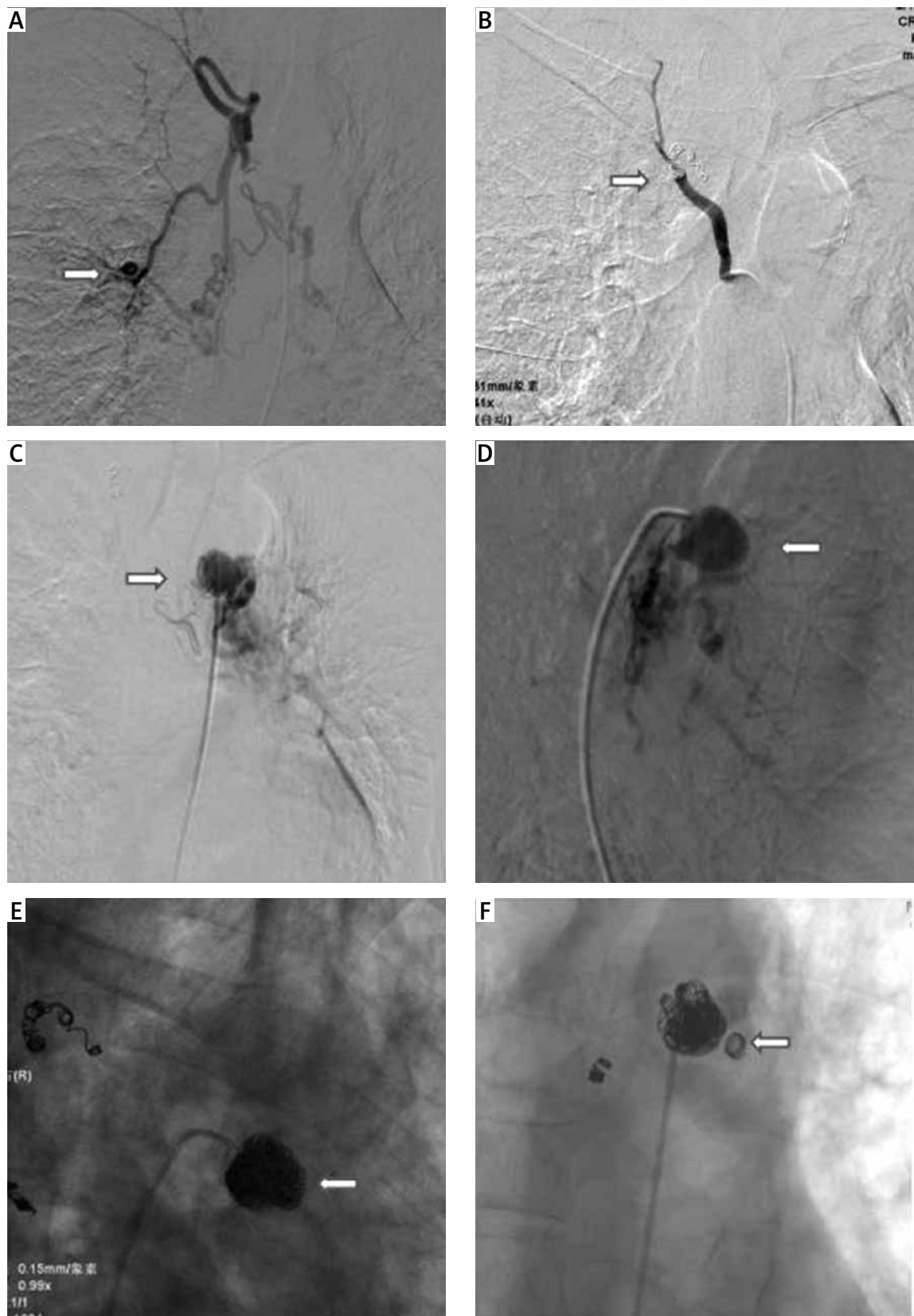
## Discussion

Bronchial artery aneurysm is a rare true aneurysm involving the entire wall of the bronchial artery. Half of all cases are found in the lung parenchyma, while the other half are found in the mediastinum. The exact etiology of BAA is unclear, although it is generally considered as the result of increased blood flow to the lungs or weakening of the vessel wall [3–8]. It has also been suggested that BAA is related to diseases such as bronchiectasis, tuberculosis, atherosclerosis, Rendu-Osler-Weber syndrome, or trauma [3, 9–11].

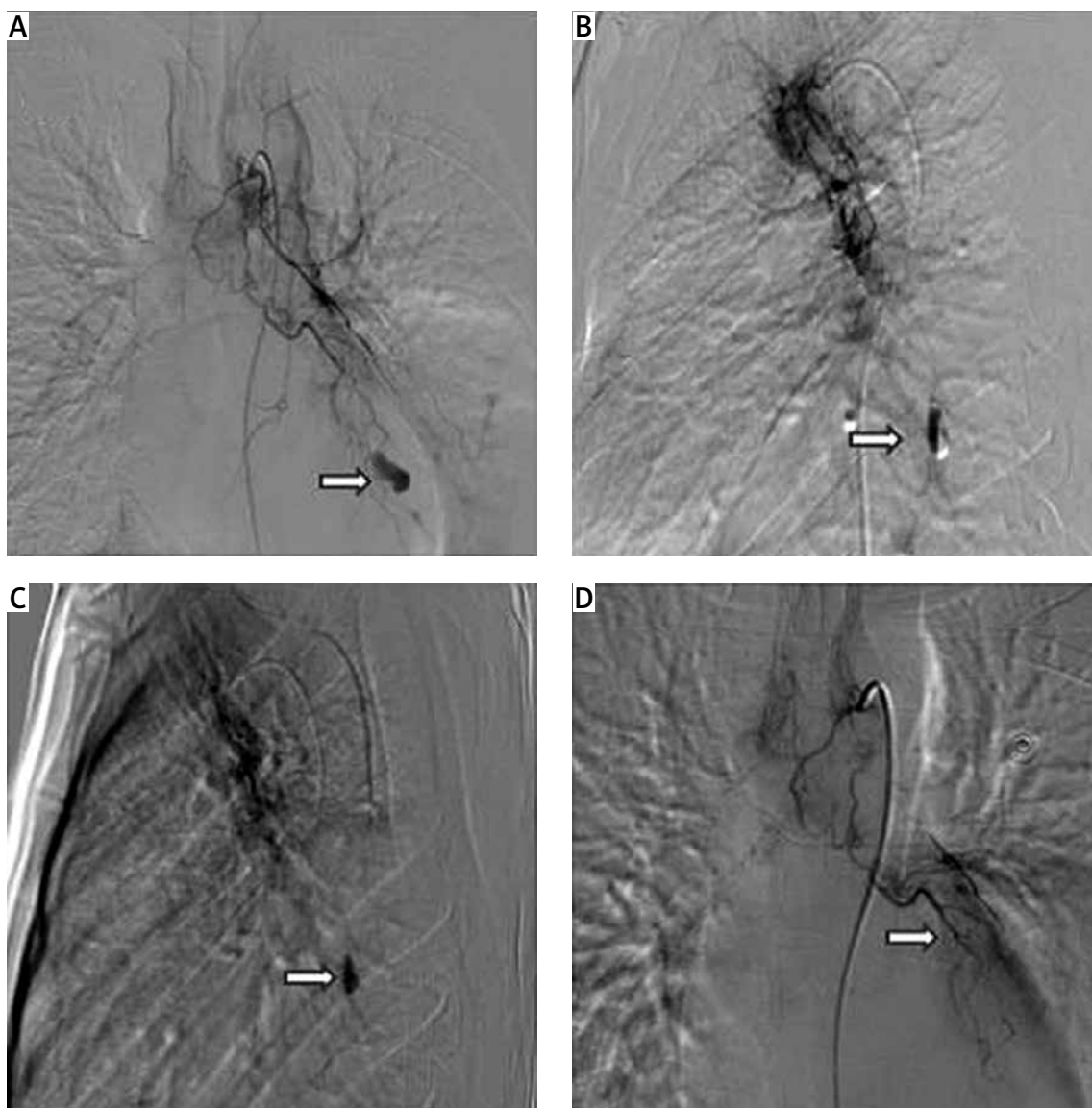
Although BAA is rare, it can be life-threatening due to massive hemoptysis. Once the diagnosis is confirmed, the aneurysm should be treated, regardless of its size or symptoms [5–8, 12, 13]. The aneurysm's diameter has not been identified as an incremental risk factor thus far. As the risk of fatal catastrophic hemorrhage upon rupture is high, all patients should be successfully treated early with radiological TAE, irrespective of their symptoms [5]. A BAA's clinical manifestation depends on its size and location as well as any concomitant disease. For example, a mediastinum BAA can mimic aortic dissection or cause hemomediastinum and even hematemesis if it ruptures into the adjacent structures as well as diseases such as dysphagia and superior vena cava syndrome [6].

Urgent embolization after the initial hemodynamic stabilization and insertion of a chest tube is the treatment of choice in an emergency setting [13–15]. A surgical approach is especially effective for a ruptured BAA. Although surgery may be required for the assessment or treatment of mediastinal compression or life-threatening bleeding, surgical procedures such as resection or ligation of the aneurysm cause high morbidity and mortality. In cases with massive, uncontrollable bleeding, cardiopulmonary bypass is helpful [1, 6, 16–18]. Moreover, if transcatheter coil embolization of the outflow vessels is technically difficult, it is possible to embolize these arteries using a fibrin sealant, as described by Sanchez *et al.*

In this study, we reviewed the 5 cases in terms of their clinical presentation and therapeutic management. In bronchiectasis, the inferior phrenic artery is one of the most common collateral arteries causing a fistula with the pulmonary artery. In the current cases, dilated tortuous arteries derived from the internal thoracic artery and inferior phrenic artery were identified around small nodular and tubular structures associated with bronchiectasis. As such, selective bronchial arteriography should be performed in patients with BAA due to the apparent occurrence of multiple feeding arteries in such cases. At least 12 ruptured BAAs have been reported in previous studies [1].



**Figure 1.** **A** – A BAA present at the distal end of the right bronchial artery (white arrow). **B** – After TAE with gel foam and four coils, DSA showed total occlusion of the engorged bronchial arteries and BAA (white arrow). **C, D** – Positive and oblique DSA demonstrated a BAA very close to the aorta (white arrow). **E, F** – After TAE with 31 coils, positive and oblique DSA showed total occlusion of the engorged bronchial arteries and BAA (white arrow)



**Figure 2.** **A** – The left DSA demonstrated a BAA at the end of the bronchial arteries and spillover of the contrast agents (white arrow). **B, C** – In the oblique position, the afferent arteries were catheterized with a microcatheter, and PVA microparticles were injected to occlude the arteries. **D** – After the embolization of the afferent arteries with PVA, the DSA showed total occlusion of the engaged target arteries and BAA (white arrow)

Since then, TAE has been increasingly used in clinical applications, as it is a minimally invasive and highly effective treatment approach for patients with BAA. Thus, endovascular treatment is the first choice for BAA.

In recent years, a variety of embolic materials have been described, including gelatin sponges, PVA, steel coils, and NBCA [14, 19]. The most suitable embolization materials for each case must be carefully chosen considering each patient's BAA position and its anatomical features [12, 13]. In the present study, we primarily used gel foam, coils, and PVA to occlude the feeding vessels and efferent branches. Coils were used to occlude the trunk of the bronchial artery, and the BAAs were successfully occluded in 4 patients. The PVA provided a permanent

therapeutic effect, indicating that it is an effective method to occlude arteries without recanalization and collateral circulation. However, patients with hemoptysis have long been cured within several days via vasoconstrictive medicines such as hypophysin. Under the constriction of vessels, fewer embolization materials can be used to achieve the embolization. Several days later, the re-expansion of bronchial vessels may lead to re-canalization owing to the low expansion rate of PVA. Gel foam is a less expensive material but has a high rate of re-expansion. Thus, a combined treatment using both PVA and gel foam might achieve a better outcome. Collateral vessels, incomplete embolization, and arterial re-canalization may cause a recurrent aneurysm; hence, long-

term follow-ups are recommended after endovascular procedures to identify endoleaks or aneurysm growth in patients.

## Conclusions

Overall, TAE is a minimally invasive and highly effective treatment for patients with BAA. Coils, PVA, and gel foam are good choices for embolization, a new method of combining a variety of materials that can successfully replace the traditional method in these cases.

## Conflict of interest

The authors declare no conflict of interest.

## References

- Mizuguchi S, Inoue K, Kida A, et al. Ruptured bronchial artery aneurysm associated with bronchiectasis: a case report. *Ann Thorac Cardiovasc Surg* 2009; 15: 115-8.
- Tanaka K, Ihaya A, Horiuchi T, et al. Giant mediastinal bronchial artery aneurysm mimicking benign esophageal tumor: a case report and review of 26 cases from literature. *J Vasc Surg* 2003; 38: 1125-9.
- Kalngos A, Khatchatourian G, Panos A, Faidutti B. Giant mediastinal bronchial artery aneurysm mimicking benign esophageal tumor: a case report and review of 26 cases from literature. *J Thorac Cardiovasc Surg* 1997; 114: 853-6.
- Osada H, Kawada T, Ashida H, et al. Bronchial artery aneurysm. *Ann Thorac Surg* 1986; 41: 440-2.
- Yanagihara K, Ueno Y, Kobayashi T, et al. Bronchial artery aneurysm. *Ann Thorac Surg* 1999; 67: 854-5.
- Tringali S, Tiffet O, Berger JL, Cuilleret J. Bronchial artery aneurysm disguised as a leiomyoma of the esophagus. *Ann Thorac Surg* 2002; 73: 632-3.
- Shaer AH, Bashist B. Computed tomography of bronchial artery aneurysm with erosion into the esophagus. *J Comput Assist Tomogr* 1989; 13: 1069-71.
- Sakuma K, Takase K, Saito H, et al. Bronchial artery aneurysm treated with percutaneous transluminal coil embolization. *Jpn J Thorac Cardiovasc Surg* 2001; 49: 330-2.
- Yajima N, Tsutsui H, Yoshioka T, et al. Gigantic bronchial artery aneurysm treated with transcatheter arterial embolization: a case report. *Angiology* 2008; 59: 757-60.
- Pugnale M, Portier F, Lamarre A, et al. Hemomediastinum caused by rupture of a bronchial artery aneurysm: successful treatment by embolization with N-butyl-2-cyanoacrylate. *J Vasc Interv Radiol* 2001; 12: 1351-2.
- Ueda R, Kotani Y, Tsujimoto T. A ruptured bronchial artery aneurysm with massive haemoptysis. *BMJ Case Rep* 2017; 2017: pii: bcr-2017-220392.
- Arici V, Bozzani A, Odero A. Successful endovascular treatment of a bronchial artery aneurysm refractory to transcatheter embolization. *Ann Vasc Surg* 2013; 27: 802.e13-5.
- Guzzardi G, Cerini P, Fossaceca R, et al. Endovascular treatment of bronchial artery aneurysm with aortic stent-graft placement and coil embolization. *Ann Vasc Surg* 2012; 26: 1013.e5-8.
- Lü PH, Wang LF, Su YS, et al. Endovascular therapy of bronchial artery aneurysm: five cases with six aneurysms. *Cardiovasc Intervent Radiol* 2011; 34: 508-12.
- Aburano H, Kawamori Y, Horiti Y, et al. Bronchial artery aneurysm embolization with NBCA. *Cardiovasc Intervent Radiol* 2006; 29: 1141-3.
- Panda A, Bhalla AS, Goyal A. Bronchial artery embolization in hemoptysis: a systematic review. *Diagn Interv Radiol* 2017; 23: 307-17.
- Suen HC, Dumontier CC, Boeren J, et al. Ruptured bronchial artery aneurysm associated with sarcoidosis. *J Thorac Cardiovasc Surg* 2003; 125: 1153-4.
- Tsolaki E, Salviato E, Coen M, et al. Double right bronchial artery aneurysm treated with combined procedures. *Eur J Vasc Endovasc Surg* 2007; 34: 537-9.
- Misselt AJ, Krowka MJ, Misra S. Successful coil embolization of mediastinal bronchial artery aneurysm. *J Vasc Interv Radiol* 2010; 21: 295-6.