

Observational Study

Low-molecular-weight dextran for optical coherence tomography may not be protective against kidney injury in patients with renal insufficiency

Toru Misawa, Tomoyo Sugiyama, Yoshihisa Kanaji, Masahiro Hoshino, Masao Yamaguchi, Masahiro Hada, Tatsuhiro Nagamine, Kai Nogami, Yumi Yasui, Eisuke Usui, Tetsumin Lee, Taishi Yonetsu, Tetsuo Sasano, Tsunekazu Kakuta

ORCID number: Toru Misawa 0000-0003-0764-0644; Tomoyo Sugiyama 0000-0002-3754-6117; Yoshihisa Kanaji 0000-0001-6535-4377; Masahiro Hoshino 0000-0003-3661-1914; Masao Yamaguchi 0000-0003-0728-1362; Masahiro Hada 0000-0003-1499-9188; Tatsuhiro Nagamine 0000-0001-6242-849X; Kai Nogami 0000-0002-0622-959X; Yumi Yasui 0000-0003-3394-1563; Eisuke Usui 0000-0002-5454-3743; Tetsumin Lee 0000-0002-9457-072X; Taishi Yonetsu 0000-0002-1798-5008; Tetsuo Sasano 0000-0003-3582-6104; Tsunekazu Kakuta 0000-0002-4004-5292.

Author contributions: Misawa T and Kakuta T contributed to the study conception and design; Misawa T, Sugiyama T, Kanaji Y, Hoshino M, Yamaguchi M, Hada M, Nagamine T, Nogami K and Yasui Y conducted material preparation and data collection; Misawa T conducted data analysis and wrote the first draft of the manuscript; all authors commented on previous versions of the manuscript, read and approved the final manuscript.

Institutional review board statement: This study was

Toru Misawa, Tomoyo Sugiyama, Yoshihisa Kanaji, Masahiro Hoshino, Masao Yamaguchi, Masahiro Hada, Tatsuhiro Nagamine, Kai Nogami, Yumi Yasui, Eisuke Usui, Tetsumin Lee, Tsunekazu Kakuta, Department of Cardiovascular Medicine, Tsuchiura Kyodo General Hospital, Ibaraki 300-0028, Japan

Taishi Yonetsu, Department of Interventional Cardiology, Tokyo Medical and Dental University, Tokyo 113-8519, Japan

Tetsuo Sasano, Department of Cardiovascular Medicine, Tokyo Medical and Dental University, Tokyo 113-8519, Japan

Corresponding author: Tsunekazu Kakuta, MD, PhD, Doctor, Department of Cardiovascular Medicine, Tsuchiura Kyodo General Hospital, 4-1-1 Otsuno, Tsuchiura, Ibaraki 300-0028, Japan. kaz@joy.email.ne.jp

Abstract

BACKGROUND

Low-molecular-weight dextran (LMWD) is considered a safe alternative to contrast media for blood displacement during optical coherence tomography (OCT) imaging.

AIM

To investigate whether the use of LMWD for OCT is protective against kidney injury in patients with advanced renal insufficiency.

METHODS

In this retrospective cohort study, we identified 421 patients with advanced renal insufficiency (estimated glomerular filtration rate < 45 mL/min/1.73 m²) who underwent coronary angiography or percutaneous coronary intervention; 79 patients who used additional LMWD for OCT imaging (LMWD group) and 342 patients who used contrast medium exclusively (control group). We evaluated the differences between these two groups and performed a propensity score-matched subgroup comparison.

performed in compliance with Institutional Ethics Committee Guidelines of Tsuchiura Kyodo General Hospital, and the study received its approval.

Informed consent statement: All patients provided written informed consent prior to study enrollment.

Conflict-of-interest statement: There are no conflicts of interest to report.

Data sharing statement: No additional data are available.

STROBE statement: The authors have read the STROBE Statement – checklist of items, and the manuscript was prepared and revised according to the STROBE Statement – checklist of items.

Open-Access: This article is an open-access article that was selected by an in-house editor and fully peer-reviewed by external reviewers. It is distributed in accordance with the Creative Commons Attribution NonCommercial (CC BY-NC 4.0) license, which permits others to distribute, remix, adapt, build upon this work non-commercially, and license their derivative works on different terms, provided the original work is properly cited and the use is non-commercial. See: <http://creativecommons.org/licenses/by-nc/4.0/>

Manuscript source: Invited manuscript

Specialty type: Urology and nephrology

Country/Territory of origin: Japan

Peer-review report's scientific quality classification

Grade A (Excellent): 0
Grade B (Very good): 0
Grade C (Good): C
Grade D (Fair): 0
Grade E (Poor): 0

Received: December 29, 2020

Peer-review started: December 30, 2020

First decision: February 15, 2021

RESULTS

The median total volume of contrast medium was 133.0 mL in the control group *vs* 140.0 mL in the LMWD group. Although baseline renal function was not statistically different between these two groups, the LMWD group demonstrated a strong trend toward the progression of renal insufficiency as indicated by the greater change in serum creatinine level during the 1-year follow-up compared with the control group. Patients in the LMWD group experienced worsening renal function more frequently than patients in the control group. Propensity score matching adjusted for total contrast media volume consistently indicated a trend toward worsening renal function in the LMWD group at the 1-year follow-up. Delta serum creatinine at 1-year follow-up was significantly greater in the LMWD group than that in the control group [0.06 (-0.06, 0.29) *vs* -0.04 (-0.23, 0.08) mg/dL, *P* = 0.001], despite using similar contrast volume.

CONCLUSION

OCT using LMWD may not be protective against worsening renal function in patients with advanced renal insufficiency.

Key Words: Coronary artery disease; Kidney injury; Contrast media; Dextran; Optical coherence tomography; Renal insufficiency

©The Author(s) 2021. Published by Baishideng Publishing Group Inc. All rights reserved.

Core Tip: Low-molecular-weight dextran (LMWD) is considered a safe alternative to contrast during optical coherence tomography (OCT) imaging. We evaluated differences between patients who used additional LMWD for OCT (LMWD group) and those who used contrast exclusively (control group) and performed a propensity score-matched subgroup comparison. The LMWD group demonstrated a strong trend toward the progression of renal insufficiency during the 1-year follow-up. Propensity score-matched analysis indicated a trend toward worsening renal function in the LMWD group at the 1-year follow-up. Additional use of LMWD for OCT may not be protective against worsening renal function in patients with advanced renal insufficiency.

Citation: Misawa T, Sugiyama T, Kanaji Y, Hoshino M, Yamaguchi M, Hada M, Nagamine T, Nogami K, Yasui Y, Usui E, Lee T, Yonetsu T, Sasano T, Kakuta T. Low-molecular-weight dextran for optical coherence tomography may not be protective against kidney injury in patients with renal insufficiency. *World J Nephrol* 2021; 10(2): 8-20

URL: <https://www.wjgnet.com/2220-6124/full/v10/i2/8.htm>

DOI: <https://dx.doi.org/10.5527/wjn.v10.i2.8>

INTRODUCTION

The presence of renal insufficiency has been reported to be associated with the increased risk of cardiovascular events^[1]. Contrast-induced acute kidney injury (AKI) is a contributing factor to poor outcomes after angiographic procedures^[2-4]. The incidence of contrast-induced AKI increases sharply as renal function decreases^[5]. Some patients may even experience a prolonged decrease in renal function late after the index procedure^[6]. Moreover, the presence of prolonged renal insufficiency in the long-term was associated with the increased risk of cardiovascular events^[7]. Renal insufficiency and the total contrast volume are widely known as risk factors for contrast-induced AKI^[8,9]. Thus, reducing total contrast volume during coronary angiography and/or percutaneous coronary intervention (PCI) is an important priority to prevent contrast-induced worsening renal function, particularly in patients with advanced renal dysfunction.

Recently, intracoronary optical coherence tomography (OCT) has been widely used to assess coronary plaque characteristics and optimize PCI in patients with coronary artery disease^[8,9]. OCT imaging requires blood displacement from the vessel lumen, and contrast media is the standard flushing agent, although the potential risk of

Revised: February 22, 2021**Accepted:** March 11, 2021**Article in press:** March 11, 2021**Published online:** March 25, 2021**P-Reviewer:** Sureshkumar K**S-Editor:** Fan JR**L-Editor:** A**P-Editor:** Wang LL

contrast-induced AKI exists^[2,3]. Previous studies have demonstrated the feasibility of low-molecular-weight dextran (LMWD) as a safe alternative to contrast media for blood displacement during OCT imaging. Previous studies reported that OCT using LMWD might decrease the required total amount of contrast without losing image quality^[10,11]. On the other hand, LMWD-induced AKI has been repeatedly reported^[12-15]. Therefore, the protective role of LMWD against kidney injury remains uncertain in patients with advanced renal insufficiency, particularly regarding the long-term influence.

In the present study, we sought to investigate whether the additional use of LMWD for OCT imaging is protective against kidney injury in patients with advanced renal insufficiency undergoing coronary angiography and/or PCI by using propensity score-matched subgroup analysis during 1-year follow-up.

MATERIALS AND METHODS

Study population

This study was performed in compliance with our institutional ethics committee guidelines, and the study received its approval. All patients provided written informed consent before invasive coronary angiography or PCI for future data utilization.

In this retrospective cohort study, we identified 700 patients with advanced renal insufficiency [estimated glomerular filtration rate (eGFR) < 45 mL/min/1.73 m²] who underwent diagnostic coronary angiography or PCI between March 2016 and June 2019 at Tsuchiura Kyodo General Hospital. The study period was chosen because, after March 2016, the total volume of injected flushing agents, including contrast medium and LMWD, was accurately documented by the use of an automated power injector. The final decision to perform an OCT examination by LMWD was at the operator's discretion. Patients receiving maintenance dialysis were excluded from the analysis. Patients with insufficient data regarding the use of contrast/LMWD or follow-up renal function were also excluded from the analysis. Thus, the final analysis included 421 patients with advanced renal insufficiency, including 342 patients with contrast medium exclusively (control group) and 79 patients receiving additional LMWD for OCT imaging (LMWD group) (Figure 1). We compared patients' clinical characteristics and the factors associated with renal function between these two groups using propensity score-matched subgroup analysis. All patient data and procedural details were obtained from patients' medical records.

Coronary angiography and PCI

Each patient underwent diagnostic coronary angiography *via* the radial artery with a 5-French system, and PCI with a 6-French or 7-French system. A low-osmolarity contrast medium (iopamidol; Fuji Pharma Co., Ltd., Tokyo, Japan) was injected using an automated power injector (ACIST CVi; ACIST Medical Systems Inc., Eden Prairie, MN, United States) at a rate of approximately 3.0-4.0 mL/s. All patients undergoing PCI were treated by coronary drug-eluting stent implantation. To determine the appropriate stent size and obtain optimal stent expansion, we used online quantitative coronary angiography and intracoronary imaging, including OCT and intravascular ultrasound findings. The type of stent was chosen at the operator's discretion, and the interventionist determined the PCI strategy.

OCT image acquisition

OCT images were acquired using frequency-domain OCT systems: Abbott OCT (ILUMIEN OPTIS; Abbott Vascular, Santa Clara, CA, United States) or Terumo optical frequency-domain imaging system (Lunawave; Terumo Corporation, Tokyo, Japan). The technique of OCT image acquisition has been described elsewhere^[8]. OCT imaging pullbacks were performed automatically by the dedicated devices while injecting the flushing agent, which was either contrast medium or LMWD-40 (Otsuka Pharmaceutical Factory, Inc., Tokushima, Japan), at a flow rate of 3.0-4.5 mL/s *via* the guiding catheter using an automated power injector. Pullback speed was 18 mm/s with the Abbott OCT system and 20 mm/s with the Terumo optical frequency-domain imaging system.

Renal function assessment

Laboratory data were sampled before coronary angiography and/or PCI at the

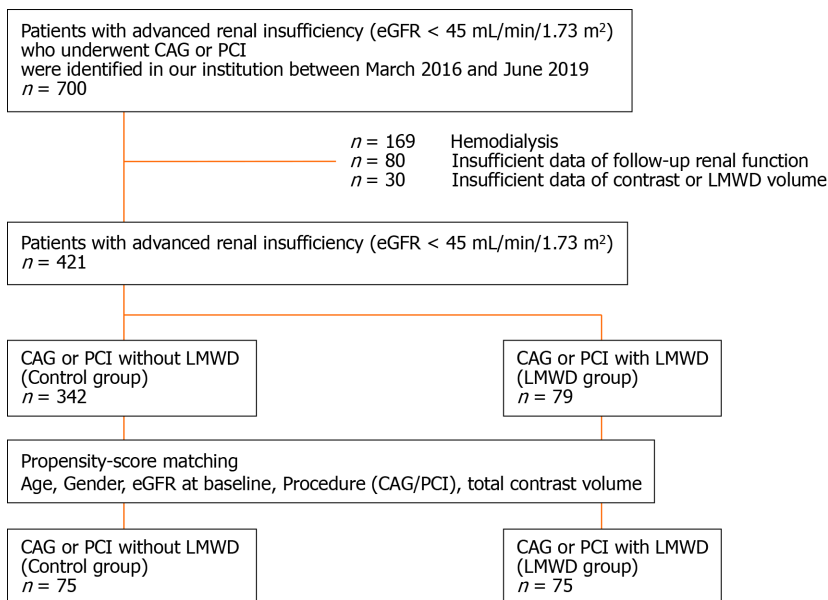


Figure 1 The patient population in this study. CAG: Coronary angiography; eGFR: Estimated glomerular filtration rate; LMWD: Low-molecular-weight dextran; OCT: Optical coherence tomography; PCI: Percutaneous coronary intervention.

protocol-specified timing for evaluating renal function. Morning fasting blood samples on the day of the procedure were obtained in patients undergoing elective procedures. In patients with acute coronary syndrome (ACS) and those undergoing urgent procedures, blood samples were obtained at admission. We calculated eGFR using the equation modified for Japanese patients: $\text{eGFR (mL/min/1.73 m}^2\text{)} = 194 \times (\text{serum creatinine})^{-1.094} \times (\text{age})^{-0.287} \times 0.739$ (for women)^[16]. Advanced renal insufficiency was defined as $\text{eGFR} < 45 \text{ mL/min/1.73 m}^2$ ^[17].

Contrast-induced AKI was defined as a $\geq 0.3 \text{ mg/dL}$ increase in serum creatinine level from baseline within 5 d after the procedure^[18]. Worsening renal function in the long-term was defined as a $\geq 0.3 \text{ mg/dL}$ increase in serum creatinine level from baseline to the 1-year follow-up^[19]. We evaluated the incidence of contrast-induced AKI and worsening renal function, and serial changes in serum creatinine level within 5 d, and at 1 mo and 1-year post-procedure. We defined delta creatinine (ΔCre) as the difference between post- and pre-procedural serum creatinine levels. Risks for contrast-induced renal dysfunction were stratified by the Mehran risk score^[20].

Hydration protocol

Our institutional standard protocol for hydration was applied in all patients undergoing elective procedures and in selected patients with ACS. Intravenous normal saline (1.5 mL/kg/h) was administered for at least 3 h before contrast exposure after blood sampling for baseline renal function, and was continued for at least 12 h after the procedure. After the literature review, this protocol was approved by the institutional ethics committee on the condition of close clinical monitoring for signs of intolerance in patients with heart failure^[21].

Statistical analysis

The statistical analysis was performed using R version 3.6.2 (The R Project for Statistical Computing, Vienna, Austria). Categorical data are expressed as absolute frequencies and percentages and were compared using the χ^2 test or Fisher's exact test, as appropriate. Continuous variables are expressed as mean \pm SD for normally distributed variables and median (25th-75th percentile) for non-normally distributed variables. Analyses were performed with the Mann-Whitney *U* test for non-normally distributed variables. Changes in serum creatinine (baseline, 5 d, 1 mo, and 1-year post-procedure) were evaluated using one-way repeated measures analysis of variance.

To reduce the effect of bias regarding exposure to LMWD in this observational study, we adjusted for significant differences in patients' baseline characteristics between the control and LMWD groups using propensity score-matched subgroup analysis. We applied propensity score-matched subgroup analysis, adjusted for age, sex, indication (coronary angiography or PCI), baseline eGFR level, and total contrast

volume. The propensity score-matched subgroup analysis adjusted for these confounders was performed with a 1:1 algorithm using nearest-neighbor matching with a caliper width of ± 0.10 and no replacement. The effect of the additional use of LMWD on renal function was assessed between these propensity score-matched subgroups. The relationship between worsening renal function (dependent variable), flushing agent, and other potential confounders was evaluated using multivariate logistic regression analysis (stepwise forward method) to assess whether LMWD use remained associated with worsening renal function. The associated variables in the univariate analyses ($P < 0.10$) were entered into the propensity score-matched models. We used the Hosmer–Lemeshow test to establish the goodness-of-fit of the model, and $P > 0.05$ indicated that the model provided a valid representation. Receiver operating characteristic (ROC) curves were analyzed to determine the optimal cut-off values for the confounding variables to predict worsening renal function. A two-sided $P < 0.05$ was considered statistically significant.

RESULTS

Patients' baseline characteristics

The final analysis included 342 patients in the control group and 79 patients in the LMWD group (Figure 1). Patients' characteristics in these two groups are shown in Table 1. The baseline eGFR level and the distribution of GFR categories were not different between the two groups. A median volume of 133.0 mL of contrast medium was used in the control group. In the LMWD group, a median LMWD volume of 67.6 mL for OCT imaging plus 140.0 mL of contrast medium was used. No anaphylactic reactions occurred. Hemodialysis was required in one patient in the control group during the 1-year follow-up.

Renal function post-procedure in the entire study cohort

The LMWD group demonstrated a strong trend toward the progression of renal insufficiency as indicated by the greater change in serum creatinine levels during the 1-year follow-up compared with the control group (Table 1, Figure 2A). Contrast-induced AKI occurred in 9 patients (11.4%) in the LMWD group and 42 patients (12.3%) in the control group ($P = 1.000$). However, patients in the LMWD group experienced worsening renal function more frequently than patients in the control group (Table 1).

Propensity score-matched comparisons

A propensity score-matched cohort adjusted for age, sex, indication (coronary angiography or PCI), baseline eGFR level, and total contrast volume yielded 150 (75 patients each in the control and LMWD groups) well-matched patients regarding potential confounding baseline variables for the clinical and procedural characteristics. A comparison of renal function after the procedure between the control and LMWD groups in the propensity score-matched cohort is shown in Table 2. The baseline eGFR level and the distribution of GFR categories were not different between the two groups. Moreover, no patients had GFR category 5 in the matched cohort. The incidence of contrast-induced AKI was not significantly different between the two groups. In contrast, the LMWD group demonstrated a strong trend toward the progression of renal insufficiency as indicated by the greater change in serum creatinine level during the 1-year follow-up compared with the control group (Table 2, Figure 2B). Although the prevalence of worsening renal function was not statistically different (25.3% vs 12.0%, $P = 0.059$), ΔCre at 1-year follow-up was significantly greater in the LMWD group than that in the Control group [0.06 (-0.06, 0.29) vs -0.04 (-0.23, 0.08) mg/dL, $P = 0.001$], despite using similar contrast volume. ROC curve analyses demonstrated that the optimal cut-off values for LMWD volume and baseline eGFR level to predict worsening renal function were 52.0 mL for LMWD volume [area under the curve (AUC): 0.614; 95% confidence interval (CI), 0.504-0.724] and 38.4 mL/min/1.73 m² for baseline eGFR level (AUC: 0.654; 95%CI: 0.555-0.753). Multivariable logistic regression analysis revealed that the factors independently associated with worsening renal function were greater LMWD volume (≥ 52.0 mL) [odds ratio (OR): 2.83, $P = 0.019$] and lower baseline eGFR level (< 38.4 mL/min/1.73 m²) (OR: 4.27, $P = 0.004$) (Table 3). The Hosmer–Lemeshow test provided a P value of 0.993 in the matched cohort, which indicated a proper goodness-of-fit for this model. Moreover, greater LMWD volume particularly identified patients with a high risk for worsening renal function in worse baseline renal function (Figure 3).

Table 1 Patients' characteristics and renal function (entire study cohort)

	Total (n = 421)	Control (n = 342)	LMWD (n = 79)	P value
Sex				
Male	281 (66.7)	219 (64.0)	62 (78.5)	0.017
Female	140 (33.3)	123 (36.0)	17 (21.5)	
Age, yr	75.0 [69.0, 80.0]	76.0 [69.0, 80.0]	74.0 [68.0, 79.0]	0.178
Body mass index, kg/m ²	24.0 [21.1, 26.2]	23.9 [21.1, 26.0]	24.4 [21.3, 26.6]	0.273
Procedure				
Coronary angiography	279 (66.3)	238 (69.6)	41 (51.9)	0.004
PCI	142 (33.7)	104 (30.4)	38 (48.1)	
Diagnosis				
Stable CAD	350 (83.1)	288 (84.2)	62 (78.5)	0.243
Acute coronary syndrome	71 (16.9)	54 (15.8)	17 (21.5)	
Prior myocardial infarction	155 (36.8)	106 (31.0)	49 (62.0)	< 0.001
Prior PCI	209 (49.6)	148 (43.3)	61 (77.2)	< 0.001
Prior CABG	22 (5.2)	20 (5.8)	2 (2.5)	0.397
Hypertension	266 (63.2)	210 (61.4)	56 (70.9)	0.122
Dyslipidemia	178 (42.3)	140 (40.9)	38 (48.1)	0.257
Diabetes mellitus	218 (51.8)	172 (50.3)	46 (58.2)	0.214
Stroke	21 (5.0)	20 (5.8)	1 (1.3)	0.147
Current smoking	56 (13.3)	35 (10.2)	21 (26.6)	< 0.001
Serum creatinine, mg/dL	1.33 [1.22, 1.56]	1.33 [1.20, 1.52]	1.36 [1.27, 1.62]	0.057
eGFR, mL/min/1.73 m ²	38.4 [32.9, 42.3]	38.5 [32.6, 42.4]	36.9 [33.1, 41.8]	0.368
GFR category				
3b (30 ≤ eGFR < 45)	352 (83.6)	284 (83.0)	68 (86.1)	0.783
4 (15 ≤ eGFR < 30)	64 (15.2)	54 (15.8)	10 (12.6)	
5 (eGFR < 15)	5 (1.2)	4 (1.2)	1 (1.3)	
Hemoglobin A1c, %	6.3 [5.8, 6.9]	6.3 [5.7, 7.0]	6.4 [6.0, 6.9]	0.109
Low-density lipoprotein cholesterol, mg/dL	86 [71, 107]	87 [72, 108]	82 [70, 103]	0.301
Hemoglobin, g/dL	11.8 [10.5, 13.4]	11.8 [10.5, 13.4]	12.1 [10.9, 13.5]	0.375
C-reactive protein, mg/dL	0.14 [0.05, 0.42]	0.13 [0.05, 0.40]	0.15 [0.06, 0.53]	0.180
NT-proBNP, pg/mL	864.5 [279.8, 3471.3]	991.0 [288.3, 3700.0]	633.0 [177.3, 1775.5]	0.099
LVEF, %	57 [44, 66]	58 [44, 66]	52 [43, 63]	0.140
Mehran risk score	8 [6, 11]	8 [6, 11]	8 [7, 11]	0.710
Catheterization procedure				
Total agent volume, mL	150.0 [103.0, 226.0]	133.0 [92.0, 192.3]	207.0 [167.5, 271.8]	< 0.001
Total contrast volume, mL	135.0 [95.0, 193.0]	133.0 [92.0, 192.3]	140.0 [102.0, 195.0]	0.618
LMWD volume, mL	0.0 [0.0, 0.0]	0.0 [0.0, 0.0]	67.6 [43.3, 86.0]	< 0.001
OCT	79 (40.6)	92 (26.9)	79 (100.0)	< 0.001
Renal function post-procedure				
ΔCre within 5 d, mg/dL	-0.01 [-0.11, 0.13]	0.00 [-0.10, 0.14]	-0.03 [-0.14, 0.12]	0.414
ΔCre at 1 mo, mg/dL	-0.01 [-0.15, 0.11]	-0.01 [-0.16, 0.11]	-0.01 [-0.13, 0.09]	0.686

ΔCre at 1 yr, mg/dL	0.01 [-0.13, 0.18]	0.00 [-0.14, 0.16]	0.07 [-0.04, 0.34]	0.004
Acute kidney injury	51 (12.1)	42 (12.3)	9 (11.4)	1.000
Worsening renal function (ΔCre ≥ 0.3 mg/dL/1 yr)	80 (19.0)	58 (17.0)	22 (27.8)	0.039

Data are presented as *n* (%) or median (25th-75th percentile). CABG: Coronary artery bypass graft surgery; CAD: Coronary artery disease; ΔCre: Delta creatinine; eGFR: Estimated glomerular filtration rate; LMWD: Low-molecular-weight dextran; LVEF: Left ventricular ejection fraction; NT-proBNP: N-terminal pro B-type natriuretic peptide; OCT: Optical coherence tomography; PCI: Percutaneous coronary intervention.

DISCUSSION

The main findings of the present study are: (1) The additional use of LMWD for OCT was identified in 18.8% (79/421) of the study patients with advanced renal insufficiency; (2) The LMWD group demonstrated a strong trend toward the progression of renal insufficiency as indicated by the greater change in serum creatinine level during the 1-year follow-up compared with the control group; (3) After propensity score matching, the LMWD group demonstrated a significant trend in the progression of renal insufficiency at the 1-year follow-up; and (4) Multivariable logistic regression analysis revealed that greater LMWD volume and lower baseline eGFR level were independently associated with worsening renal function in the propensity score-matched cohort. To the best of our knowledge, this is the first study to demonstrate that the additional use of LMWD for OCT imaging may not be protective against worsening renal function in patients with advanced renal insufficiency, particularly with respect to the long-term influence.

Impact of renal insufficiency for worse outcomes

Various studies have reported that renal insufficiency is independently associated with cardiovascular events and mortality^[22-24]. Notably, patients with eGFR < 45 mL/min/1.73 m² were associated with a 1.49-fold increase in the risk of cardiovascular events compared with patients with eGFR > 75 mL/min/1.73 m², which resulted in a substantial reduction in life expectancy for patients with eGFR < 45 mL/min/1.73 m²^[25,26]. Hypertension and diabetes mellitus are important causes of kidney dysfunction, which increase the risk of cardiovascular events. One of the mechanisms of cardiovascular complications in renal insufficiency involves endothelial dysfunction. Bajaj *et al*^[27] reported that coronary microvascular dysfunction was associated with impaired left ventricular mechanics and cardiovascular events in patients with chronic kidney impairment.

Contrast and LMWD for OCT imaging

OCT enables clear visualization of culprit and non-culprit plaque morphologies^[8,9] and PCI optimization^[28,29]. LMWD is considered a safe alternative to contrast media for blood displacement during OCT imaging. Moreover, a recent study demonstrated that the changes in serum creatinine level just after the procedure did not differ between the patients treated with OCT guidance and those with intravascular ultrasound guidance, which included mainly normal and mild renal insufficiency^[30]. However, these previous studies enrolled a relatively small number of patients, and sample sizes were too small to draw definitive recommendations for the safety of additional use of LMWD for OCT in patients with advanced renal insufficiency. In contrast, our study involved a much larger number of patients with advanced renal insufficiency receiving LMWD additionally as a substitute flushing agent. In daily clinical practice, the additional use of LMWD for OCT has been preferentially performed in patients with advanced renal insufficiency to reduce the total contrast volume and prevent contrast-induced AKI. However, the safety of LMWD over contrast medium against kidney injury, particularly over the long-term, has not been fully studied. To our knowledge, our study is the first report examining the possibility of LMWD-related kidney injury when LMWD is used for OCT combined with contrast medium in patients with advanced renal insufficiency during a 1-year follow-up.

LMWD and renal impairment

In the previous studies that reported the association between LMWD and AKI^[12-15], the total LMWD volume was much greater than that used for OCT because LMWD was used mainly to correct hypovolemia as a substitute for plasma concentrate. In contrast, in our study, the LMWD group showed a strong trend toward worsening renal

Table 2 Patients' characteristics and renal function (matched cohort)

	Total (n = 150)	Control (n = 75)	LMWD (n = 75)	P value
Sex				
Male	119 (79.3)	61 (81.3)	58 (77.3)	0.687
Female	31 (20.7)	14 (18.7)	17 (22.7)	
Age, yr	75.0 [67.5, 80.0]	75.0 [69.0, 80.0]	74.0 [67.0, 79.5]	0.643
Body mass index, kg/m ²	23.7 [21.0, 25.9]	23.0 [20.8, 25.4]	24.5 [21.3, 26.8]	0.030
Procedure				
Coronary angiography	84 (56.0)	43 (57.3)	41 (54.7)	0.869
PCI	66 (44.0)	32 (42.7)	34 (45.3)	
Diagnosis				
Stable CAD	121 (80.7)	61 (81.3)	60 (80.0)	1.000
Acute coronary syndrome	29 (19.3)	14 (18.7)	15 (20.0)	
Prior myocardial infarction	77 (51.3)	30 (40.0)	47 (62.7)	0.009
Prior PCI	93 (62.0)	34 (45.3)	59 (78.7)	< 0.001
Prior CABG	4 (2.7)	2 (2.7)	2 (2.7)	1.000
Hypertension	98 (65.3)	45 (60.0)	53 (70.7)	0.230
Dyslipidemia	63 (42.0)	28 (37.3)	35 (46.7)	0.321
Diabetes mellitus	81 (54.0)	37 (49.3)	44 (58.7)	0.326
Stroke	5 (3.3)	4 (5.3)	1 (1.3)	0.367
Current smoking	29 (19.3)	9 (12.0)	20 (26.7)	0.037
Serum creatinine, mg/dL	1.36 [1.25, 1.63]	1.37 [1.26, 1.71]	1.35 [1.25, 1.61]	0.612
eGFR, mL/min/1.73 m ²	37.6 [32.8, 42.0]	38.0 [31.0, 42.2]	37.0 [33.2, 41.8]	0.949
GFR category				
3b (30 ≤ eGFR < 45)	125 (83.3)	59 (78.7)	66 (88.0)	0.189
4 (15 ≤ eGFR < 30)	25 (16.7)	16 (21.3)	9 (12.0)	
5 (eGFR < 15)	0 (0.0)	0 (0.0)	0 (0.0)	
Hemoglobin A1c, %	6.3 [5.9, 6.9]	6.1 [5.7, 6.9]	6.5 [6.0, 7.0]	0.058
Low-density lipoprotein cholesterol, mg/dL	87 [70, 108]	88 [72, 114]	81 [70, 103]	0.155
Hemoglobin, g/dL	11.8 [10.5, 13.4]	11.5 [10.3, 13.5]	12.1 [10.9, 13.3]	0.230
C-reactive protein, mg/dL	0.14 [0.05, 0.46]	0.12 [0.05, 0.35]	0.15 [0.06, 0.53]	0.320
NT-proBNP, pg/mL	835.5 [244.8, 3265.3]	1560.0 [270.0, 4268.5]	632.0 [175.0, 1679.5]	0.076
LVEF, %	53 [43, 64]	56 [44, 64]	52 [43, 63]	0.697
Mehran risk score	8 [7, 11]	8 [7, 11]	8 [7, 11]	0.548
Catheterization procedure				
Total agent volume, mL	174.1 [120.0, 244.8]	130.0 [88.0, 196.5]	209.7 [170.1, 271.8]	< 0.001
Total contrast volume, mL	138.0 [97.5, 200.0]	130.0 [88.0, 196.5]	142.0 [104.5, 200.0]	0.408
LMWD volume, mL	7.6 [0.0, 68.2]	0.0 [0.0, 0.0]	68.5 [43.9, 86.0]	< 0.001
OCT	95 (63.3)	20 (26.7)	75 (100.0)	< 0.001
Renal function post-procedure				
ΔCre within 5 d, mg/dL	-0.03 [-0.15, 0.13]	-0.04 [-0.15, 0.14]	-0.03 [-0.14, 0.10]	0.848
ΔCre at 1 mo, mg/dL	-0.03 [-0.17, 0.09]	-0.06 [-0.23, 0.10]	-0.02 [-0.14, 0.08]	0.276

ΔCre at 1 yr, mg/dL	0.01 [-0.14, 0.19]	-0.04 [-0.23, 0.08]	0.06 [-0.06, 0.29]	0.001
Acute kidney injury	14 (9.3)	7 (9.3)	7 (9.3)	1.000
Worsening renal function (ΔCre ≥ 0.3 mg/dL/1 yr)	28 (18.7)	9 (12.0)	19 (25.3)	0.059

Data are presented as *n* (%) or median (25th-75th percentile). CABG: Coronary artery bypass graft surgery; CAD: Coronary artery disease; ΔCre: Delta creatinine; eGFR: Estimated glomerular filtration rate; LMWD: Low-molecular-weight dextran; LVEF: Left ventricular ejection fraction; NT-proBNP: N-terminal pro B-type natriuretic peptide; OCT: Optical coherence tomography; PCI: Percutaneous coronary intervention.

Table 3 Univariable and multivariable logistic regression model for predicting worsening renal function (ΔCre ≥ 0.3 mg/dL/1-year) in matched cohort

Variable	Univariable				Multivariable			
	OR	95%CI lower limit	95%CI upper limit	P value	OR	95%CI lower limit	95%CI upper limit	P value
Female	1.72	0.68	4.39	0.256				
Age	0.96	0.92	0.99	0.036				Not selected
Body mass index, kg/m ²	1.02	0.92	1.13	0.759				
PCI	1.61	0.70	3.67	0.260				
Acute coronary syndrome	1.92	0.75	4.95	0.175				
Prior myocardial infarction	1.33	0.58	3.05	0.496				
Prior PCI	1.68	0.69	4.11	0.258				
Hypertension	0.95	0.40	2.23	0.897				
Diabetes mellitus	2.04	0.86	4.87	0.107				
Stroke	1.09	0.12	10.20	0.938				
Current smoking	1.17	0.43	3.22	0.756				
eGFR < 38.4 mL/min/1.73 m ²	4.18	1.58	11.00	0.004	4.27	1.59	11.40	0.004
LVEF, %	0.98	0.95	1.01	0.220				
Mehran risk score	1.07	0.98	1.17	0.127				
Total agent volume, mL	1.00	0.99	1.01	0.533				
Total contrast volume, mL	0.99	0.99	1.01	0.776				
LMWD volume ≥ 52 mL	2.76	1.19	6.37	0.018	2.83	1.18	6.76	0.019

CI: Confidence interval; eGFR: Estimated glomerular filtration rate; LMWD: Low-molecular-weight dextran; LVEF: Left ventricular ejection fraction; OR: Odds ratio; PCI: Percutaneous coronary intervention.

function at the 1-year follow-up, after propensity score-matched comparisons, even though LMWD volume for OCT was a median of 68.5 (43.9, 86.0) mL. The pathogenesis of contrast-induced AKI involves several mechanisms, such as nephrotoxic effects on tubular epithelial cells, tubular obstruction, decreased renal perfusion, and renal vasoconstriction^[4]. Osmotic nephrosis characterized by vacuolization and swelling of proximal tubular cells is induced by many substrates such as contrast medium and LMWD^[15]. LMWD is also associated with hyperoncotic kidney injury^[13]. Excretion of LMWD particles could be reduced, particularly in the presence of renal insufficiency. In previous studies, approximately 70% of LMWD was excreted by the kidneys within 24 h, while the remaining LMWD was excreted over several days^[14,31]. Administration of LMWD accompanied by a certain amount of contrast medium could potentially cause prolonged renal insufficiency in the long-term.

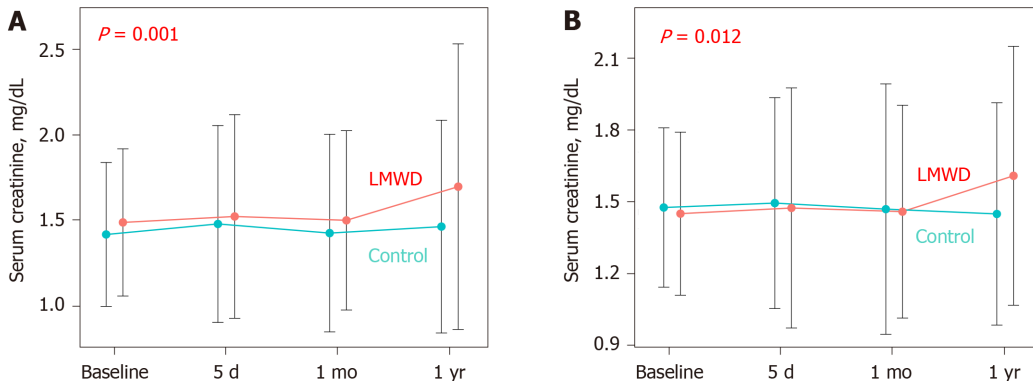


Figure 2 Serial comparison of serum creatinine levels at baseline, and within 5 d, 1 mo, and 1-year post-procedure. A: Entire study cohort. Renal function was consistently lower in the low-molecular-weight dextran (LMWD) group than in the control group; B: Propensity score-matched cohort. The LMWD group demonstrated a trend toward worsening renal insufficiency during the 1-year follow-up compared with the control group. LMWD: Low-molecular-weight dextran.

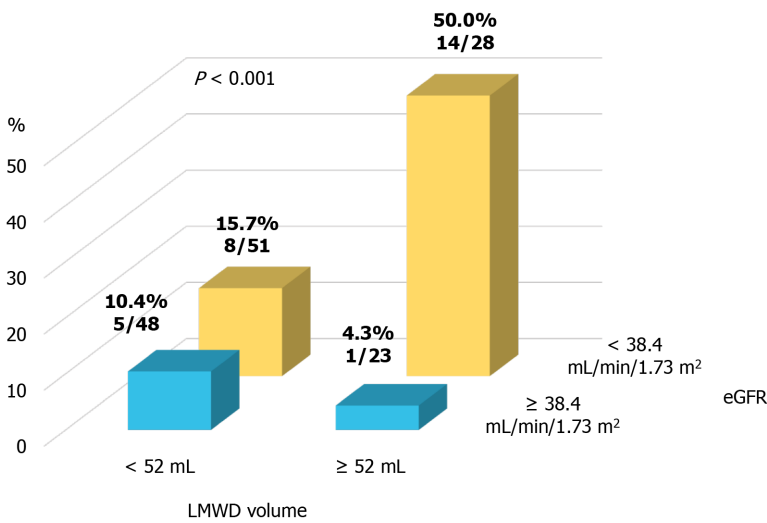


Figure 3 Prevalence of worsening renal function stratified by the cut-off values for low-molecular-weight dextran volume and baseline estimated glomerular filtration rate level in propensity score-matched cohort. eGFR: Estimated glomerular filtration rate; LMWD: Low-molecular-weight dextran.

Clinical implications

The present study indicated that the additional use of LMWD in patients with advanced renal insufficiency showed a strong trend toward renal impairment at the 1-year follow-up. Our results also suggested that greater LMWD volume may be a contributing factor to the progression of long-term renal dysfunction in patients with advanced renal insufficiency. Excessive use of LMWD in place of contrast medium may not effectively decrease the prevalence of renal impairment after OCT imaging.

Our results, including the propensity score-matched comparison, suggest that using LMWD for OCT in patients with advanced renal insufficiency should be avoided, or at least care should be exercised to reduce the amount of LMWD. The present study also suggested the importance of long-term follow-up of renal function after LMWD use for OCT imaging. Since our study is of hypothesis generating nature, further studies are needed to test this hypothesis.

Study limitations

First, this was a retrospective study from a single center with a relatively small sample size and, thus, has inherent limitations. Although we used propensity score matching to adjust for differences in patients’ baseline clinical characteristics, including renal function, the final decision regarding the choice of flushing agents for OCT was at the operator’s discretion, and selection bias cannot be canceled. Second, because we collected data from our institutional OCT registry, some patients with ACS underwent pre- and post-PCI OCT examinations for the culprit lesion, and some underwent OCT

examination for the non-culprit lesion before or after culprit lesion assessment/treatment for the clinical research. This nature of the study cohort might have led to an increase in contrast medium and/or LMWD volume. Third, we did not evaluate the influence of medical therapy and clinical status post-procedure on the incidence of contrast-induced AKI and worsening renal function, which could have affected our results. Although this study evaluated the renal function only within 5 d, and at 1 mo and 1-year post-procedure, the mid-term effect of LMWD on renal function was not fully studied. Fourth, the prevalence and severity of proteinuria and the cause of renal insufficiency were not assessed, and both could be closely related to the progression of renal dysfunction. Finally, we did not assess clinical outcomes or perform extensive subgroup analyses because of the relatively small number of events.

CONCLUSION

In this retrospective study, we observed the greater extent of the progression of renal dysfunction and the higher prevalence of worsening renal function, particularly at the 1-year follow-up, in patients with advanced renal insufficiency who underwent OCT imaging using LMWD. These findings provide a novel insight regarding LMWD use by interventionalists who are involved in OCT examinations. Further large, prospective studies are warranted.

ARTICLE HIGHLIGHTS

Research background

Low-molecular-weight dextran (LMWD) is considered a safe alternative to contrast media for blood displacement during optical coherence tomography (OCT) imaging. On the other hand, LMWD-induced acute kidney injury has been repeatedly reported.

Research motivation

The protective role of LMWD against kidney injury remains uncertain in patients with advanced renal insufficiency, particularly regarding the long-term influence.

Research objectives

To investigate whether the use of LMWD for OCT is protective against kidney injury in patients with advanced renal insufficiency.

Research methods

In this retrospective cohort study, we identified 421 patients with advanced renal insufficiency (estimated glomerular filtration rate < 45 mL/min/1.73 m²) who underwent coronary angiography or percutaneous coronary intervention; 79 patients who used additional LMWD for OCT imaging (LMWD group) and 342 patients who used contrast medium exclusively (control group). We evaluated the differences between these two groups and performed a propensity score-matched subgroup comparison.

Research results

Although baseline renal function was not statistically different between these two groups, the LMWD group demonstrated a strong trend toward the progression of renal insufficiency as indicated by the greater change in serum creatinine level during the 1-year follow-up compared with the control group. Patients in the LMWD group experienced worsening renal function more frequently than patients in the control group. Propensity score matching adjusted for total contrast media volume consistently indicated a trend toward worsening renal function in the LMWD group at the 1-year follow-up. Delta serum creatinine at 1-year follow-up was significantly greater in the LMWD group than that in the control group [0.06 (-0.06, 0.29) vs -0.04 (-0.23, 0.08) mg/dL, $P = 0.001$], despite using similar contrast volume.

Research conclusions

Additional use of LMWD for OCT may not be protective against worsening renal function in patients with advanced renal insufficiency.

Research perspectives

Since our study is of hypothesis generating nature, further large, prospective studies are warranted.

REFERENCES

- 1 **Parikh NI**, Hwang SJ, Larson MG, Levy D, Fox CS. Chronic kidney disease as a predictor of cardiovascular disease (from the Framingham Heart Study). *Am J Cardiol* 2008; **102**: 47-53 [PMID: 18572034 DOI: 10.1016/j.amjcard.2008.02.095]
- 2 **Gruberg L**, Mintz GS, Mehran R, Gangas G, Lansky AJ, Kent KM, Pichard AD, Satler LF, Leon MB. The prognostic implications of further renal function deterioration within 48 h of interventional coronary procedures in patients with pre-existent chronic renal insufficiency. *J Am Coll Cardiol* 2000; **36**: 1542-1548 [PMID: 11079656 DOI: 10.1016/s0735-1097(00)00917-7]
- 3 **Rihal CS**, Textor SC, Grill DE, Berger PB, Ting HH, Best PJ, Singh M, Bell MR, Barsness GW, Mathew V, Garratt KN, Holmes DR Jr. Incidence and prognostic importance of acute renal failure after percutaneous coronary intervention. *Circulation* 2002; **105**: 2259-2264 [PMID: 12010907 DOI: 10.1161/01.cir.0000016043.87291.33]
- 4 **Mehran R**, Dangas GD, Weisbord SD. Contrast-Associated Acute Kidney Injury. *N Engl J Med* 2019; **380**: 2146-2155 [PMID: 31141635 DOI: 10.1056/NEJMra1805256]
- 5 **McCullough PA**, Choi JP, Feghali GA, Schussler JM, Stoler RM, Vallabahn RC, Mehta A. Contrast-Induced Acute Kidney Injury. *J Am Coll Cardiol* 2016; **68**: 1465-1473 [PMID: 27659469 DOI: 10.1016/j.jacc.2016.05.099]
- 6 **Wang F**, Peng C, Zhang G, Zhao Q, Xuan C, Wei M, Wang N. Delayed kidney injury following coronary angiography. *Exp Ther Med* 2016; **12**: 530-534 [PMID: 27347090 DOI: 10.3892/etm.2016.3315]
- 7 **Turin TC**, James MT, Jun M, Tonelli M, Coresh J, Manns BJ, Hemmelgarn BR. Short-term change in eGFR and risk of cardiovascular events. *J Am Heart Assoc* 2014; **3**: e000997 [PMID: 25213565 DOI: 10.1161/JAHA.114.000997]
- 8 **Prati F**, Regar E, Mintz GS, Arbustini E, Di Mario C, Jang IK, Akasaka T, Costa M, Guagliumi G, Grube E, Ozaki Y, Pinto F, Serruys PW; Expert's OCT Review Document. Expert review document on methodology, terminology, and clinical applications of optical coherence tomography: physical principles, methodology of image acquisition, and clinical application for assessment of coronary arteries and atherosclerosis. *Eur Heart J* 2010; **31**: 401-415 [PMID: 19892716 DOI: 10.1093/eurheartj/ehp433]
- 9 **Prati F**, Guagliumi G, Mintz GS, Costa M, Regar E, Akasaka T, Barlis P, Tearney GJ, Jang IK, Arbustini E, Bezerra HG, Ozaki Y, Bruining N, Dudek D, Radu M, Erglis A, Motreff P, Alfonso F, Toutouzas K, Gonzalo N, Tamburino C, Adriaenssens T, Pinto F, Serruys PW, Di Mario C; Expert's OCT Review Document. Expert review document part 2: methodology, terminology and clinical applications of optical coherence tomography for the assessment of interventional procedures. *Eur Heart J* 2012; **33**: 2513-2520 [PMID: 22653335 DOI: 10.1093/eurheartj/ehs095]
- 10 **Ozaki Y**, Kitabata H, Tsujioka H, Hosokawa S, Kashiwagi M, Ishibashi K, Komukai K, Tanimoto T, Ino Y, Takarada S, Kubo T, Kimura K, Tanaka A, Hirata K, Mizukoshi M, Imanishi T, Akasaka T. Comparison of contrast media and low-molecular-weight dextran for frequency-domain optical coherence tomography. *Circ J* 2012; **76**: 922-927 [PMID: 22301848 DOI: 10.1253/circj.CJ-11-1122]
- 11 **Frick K**, Michael TT, Alomar M, Mohammed A, Rangan BV, Abdullah S, Grodin J, Hastings JL, Banerjee S, Brilakis ES. Low molecular weight dextran provides similar optical coherence tomography coronary imaging compared to radiographic contrast media. *Catheter Cardiovasc Interv* 2014; **84**: 727-731 [PMID: 23804461 DOI: 10.1002/ccd.25092]
- 12 **Feest TG**. Low molecular weight dextran: a continuing cause of acute renal failure. *Br Med J* 1976; **2**: 1300 [PMID: 1000202 DOI: 10.1136/bmj.2.6047.1300]
- 13 **Moran M**, Kapsner C. Acute renal failure associated with elevated plasma oncotic pressure. *N Engl J Med* 1987; **317**: 150-153 [PMID: 2439908 DOI: 10.1056/nejm198707163170306]
- 14 **Zwaveling JH**, Meulenbelt J, van Xanten NH, Hené RJ. Renal failure associated with the use of dextran-40. *Neth J Med* 1989; **35**: 321-326 [PMID: 2483959]
- 15 **Dickenmann M**, Oettl T, Mihatsch MJ. Osmotic nephrosis: acute kidney injury with accumulation of proximal tubular lysosomes due to administration of exogenous solutes. *Am J Kidney Dis* 2008; **51**: 491-503 [PMID: 18295066 DOI: 10.1053/j.ajkd.2007.10.044]
- 16 **Japan nephrology society**. [Special issue: Clinical practice guidebook for diagnosis and treatment of chronic kidney disease 2012]. *Nihon Jinzo Gakkai Shi* 2012; **54**: 1034-1191 [PMID: 23387281]
- 17 **Farrington K**, Covic A, Nistor I, Aucella F, Clyne N, De Vos L, Findlay A, Fouque D, Grodzicki T, Iyasere O, Jager KJ, Joosten H, Macias JF, Mooney A, Nagler E, Nitsch D, Taal M, Tattersall J, Stryckers M, van Asselt D, Van den Noortgate N, van der Veer S, van Biesen W. Clinical Practice Guideline on management of older patients with chronic kidney disease stage 3b or higher (eGFR<45 mL/min/1.73 m²): a summary document from the European Renal Best Practice Group. *Nephrol Dial Transplant* 2017; **32**: 9-16 [PMID: 28391313 DOI: 10.1093/ndt/gfw411]
- 18 **Mehran R**, Faggioni M, Chandrasekhar J, Angiolillo DJ, Bertolet B, Jobe RL, Al-Joundi B, Brar S, Dangas G, Batchelor W, Prasad A, Gurm HS, Tumlin J, Stone GW. Effect of a Contrast Modulation

- System on Contrast Media Use and the Rate of Acute Kidney Injury After Coronary Angiography. *JACC Cardiovasc Interv* 2018; **11**: 1601-1610 [PMID: 30139467 DOI: 10.1016/j.jcin.2018.04.007]
- 19 **Bleyer AJ**, Shemanski LR, Burke GL, Hansen KJ, Appel RG. Tobacco, hypertension, and vascular disease: risk factors for renal functional decline in an older population. *Kidney Int* 2000; **57**: 2072-2079 [PMID: 10792626 DOI: 10.1046/j.1523-1755.2000.00056.x]
 - 20 **Mehran R**, Aymong ED, Nikolsky E, Lasic Z, Iakovou I, Fahy M, Mintz GS, Lansky AJ, Moses JW, Stone GW, Leon MB, Dangas G. A simple risk score for prediction of contrast-induced nephropathy after percutaneous coronary intervention: development and initial validation. *J Am Coll Cardiol* 2004; **44**: 1393-1399 [PMID: 15464318 DOI: 10.1016/j.jacc.2004.06.068]
 - 21 **Balemans CE**, Reichert LJ, van Schelven BI, van den Brand JA, Wetzels JF. Epidemiology of contrast material-induced nephropathy in the era of hydration. *Radiology* 2012; **263**: 706-713 [PMID: 22535561 DOI: 10.1148/radiol.12111667]
 - 22 **Freeman RV**, Mehta RH, Al Badr W, Cooper JV, Kline-Rogers E, Eagle KA. Influence of concurrent renal dysfunction on outcomes of patients with acute coronary syndromes and implications of the use of glycoprotein IIb/IIIa inhibitors. *J Am Coll Cardiol* 2003; **41**: 718-724 [PMID: 12628712 DOI: 10.1016/s0735-1097(02)02956-x]
 - 23 **Herzog CA**, Ma JZ, Collins AJ. Comparative survival of dialysis patients in the United States after coronary angioplasty, coronary artery stenting, and coronary artery bypass surgery and impact of diabetes. *Circulation* 2002; **106**: 2207-2211 [PMID: 12390949 DOI: 10.1161/01.cir.0000035248.71165.eb]
 - 24 **Sørensen CR**, Brendorp B, Rask-Madsen C, Køber L, Kjølner E, Torp-Pedersen C. The prognostic importance of creatinine clearance after acute myocardial infarction. *Eur Heart J* 2002; **23**: 948-952 [PMID: 12069449 DOI: 10.1053/ehj.2001.2989]
 - 25 **Anavekar NS**, McMurray JJ, Velazquez EJ, Solomon SD, Kober L, Rouleau JL, White HD, Nordlander R, Maggioni A, Dickstein K, Zelenkofske S, Leimberger JD, Califf RM, Pfeffer MA. Relation between renal dysfunction and cardiovascular outcomes after myocardial infarction. *N Engl J Med* 2004; **351**: 1285-1295 [PMID: 15385655 DOI: 10.1056/NEJMoa041365]
 - 26 **Turin TC**, Tonelli M, Manns BJ, Ravani P, Ahmed SB, Hemmelgarn BR. Chronic kidney disease and life expectancy. *Nephrol Dial Transplant* 2012; **27**: 3182-3186 [PMID: 22442392 DOI: 10.1093/ndt/gfs052]
 - 27 **Bajaj NS**, Singh A, Zhou W, Gupta A, Fujikura K, Byrne C, Harms HJ, Osborne MT, Bravo P, Andrikopolou E, Divakaran S, Bibbo CF, Hainer J, Skali H, Taqueti V, Steigner M, Dorbala S, Charytan DM, Prabhu SD, Blankstein R, Deo RC, Solomon SD, Di Carli MF. Coronary Microvascular Dysfunction, Left Ventricular Remodeling, and Clinical Outcomes in Patients With Chronic Kidney Impairment. *Circulation* 2020; **141**: 21-33 [PMID: 31779467 DOI: 10.1161/CIRCULATIONAHA.119.043916]
 - 28 **Meneveau N**, Souteyrand G, Motreff P, Caussin C, Amabile N, Ohlmann P, Morel O, Lefrançois Y, Descotes-Genon V, Silvain J, Braik N, Chopard R, Chatot M, Ecarnot F, Tauzin H, Van Belle E, Belle L, Schiele F. Optical Coherence Tomography to Optimize Results of Percutaneous Coronary Intervention in Patients with Non-ST-Elevation Acute Coronary Syndrome: Results of the Multicenter, Randomized DOCTORS Study (Does Optical Coherence Tomography Optimize Results of Stenting). *Circulation* 2016; **134**: 906-917 [PMID: 27573032 DOI: 10.1161/CIRCULATIONAHA.116.024393]
 - 29 **Kubo T**, Shinke T, Okamura T, Hibi K, Nakazawa G, Morino Y, Shite J, Fusazaki T, Otake H, Kozuma K, Ioji T, Kaneda H, Serikawa T, Kataoka T, Okada H, Akasaka T; OPINION Investigators. Optical frequency domain imaging vs. intravascular ultrasound in percutaneous coronary intervention (OPINION trial): one-year angiographic and clinical results. *Eur Heart J* 2017; **38**: 3139-3147 [PMID: 29121226 DOI: 10.1093/eurheartj/ehx351]
 - 30 **Kurogi K**, Ishii M, Sakamoto K, Komaki S, Kusaka H, Yamamoto N, Takashio S, Arima Y, Yamamoto E, Kaikita K, Tsujita K. Optical Coherence Tomography-Guided Percutaneous Coronary Intervention With Low-Molecular-Weight Dextran-Effect on Renal Function. *Circ J* 2020; **84**: 917-925 [PMID: 32350234 DOI: 10.1253/circj.CJ-20-0093]
 - 31 **Nearman HS**, Herman ML. Toxic effects of colloids in the intensive care unit. *Crit Care Clin* 1991; **7**: 713-723 [PMID: 1713807 DOI: 10.1016/S0749-0704(18)30302-6]



Published by **Baishideng Publishing Group Inc**
7041 Koll Center Parkway, Suite 160, Pleasanton, CA 94566, USA
Telephone: +1-925-3991568
E-mail: bpgoffice@wjgnet.com
Help Desk: <https://www.f6publishing.com/helpdesk>
<https://www.wjgnet.com>

