

Case Report

Successful outcome with early renal transplantation following treatment of encapsulating peritoneal sclerosis

Frank Ward, Ann-Marie Moran, Malik Minhas and Alan Watson

Department of Nephrology, St. Vincent's University Hospital, Dublin, Ireland

Correspondence and offprint requests to: Frank Ward; E-mail: fward79@hotmail.com

Abstract

Encapsulating peritoneal sclerosis (EPS) is a rare complication of peritoneal dialysis (PD) associated with cocooning of the bowel within a sheath of fibrous tissue causing obstruction. Uncertainty remains regarding the aetiology, pathogenesis and optimal treatment. The current management of EPS is largely based on case reports and small series, and there are limited data regarding outcomes of patients who have undergone renal transplantation following treatment for EPS. We present the case of a 28-year-old man with EPS who was treated surgically followed by anti-fibrotic therapy, with tamoxifen, and 7 months later proceeded to renal transplantation with good outcome.

Keywords: encapsulating peritoneal sclerosis; peritoneal dialysis; renal transplant; tamoxifen

Background

Encapsulating peritoneal sclerosis (EPS) may be idiopathic or secondary, as in the case of chronic peritoneal dialysis (PD) patients. The prevalence in PD patients is reported at various frequencies internationally ranging from 0.6% to 3.3% [1,2]. Recently, an increased incidence in transplanted patients was suggested [3]. Mortality is historically high, and a study of 111 patients in the UK demonstrated an overall mortality of 53%, with median survival of 14 months and median time to death of 7 months [4]. Current management strategies are based on immunosuppressants or anti-fibrotic agents, like tamoxifen, combined with surgery and parenteral nutrition in some cases. There remains uncertainty regarding the role of current medical therapies and optimal timing, and outcome of transplantation.

Case report

A 28-year-old male with end-stage kidney disease treated by automated PD presented in September 2008 with peritonitis. His background history was chronic glomerulonephritis with nephrotic syndrome. The patient was on

PD for 30 months with no previous peritonitis episode. *Acinetobacter* peritonitis was confirmed and treated with intraperitoneal vancomycin and gentamicin for 2 weeks. The PD catheter was removed, necessitating transfer to haemodialysis.

Within 6 weeks of cessation of PD, the patient described intermittent abdominal pain with distension. Symptoms were progressive and associated with constipation, anorexia, fever, and weight loss. Initial investigation included a computed tomography (CT) abdominal scan (Figure 1) that showed gross ascites with no evidence of bowel obstruction. A diagnostic ascitic tap showed 430 white cells/cm³ (88% lymphocytes) and 900 red cells/cm³. Gram stain and culture, acid-fast bacillus (AFB) staining, and TB culture were negative. Cytology was negative for malignant cells.

Upon admission in January 2009, physical examination revealed generalized wasting and ascites. Blood tests showed an elevated ESR at 120 mm/h and C-reactive protein (CRP) at 133 mg/L. A plain film of abdomen was consistent with small bowel obstruction. Repeat ascitic tap showed predominant lymphocytes with negative TB culture. The patient proceeded to a laparoscopy that demonstrated the distal 60 cm of ileum cocooned in a thick fibrous membrane of visceral peritoneum. Open peritonectomy was performed. Histological appearance of the peritoneal membrane supported the diagnosis of EPS in this clinical setting, showing chronic inflammatory change with very marked submesothelial fibrotic thickening, very plump fibroblasts, and a significant loss of mesothelial cells (Figure 2).

Post-operatively, the patient was maintained on parenteral nutrition with bowel rest. Tamoxifen therapy was commenced at 10 mg twice daily. CRP remained elevated at 127 mg/L at this time. Abdominal distension persisted over subsequent weeks, and repeat CT scan demonstrated moderate ascites with no bowel obstruction. The patient was monitored as an inpatient, and a further surgical intervention was anticipated. However, abdominal distension and ascites began to subside, and appetite improved allowing resumption of oral diet. Bowels began to open regularly. The patient was discharged well in April 2009 on continued tamoxifen therapy. CRP had fallen to 38 mg/L. The patient

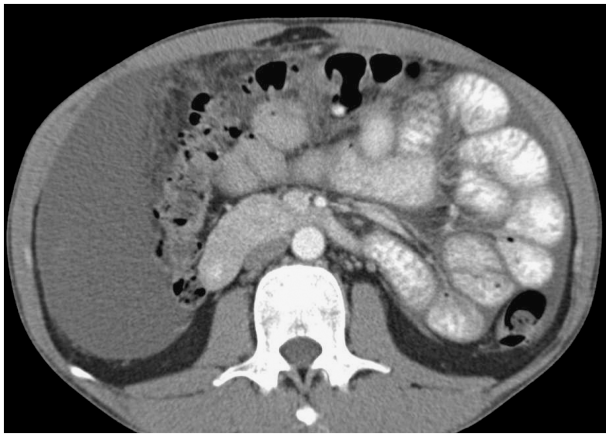


Fig. 1. CT abdomen showing large volume ascites, with normal bowels and no evidence of obstruction.

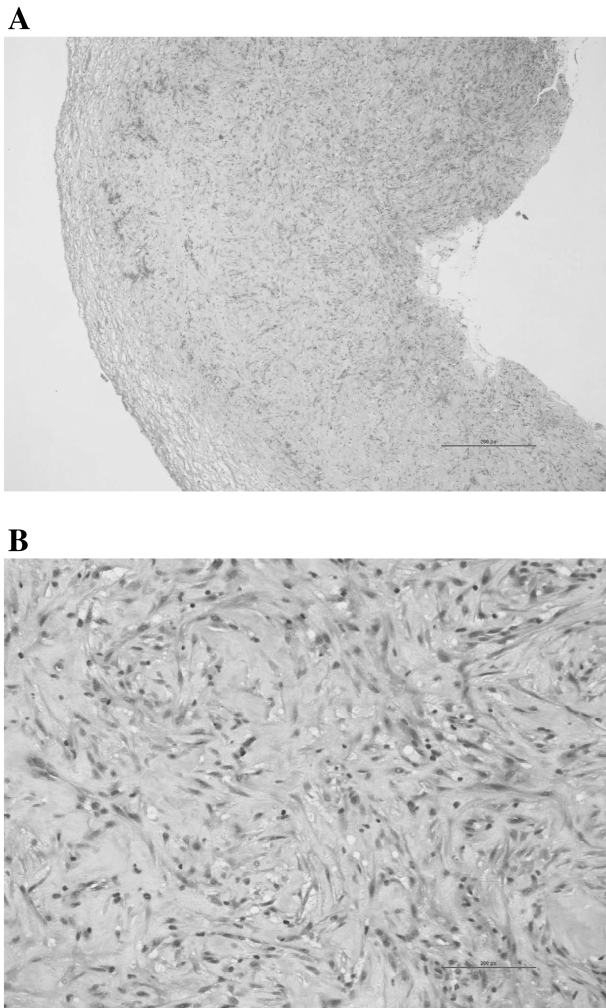


Fig. 2. Light microscopy of peritoneal biopsy (**A** low power; **B** high power) showing fibroadipose tissue with extensive chronic inflammatory change and a granulation tissue-like reaction consistent with sclerosing peritonitis.

was activated on the transplant list in August 2009, and tamoxifen was reduced to 10 mg once daily for 1 month and then discontinued. A cadaveric transplant was carried out in September 2009 without complication, using basiliximab induction, and tacrolimus, mycophenolate and prednisolone were started at time of transplantation. The patient is currently 9 months post-transplantation, and remains well with normal gastrointestinal function.

Discussion

On review of the current literature, we found a case report of one patient who underwent renal transplantation after 12 months of treatment with mycophenolate and prednisolone for EPS [5]. Our case demonstrates a positive outcome in EPS treated with surgical resection and tamoxifen, followed by successful renal transplantation shortly thereafter. Anti-fibrotic agents appear promising based on a series of cases reviews [1]. The use of tamoxifen, an anti-oestrogen drug used in breast cancer, stems from efficacy in other disorders such as retroperitoneal fibrosis. Tamoxifen treatment avoids the adverse effects of steroids and immunosuppressants, but may have inherent risks such as increased venous thrombosis. There is anecdotal evidence for combining anti-fibrotic treatment with steroid therapy. However, there remains no clear evidence for efficacy of this medication, optimal dosage regimes or duration of maintenance therapy.

Reduced EPS disease activity and improved survival have been observed in some patients who received immunosuppression with or without transplantation [6]. Recently, case series have reported the benefit of steroids, azathioprine and mycophenolate, alone or in combination [5,7]. There remains, however, no clear evidence that standard immunosuppressive agents, as used post-transplantation, can prevent the progression of EPS. The pathogenesis of EPS may involve peritoneal sclerosis, associated with PD, that is triggered into EPS, in part by increased expression of transforming growth factor beta (TGF β) [8], which interferes with local regulation of plasmin by plasminogen activator inhibitor type 1 and leads to adhesion formation [9]. This speculated 'second hit' may include an episode of peritonitis or possibly introduction of profibrotic drugs such as calcineurin inhibitors. Cyclosporin and tacrolimus are known to increase expression of TGF β [10]. Moreover, the reported emergence of EPS in recently transplanted patients questions the absolute benefit of immunosuppressants. However, if indeed there is a 'clinically' significant causality, we might expect to encounter a higher incidence of EPS in newly transplanted patients than what is currently reported. In cases of *de novo* EPS post-transplantation, it is widely believed to be the cessation of PD that is the trigger factor as opposed to introduction of any drug. Overall, the effect of transplantation in a case of treated EPS, as we have described, might be expected to be neutral.

In conclusion, whereas there is no specific protocol regarding optimal timing of transplantation after diagnosis and treatment, this case demonstrates the benefit of peritonectomy combined with tamoxifen treatment for EPS,

with early renal transplantation being both feasible and successful.

Acknowledgements. We are grateful to Dr Peter Rutherford, Medical Director—Europe, Middle East and Africa—at Baxter Healthcare for his advice.

Conflict of interest statement. None declared.

References

1. Eltoun MA, Wright S, Atchley J *et al.* Four consecutive cases of peritoneal dialysis related encapsulating peritoneal sclerosis treated successfully with tamoxifen. *Perit Dial Int* 2006; 26: 203–206
2. Summers AM, Clancy MJ, Syed F *et al.* Single-center experience of encapsulating peritoneal sclerosis in patients on peritoneal dialysis for end-stage renal failure. *Kidney Int* 2005; 68: 2381–2388
3. Korte MR, Yo M, Betjes MGH *et al.* Increasing incidence of severe encapsulating peritoneal sclerosis after kidney transplantation. *Nephrol Dial Transplant* 2007; 22: 2412–2414
4. Balasubramaniam G, Brown EA, Davenport A *et al.* The Pan-Thames EPS study: treatment and outcomes of encapsulating peritoneal sclerosis. *Nephrol Dial Transplant* 2009; 24: 3209–3215
5. Lafrance JP, Létourneau I, Ouiment D *et al.* Successful treatment of encapsulating peritoneal sclerosis with immunosuppressive therapy. *Am J Kidney Dis* 2008; 51: e7–e10
6. Junor BJ, McMillan MA. Immunosuppression in sclerosing peritonitis. *Adv Perit Dial* 1993; 9: 187–189
7. Wong CF, Beshir S, Khalil A *et al.* Successful treatment of encapsulating peritoneal sclerosis with azathioprine and prednisolone. *Perit Dial Int* 2005; 25: 285–287
8. Saito A. Peritoneal dialysis in Japan: the issue of encapsulating peritoneal sclerosis and future challenges. *Perit Dial Int* 2005; 25: 77–82
9. Holmdahl L, Kotseos K, Bergström M *et al.* Overproduction of transforming growth factor-beta1 (TGF-beta1) is associated with adhesion formation and peritoneal fibrinolytic impairment. *Surgery* 2001; 129: 626–632
10. Khanna A, Cairns V, Hosenpud JD. Tacrolimus induces increased expression of transforming growth factor-beta1 in mammalian lymphoid as well as nonlymphoid cells. *Transplantation* 1999; 67: 614–619

Received for publication: 24.3.10; Accepted in revised form: 22.6.10