



Macular neovascularization lesion type and vision outcomes in neovascular age-related macular degeneration: post hoc analysis of HARBOR

K. Bailey Freund^{1,2} · Giovanni Staurenghi³ · Jesse J. Jung^{4,5} · Sandrine A. Zweifel^{6,7} · Mariano Cozzi³ · Lauren Hill⁸ · Steven Blotner⁸ · Min Tsuboi⁸ · Shamika Gune⁸

Received: 23 September 2021 / Revised: 20 January 2022 / Accepted: 3 February 2022 / Published online: 3 March 2022
© The Author(s), under exclusive licence to Springer-Verlag GmbH Germany, part of Springer Nature 2022

Abstract

Purpose To characterize relationships between Consensus on Neovascular Age-Related Macular Degeneration Nomenclature (CONAN) Study Group classifications of macular neovascularization (MNV) and visual responses to ranibizumab in patients with neovascular age-related macular degeneration (nAMD).

Methods This was a post hoc analysis of the phase 3 HARBOR trial of ranibizumab in nAMD. Analyses included ranibizumab-treated eyes with baseline multimodal imaging data; baseline MNV; subretinal and/or intraretinal fluid at screening, baseline, or week 1; and spectral-domain optical coherence tomography images through month 24 ($n = 700$). Mean best-corrected visual acuity (BCVA) over time and mean BCVA change at months 12 and 24 were compared between eyes with type 1, type 2/mixed type 1 and 2 (type 2/M), and any type 3 MNV at baseline.

Results At baseline, 263 (37.6%), 287 (41.0%), and 150 (21.4%) eyes had type 1, type 2/M, and any type 3 lesions, respectively. Type 1 eyes had the best mean BCVA at baseline (59.0 [95% CI: 57.7–60.3] letters) and month 24 (67.7 [65.8–69.6] letters), whereas type 2/M eyes had the worst (50.0 [48.6–51.4] letters and 60.8 [58.7–62.9] letters, respectively). Mean BCVA gains at month 24 were most pronounced for type 2/M eyes (10.8 [8.9–12.7] letters) and similar for type 1 (8.7 [6.9–10.5] letters) and any type 3 eyes (8.3 [6.3–10.3] letters).

Conclusion Differences in BCVA outcomes between CONAN lesion type subgroups support the use of an anatomic classification system to characterize MNV and prognosticate visual responses to anti-vascular endothelial growth factor therapy for nAMD.

Trial registration ClinicalTrials.gov identifier: NCT00891735. Date of registration: April 29, 2009.

Keywords Consensus on Neovascular Age-Related Macular Degeneration Nomenclature (CONAN) · Macular neovascularization · Neovascular age-related macular degeneration · Ranibizumab · Visual acuity

Meeting presentation: Data reported in this manuscript were presented in part at the 43rd Annual Macula Society Meeting, San Diego, CA, February 19–22, 2020, and the 53rd Annual Scientific Meeting of the Retina Society VR, September 21–22, 2020.

✉ K. Bailey Freund
kbfreund@gmail.com

¹ Vitreous Retina Macula Consultants of New York,
New York, NY, USA

² Department of Ophthalmology, NYU Grossman School
of Medicine, New York, NY, USA

³ Department of Biomedical and Clinical Science Luigi Sacco,
Luigi Sacco Hospital, University of Milan, Milan, Italy

⁴ East Bay Retina Consultants, Inc., Oakland, CA, USA

⁵ Department of Ophthalmology, University of California,
San Francisco, CA, USA

⁶ Department of Ophthalmology, University Hospital Zurich,
Zurich, Switzerland

⁷ University of Zurich, Zurich, Switzerland

⁸ Genentech, Inc., South San Francisco, CA, USA

Key messages

- The Consensus on Neovascular Age-Related Macular Degeneration Nomenclature (CONAN) Study Group recently published consensus definitions to classify macular neovascularization (MNV) in patients with neovascular age-related macular degeneration (nAMD).
- In this first application of CONAN Study Group criteria to a major trial dataset, anatomic classification of MNV correlated with 24-month vision outcomes in the phase 3 HARBOR trial of ranibizumab in nAMD.
- These data support the adoption of an anatomic classification system to characterize MNV in patients with nAMD and aid predictions of treatment response in clinical practice.

Introduction

Neovascular age-related macular degeneration (nAMD) is a chronic, progressive retinal condition and a leading cause of severe vision loss among individuals aged ≥ 50 years [1–3]. Intravitreal anti-vascular endothelial growth factor (VEGF) therapy is the first-line strategy to improve visual and anatomic outcomes for patients with nAMD; however, clinical presentations are varied and responses to treatment often display considerable heterogeneity [1, 4]. A greater understanding of the pathophysiology and manifestations of nAMD can inform the development of individualized therapies and improve treatment outcomes across a diverse patient population [4].

For the past 3 decades, nAMD has commonly been subtyped by neovascular lesion characteristics observable via fluorescein angiography (FA). A formal FA-based classification system was first described in the Macular Photocoagulation Study in 1991 and categorized choroidal neovascularization (CNV) lesions as occult (poorly defined) or classic (well defined) according to patterns of fluorescence seen on FA [5, 6]. Previous studies of photodynamic therapy with verteporfin showed differences in vision outcomes between eyes with predominantly classic, minimally classic, and occult CNV lesions [7, 8]; however, subsequent analyses found that lesion size, rather than lesion type, may be a more significant predictor of treatment response [9]. More recently, exploratory analyses of the Comparison of Age-Related Macular Degeneration Treatment Trials (CATT) of anti-VEGF therapy in nAMD showed that predominantly or minimally classic lesions at baseline were associated with worse visual acuity (VA) at 1 year relative to occult lesions, and although eyes with retinal angiomatous proliferation (RAP) lesions initially displayed good visual responses to treatment, they were also more likely to develop macular atrophy over time [10, 11].

An anatomic classification system for CNV (type 1, beneath the retinal pigment epithelium [RPE]; type 2, between the sensory retina and RPE) was first proposed by Gass in 1994 [12]; however, widespread adoption of this

terminology was likely hampered by an inability to reliably discern the location of neovascular lesions using FA and color fundus photography (CFP) alone. More recent advances in retinal imaging, particularly spectral-domain optical coherence tomography (SD-OCT), have subsequently afforded us the opportunity to revisit an anatomic classification for neovascularization in nAMD. Multimodal imaging combined with histopathologic correlations has also enabled the characterization of other nAMD subtypes, including polypoidal choroidal vasculopathy (type 1 neovascularization with aneurysmal lesions) and RAP [4, 13–18].

In 2010, Freund et al. used SD-OCT in conjunction with dye angiography (FA and/or indocyanine green angiography) to develop an anatomic classification scheme that built upon the neovascular lesion subtypes originally proposed by Gass [4]. In addition to providing multimodal imaging definitions for type 1 and type 2 lesions, the authors introduced a type 3 subgroup to classify intraretinal neovascularization otherwise known as RAP and preferred the term neovascularization over CNV to accommodate lesions that originate from the retinal circulation [4, 18]. In a study of 266 eyes with newly diagnosed nAMD, Jung et al. found that grading OCT and FA images using these updated anatomic definitions showed good agreement with traditional FA-based grading, although the addition of OCT was able to detect a higher frequency of type 3 and mixed-type lesions than FA alone [19]. In a retrospective analysis of 210 newly diagnosed, treatment-naïve eyes receiving treat-and-extend anti-VEGF therapy for nAMD, Mrejen et al. also showed that anatomic classification of neovascular lesions was an independent predictor of VA over 4 years of follow-up, whereas FA-based classification was inconsistently correlated with vision outcomes during this period [20].

Recognizing a need for standardized terminology in research and clinical practice, the Consensus on Neovascular Age-Related Macular Degeneration Nomenclature (CONAN) Study Group recently published consensus nomenclature to classify nAMD subtypes based on multimodal imaging characteristics [21]. Similar to the classification proposed by Freund et al. [4], CONAN Study

Group criteria define neovascularization as type 1, type 2, mixed type 1 and 2, or type 3, depending on the anatomic location of the lesion; advocate the term macular neovascularization (MNV) over CNV or neovascularization; and also provide multimodal imaging definitions for other nAMD components and signs of disease activity, including polypoidal choroidal vasculopathy, retinal-choroidal anastomosis, subretinal fluid (SRF), and intraretinal fluid (IRF) [21].

Given that previous anatomic classifications for neovascular lesions have correlated with vision in patients with nAMD [20], we were interested to examine whether CONAN Study Group definitions of MNV would similarly associate with VA outcomes and might prognosticate longer-term responses to anti-VEGF therapy. To this end, we sought to characterize the relationships between CONAN Study Group classifications of baseline MNV and 24-month vision outcomes in the pHase 3 double-masked, multicenter, randomized, Active treatment-controlled study of the efficacy and safety of 0.5 mg and 2.0 mg Ranibizumab administered monthly or on an as-needed Basis in patients with subfoveal neOvasculaR age-related macular degeneration (HARBOR) trial [22, 23].

Methods

HARBOR

This was a post hoc analysis of the 24-month HARBOR trial of ranibizumab in patients with nAMD (ClinicalTrials.gov identifier, NCT00891735). HARBOR was conducted in accordance with Good Clinical Practice (International Conference on Harmonisation of Technical Requirements for Registration of Pharmaceuticals for Human Use E6), applicable US Food and Drug Administration regulations, the Health Insurance Portability and Accountability Act, and the tenets of the Declaration of Helsinki. The trial protocol was approved by institutional review boards and ethics committees as applicable, and all patients provided written informed consent to participate.

The study design, treatment protocol, and prespecified efficacy and safety outcomes of HARBOR are reported in

the original trial publications [22, 23]. Briefly, HARBOR evaluated the safety and efficacy of intravitreal ranibizumab 0.5 mg and 2.0 mg, administered monthly or as-needed (pro re nata [PRN]), in patients aged ≥ 50 years with treatment-naïve subfoveal nAMD ($N = 1097$). One eye per patient was designated the study eye and randomized 1:1:1:1 to receive monthly ranibizumab 0.5 mg ($n = 275$) or 2.0 mg ($n = 274$), or PRN ranibizumab 0.5 mg ($n = 275$) or 2.0 mg ($n = 273$) after 3 monthly loading doses. Inclusion criteria for the study eye were Snellen best-corrected VA (BCVA) 20/40–20/320 using Early Treatment Diabetic Retinopathy Study (ETDRS) charts; evidence of active subfoveal CNV (classic or occult); total lesion area < 12 disc areas or 30.48 mm^2 ; and total CNV area $\geq 50\%$ of the total lesion area as determined on FA.

Participants attended monthly study visits through month 24. From month 3 onward, patients randomized to PRN ranibizumab received re-treatment upon prespecified signs of disease activity, defined as a ≥ 5 -letter decrease in BCVA from the previous visit or any evidence of IRF, SRF, or subretinal pigment epithelial fluid on SD-OCT. Throughout the treatment period, BCVA was evaluated monthly using standard ETDRS protocols, SD-OCT (macular cube scans composed of 512 A-scans and 128 B-scans over a 6×6 -mm square centered on the fovea) was performed at each study visit, and FA and CFP were performed at baseline and months 3, 6, 12, 18, and 24. CFP, FA, and SD-OCT images were independently reviewed by masked graders at a single central reading center.

Post hoc analyses

The present study evaluated the relationship between anatomic lesion subtype and vision outcomes in eyes with baseline MNV evaluable by all of SD-OCT, CFP, and FA; SRF and/or IRF at baseline, screening, or week 1; and SD-OCT images available through month 24. Baseline multimodal images were retrospectively reviewed by ≥ 1 reader from the Web Reading Center at the Eye Clinic, Luigi Sacco Hospital, University of Milan (Milan, Italy), and MNV lesions were classified as type 1, type 2, mixed type 1 and 2, and type 3 using criteria consistent with CONAN Study Group definitions (Table 1) [21]. In particular, type 3 MNV was

Table 1 CONAN Study Group nomenclature and definitions for MNV lesions in nAMD (adapted from Spaide et al. [21])

MNV lesion type	Multimodal imaging findings
Type 1	Neovascularization located between Bruch's membrane and the RPE
Type 2	Neovascularization in the subretinal space above the RPE
Mixed type 1 and 2	Neovascularization in both the sub-RPE and subretinal compartments
Type 3	Intraretinal neovascularization originating from the deep vascular complex

CONAN Consensus on Neovascular Age-Related Macular Degeneration Nomenclature, MNV macular neovascularization, nAMD neovascular age-related macular degeneration, RPE retinal pigment epithelium

identified by small flame hemorrhage in the perimacular area on CFP, feeding retinal vessel larger than surrounding perifoveal vessels on FA, floating net (between retinal vessel layer and choroidal vessels) on stereo FA, FA hot spot at the center of RPE detachment (if present), presence (not always) of cystoid edema on SD-OCT, presence (not always) of interrupted RPE layer of an RPE detachment on SD-OCT, and reticular pseudodrusen on SD-OCT. Indirect evidence of type 3 MNV included retinal choroidal anastomosis and reticular pseudodrusen in the fellow eye. To assess repeatability, selected images were reviewed by a second independent reader; in the event of a discrepancy, the readers met to adjudicate each case. If the readers were unable to resolve the discrepancy or had <90% confidence in any of the assessments (per reading center guidelines), the case was reviewed by the principal investigator (G.S.) for a final determination.

Post hoc analyses compared 24-month BCVA outcomes (mean BCVA over time and mean change from baseline at months 12 and 24) between study eyes with type 1, type 2/mixed type 1 and 2 (type 2/M), and any evidence of type 3 MNV lesions at baseline. The pooled type 2/M subgroup was based on the observation that very few eyes ($n=30$) had mixed type 1 and 2 lesions at baseline, and the hypothesis that type 2 MNV may occur in conjunction with undetected type 1 MNV [4].

Statistical analysis

Post hoc analyses were performed using observed data, with no imputation for missing values. Baseline and 24-month BCVA outcomes (described using means and 95% CIs) are reported for the overall analysis population (all HARBOR treatment arms pooled), in addition to monthly and PRN-treated subgroups.

Results

In total, 700 study eyes in HARBOR had SD-OCT, CFP, and FA images available to assess anatomic MNV lesion type at baseline; SRF and/or IRF at baseline, screening, or week 1; and SD-OCT images through month 24. Classification according to CONAN Study Group criteria identified 263

(37.6%) eyes with type 1 MNV lesions, 287 (41.0%) eyes with type 2/M lesions, and 150 (21.4%) eyes with any type 3 lesions at baseline. The baseline distribution of eyes across MNV lesion types were generally balanced for monthly and PRN-treated subgroups (Table 2).

24-month BCVA profiles by baseline MNV lesion type

Mean BCVA over 24 months was consistently greater in eyes with type 1 MNV lesions at baseline and lowest in those with type 2/M lesions (Fig. 1a). Among type 1 eyes, mean BCVA was 59.0 ETDRS letters (95% CI: 57.7–60.3; approximate Snellen equivalent, ~20/63) at baseline, increased to 68.3 ETDRS letters (66.6–70.1; ~20/40) at month 12, and was maintained at 67.7 ETDRS letters (65.8–69.6; ~20/40) at month 24; corresponding BCVA in type 2/M eyes was 50.0 ETDRS letters (48.6–51.4; ~20/100), 61.3 ETDRS letters (59.3–63.3; ~20/63), and 60.8 ETDRS letters (58.7–62.9; ~20/63), respectively. In eyes with any type 3 lesions, mean BCVA was 55.3 ETDRS letters (53.4–57.1; ~20/80) at baseline and 65.3 ETDRS letters (62.9–67.7; ~20/50) at month 12; however, BCVA at month 24 (63.5 [61.0–66.0] ETDRS letters; ~20/50) suggests that any type 3 eyes may tend to lose initial vision gains over time. Trends in BCVA over 24 months were generally similar between monthly and PRN-treated subgroups; type 1 eyes displayed the best mean BCVA profile whereas type 2/M eyes displayed the worst, regardless of whether they received monthly or PRN ranibizumab (Fig. 1b, c, respectively).

Change in BCVA by baseline MNV lesion type

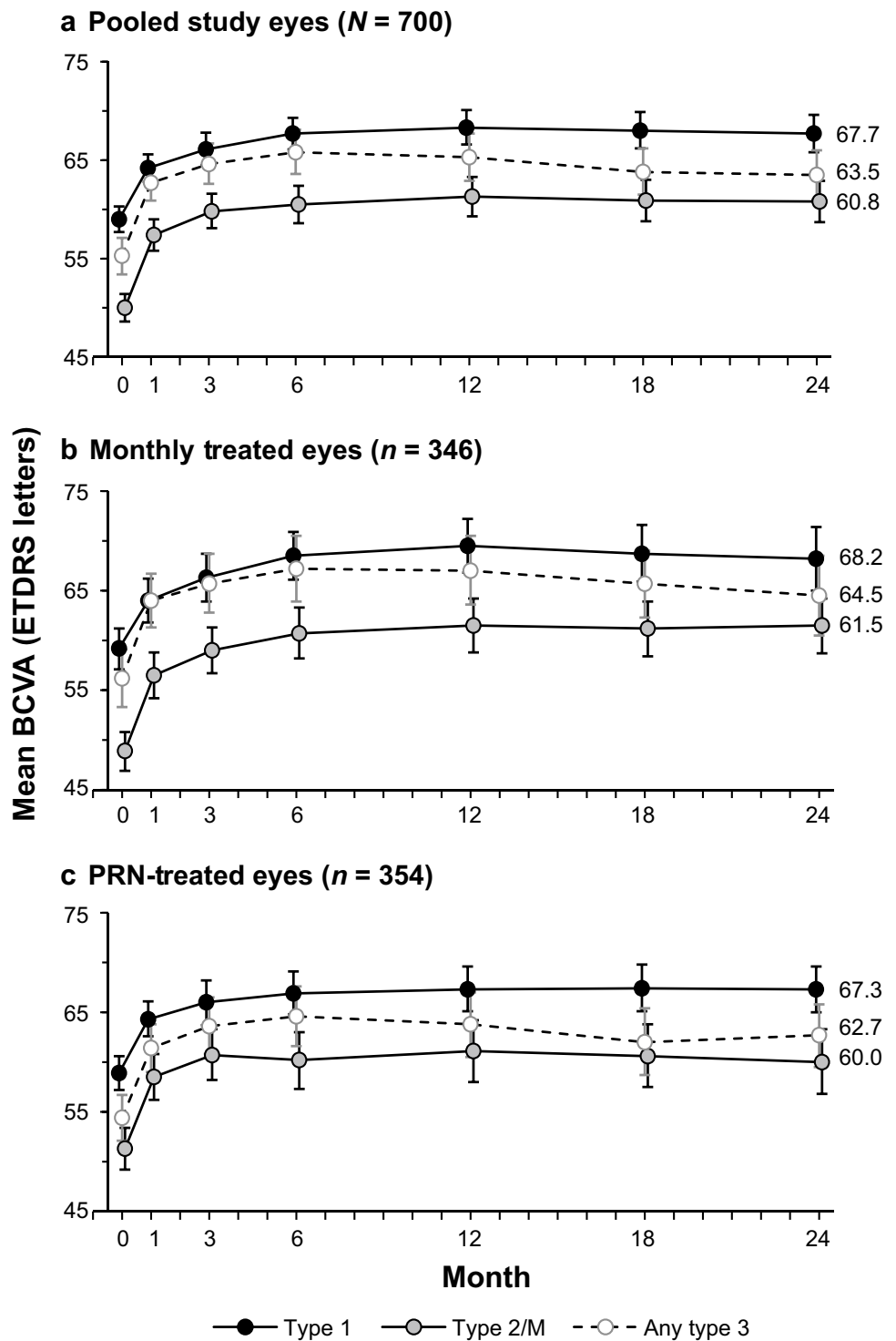
Although eyes with type 1 MNV lesions had the highest mean BCVA profiles over 24 months, we observed a small trend for greater mean BCVA gains among eyes with type 2/M lesions at baseline (Fig. 2a). In these eyes, mean BCVA change from baseline at month 12 was 11.1 ETDRS letters (95% CI: 9.3–12.8), compared with 9.3 (7.8–10.8) ETDRS letters in eyes with type 1 lesions and 9.8 (8.1–11.6) ETDRS letters in eyes with any type 3 lesions at baseline. Corresponding mean BCVA gains at month 24 were 10.8 (8.9–12.7), 8.7 (6.9–10.5), and 8.3 (6.3–10.3) ETDRS letters, respectively.

Table 2 Distribution of HARBOR study eyes across baseline MNV lesion types

Baseline MNV lesion type, n (%)	Monthly treated eyes ($n=346$)	PRN-treated eyes ($n=354$)	Pooled study eyes ($N=700$)
Type 1	123 (35.5)	140 (39.5)	263 (37.6)
Type 2/M	151 (43.6)	136 (38.4)	287 (41.0)
Any type 3	72 (20.8)	78 (22.0)	150 (21.4)

MNV macular neovascularization, PRN pro re nata (as-needed), type 2/M type 2/mixed type 1 and 2

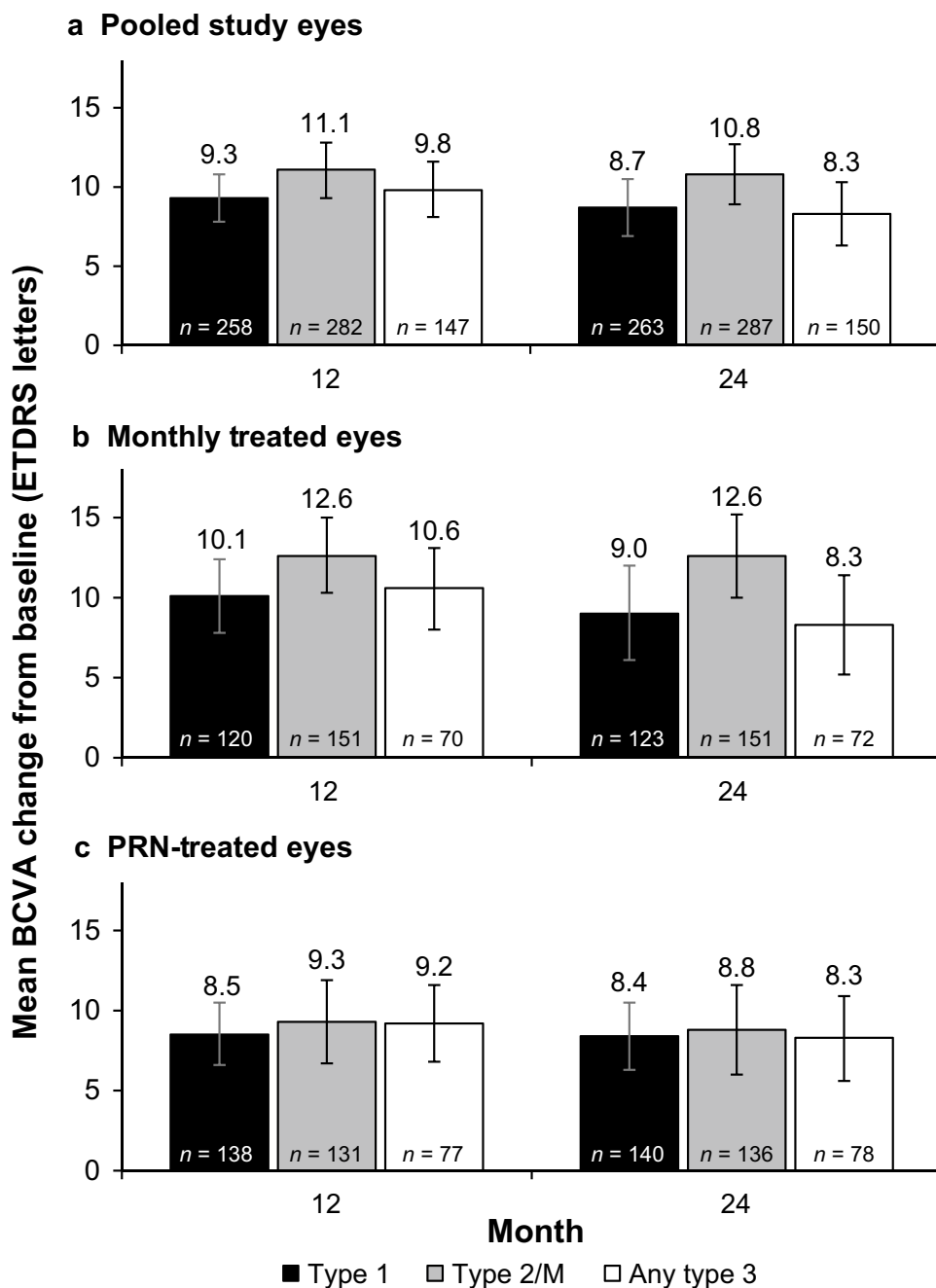
Fig. 1 Mean BCVA over 24 months by baseline MNV lesion type in **a**, pooled monthly and PRN treatment arms; **b**, monthly treated eyes; and **c**, PRN-treated eyes in HARBOR. Error bars represent 95% CI. BCVA best-corrected visual acuity, ETDRS Early Treatment Diabetic Retinopathy Study, MNV macular neovascularization, PRN pro re nata (as-needed), type 2/M type 2/mixed type 1 and 2



For all MNV lesion type subgroups, small improvements in mean BCVA gains were observed for eyes randomized to monthly versus PRN ranibizumab (Fig. 2b and 2c). This trend was most pronounced for eyes with type 2/M lesions at baseline; mean BCVA gains at month 24 were 12.6 (10.0–15.2) versus 8.8 (6.0–11.6) ETDRS letters in monthly

versus PRN-treated eyes, respectively. Regardless of treatment regimen, 12-month vision gains achieved in type 1 and type 2/M eyes were generally maintained at month 24; in comparison, any type 3 eyes displayed small vision losses between month 12 and month 24.

Fig. 2 Mean BCVA change by baseline MNV lesion type in: **a**, pooled monthly and PRN treatment arms; **b**, monthly treated eyes; and **c**, PRN-treated eyes in HARBOR. Error bars represent 95% CI. BCVA best-corrected visual acuity, ETDRS Early Treatment Diabetic Retinopathy Study, MNV macular neovascularization, PRN pro re nata (as-needed), type 2/M type 2/ mixed type 1 and 2



Discussion

There is an unmet need for individualized nAMD therapies that reduce the burden of treatment on patients, caregivers, and clinicians, and improve long-term outcomes across the spectrum of nAMD [22, 24]. In this first application of CONAN Study Group criteria to a major nAMD dataset, we showed that baseline MNV lesion type correlated with 24-month vision outcomes among ranibizumab-treated eyes in the phase 3 HARBOR trial. These data support the adoption of an anatomic classification system to characterize

MNV in patients with nAMD and aid predictions of treatment response in clinical practice.

When we retrospectively applied CONAN Study Group criteria to multimodal images collected in HARBOR, eyes with type 1 MNV at baseline had the best mean BCVA profile over 24 months, whereas those with type 2/M lesions had the lowest BCVA overall but achieved greater mean vision gains at months 12 and 24. Non-overlapping 95% CI error bars in Fig. 1 indicate statistical significance ($p < 0.05$) and suggest different courses of vision between type 1 and type 2/M lesion subgroups. Our findings coincide with a

previous study of treat-and-extend anti-VEGF therapy for nAMD, which showed that mean VA over 4 years was consistently greater in eyes with type 1 neovascularization (as defined by Freund et al. [4]) and lowest in those with type 2 and mixed-type lesions [20]. Of note, eyes with type 2 neovascularization at baseline achieved greater VA improvements with anti-VEGF therapy than eyes with other neovascular lesion types [20]. Similarly, the landmark Minimally Classic/Occult Trial of the Anti-VEGF Antibody Ranibizumab in the Treatment of Neovascular Age-Related Macular Degeneration (MARINA) [25] and Anti-VEGF Antibody for the Treatment of Predominantly Classic CNV in Age-related Macular Degeneration (ANCHOR) [26] trials of ranibizumab in nAMD showed that vision gains achievable with anti-VEGF therapy were dependent on baseline lesion type. In MARINA, eyes with occult or minimally classic neovascularization as determined by FA and CFP (CONAN Study Group equivalent of type 1 or mixed type 1 and 2 MNV, respectively [21]) had a mean baseline VA of 53.1–53.7 ETDRS letters across treatment arms, and those randomized to ranibizumab 0.5 mg gained 6.6 ETDRS letters on average at month 24 [25]. In comparison, study eyes in ANCHOR had predominantly classic lesions (roughly equivalent to type 2 MNV [21]), a mean baseline VA of 45.5–47.1 ETDRS letters across treatment arms, and those receiving ranibizumab 0.5 mg achieved a mean VA improvement of 10.7 ETDRS letters at month 24 [26]. Taken together, our results and others indicate that eyes with sub-RPE neovascularization (i.e., occult or type 1 MNV) typically display higher baseline BCVA and achieve smaller vision gains with treatment, whereas those with subretinal lesions (i.e., classic or type 2 MNV) have lower baseline BCVA and therefore greater capacity for vision improvement with anti-VEGF therapy. Lower baseline BCVA in eyes with type 2 lesions may reflect the propensity for subretinal MNV to damage photoreceptor inner and outer segments, whereas greater capacity for vision improvement supports the hypothesis that vessels in type 2 lesions are less mature and thus more sensitive to anti-VEGF therapy [4, 27].

Our results also suggest that eyes with type 1 MNV at baseline are more likely to maintain greater VA over time, which is consistent with a retrospective observational study that identified type 1 lesions as a significant baseline predictor of good vision over 4 years of anti-VEGF therapy [28]. It has been hypothesized that sub-RPE neovascularization in nAMD represents a compensatory response to hypoxia that limits ischemia and further damage to the RPE [29–31]. In support of this, previous studies have associated type 1 (or occult) MNV with lower rates of geographic atrophy, macular atrophy progression, and retinal scarring compared with other MNV subtypes [31–34]. Similar to type 1 MNV, the presence of SRF has also been associated with

lower rates of atrophy and better long-term vision outcomes [30, 35–38], and the phase 4 FLUID study (Comparison of Treatment Regimens Using Ranibizumab: Intensive [Resolution of Intra- and Subretinal fluid] Versus Relaxed [Resolution of Primarily Intraretinal Fluid]) recently showed that BCVA gains in patients treated with a ranibizumab treat-and-extend regimen that tolerated some SRF were comparable with those receiving a treat-and-extend regimen that resolved all SRF [39]. Based on these findings, Sadda et al. subsequently proposed that a small amount of SRF may indicate minimally exudative type 1 MNV and that residual sub-RPE neovascularization, rather than residual SRF, may be mediating these protective effects [30].

We observed slightly greater mean vision gains in monthly versus PRN-treated eyes across all MNV lesion type subgroups (though most pronounced in type 2/M eyes), highlighting the importance of close monitoring and treatment for all patients with nAMD. Indeed, PRN protocols in clinical trials typically allow frequent follow-up and prompt re-treatment that are difficult to maintain in clinical practice; as a result, real-world injection frequencies and vision outcomes are routinely lower than those reported in clinical trials [40]. This has been particularly exemplified during the COVID-19 pandemic, which continues to disrupt timely access to ophthalmic care around the world [41, 42]. Landmark trials such as CATT and the Open-Label Extension Trial of Ranibizumab for Choroidal Neovascularization Secondary to Age-Related Macular Degeneration (HORIZON) study, and findings from the Fight Retinal Blindness Study Group, have similarly associated less frequent treatment and monitoring with poorer long-term vision in patients with nAMD [43–45]; however, these studies did not examine whether anatomical classification of baseline MNV affected the relationship between injection frequency and treatment outcomes.

Regardless of monthly or PRN treatment regimen, eyes with type 1 or type 2/M MNV at HARBOR baseline achieved initial vision gains with ranibizumab that were maintained through study end at month 24. In comparison, both monthly and PRN-treated eyes with any type 3 lesions at baseline tended to lose initial vision gains over time, suggesting that a mechanism other than persistent and/or recurrent exudation, such as increased incidence and progression of macular atrophy, may be contributing to gradual visual decline in these eyes [11, 33, 46]. In fact, PRN-treated eyes with any type 3 MNV required fewer injections over 24 months, on average, when compared with PRN-treated eyes with type 1 or type 2/M lesions at baseline (data not shown). This may possibly reflect the nature of type 3 lesions, which are characterized by multiple small intraretinal hemorrhages, focal RPE atrophy, and exudation typically in the form of intraretinal cystoid macular edema [4, 21]. Previous studies have shown that eyes with type 3 MNV

are highly responsive to anti-VEGF therapy and are more likely to achieve extended remission than eyes with type 2 lesions [47, 48].

Although FA has traditionally been considered the gold standard imaging modality to visualize retinal vasculature and identify MNV, it is invasive and labor intensive, and the need for intravenous dyes has been associated with adverse events (namely nausea and vomiting) in some patients [49, 50]. Terms traditionally used to describe neovascular lesions as seen on FA are not fully applicable to newer SD-OCT, swept-source OCT, and OCT angiography technologies, which can non-invasively provide 3-dimensional, depth-resolved images of retinal structure and blood flow [4, 21, 51]. Despite these advantages, the diagnostic accuracy of OCT alone has not been widely studied, and several groups have recommended that OCT-based imaging should supplement but not replace FA for diagnosing nAMD and monitoring disease activity [50, 52, 53]. Overall, the results of this study and others highlight the utility of multimodal imaging, in conjunction with an updated anatomic classification system, to characterize MNV subtypes and predict longer-term prognoses for patients with nAMD [19, 20, 33].

Limitations include the post hoc nature of our analysis, in which CONAN Study Group criteria were retrospectively applied to prospectively collected multimodal images. Vision outcomes by baseline MNV lesion type were not prespecified endpoints in HARBOR; therefore, our analysis may be inadequately powered for comparison between subgroups. As previously described, eyes with type 2 and mixed type 1 and 2 lesions were pooled in this study to account for the finding that only 4% (30/700 eyes) had evidence of mixed type 1 and 2 lesions at baseline, and the possibility that type 2 MNV could occur in conjunction with undetected type 1 MNV [4]. Moreover, eyes with any type 3 lesions at baseline were not further subclassified by stage to maintain adequate sample sizes for statistical analysis. Because our study characterized relationships between baseline MNV lesion type and visual responses to ranibizumab in nAMD, we were unable to account for cases of changing lesion composition following anti-VEGF treatment [54]. Although our results suggest an association between anatomic MNV lesion type at baseline and 24-month vision outcomes in HARBOR, further prospective studies are needed to quantify the predictive value of the CONAN Study Group classification system on visual responses to anti-VEGF therapy in nAMD.

In conclusion, this post hoc analysis of HARBOR revealed associations between baseline MNV lesion type classified using CONAN Study Group criteria and 24-month vision outcomes among ranibizumab-treated patients with nAMD. These findings highlight the potential for an anatomic MNV classification system to characterize the diversity seen among patients with nAMD and

prognosticate visual responses to anti-VEGF therapy in clinical practice.

Author contribution All authors participated in the design of the study and the collection, analysis, and interpretation of the data. All authors participated in the preparation of the manuscript and the decision to submit for publication.

Funding Financial support was provided by Genentech, Inc., a member of the Roche Group (South San Francisco, CA), for the study and third-party writing assistance, which was provided by Karina D. Hamilton-Peel, PhD, CMPP, of Envision Pharma Group. The sponsor participated in the design of the study; collection, management, analysis, and interpretation of the data; and preparation, review, and approval of the manuscript.

Data availability Qualified researchers may request access to individual patient level data through the clinical study data request platform (<https://vivli.org/>). Further details on Roche's criteria for eligible studies are available here (<https://vivli.org/members/ourmembers/>). For further details on Roche's Global Policy on the Sharing of Clinical Information and how to request access to related clinical study documents, see here (https://www.roche.com/research_and_development/who_we_are_how_we_work/clinical_trials/our_commitment_to_data_sharing.htm).

Code availability Not applicable.

Declarations

Ethics approval The HARBOR trial was conducted in accordance with Good Clinical Practice (International Conference on Harmonisation of Technical Requirements for Registration of Pharmaceuticals for Human Use [ICH] E6), applicable US Food and Drug Administration regulations, the Health Insurance Portability and Accountability Act, and the tenets of the Declaration of Helsinki. The trial protocol was approved by institutional review boards and ethics committees as applicable.

Consent to participate Written informed consent was obtained from all participants in the HARBOR trial.

Consent for publication Not applicable.

Conflict of interest KBF has served as a consultant to Allergan, Bayer HealthCare, Carl Zeiss Meditec, Genentech, Inc., Heidelberg Engineering, Novartis, and Regeneron, and has received grant support from Genentech, Inc. and Roche. GS has served as a consultant to Allergan, Apellis, Bayer HealthCare, Boehringer Ingelheim, CenterVue, Chengdu Kanghong, Genentech, Inc., Heidelberg Engineering, Novartis, and Roche; received grant support from Carl Zeiss Meditec, CenterVue, Heidelberg Engineering, Nidek, Optos, Optovue, Quantel Medical, and Topcon; received lecture fees from Bayer HealthCare, Heidelberg Engineering, Nidek, Novartis, and Roche; and declares patents and/or royalties from Ocular Instruments. JJJ has served as a consultant to Carl Zeiss Meditec. SZ has served as a consultant to Allergan, Bayer HealthCare, Novartis, and Roche, and received grant support from Bayer HealthCare and Novartis. MC has received grant support from Bayer HealthCare, CenterVue, and Nidek. LH has served as a consultant to Aerpio, Alimera, Genentech, Inc., PolyPhotonix, and RecensMedical. SB and SG are employees of Genentech, Inc. MT was an employee of Genentech, Inc. during the course of this study (current employee of Kodiak Sciences Inc.).

References

- Flaxel CJ, Adelman RA, Bailey ST, Fawzi A, Lim JJ, Vemulakonda GA, Ying G-S (2020) Age-related macular degeneration preferred practice pattern[®]. *Ophthalmology* 127(1):P1–P65. <https://doi.org/10.1016/j.ophtha.2019.09.024>
- Wong TY, Chakravarthy U, Klein R, Mitchell P, Zlateva G, Bugge R, Fahrback K, Probst C, Sledge I (2008) The natural history and prognosis of neovascular age-related macular degeneration: a systematic review of the literature and meta-analysis. *Ophthalmology* 115(1):116–126. <https://doi.org/10.1016/j.ophtha.2007.03.008>
- Congdon N, O'Colmain B, Klaver CCW, Klein R, Muñoz B, Friedman DS, Kempen J, Taylor HR, Mitchell P, Eye Diseases Prevalence Research Group (2004) Causes and prevalence of visual impairment among adults in the United States. *Arch Ophthalmol* 122(4):477–485. <https://doi.org/10.1001/archophth.122.4.477>
- Freund KB, Zweifel SA, Engelbert M (2010) Do we need a new classification for choroidal neovascularization in age-related macular degeneration? *Retina* 30(9):1333–1349. <https://doi.org/10.1097/IAE.0b013e3181e7976b>
- Macular Photocoagulation Study Group (1991) Laser photocoagulation of subfoveal neovascular lesions in age-related macular degeneration. Results of a randomized clinical trial. *Arch Ophthalmol* 109(9):1220–1231. <https://doi.org/10.1001/archophth.1991.01080090044025>
- Macular Photocoagulation Study Group (1996) Occult choroidal neovascularization. Influence on visual outcome in patients with age-related macular degeneration. *Arch Ophthalmol* 114(4):400–412. <https://doi.org/10.1001/archophth.1996.01100130396006>
- Treatment of Age-Related Macular Degeneration with Photodynamic Therapy (TAP) Study Group (2001) Photodynamic therapy of subfoveal choroidal neovascularization in age-related macular degeneration with verteporfin: two-year results of 2 randomized clinical trials—TAP report 2. *Arch Ophthalmol* 119(2):198–207. <https://doi.org/10.1001/pubs.Ophthalmol.-ISSN-0003-9950-119-2-ecs00156>
- Verteporfin In Photodynamic Therapy Study Group (2001) Verteporfin therapy of subfoveal choroidal neovascularization in age-related macular degeneration: two-year results of a randomized clinical trial including lesions with occult with no classic choroidal neovascularization—verteporfin in photodynamic therapy report 2. *Am J Ophthalmol* 131(5):541–560. [https://doi.org/10.1016/s0002-9394\(01\)00967-9](https://doi.org/10.1016/s0002-9394(01)00967-9)
- Treatment of Age-Related Macular Degeneration With Photodynamic Therapy and Verteporfin in Photodynamic Therapy Study Groups (2003) Effect of lesion size, visual acuity, and lesion composition on visual acuity change with and without verteporfin therapy for choroidal neovascularization secondary to age-related macular degeneration: TAP and VIP report no. 1. *Am J Ophthalmol* 136(3):407–418. [https://doi.org/10.1016/s0002-9394\(03\)00223-x](https://doi.org/10.1016/s0002-9394(03)00223-x)
- Ying GS, Huang J, Maguire MG, Jaffe GJ, Grunwald JE, Toth C, Daniel E, Klein M, Pieramici D, Wells J, Martin DF, Comparison of Age-related Macular Degeneration Treatments Trials Research Group (2013) Baseline predictors for one-year visual outcomes with ranibizumab or bevacizumab for neovascular age-related macular degeneration. *Ophthalmology* 120(1):122–129. <https://doi.org/10.1016/j.ophtha.2012.07.042>
- Daniel E, Shaffer J, Ying G-S, Grunwald JE, Martin DF, Jaffe GJ, Maguire MG, Comparison of Age-related Macular Degeneration Treatments Trials (CATT) Research Group (2016) Outcomes in eyes with retinal angiomatous proliferation in the Comparison of Age-related Macular Degeneration Treatments Trials (CATT). *Ophthalmology* 123(3):609–616. <https://doi.org/10.1016/j.ophtha.2015.10.034>
- Gass JD (1994) Biomicroscopic and histopathologic considerations regarding the feasibility of surgical excision of subfoveal neovascular membranes. *Trans Am Ophthalmol Soc* 92:91–116
- Yannuzzi LA, Sorenson J, Spaide RF, Lipson B (1990) Idiopathic polypoidal choroidal vasculopathy (IPCV). *Retina* 10(1):1–8
- Dansingani KK, Gal-Or O, Sadda SR, Yannuzzi LA, Freund KB (2018) Understanding aneurysmal type 1 neovascularization (polypoidal choroidal vasculopathy): a lesson in the taxonomy of 'expanded spectra'—a review. *Clin Exp Ophthalmol* 46(2):189–200. <https://doi.org/10.1111/ceo.13114>
- Li M, Dolz-Marco R, Messinger JD, Sloan KR, Ferrara D, Curcio CA, Freund KB (2019) Clinicopathologic correlation of aneurysmal type 1 neovascularization in age-related macular degeneration. *Ophthalmol Retina* 3(2):99–111. <https://doi.org/10.1016/j.oret.2018.08.008>
- Slakter JS, Yannuzzi LA, Schneider U, Sorenson JA, Ciardella A, Guyer DR, Spaide RF, Freund KB, Orlock DA (2000) Retinal choroidal anastomoses and occult choroidal neovascularization in age-related macular degeneration. *Ophthalmology* 107(4):742–753. [https://doi.org/10.1016/s0161-6420\(00\)00009-9](https://doi.org/10.1016/s0161-6420(00)00009-9)
- Yannuzzi LA, Negrão S, Iida T, Carvalho C, Rodriguez-Coleman H, Slakter J, Freund KB, Sorenson J, Orlock D, Borodoker N (2001) Retinal angiomatous proliferation in age-related macular degeneration. *Retina* 21(5):416–434. <https://doi.org/10.1097/00006982-200110000-00003>
- Freund KB, Ho I-V, Barbazetto IA, Koizumi H, Laud K, Ferrara D, Matsumoto Y, Sorenson JA, Yannuzzi L (2008) Type 3 neovascularization: the expanded spectrum of retinal angiomatous proliferation. *Retina* 28(2):201–211. <https://doi.org/10.1097/IAE.0b013e3181669504>
- Jung JJ, Chen CY, Mrejen S, Gallego-Pinazo R, Xu L, Marsiglia M, Boddu S, Freund KB (2014) The incidence of neovascular subtypes in newly diagnosed neovascular age-related macular degeneration. *Am J Ophthalmol* 158(4):769–779.e2. <https://doi.org/10.1016/j.ajo.2014.07.006>
- Mrejen S, Jung JJ, Chen C, Patel SN, Gallego-Pinazo R, Yannuzzi N, Xu L, Marsiglia M, Boddu S, Freund KB (2015) Long-term visual outcomes for a treat and extend anti-vascular endothelial growth factor regimen in eyes with neovascular age-related macular degeneration. *J Clin Med* 4(7):1380–1402. <https://doi.org/10.3390/jcm4071380>
- Spaide RF, Jaffe GJ, Sarraf D, Freund KB, Sadda SR, Staurenghi G, Waheed NK, Chakravarthy U, Rosenfeld PJ, Holz FG, Souied EH, Cohen SY, Querques G, Ohno-Matsui K, Boyer D, Gaudric A, Blodi B, Baumal CR, Li X, Coscas GJ, Brucker A, Singerman L, Luthert P, Schmitz-Valckenberg S, Schmidt-Erfurth U, Grossniklaus HE, Wilson DJ, Guymer R, Yannuzzi LA, Chew EY, Csaky K, Monés JM, Pauleikhoff D, Tadayoni R, Fujimoto J (2020) Consensus nomenclature for reporting neovascular age-related macular degeneration data: Consensus on Neovascular Age-Related Macular Degeneration Nomenclature Study Group. *Ophthalmology* 127(5):616–636. <https://doi.org/10.1016/j.ophtha.2019.11.004>
- Busbee BG, Ho AC, Brown DM, Heier JS, Suñer IJ, Li Z, Rubio RG, Lai P, HARBOR Study Group (2013) Twelve-month efficacy and safety of 0.5 mg or 2.0 mg ranibizumab in patients with subfoveal neovascular age-related macular degeneration. *Ophthalmology* 120(5):1046–1056. <https://doi.org/10.1016/j.ophtha.2012.10.014>
- Ho AC, Busbee BG, Regillo CD, Wieland MR, Van Everen SA, Li Z, Rubio RG, Lai P, HARBOR Study Group (2014) Twenty-four-month efficacy and safety of 0.5 mg or 2.0 mg

- ranibizumab in patients with subfoveal neovascular age-related macular degeneration. *Ophthalmology* 121(11):2181–2192. <https://doi.org/10.1016/j.ophtha.2014.05.009>
24. Stewart MW (2015) Individualized treatment of neovascular age-related macular degeneration: what are patients gaining? Or losing? *J Clin Med* 4(5):1079–1101. <https://doi.org/10.3390/jcm4051079>
 25. Rosenfeld PJ, Brown DM, Heier JS, Boyer DS, Kaiser PK, Chung CY, Kim RY, MARINA Study Group (2006) Ranibizumab for neovascular age-related macular degeneration. *N Engl J Med* 355(14):1419–1431. <https://doi.org/10.1056/NEJMoa054481>
 26. Brown DM, Michels M, Kaiser PK, Heier JS, Sy JP, Ianchulev T, ANCHOR Study Group (2009) Ranibizumab versus verteporfin photodynamic therapy for neovascular age-related macular degeneration: two-year results of the ANCHOR study. *Ophthalmology* 116(1):57–65.e5. <https://doi.org/10.1016/j.ophtha.2008.10.018>
 27. Nakano Y, Kataoka K, Takeuchi J, Fujita A, Kaneko H, Shimizu H, Ito Y, Terasaki H (2019) Vascular maturity of type 1 and type 2 choroidal neovascularization evaluated by optical coherence tomography angiography. *PLoS One* 14(4):e0216304. <https://doi.org/10.1371/journal.pone.0216304>
 28. Chae B, Jung JJ, Mrejen S, Gallego-Pinazo R, Yannuzzi NA, Patel SN, Chen CY, Marsiglia M, Boddur S, Freund KB (2015) Baseline predictors for good versus poor visual outcomes in the treatment of neovascular age-related macular degeneration with intravitreal anti-VEGF therapy. *Invest Ophthalmol Vis Sci* 56(9):5040–5047. <https://doi.org/10.1167/iovs.15-16494>
 29. Grossniklaus HE, Green WR (2004) Choroidal neovascularization. *Am J Ophthalmol* 137(3):496–503. <https://doi.org/10.1016/j.ajo.2003.09.042>
 30. Sadda SR, Guymer R, Monés JM, Tufail A, Jaffe GJ (2020) Anti-vascular endothelial growth factor use and atrophy in neovascular age-related macular degeneration: systematic literature review and expert opinion. *Ophthalmology* 127(5):648–659. <https://doi.org/10.1016/j.ophtha.2019.11.010>
 31. Pfau M, Möller PT, Künzel SH, von der Emde L, Lindner M, Thiele S, Dysli C, Nadal J, Schmid M, Schmitz-Valckenberg S, Holz FG, Fleckenstein M (2020) Type 1 choroidal neovascularization is associated with reduced localized progression of atrophy in age-related macular degeneration. *Ophthalmol Retina* 4(3):238–248. <https://doi.org/10.1016/j.oret.2019.09.016>
 32. Daniel E, Toth CA, Grunwald JE, Jaffe GJ, Martin DF, Fine SL, Huang J, Ying G-s, Hagstrom SA, Winter K, Maguire MG, Comparison of Age-related Macular Degeneration Treatments Trials Research Group (2014) Risk of scar in the Comparison of Age-related Macular Degeneration Treatments Trials. *Ophthalmology* 121(3):656–666. <https://doi.org/10.1016/j.ophtha.2013.10.019>
 33. Xu L, Mrejen S, Jung JJ, Gallego-Pinazo R, Thompson D, Marsiglia M, Freund KB (2015) Geographic atrophy in patients receiving anti-vascular endothelial growth factor for neovascular age-related macular degeneration. *Retina* 35(2):176–186. <https://doi.org/10.1097/IAE.0000000000000374>
 34. Cho HJ, Park SM, Kim J, Nah SK, Lee J, Lee DW, Kim JW (2021) Progression of macular atrophy in patients undergoing anti-vascular endothelial growth factor therapy for neovascular age-related macular degeneration. *Acta Ophthalmol* 99:e540–e546. <https://doi.org/10.1111/aos.14631>
 35. Sharma S, Toth CA, Daniel E, Grunwald JE, Maguire MG, Ying G-s, Huang J, Martin DF, Jaffe GJ, Comparison of Age-related Macular Degeneration Treatments Trials Research Group (2016) Macular morphology and visual acuity in the second year of the Comparison of Age-related Macular Degeneration Treatments Trials. *Ophthalmology* 123(4):865–875. <https://doi.org/10.1016/j.ophtha.2015.12.002>
 36. Grunwald JE, Pistilli M, Daniel E, Ying GS, Pan W, Jaffe GJ, Toth CA, Hagstrom SA, Maguire MG, Martin DF, Comparison of Age-related Macular Degeneration Treatments Trials Research Group (2017) Incidence and growth of geographic atrophy during 5 years of Comparison of Age-Related Macular Degeneration Treatments Trials. *Ophthalmology* 124(1):97–104. <https://doi.org/10.1016/j.ophtha.2016.09.012>
 37. Sadda SR, Tuomi LL, Ding B, Fung AE, Hopkins JJ (2018) Macular atrophy in the HARBOR study for neovascular age-related macular degeneration. *Ophthalmology* 125(6):878–886. <https://doi.org/10.1016/j.ophtha.2017.12.026>
 38. Bailey C, Scott LJ, Rogers CA, Reeves BC, Hamill B, Peto T, Chakravarthy U, Harding SP, Writing Committee for the IVAN Study Group (2019) Intralesional macular atrophy in anti-vascular endothelial growth factor therapy for age-related macular degeneration in the IVAN trial. *Ophthalmology* 126(1):75–86. <https://doi.org/10.1016/j.ophtha.2018.07.013>
 39. Guymer RH, Markey CM, McAllister IL, Gillies MC, Hunyor AP, Arnold JJ, FLUID Investigators (2019) Tolerating subretinal fluid in neovascular age-related macular degeneration treated with ranibizumab using a treat-and-extend regimen: FLUID study 24-month results. *Ophthalmology* 126(5):723–734. <https://doi.org/10.1016/j.ophtha.2018.11.025>
 40. Ciulla TA, Hussain RM, Pollack JS, Williams DF (2020) Visual acuity outcomes and anti-vascular endothelial growth factor therapy intensity in neovascular age-related macular degeneration patients: a real-world analysis of 49 485 eyes. *Ophthalmol Retina* 4(1):19–30. <https://doi.org/10.1016/j.oret.2019.05.017>
 41. Arruabarrena C, Toro MD, Onen M, Malyugin BE, Rejdak R, Tognetto D, Zweifel S, Giglio R, Teus MA (2021) Impact on visual acuity in neovascular age-related macular degeneration (nAMD) in Europe due to COVID-19 pandemic lockdown. *J Clin Med* 10(15):3281. <https://doi.org/10.3390/jcm10153281>
 42. Breazzano MP, Nair AA, Arevalo JF, Barakat MR, Berrocal AM, Chang JS, Chen A, Elliott D, Garg SJ, Ghadiali Q, Gong D, Grewal DS, Handa JT, Henderson M, Leiderman YI, Leng T, Mannina A, Mendel TA, Mustafi D, de Koo LCO, Patel SN, Patel TP, Prenner J, Richards P, Singh RP, Wykoff CC, Yannuzzi NA, Yu H, Modi YS, Chang S (2021) Frequency of urgent or emergent vitreoretinal surgical procedures in the United States during the COVID-19 pandemic. *JAMA Ophthalmol* 139(4):456–463. <https://doi.org/10.1001/jamaophthalmol.2021.0036>
 43. Martin DF, Maguire MG, Fine SL, Ying G-s, Jaffe GJ, Grunwald JE, Toth C, Redford M, Ferris FL 3rd, Comparison of Age-related Macular Degeneration Treatments Trials (CATT) Research Group (2012) Ranibizumab and bevacizumab for treatment of neovascular age-related macular degeneration: two-year results. *Ophthalmology* 119(7):1388–1398. <https://doi.org/10.1016/j.ophtha.2012.03.053>
 44. Singer MA, Awh CC, Sadda S, Freeman WR, Antoszyk AN, Wong P, Tuomi L (2012) HORIZON: an open-label extension trial of ranibizumab for choroidal neovascularization secondary to age-related macular degeneration. *Ophthalmology* 119(6):1175–1183. <https://doi.org/10.1016/j.ophtha.2011.12.016>
 45. Gillies MC, Campain A, Barthelmes D, Simpson JM, Arnold JJ, Guymer RH, McAllister IL, Essex RW, Morlet N, Hunyor AP, Fight Retinal Blindness Study Group (2015) Long-term outcomes of treatment of neovascular age-related macular degeneration: data from an observational study. *Ophthalmology* 122(9):1837–1845. <https://doi.org/10.1016/j.ophtha.2015.05.010>
 46. Spooner KL, Fraser-Bell S, Cozzi M, Staurenghi G, Invernizzi A, Monteduro D, Munk MR, Hong T, Chang AA (2020) Macular atrophy incidence and progression in eyes with neovascular age-related macular degeneration treated with vascular endothelial growth factor inhibitors using a treat-and-extend or a pro re nata

- regimen: four-year results of the MANEX study. *Ophthalmology* 127(12):1663–1673. <https://doi.org/10.1016/j.ophtha.2020.06.019>
47. Nagiel A, Sarraf D, Sadda SR, Spaide RF, Jung JJ, Bhavsar KV, Ameri H, Querques G, Freund KB (2015) Type 3 neovascularization: evolution, association with pigment epithelial detachment, and treatment response as revealed by spectral domain optical coherence tomography. *Retina* 35(4):638–647. <https://doi.org/10.1097/IAE.0000000000000488>
 48. Lin T, Dans KC, Muftuoglu IK, Meshi A, Amador-Patarroyo MJ, Cheng L, Freeman WR (2020) Factors associated with extended remission in neovascular age-related macular degeneration on pro re nata treatment protocol. *Br J Ophthalmol* 104(1):58–63. <https://doi.org/10.1136/bjophthalmol-2018-313447>
 49. Kwan AS, Barry C, McAllister IL, Constable I (2006) Fluorescein angiography and adverse drug reactions revisited: the Lions Eye experience. *Clin Exp Ophthalmol* 34(1):33–38. <https://doi.org/10.1111/j.1442-9071.2006.01136.x>
 50. Wilde C, Patel M, Lakshmanan A, Amankwah R, Dhar-Munshi S, Amoaku W (2015) The diagnostic accuracy of spectral-domain optical coherence tomography for neovascular age-related macular degeneration: a comparison with fundus fluorescein angiography. *Eye (Lond)* 29(5):602–610. <https://doi.org/10.1038/eye.2015.44>
 51. Lavinsky F, Lavinsky D (2016) Novel perspectives on swept-source optical coherence tomography. *Int J Retina Vitreous* 2:25. <https://doi.org/10.1186/s40942-016-0050-y>
 52. Castillo MM, Mowatt G, Lois N, Elders A, Fraser C, Amoaku W, Burr J, Lotery A, Ramsay C, Azuara-Blanco A (2014) Optical coherence tomography for the diagnosis of neovascular age-related macular degeneration: a systematic review. *Eye (Lond)* 28(12):1399–1406. <https://doi.org/10.1038/eye.2014.214>
 53. Castillo MM, Mowatt G, Elders A, Lois N, Fraser C, Hernández R, Amoaku W, Burr JM, Lotery A, Ramsay CR (2015) Optical coherence tomography for the monitoring of neovascular age-related macular degeneration: a systematic review. *Ophthalmology* 122(2):399–406. <https://doi.org/10.1016/j.ophtha.2014.07.055>
 54. Dolz-Marco R, Phasukkijwatana N, Sarraf D, Freund KB (2017) Regression of type 2 neovascularization into a type 1 pattern after intravitreal anti-vascular endothelial growth factor therapy for neovascular age-related macular degeneration. *Retina* 37(2):222–233. <https://doi.org/10.1097/iae.0000000000001279>

Publisher's note Springer Nature remains neutral with regard to jurisdictional claims in published maps and institutional affiliations.