

# Transmural coil embolization—alternative technique for management of arterial perforation during subintimal angioplasty

Karthikeyan Damodharan, Amman Bolia<sup>1</sup>

Department of Diagnostic Radiology, Singapore General Hospital, Singapore, <sup>1</sup>Department of Radiology, University Hospitals of Leicester, Leicester, UK

**Correspondence:** Dr. Karthikeyan Damodharan, Department of Diagnostic Radiology, Singapore General Hospital, Singapore - 169608. E-mail: drdkarthik@hotmail.com

## Abstract

Subintimal angioplasty of lower limb arterial occlusion carries a relatively higher risk of vessel perforation compared to transluminal angioplasty. Vessel perforation is a potentially life threatening complication which requires prompt recognition and management. They are usually managed by endovascular techniques such as low-pressure balloon tamponade, covered stents, and coil embolization of the ruptured artery. We describe a technique of treating vessel perforation following balloon angioplasty. Patient developed a large perforation of the proximal superficial femoral artery (SFA) after balloon inflation during subintimal angioplasty of complete SFA occlusion. Following failure of balloon tamponade in sealing the perforation, we successfully treated it by deploying an embolization coil at the site of perforation through the vessel wall followed by balloon tamponade. Our technique could be a useful relatively inexpensive alternative treatment option in the management of vessel perforation compared to covered stents.

**Key words:** Perforation; subintimal angioplasty; transmural coil embolisation

## Background

Percutaneous balloon angioplasty carries a low risk of serious complications; one of them is vessel perforation.<sup>[1]</sup> Subintimal angioplasty (SIA) of occluded segments has a slightly higher risk of perforation of 5–8%, compared to percutaneous transluminal angioplasty (PTA).<sup>[2]</sup> Arterial ruptures following balloon angioplasty are usually managed by low-pressure balloon tamponade, covered stents, or embolization of the ruptured vessel if it could be sacrificed. We report an alternative technique to manage

a perforation subsequent to balloon inflation during SIA, which allowed us to preserve the subintimal channel and complete the procedure.

## Procedure

A 62-year-old male with a longstanding history of peripheral vascular disease and two previous PTA's presented with rest pain in left foot. He was an ex smoker, type 2 diabetic, and had Crohn's disease, for which he was

### Access this article online

#### Quick Response Code:



**Website:**  
www.ijri.org

**DOI:**  
10.4103/0971-3026.190422

This is an open access article distributed under the terms of the Creative Commons Attribution-NonCommercial-ShareAlike 3.0 License, which allows others to remix, tweak, and build upon the work non-commercially, as long as the author is credited and the new creations are licensed under the identical terms.

**For reprints contact:** reprints@medknow.com

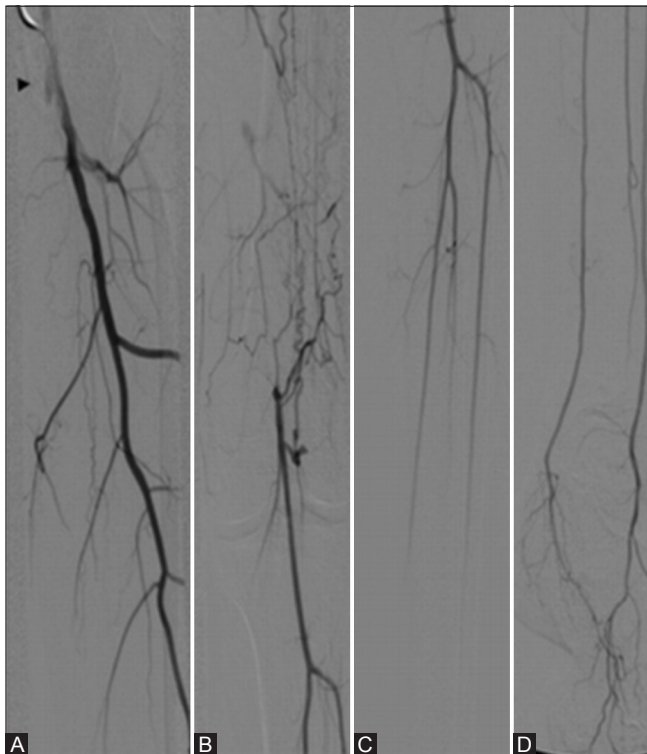
**Cite this article as:** Damodharan K, Bolia A. Transmural coil embolization—alternative technique for management of arterial perforation during subintimal angioplasty. Indian J Radiol Imaging 2016;26:360-3.

on long-term oral steroids. The patient was deemed high risk for surgical bypass by vascular surgeons due to his poor background pulmonary function status. Hence, he was referred for endovascular revascularization of his left lower limb arteries. Patient consented for the procedure after the risks of the procedure including vessel rupture were explained to him and was admitted for an elective left leg angioplasty.

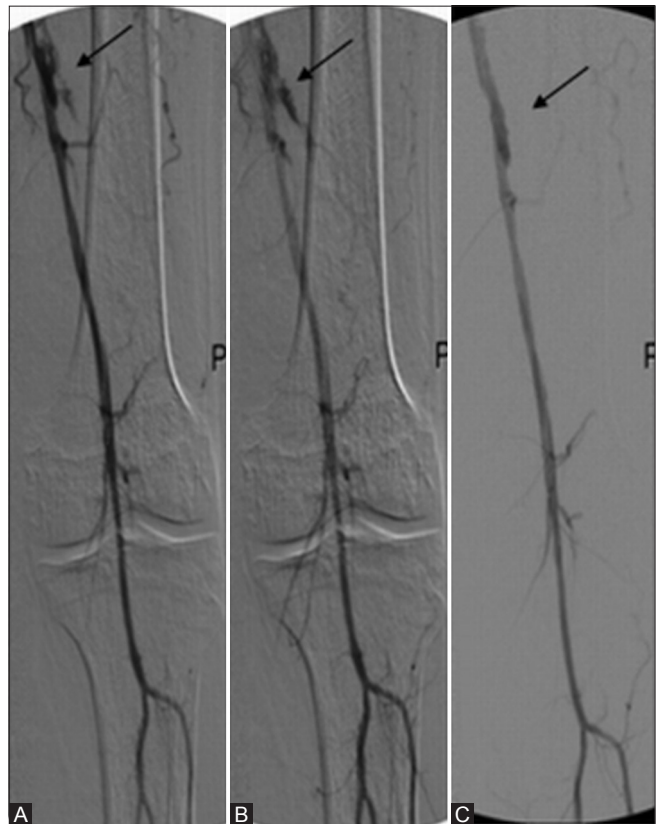
An antegrade left transfemoral angiogram demonstrated a complete left superficial femoral artery (SFA) occlusion from its origin with diffuse arterial wall calcification. The popliteal artery was noted to reconstitute via collaterals from the profunda and a good three vessel runoff in the calf was present [Figure 1A–D]. 3000 international units (IU) of heparin was given intra-arterially at the beginning of the procedure as per our standard local protocol. Initial attempts to cross the occlusion via transluminal approach were unsuccessful probably due to the chronic calcific occlusion extending from the SFA origin. The SFA occlusion was crossed via antegrade subintimal approach using a 035" hydrophilic wire (Terumo, Japan) supported by a 5F Bern™ catheter (Cordis, USA). Successful re-entry into the true lumen of the proximal popliteal artery was confirmed with contrast injection. Our standard practice is to attempt crossing of the lesion preferably via an antegrade approach as the first option before moving on to a retrograde approach. Angioplasty was performed using

a 5 mm × 4 cm balloon (Admiral Xtreme™—MEDTRONIC, USA). Initial post-angioplasty run showed significant residual stenoses and a small distal SFA perforation. This perforation was successfully treated using the 5 mm balloon inflated intraluminally at the level of the perforation for 120 s [Figure 2]. The residual stenoses were treated with a 6 mm × 4 cm shaft balloon (Admiral Xtreme™—MEDTRONIC, USA), following which a large perforation was noted in the proximal SFA [Figure 3A and B], which could not be resolved by low-pressure balloon tamponade despite prolonged balloon inflation up to 5 min. The balloon catheter was exchanged for a 4 Fr Bernstein catheter over a 035" guide wire and positioned with its tip through the perforation [Figure 3C]. Using this catheter, a 5 mm × 50 mm (MReye™ Embolization coil—COOK Medical, USA) coil was deployed at the site of the perforation, which was pushed through the vessel wall, to just outside the adventitia. Following this, the 6 mm balloon was inflated at low pressure for a few seconds at this site [Figure 3C and D] to reduce the chance of coil migration and aid the sealing of the perforation. Final angiogram showed patent SFA with no leak and brisk distal runoff [Figure 4].

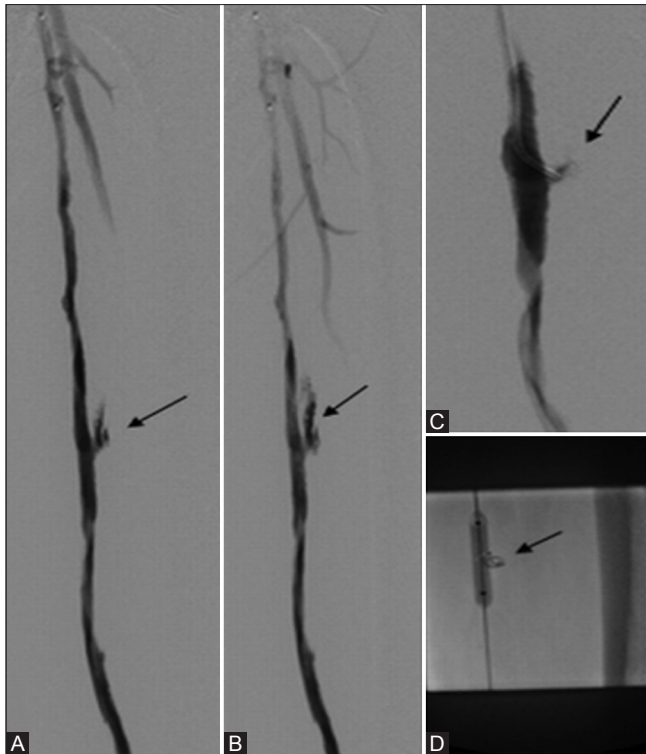Patient made an uneventful recovery and reported significant symptomatic relief post procedure. The Ankle Brachial Pressure Index (ABPI) improved from 0.62



**Figure 1 (A-D):** (A) Flush superficial femoral artery (SFA) occlusion at the origin. (B) Reconstitution of the distal SFA via collaterals. (C, D) Good three vessel distal runoff



**Figure 2 (A-C):** (A, B) Distal superficial femoral artery perforation. (C) Treated successfully with balloon tamponade



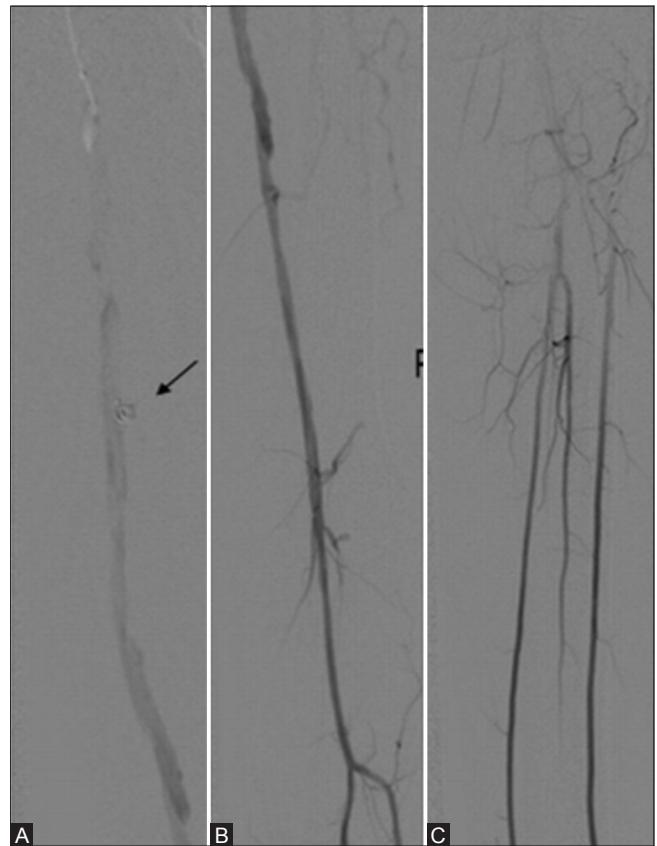
**Figure 3 (A-D):** (A, B) Proximal superficial femoral artery perforation with brisk extravasation. (C) Shows the tip of Bernstein catheter at the site of perforation. (D) Shows balloon tamponade post coil deployment at site of perforation

(pre-procedure) to 0.83 at 24 h post-procedure. Patient remained rest pain free at 3 months outpatient follow up and a Duplex scan confirmed patent left SFA, with the coil well-implanted within the wall at the original deployment site.

### Discussion

The complication rates of SIA vary between 8 and 17% and most of them are minor.<sup>[5]</sup> SIA of occluded vessel segments is associated with an overall risk of perforation of 5–8%, which is relatively higher compared to transluminal angioplasty.<sup>[2]</sup> The risk of perforation is increased in heavily calcified vessels, old age group, and in smokers.<sup>[2,3]</sup> It is also increased in patients who are on steroids, first described by Lois *et al.*,<sup>[4]</sup> which was probably one of the factors that led to two perforations in our patient, despite inflation of appropriate size balloons.

Management of the perforation is based on the radiologist's evaluation of its severity based on the radiological evidence of the briskness of contrast extravasation because it is difficult to ascertain the volume of blood loss.<sup>[2,3]</sup> The size of the vessel involved and the patient's clinical status is also likely to influence the management. However, the perforations usually do not compromise the clinical outcome or preclude



**Figure 4 (A-C):** (A) Patent SFA with sealed proximal perforation - Arrow showing the site of perforation with the implanted transmural coil. (B,C) Patent popliteal and calf runoff

continuing with the procedure in most patients because most of them are self-limiting or can be resolved by an endovascular approach.<sup>[3]</sup>

Guide wire perforations are usually small and resolve spontaneously. Creating a new dissection plane proximal to the perforated segment, to divert the blood flow through the new channel as well as to exclude the perforation, can be used to treat a large perforation during subintimal dissection. A large perforation with brisk contrast leak may make it difficult to create a new dissection flap, and in such cases coil embolization of the vessel proximal to the perforation could be performed. In such cases, patient may be brought back few weeks later for a repeat attempt at subintimal recanalization.<sup>[2]</sup>

Perforations following balloon inflation are usually large and are initially treated by balloon tamponade of the perforated segment at low pressures for up to 3 min, which can be repeated a few times. Balloon tamponade essentially causes temporary occlusion of blood flow through the perforated segment and thereby aids thrombus formation at the perforation site, which closes the perforation.

In our patient, the balloon tamponade was unsuccessful. The conventional practice in this situation is stent

graft deployment across the perforation to exclude the perforation and also preserve the recanalized lumen. However we find that the long-term outcomes of covered stents in this segment are not favorable in our experience,<sup>[2]</sup> and hence we tend to use it as our last resort. We do maintain a stock of “bail out” stent grafts for use in iliac and femoral arteries, if all the other methods are unsuccessful in sealing the perforation. The stent graft option can be expensive and may be limited by the immediate availability of appropriate sized stent grafts, especially the smaller diameter stent grafts required in the below knee arterial perforations. The alternative strategy of coil embolization of the recanalized vessel proximal to the site of perforation would have precluded further treatment for this patient. Hence, a coil was deployed through the perforation, which probably served as a framework to accelerate clot formation. This, in synergy with the subsequent balloon tamponade, sealed the large perforation.

This technique allowed us to preserve the subintimal channel and complete the procedure successfully at the same sitting. Hence, we avoided the inherent risks of a repeat procedure. This technique may be a useful treatment

option for the management of arterial perforations during arterial angioplasty.

#### Financial support and sponsorship

Nil.

#### Conflicts of interest

There are no conflicts of interest.

#### References

1. Belli AM, Cumberland DC, Knox AM, Procter AE, Welsh CL. The complication rate of percutaneous peripheral balloon angioplasty. *Clin Radiol* 1990;41:380-3.
2. Bolia A. Subintimal angioplasty, the way forward. *Acta Chir Belg* 2004;104:547-54.
3. Hayes PD, Chokkalingam A, Jones R, Bell PR, Fishwick G, Bolia A, *et al.* Arterial perforation during infrainguinal lower limb angioplasty does not worsen outcome: Results from 1409 patients. *J Endovasc Ther* 2002;9:422-7.
4. Lois JF, Takiff H, Schechter MS, Gomes AS, Machleder HI. Vessel rupture by balloon catheters complicating chronic steroid therapy. *AJR Am J Roentgenol* 1985;144:1073-4.
5. Met R, Van Lienden KP, Koelemay MJ, Bipat S, Legemate DA, Reekers JA. Subintimal angioplasty for peripheral arterial occlusive disease: A systematic review. *Cardiovasc Intervent Radiol*. 2008;31:687-97.