



Contents lists available at ScienceDirect

AACE Clinical Case Reports

journal homepage: www.aaceclinicalcasereports.com

Case Report

Coexistence of Cushing Disease With a Solitary Adrenocorticotrophic Hormone-Dependent Adrenal Adenoma

Mohamed K.M. Shakir, MD^{1,2}, Ismail C. Ebrahim^{1,2}, Andrew Spiro, MD^{1,2}, Vinh Q. Mai, DO^{1,2}, Thanh D. Hoang, DO^{1,2,*}¹ Division of Endocrinology, Department of Medicine, Walter Reed National Military Medical Center, Bethesda, Maryland² Division of Endocrinology, Department of Medicine, Uniformed Services University of the Health Sciences, Bethesda, Maryland

ARTICLE INFO

Article history:

Available online 8 December 2020

Key words:

Cushing disease
adrenal adenoma
coexistence
ACTH dependent adrenal adenoma

ABSTRACT

Objective: We report a 49-year-old woman who had minimal features of Cushing syndrome and an incidentally discovered adrenal adenoma. She was subsequently diagnosed with pituitary-dependent Cushing syndrome.**Methods:** Laboratory and imaging studies including serum cortisol, plasma adrenocorticotrophic hormone (ACTH), high dose dexamethasone test, corticotropin-releasing hormone test, computed tomography (CT) scan, and magnetic resonance imaging were performed.**Results:** A 49-year-old woman was admitted for urosepsis. An abdominal CT scan performed during the urosepsis workup showed a 2.7-cm right adrenal adenoma. She denied any abdominal striae or other symptoms. Physical examination showed normal vital signs, minimal facial fullness without central obesity, and striae. Laboratory results were as follows: 24-hour-urine cortisol 294 µg (reference 4.0–50.0), midnight serum cortisol 23.0 µg/dL (reference < 7.5), and plasma ACTH level 39 pg/mL (reference 5–27). A corticotropin-releasing hormone stimulation test showed >20% rise in serum cortisol and >35% rise in ACTH levels. A pituitary magnetic resonance image showed a 5 mm pituitary lesion. The patient underwent transsphenoidal pituitary surgery, which confirmed an ACTH-secreting lesion. Postoperatively, she required hydrocortisone replacement for the next 10 months. A follow-up adrenal CT performed 6 months later showed a decrease in the size of the adrenal adenoma (1.8 cm).**Conclusion:** This case highlights the importance of recognizing the coexistence of ACTH-dependent Cushing disease with an adrenal adenoma and partial ACTH dependency of the adrenal adenoma.Published by Elsevier Inc. on behalf of the AACE. This is an open access article under the CC BY-NC-ND license (<http://creativecommons.org/licenses/by-nc-nd/4.0/>).

Introduction

Cushing syndrome resulting from either a pituitary or adrenal lesion is rare, with a prevalence of 10 to 15 per million people. Cushing disease resulting from excessive secretion of adrenocorticotrophic hormone (ACTH) by the pituitary gland accounts for approximately 65% of the cases of Cushing syndrome. In another 30% of patients, Cushing syndrome develops independently of ACTH, and the majority of these patients have an adrenal adenoma or carcinoma.^{1–3} Other causes of Cushing syndrome include primary hyperplasia of the

adrenal gland and ectopic ACTH production.⁴ The exact mechanism by which the adrenal hyperplasia develops is not clear. It has been proposed that it begins as a pituitary ACTH-dependent hyperfunction and that, secondarily, adrenal nodules develop, which become autonomous and eventually suppress the abnormally elevated pituitary secretion. We report a 49-year-old woman who had minimal features of Cushing syndrome and an incidentally discovered adrenal adenoma. She was subsequently diagnosed with a pituitary-dependent Cushing syndrome. Following transsphenoidal surgery, there was a shrinkage of the adrenal adenoma, thus indicating at least partial ACTH dependency for the adenoma growth.

Abbreviations: ACTH, adrenocorticotrophic hormone; ACTH-R, ACTH receptors; BIPSS, bilateral inferior petrosal sinus sampling test; MRI, magnetic resonance imaging scan.

* Address correspondence and reprint requests to Dr. Thanh D. Hoang, Division of Endocrinology, Walter Reed National Military Medical Center, 8901 Wisconsin Avenue, Bethesda, MD 20889.

E-mail address: thanh.d.hoang.mil@mail.mil (T.D. Hoang).

Case Report

All laboratory tests were performed either by Walter Reed National Military Medical Center or Lab Corp. Corticotropin-releasing hormone stimulation test (Acthrel; Ferring Pharmaceutical) was performed as described previously.⁵

<https://doi.org/10.1016/j.aace.2020.11.027>

2376-0605/Published by Elsevier Inc. on behalf of the AACE. This is an open access article under the CC BY-NC-ND license (<http://creativecommons.org/licenses/by-nc-nd/4.0/>).

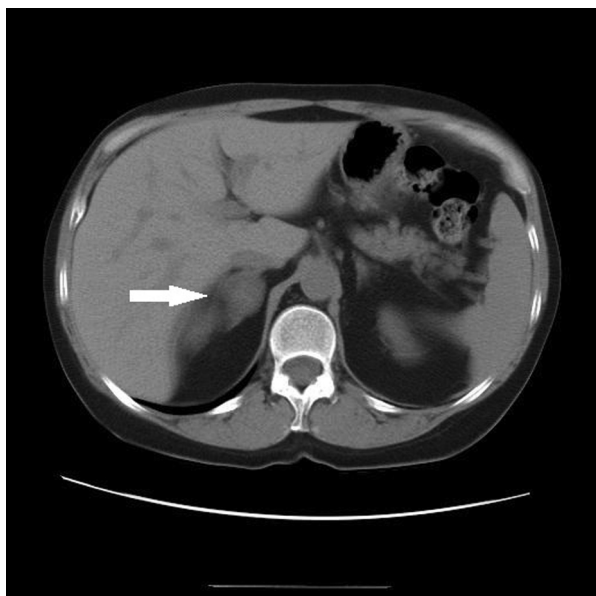


Fig. 1. CT scan showing a 2.7 cm right adrenal adenoma (arrow).

A 49-year-old woman was admitted for urosepsis. She noted decreased exercise tolerance (especially on climbing stairs) for several months. An abdominal computed tomography scan performed during the urosepsis workup showed a 2.7-cm right adrenal adenoma (Fig. 1), with 67% wash out. She denied any abdominal striae, skin bruising, or depression. However, she had gained 8 pounds in a period of 3 months. Past history was significant for psoriasis and hypertension. Her current medications included methotrexate, remicade, and lisinopril. Physical examination showed normal vital signs and minimal facial fullness without central obesity, striae, or proximal muscle weakness. Laboratory results showed normal complete blood count and serum electrolytes, 24-hour-urine cortisol 294 µg (reference 4.0-50.0), and midnight serum cortisol 23.0 µg/dL (reference < 7.5), suggesting Cushing syndrome. The plasma aldosterone/renin did not support hyperaldosteronism. Serum metanephrine levels were normal. Following an overnight 8-mg dexamethasone administration, 8 AM serum cortisol was suppressed by 40% compared to baseline serum cortisol level. Morning serum ACTH was 39 pg/mL (reference 5-27) (Table). A corticotropin-releasing hormone test showed >20% rise in serum cortisol and >35% rise in ACTH levels. A pituitary magnetic resonance imaging (MRI) showed a 5 mm pituitary lesion (Fig. 2). She underwent transsphenoidal pituitary surgery, which confirmed an ACTH-secreting lesion. Postoperative serum cortisol was <2 µg/dL, and she required hydrocortisone replacement for the

next 10 months. A follow-up adrenal computed tomography done 6 months later showed a decrease in the size of adrenal adenoma of 1.8 cm (Fig. 3), indicating that the adrenal adenoma may have been partially dependent on ACTH for its growth. The patient had several normal midnight salivary cortisol levels during follow-up.

Discussion

Establishing the diagnosis of Cushing syndrome is often delayed because few of the symptoms or signs are specific in a significant proportion of patients. Depending on the duration and intensity of excess glucocorticoid production, the manifestations may vary from subclinical to overt syndrome. Simultaneous development and increasing severity of several of the clinical features of Cushing syndrome are important clues to its presence.¹⁻⁴ However, in our patient the only clinical feature was fullness of the face and difficulty in climbing stair cases. Although the facial fullness was a subtle finding, she had no other symptoms or signs except for an incidentally found adrenal lesion. She had a history of hypertension, and this was well controlled with 1 medication. We have observed that the clinical features of Cushing syndrome are often minimal in physically active military patients (unpublished data). It is possible that our patient, a professional physical trainer, had minimal manifestation because of the regularly paced intense physical exercise. Additionally, our patient had gained only 8 pounds when she was diagnosed with Cushing syndrome, and following pituitary surgery she lost 4 pounds. Interestingly, she did not observe any remission in psoriatic arthritis when she developed Cushing syndrome.

Patients presenting with adrenal incidentalomas require detailed laboratory investigation to rule out hormonal hypersecretion.⁶ Pheochromocytoma and primary hyperaldosteronism were ruled out in our patient; however, an overnight 1-mg dexamethasone test revealed nonsuppressible serum cortisol. Several 24-hour urine free-cortisol levels were also elevated, thus suggesting a diagnosis of Cushing syndrome. However, a follow-up 8 mg overnight dexamethasone suppression test resulted in a 40% suppression of serum cortisol. Generally, a 50% to 80% suppression following high dose dexamethasone administration occurs in Cushing disease. Several drugs affecting the metabolism of dexamethasone affect the dexamethasone suppression test;⁷ however, our patient was not taking any of these drugs. A plasma ACTH level in our patient was modestly elevated, suggesting a diagnosis of Cushing disease. A plasma ACTH level of 5 to 20 pg/mL or a modestly elevated plasma ACTH level in a patient with Cushing syndrome may indicate that cortisol secretion is ACTH-dependent.⁸ Patients with a bronchial carcinoid tumor and ectopic Cushing syndrome occasionally have modestly elevated plasma ACTH levels and additionally may even demonstrate suppressibility of serum cortisol following high dose dexamethasone administration.^{9,10}

Table
Laboratory Tests

Laboratory tests	Results	Reference values
1 mg overnight dexamethasone suppression		
Serum cortisol (µg/dL)	13.6	<1.8
Serum dexamethasone (ng/dL)	280	180-550
24-hour urine cortisol (µg)	294	4.0-50
8 AM plasma ACTH (pg/mL)	39.4	5-27
Midnight serum cortisol (pg/mL)	12.3	5-10
Serum DHEAS (µg/dL)	262	35-256
8 mg overnight dexamethasone suppression	AM serum cortisol suppressed by 40%	50%-80% or greater suppression indicates Cushing disease
CRH stimulation test	Increase of serum cortisol 41% and plasma ACTH 50%	Increase of serum cortisol >20% and plasma ACTH >35% indicate Cushing disease

Abbreviations: ACTH = adrenocorticotrophic hormone; CRH = corticotropin-releasing hormone; DHEAS = dehydroepiandrosterone sulfate.

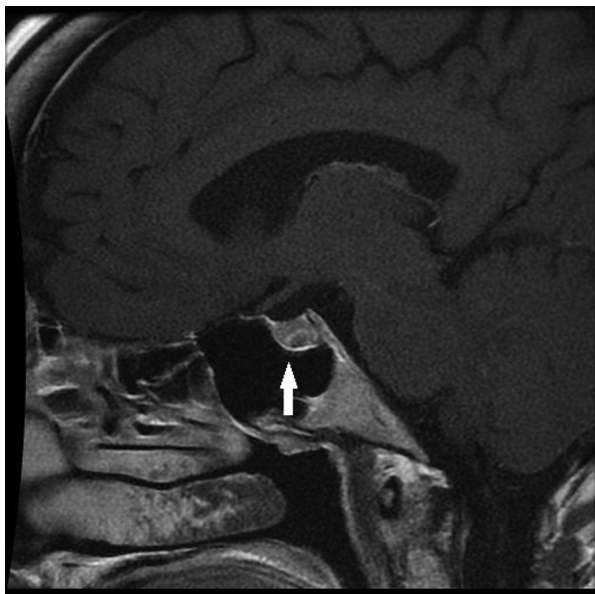


Fig. 2. Pituitary MRI showing a 5 mm pituitary lesion (arrow).

In our patient, a corticotropin-releasing hormone stimulation test also supported a diagnosis of Cushing disease and an MRI of the pituitary gland showed a 5-mm pituitary lesion. It is interesting to note that there is a positive correlation between plasma ACTH values and the size of pituitary tumors in patients with Cushing disease.¹¹ Woo et al¹² reported that ACTH-secreting pituitary macroadenomas had much higher ACTH levels, 136 ± 33 pg/L versus 45 ± 4 pg/L in microadenomas. Thus, in our patient a plasma ACTH level of 39 pg/mL was consistent with a microadenoma.

Although our patient had only subtle clinical features of Cushing syndrome, the laboratory tests supported a diagnosis of Cushing disease. Additionally, an MRI of the pituitary showed a 5-mm left-sided pituitary tumor. Generally, in patients with a pituitary tumor >6 mm in size, surgery can be performed without a bilateral

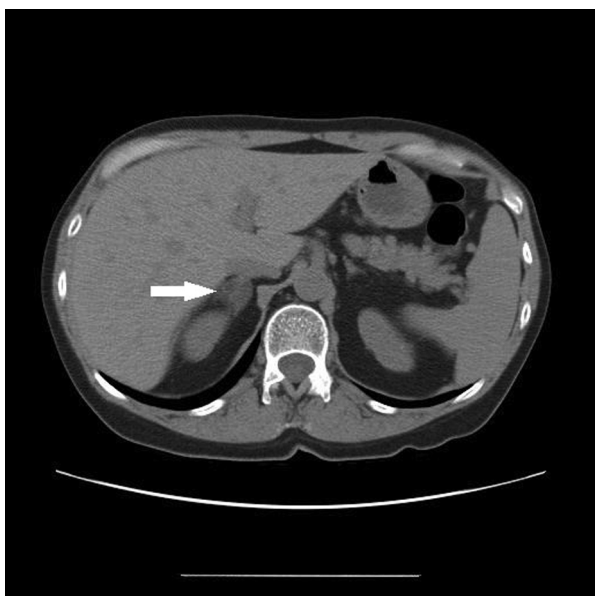


Fig. 3. Follow up CT showing a decrease in the size of adrenal adenoma of 1.8 cm (arrow).

inferior petrosal sinus sampling test (BIPSS). However, it is to be noted that the BIPSS test has several draw backs.¹³ Our patient underwent transsphenoidal surgery without BIPSS and the pituitary tumor stained positive for ACTH and the patient remained adrenal insufficient for approximately 10 months, thus further supporting the diagnosis of Cushing disease.

Abs et al¹⁴ reported a case series of 3 patients with Cushing disease with bilateral macronodular adrenal hyperplasia, presenting initially as an adrenal macronodule. ⁷⁵Se cholesterol scintigraphy showed bilateral radionuclide uptake, although mostly localized over the macronodule, and this was consistent with diffuse hyperplasia of both adrenal glands with formation of a single dominant macronodule. Interestingly, 2 of the nodules developed shrinkage after removal of the pituitary adenoma. These investigators suggested that the macronodule may possibly represent an evolutionary stage of diffuse adrenal hyperplasia to the autonomous adrenal nodule after prolonged ACTH stimulation. In 1986, Leiba et al¹⁵ reported a case of Cushing disease coexisting with a single adenoma of the adrenal cortex, and this patient was treated by surgical resection of the adrenal adenoma followed by pituitary irradiation. In contrast, our patient only underwent pituitary surgery. Schteinhart and Tsao¹⁶ reported a 45-year-old woman with Cushing syndrome. She had elevated urine free-cortisol and plasma ACTH levels and a right adrenal tumor. These authors concluded that the case represented a transition between pituitary ACTH-dependent bilateral adrenocortical hyperfunction and solitary adrenal adenoma.

Kobayashi et al¹⁷ reported a 67-year-old woman with acromegaly with subclinical Cushing disease and a left adrenal adenoma. Most previously reported cases of pituitary adenomas coexisting with adrenal adenoma are seen in patients with multiple endocrine neoplasia syndrome.¹⁸ There is also a reported case of pheochromocytoma coexisting with pituitary adenoma.¹⁹ Our case has several similarities to these previously reported cases. However, in our patient, the uninvolved part of the affected adrenal gland appeared normal on radiological imaging. Additionally, the contralateral adrenal gland also appeared normal. These findings suggest that the adrenal incidentaloma seen in our patient was ACTH-dependent. The reduction in the size of the adrenal tumor after the removal of the ACTH-secreting pituitary adenoma also suggests a possible ACTH dependency for its growth.

The actions of ACTH are mediated by specific membrane receptors (ACTH-Rs) in the adrenocortical cells. Mutations of ACTH-R genes have been reported. It has been suggested that deletion of the ACTH-R gene may be involved in some adrenocortical tumors, contributing to cellular dedifferentiation and tumor formation.^{20,21} Additionally, this may also explain the variable responses to ACTH stimulation in these adenomas. It is also not clear why adenoma was seen in 1 adrenal gland in our patient, although it is possible that some of the adrenocortical cells only may have the aberrant ACTH-R.

Conclusion

In conclusion, it is important to search for a pituitary or ectopic source of ACTH in a patient with an adrenal adenoma coexisting with Cushing syndrome and an elevated plasma ACTH level.

Disclosure

The authors have no multiplicity of interest to disclose. The views expressed in this article are those of the authors and do not reflect the official policy or position of the Department of the Army, Department of the Navy, Department of Defense, or the US Government.

References

- Newell-Price J, Bertagna X, Grossman AB, Nieman LK. Cushing's syndrome. *Lancet*. 2006;367(9522):1605–1617.
- Barbot M, Zilio M, Scaroni C. Cushing's syndrome: overview of clinical presentation, diagnostic tools and complications. *Best Pract Res Clin Endocrinol Metab*. 2020;34(2):101380.
- Wengander S, Trimpou P, Papakokkinou E, Ragnarsson O. The incidence of endogenous Cushing's syndrome in the modern era. *Clin Endocrinol*. 2019;91(2):263–270.
- Bourdeau I, Parisien-La Salle S, Lacroix A. Adrenocortical hyperplasia: A multifaceted disease. *Best Pract Res Clin Endocrinol Metab*. 2020;34(3):101386.
- Trainer PJ, Faria M, Newell-Price J, et al. A comparison of the effects of human and ovine corticotropin-releasing hormone on the pituitary-adrenal axis. *J Clin Endocrinol Metab*. 1995;80(2):412–417.
- Mantero F, Terzolo M, Arnaldi G, et al. A survey on adrenal incidentaloma in Italy. Study group on adrenal tumors of the Italian Society of Endocrinology. *J Clin Endocrinol Metab*. 2000;85(2):637–644.
- Berlińska A, Świątkowska-Stodulska R, Sworzak K. Factors affecting dexamethasone suppression test results. *Exp Clin Endocrinol Diabetes*. 2020;128(10):667–671.
- Korkmaz PO, Karayel B, Korkmaz M, et al. Reliability of the corticotropin releasing hormone stimulation test for differentiating between ACTH dependent and independent Cushing syndrome. *Acta Endocrinol (Buchar)*. 2019;15(2):195–202.
- Galm BP, Qiao N, Klibanski A, Biller BMK, Tritos NA. Accuracy of laboratory tests for the diagnosis of Cushing syndrome. *J Clin Endocrinol Metab*. 2020;105(6):2081–2094.
- Malchoff CD, Orth DN, Abboud C, Carney JA, Pairolero PC, Carey RM. Ectopic ACTH syndrome caused by a bronchial carcinoid tumor responsive to dexamethasone, metyrapone, and corticotropin-releasing factor. *Am J Med*. 1988;84:760–764.
- Selvais P, Donckier J, Buysschaert M, Maiter D. Cushing's disease: a comparison of pituitary corticotroph microadenomas and macroadenomas. *Eur J Endocrinol*. 1998;138(2):153–159.
- Woo YS, Isidori AM, Wat WZ, et al. Clinical and biochemical characteristics of adrenocorticotropin-secreting macroadenomas. *J Clin Endocrinol Metab*. 2005;90(8):4963–4969.
- Frete C, Corcuff JB, Kuhn E, et al. Non-invasive diagnostic strategy in ACTH-dependent Cushing's syndrome [published online ahead of print, 2020 Jun 27]. *J Clin Endocrinol Metab*. 2020:dga409.
- Abs R, Nobels F, Verhelst J, et al. Hyperfunctioning unilateral adrenal macronodule in three patients with Cushing's disease: hormonal and imaging characterization. *Acta Endocrinol (Copenh)*. 1993;129(4):284–290.
- Leiba S, Shindel B, Weinberger I, et al. Cushing's disease coexisting with a single macronodule simulating adenoma of the adrenal cortex. *Acta Endocrinol (Copenh)*. 1986;112(3):323–328.
- Schteingart DE, Tsao HS. Coexistence of pituitary adrenocorticotropin-dependent Cushing's syndrome with a solitary adrenal adenoma. *J Clin Endocrinol Metab*. 1980;50(5):961–966.
- Kobayashi Y, Takei M, Ohkubo Y, et al. A somatotropin-producing pituitary adenoma with an isolated adrenocorticotropin-producing pituitary adenoma in a female patient with acromegaly, subclinical Cushing's disease and a left adrenal tumor. *Endocr J*. 2014;61(6):589–595.
- Alzahrani AS, Al-Khaldi N, Shi Y, et al. Diagnosis by serendipity: Cushing syndrome attributable to cortisol-producing adrenal adenoma as the initial manifestation of multiple endocrine neoplasia type 1 due to a rare splicing site MEN1 gene mutation. *Endocr Pract*. 2008;14(5):595–602.
- Yaylali GF, Akin F, Bastemir M, Yaylali YT, Ozden A. Pheochromocytoma combined with subclinical Cushing's syndrome and pituitary microadenoma. *Clin Invest Med*. 2008;31(3):E176–E181.
- Beuschlein F, Fassnacht M, Klink A, Allolio B, Reincke M. ACTH-receptor expression, regulation and role in adrenocortical tumor formation. *Eur J Endocrinol*. 2001;144(3):199–206.
- Latronico AC. Role of ACTH receptor in adrenocortical tumor formation. *Braz J Med Biol Res*. 2000;33(10):1249–1252.