

Review Article

Current Proceedings of Childhood Stroke

Hueng-Chuen Fan,¹ Chih-Fen Hu,¹ Chun-Jung Juan,² and Shyi-Jou Chen¹

¹ Department of Pediatrics, Tri-Service General Hospital, National Defense Medical Center, Neihu, Taipei 114, Taiwan

² Department of Radiology, Tri-Service General Hospital, National Defense Medical Center, Neihu, Taipei 114, Taiwan

Correspondence should be addressed to Shyi-Jou Chen, chensjou@yahoo.com.tw

Received 6 October 2010; Accepted 4 December 2010

Academic Editor: Halvor Naess

Copyright © 2011 Hueng-Chuen Fan et al. This is an open access article distributed under the Creative Commons Attribution License, which permits unrestricted use, distribution, and reproduction in any medium, provided the original work is properly cited.

Stroke is a sudden onset neurological deficit due to a cerebrovascular event. In children, the recognition of stroke is often delayed due to the low incidence of stroke and the lack of specific assessment measures to this entity. The causes of pediatric stroke are significantly different from that of adult stroke. The lack of safety and efficiency data in the treatment is the challenge while facing children with stroke. Nearly half of survivors of pediatric stroke may have neurologic deficits affecting functional status and quality of life. They may cause a substantial burden on health care resources. Hence, an accurate history, including onset and duration of symptoms, risk factors, and a complete investigation, including hematologic, neuroimaging, and metabolic studies is the key to make a corrective diagnosis. A prompt and optimal treatment without delay may minimize the damage to the brain.

1. Introduction

Stroke is defined as the sudden occlusion or rupture of cerebral arteries or veins resulting in focal damage and clinical neurologic deficits. Clinical manifestations of stroke include weakness or paralysis of a limb, or the sudden inability to speak, and the onset of the deficit may be within seconds, minutes, or hours. Stroke is one of the most common neurological causes for admission to a hospital and is the second commonest cause of death in the world [1]. Although stroke is still a disease of the senescence and the incidence of stroke for old people is approximately 12/1,000, [2–4] stroke in the young people is relatively rare. The annual incidence rate for stroke in children is 2–3/100,000 [5]. The incidence of neonatal stroke is much rarer, approximately 1 in 4000 term live births. There was a slight female predominance [6–8]. The prevalence of stroke in the east countries is different from that in the West, and this difference has been attributed to differences in urbanization, change of diet, lifestyles, and healthcare facilities [9, 10]. Stroke is particularly tragic because of much longer expected lifespan ahead leading to a long-term burden for the victims, their families, and community, emphasizing the need for a high degree of clinical suspicion toward

the stroke in the young. The current review focuses on pediatric strokes.

2. Etiologies

Contrary to adults in whom arteriosclerosis is the leading cause, risk factors of pediatric strokes are multiple [11], including cardiac disorders, infection, prothrombotic disorders, moyamoya disease and moyamoya syndrome, and others.

2.1. Cardiac Disorders. Congenital heart disease (CHD) and other cardiac problems are still recognized as presumed risk factors for pediatric stroke [12]. In the presence of an atrial or ventricular septal defect with intermittent right-to-left intracardiac shunting including patent foramen ovale [13–15], systemic venous clots can reach the cerebral circulation. In addition, stroke is highly related to procedures such as surgery of catheterization [12, 16, 17] and Fontan surgery [18–20]. Prosthetic heart valves are an important source of emboli [21, 22]. Therefore, most congenital heart lesions should be repaired to improve cardiac function and reduce the risk of subsequent stroke. All children with strokes

of undermined causes should have an echocardiogram performed.

2.2. Infection. Varicella is reported to be related to pediatric ischemic strokes [23–27]. Radiographic features of postvaricella angiopathy include basal ganglion infarctions and self-resolving unilateral stenosis of the distal internal carotid or proximal anterior, middle, or posterior cerebral arteries [28, 29]. Several viruses have been linked to arteriopathies and strokes in children, but paradoxically, not so many children have strokes as minor viral infections are so common in children. It is still not clear how viral infections contribute to arteriopathies and strokes.

2.3. Prothrombotic and Hematologic Disorders. Inherited or acquired prothrombotic or coagulation disorders can predispose children to strokes [30, 31]. Most common prothrombotic abnormalities include deficiencies of protein C [32], protein S [33], antithrombin III [34], plasminogen [35], anticardiolipin antibody [33], lupus anticoagulant [33], homocystein [34] and antiphospholipid antibodies [34], prothrombin 20210A gene [36], and mutated Factor V [37] and mutated methyl-tetrahydrofolate reductase (MTHFR) [38]. Coagulation studies should be performed in any child with stroke without identified risk factors. Abnormal results on samples taken within several weeks of the stroke should be confirmed by testing parents, if the abnormality is a hereditary coagulation abnormality, or the child should be retested several months later.

2.4. Moyamoya Disease and Moyamoya Syndrome. Moyamoya disease is a nonatherosclerotic, noninflammatory, and nonamyloid vasculopathy characterized by chronic progressive stenosis or occlusion of the terminal internal carotid arteries and/or the proximal portion of the anterior cerebral arteries and/or middle cerebral arteries [39]. Moyamoya disease is more common in girls [40] and peaks in both the first and fourth decades of life [41]. The definitive method for diagnosis is conventional angiography, which may show a pattern of “hazy, cloudy puff of smoke.” The underlying reflects an abnormal network of small collateral vessels in response to the stenosis (Figure 3). In Japanese, the term “moyamoya” represents the appearance of radiographic features [42]. The clinical course may be stable, may appear recurrent transient ischemic attacks (TIAs), and may manifest strokes with progressive neurologic impairment or alternate hemiplegia [43, 44]. Partial and secondary generalized seizures are common in younger children [45]. No specific medical therapy can effectively halt the progression of moyamoya disease. Complications of moyamoya disease include intellectual impairment and permanent motor deficits [46]. The moyamoya syndrome shows radiographic features of moyamoya disease but different underlying etiologies, such as sickle cell disease or postradiation vasculopathy. Revascularization including anastomosis of the superficial temporal artery to the cerebral artery, encephalomyosynangiosis, and encephaloduroarteriosynangiosis [47] is promising because it is associated with a reduced stroke rate [48].

2.5. Other Risk Factors. Hyperlipidemia is one of the most common risk factors for stroke in a Chinese young stroke study [49]. Mild trauma or exertion causing cerebral arterial dissection may lead to pediatric stroke [8]. Hsu et al. [50] reported a child suddenly experienced left hemiparalysis after performing repeated backward somersault resulting in an isolated middle cerebral artery dissection (Figure 4). When the dissection of carotid or vertebral arteries occurs, this event may result from a tear to the arterial wall often related to trauma. However, this tragedy may occur spontaneously in children [51] or be caused by nonaccidental traumas and strangulation. If there is any unexplained subdural hemorrhage (SDH) in infants (Figure 2), nonaccidental traumas should be considered, and retinal hemorrhage may provide a supportive clue of shaken baby syndrome. Migraine is also a dangerous risk factor because literature shows that women who had experienced onset of migraine within the previous year had 6.9-fold higher odds of stroke compared with women without a history of migraine [52]. Vasculitis, such as polyarteritis nodosa [53], Takayasu’s arteritis [54], mixed connective tissue disease [55], and systemic lupus erythematosus [56], has all been reported in childhood strokes. An elevated homocystein level appears to be associated with strokes in young Asian patients [57]. Patients with Fabry’s disease, a lack of alpha galactosidase, may have multiple lacunar cerebral infarcts in affected boys during the teenage and early adult years [58]. Mitochondrial myopathy, encephalopathy, lactic acidosis, and stroke-like episodes (MELAS syndrome) in children present with episodes of nausea, vomiting, headache, seizures, hemiparesis, and cortical blindness. Infarct-like lesions in the cerebral cortex, basal ganglia, and brainstem are confirmed by autopsy [59]. Cranial CT or MRI shows areas of infarctions that do not correspond to major vascular distributions. A3243G mutation affecting the rates of mitochondrial translation and respiration consequently causes the mitochondrial dysfunction [60]. Children with neurofibromatosis may have complications of cerebral arteriopathies [61]. History of use of oral contraceptives and illicit drugs (amphetamines, cocaine) is a risk factor for strokes in the young people.

3. Clinical Features

Seizures, irritability, or altered consciousness are common in infants and young children, but hemiparesis is difficult to recognize in this age group [11]. Older children typically present with speech, visual, focal sensory, or coordination abnormalities. Dystonia is more common in children with basal ganglia infarction than in adults. TIAs are increasingly recognized in children and infants [11]. Even so, the recognition of cerebral infarction in children is often delayed due to the low incidence of stroke and the lack of awareness of pediatricians to this entity [62]. Hence, clinical features obtained from the history and physical examination can provide significant information. For instance, a recent head or neck injury suggests dissection. A recent varicella infection should lead to consideration of postvaricella angiopathy.

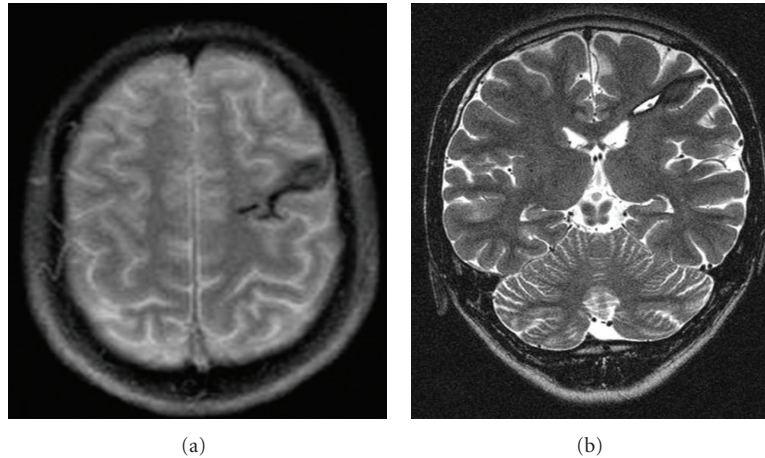


FIGURE 1: A 17-year-old boy was presented with seizures one month after a prior head injury. Axial T1-weighted image (a) and coronal T2-weighted image (b) showed the hemosiderin deposition and a small CSF-filled cavity of the left middle frontal gyrus.

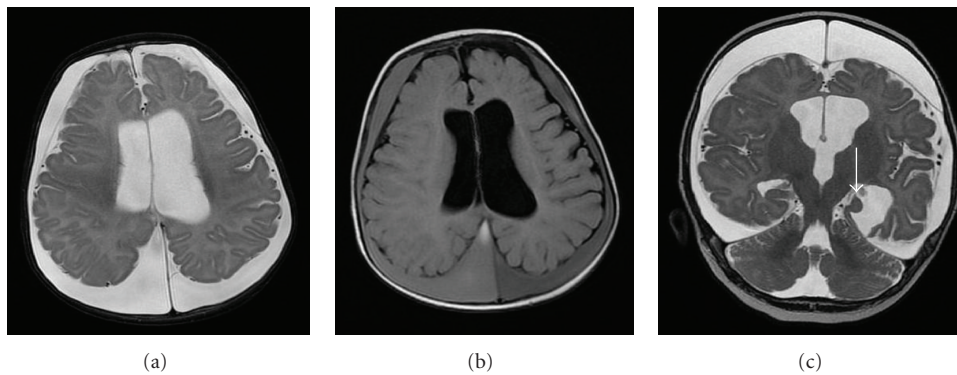


FIGURE 2: A 4-month-old infant was presented with a large head circumference followed by seizure-like episodes. Axial T2-weighted image (a) showed hydrocephalus and prominent CSF space along bilateral cerebral convexities. The fluid was subdural hematomas because the signal intensity of the fluid is different from that of CSF on FLAIR T2-weighted image (b). Coronal T2-weighted image showed hypoplasia of the left hippocampus.

Migraine and oral contraceptive, amphetamine, or cocaine use all predispose to infarction. A family history of stroke [63], heart attack, lipid problems, and calf deep vein or pulmonary thrombosis at young ages may be associated with increased stroke risk. Physical examination such as head or neck bruits, cardiac murmurs or skin lesions of tuberous sclerosis, Neurofibromatosis or Fabry's disease may also provide additional clues.

4. Classification

Strokes can be subdivided into two types: ischemic and hemorrhagic.

4.1. Hemorrhagic Stroke. Hemorrhagic stroke is as common as ischemic stroke in childhood, and nearly half of pediatric strokes are hemorrhagic [64]. There are two major types of hemorrhagic stroke which reflect the anatomic site of the bleeding and are classified as "intracerebral hemorrhage (ICH)" and "subarachnoid hemorrhage (SAH)." They can

coexist in individual patients, such as when rupture of an arteriovenous malformation (AVM) produces both SAH and ICH. In contrast to ischemic stroke, definitive treatment for hemorrhagic stroke frequently requires neurological intervention [65, 66].

4.2. Intracerebral Hemorrhage (ICH). ICH devastates children with death reported in up to 33% and permanent deficits in up to 40%, including seizures and cognitive and motor impairment [65, 67]. ICHs result from the rupture of cranial vessels and are classified as extradural, subdural, subarachnoid, intracerebral, or intraventricular. Compared with adults, pediatric ICH is more likely to result from a bleeding diathesis due to inherited hemophilic or thrombocytopenic disorders [68]. In acquired conditions, ICH is present in at least 9% of infants undergoing extracorporeal membrane oxygenator (ECHO) procedure and occurs early after initiation of bypass in 85% [69]. Trauma is the common cause for ICH in children (Figure 1). Typical clinical features in children are seizures,

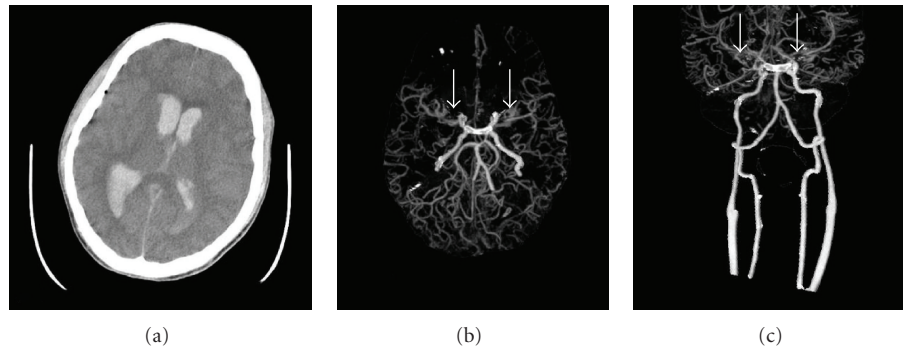


FIGURE 3: A 17-year-old boy was presented with sudden loss of consciousness and generalized seizure attack. Nonenhanced CT study (a) showed acute intraventricular hemorrhage. CT angiography (b, c) disclosed occlusion of bilateral prebifurcation M1 segment of middle cerebral arteries with some moyamoya vessels (arrows).

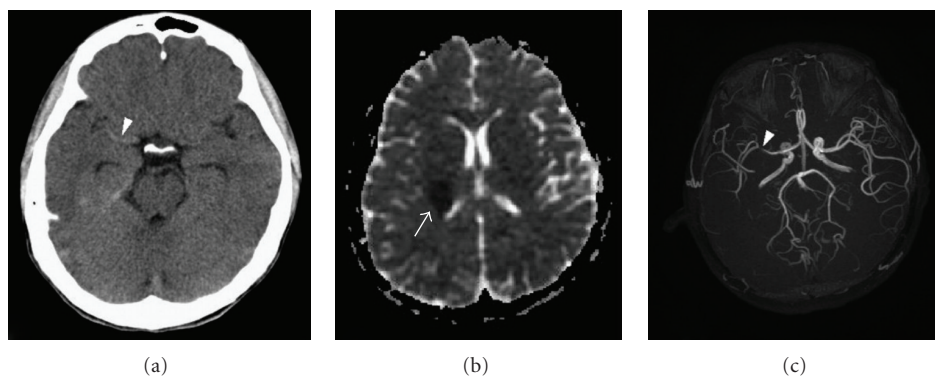


FIGURE 4: A 15-year-old boy suddenly experienced acute right-sided headache and dizziness followed by drowsy consciousness and left-sided weakness after practicing backward somersaults. Nonenhanced CT image of the brain (a) showed increased attenuation at the M1 segment of the right MCA (white arrowhead). Apparent diffusion map of the brain (b) delineated a 2.4-cm low-signal area in the posterior limb of the right internal capsule, consistent with a hyperacute infarct (arrow). Magnetic resonance angiography of the brain (c) showed focal stenosis of the right MCA with decreased flow and number of distal branches (white arrowhead).

decreasing levels of consciousness, and IICP. It is unusual for infants to present bulging fontanel and splayed sutures and focal signs resulting from the increasing volume of intracranial blood, edema, or secondary hydrocephalus because infants with nonfused cranial sutures can accommodate to increase in brain volumes with raised ICP. The periventricular germinal matrix of preterm neonates is extremely vulnerable to hypoxia. Once hemorrhage occurs, blood may extend into the ventricular system and cause extension of hemorrhage because the unmyelinated brain of infant offers relatively less mechanical resistance than the adult brain. Available evidence shows that pediatric ICH is caused by hematologic abnormalities and infratentorial hemorrhage location [70], and ICH volume [71] is associated with poor outcome.

4.3. Subarachnoid Hemorrhage (SAH). SAH is a neurologic emergency characterized by the extravasation of blood into the spaces covering the CNS that are filled with CSF [72]. Ruptures of aneurysms, AVMs, and head trauma are the major causes for SAH. The underlying cause for neonate SAH is usually hypoxia in preterm or trauma in term

infants. Trauma is the common cause for SAH in children [73]. Rupture of an aneurysm accounts for 80% of cases [74]. In infants, most aneurysms tend to rupture less than 2 years of age or in children older than 10 years [75]. Typical presentations of SAH include a sudden and severe onset of headache, a stiff or painful neck, vision loss, inability to move an arm or leg, numbness, speech difficulty, and/or loss of consciousness in adults, and there may be intermittent seizures or no symptoms on a well baby. SAH is occasionally detected on CT, MRI, or postmortem in neonates after a normal or minor traumatic vaginal delivery. Lumbar puncture should be performed in any patient with suspected SAH and equivocal results on head CT scanning. MRI and MRA can provide good visualization of aneurysms, but angiography is more reliable. Treatment of patients with aneurysmal SAH not only involves securing the aneurysm by endovascular coiling or surgical clipping but also prevention and treatment of the medical and neurological complications, including symptomatic vasospasm [76], hydrocephalus [77], and rebleeding [78]. More than half of survivors report problems with memory, mood, or neuropsychological function [72]. The average

case mortality rate for SAH is 51% [79]. Early identification and therapy of cerebral and systemic complications are very important to preserve and improve functional outcome.

4.4. Cerebral Sinovenous Thrombosis (CSVT). CSVT is defined by the presence of thrombus or flow interruption within cerebral veins or dural venous sinuses. More rapid rates of occlusion of cerebral venous structures lead to a rise in cerebral venous pressure that are more likely to produce infarction and occasionally may interfere regional perfusion. CVST is rare in children and the incidence is 0.67 per 100,000 children per year with over 40% occurring in newborn [80]. CSVT has been reported in neonates with asphyxia, lethargy, jitteriness, and seizure without focal signs [80–83] and in 25% of children with pseudotumor cerebri [84]. Iron-deficiency anemia has been increasingly reported in pediatric patients with CSVT [85–87]. In septic CSVT, a bacterial infection adjacent to the sinuses spreads directly into the sinus, provoking thrombophlebitis. Dehydration is a dangerous signal for SVT because of increased hemoconcentration impairing laminar flow. In neonates, the increased risk for CSVT may be due to the location of the major dural sinuses along the bony suture lines and their consequent mechanical distortion during calvarial molding in the birth process [88]. In older children, head trauma or cranial surgery may damage the dural sinuses, leading to CVST [89, 90]. The diagnosis of CVST requires neuroimaging evidence of thrombus or lack of flow in the cerebral veins or venous sinus. However, brain CT scan may yield false-positive results, particularly in neonates. Spiral CT imaging can delineate vascular flow, enabling noninvasive cerebral CT venography [91]. MRI can clearly visualize both absent flow and the presence of thrombus, clot progression, and resolution over time as well as associated parenchymal lesions have made MRI the diagnostic study of choice in CSVT [84, 92, 93]. Cerebral angiography is still the gold standard especially when CT or MRI is not definitive. Treatment of SVT includes general supportive measures and antithrombotic and nonantithrombotic therapies. Studies showed that anticoagulants were used in up to 50% of childhood CSVT patients without significant hemorrhagic complications [80, 94]. For neonates with CSVT, unfractionated heparin or low-molecular-weight heparin given for 7 days followed by low-molecular-weight heparin alone for 6 to 12 weeks is indicative. For older infants and children, unfractionated heparin or low-molecular-weight heparin given for 7 days, followed by Coumadin for 3 to 6 months, is a treatment option. If significant ICH is associated with SVT, the use of anticoagulants is controversial. Septic SVT requires antibiotics and may need surgical removal and drainage of the infection. Regular cranial ultrasound can monitor and screen the course of CSVT. The long-term outcome in adults with SVT is quite good, but mortality rate in pediatric CSVT is reported to be 6 to 30% [95, 96]. Therefore, children with CSVT should be closely monitored.

5. Diagnosis

The diagnosis of stroke relies mainly on a detailed history, careful neurological examination and astute suspicion, and its differentiation from other conditions that mimic stroke's presentations. The confirmation requires laboratory investigations including (1) a full blood count (CBC) to detect polycythemia, thrombocytosis, or anemia; (2) ESR to exclude arteritis or bacterial endocarditis; (3) levels of urea and electrolytes to reveal any electrolyte disturbance that can mimic stroke; (4) level of blood glucose; hyper- and hypoglycemia can mimic stroke, and diabetes mellitus is a risk factor; (5) serum cholesterol; a well-known risk factor for strokes and heart attack; (6) syphilis serology as syphilis is a rare but treatable cause of stroke; (7) blood cultures should be performed if there is any suspicion of bacterial endocarditis. EKG may detect cardiac sources of ventricular hypertrophy and/or arrhythmia. Chest X-ray can demonstrate cardiac sources of emboli, ventricular hypertrophy, and/or any organic lesions. Doppler ultrasound can detect large vessel vasculopathy in carotid and intracranial arteries. CT scans, CT spiral angiography, and MRI may navigate clinicians the anatomy of each major artery in the brain and localize hemorrhages and damaged tissue. MRI is far superior to CT in detecting small and multiple infarcts, especially in the brainstem and cerebellum. Modifications of MRI include diffusion-weighted imaging, perfusion MR imaging, proton spectroscopic imaging, and MRA, that have improved the early detection and specificity of ischemic injury. Moreover, single-photon emission computed tomography (SPECT) scanning can detect areas of hypoperfusion that may occur earlier than other radiographically detected defects in the arterial ischemic stroke.

6. Treatment

In acute stage, newborns with arterial ischemic stroke rarely require antithrombotic treatment; children with stroke should be stabilized promptly and transferred to a tertiary care centers with expertise that can provide specialized pediatric neurovascular care, because their autoregulation of CNS vascular system is dysfunction [97]. Optimal treatment, including antithrombotic therapies, thrombolytics agents, neuroprotective agents, neurosurgical procedures, and careful monitor of blood pressure, body temperature, and biochemical data such as hemoglobin and blood glucose and careful fluid management, should be given to minimize the damage to the brain.

6.1. Heparin. Heparin, a large heterogenous polysaccharide complex, cannot cross the placenta. The mechanisms of Heparin are those that enhance the rate by which antithrombin III neutralizes the activity of several activated clotting proteins, especially factor Xa and thrombin in turn prevent clot extension or new clot formation [98]. The average $t_{1/2}$ of intravenous heparin is about 60 minutes in adults and can be as short as 30 minutes in the newborn. Heparin is commonly used in children for deep vein thrombosis and pulmonary embolism. Heparin has been the standard

therapy for acute anticoagulation following stroke [99]. Heparin is given at maintenance dose of 28 units/kg/hour in infants, 20 units/kg/hour in children older than 1 year of age, and 18 units/kg/hour in older children. The target activated partial thromboplastin time is 60 to 85 seconds or 1.5 to 2 times of the baseline value. A recent central nervous system hemorrhage; bleeding from inaccessible sites; malignant hypertension; bacterial endocarditis; recent surgery of the eye, brain, or spinal cord; current administration of regional or lumbar block anesthesia are contraindicated in the anticoagulation treatment with heparin. Because heparin can be neutralized by protamine sulfate, specific heparin levels should be obtained so that the heparin level is 0.35–0.70 Unit/mL by antifactor Xa assay or 0.2–0.4 unit/mL by protamine sulfate assay. Low-molecular-weight (LMW) heparin has become the first choice for acute anticoagulation therapy because adults with arterial infarcts treated with low-molecular-weight (LMW) heparin may have a better outcome [100] and so as to that in children [101]. However, adult patients receiving LMW heparin usually do not need to have their heparin levels monitored, but in pediatric patients, monitoring is critical to ensure that a therapeutic level is achieved, which for antifactor Xa is 0.5 to 1.0 units/mL in a sample drawn 4 to 6 hours after the subcutaneous dose.

6.2. Warfarin. Warfarin is an oral anticoagulant drug that reduce the activity of the vitamin K-dependent coagulation factors: II, VII, IX, and X, as well as protein C and protein S. Prothrombin time (PT) is the clotting test used to assess warfarin anticoagulation. Warfarin is used in adults for the secondary prevention of stroke in situations in which aspirin therapy has failed. In children with cerebrovascular disorders, including severe hypercoagulable states, arterial dissection [102], cardiogenic embolism [102], cerebral sinovenous thrombosis (CSVT) [103], and ischemic stroke or TIA [104], the international normalized ratio (INR) for standard treatment of thrombosis is 2.0–3.0. The most serious side effect of warfarin is hemorrhage. Contraindications to Warfarin anticoagulants are essentially the same as those for heparin therapy.

6.3. Thrombolytic Agents. Thrombolytic agents include streptokinase, urokinase, prourokinase, and recombinant tissue-type plasminogen activator (rTPA). Natural streptokinase is isolated and purified from streptococci. Streptokinase is not a protease and has no enzymatic activity; however, it forms a complex with plasminogen that releases plasmin [105]. Urokinase is occasionally referred to as urinary-type plasminogen activator (uPA) because it is formed by kidneys and is found in urine [106]. One benefit over streptokinase is that urokinase is nonantigenic; however, this is offset by a much greater cost. Lack of fibrin specificity makes streptokinase and urokinase less desirable thrombolytic drugs than rTPA compounds. Single-chain urokinase-type plasminogen activator or prourokinase is a zymogen with an intrinsic catalytic activity which is

greater than that of most of the other zymogens. Intra-arterial prourokinase administration has been proved to be beneficial in clinical trails in adults within 6 hours of the onset of acute ischemic stroke caused by MCA occlusion which significantly improved clinical outcome at 90 days [107], and the risk of symptomatic intracranial hemorrhage was increased in the presence of acute hyperglycemia [108]. rTPA is a purified glycoprotein produced by recombinant DNA technology. It has the property of fibrin-enhanced conversion of plasminogen to plasmin and is successfully used in acute myocardial infarction [109] and ischemic stroke [110]. Although studies show that the intravenous rTPA administration is effective in reducing disability and possibly decreasing the size of the infarct [110, 111], many patients are left with moderate to severe neurological deficits in this manner. Intra-arterial treatment is proposed for its higher rates of recanalization, lower doses of thrombolytics used compared with intravenous therapy, and lower rates of intracerebral hemorrhage (ICH) [112, 113]. However, the US Food and Drug Administration only approves the use of intravenous rTPA in adults with acute ischemic stroke, and the condition for this thrombolytic agent is that the duration between onset of symptoms and the time for the use of rTPA is within three hours and can be extended to four and half hours in certain patients [114]. Clinical trials evaluating the feasibility and efficacy of intravenous and intra-arterial rTPA therapy for pediatric strokes are difficult because of the frequent delay in diagnosis and the lack of safety data. A study on the safety and effectiveness of a low dose of rTPA for thrombolysis in children with arterial and venous thrombi is under investigation and the results are promising [115].

6.4. Neuroprotective Agents. Accumulative evidence supports that hypothermia can protect against brain damage, especially in neonates with hypoxic ischemic encephalopathy [116, 117]. Hypothermia in adults with stroke may be associated with serious sequelae, such as hypotension, arrhythmia, and pneumonia [118]. Early use of antiepileptic drugs in children with seizures associated with arterial ischemic stroke is essential to prevention from recurrent seizures that may worsen the infarct volume [119].

6.5. Neurosurgical Procedures. Emergent decompression with hemicraniectomy may save a patient's life when a huge amount of hemorrhage and/or hematoma causes herniation.

6.6. Rehabilitation Therapy. Compared with old patients with strokes, infant and young children have additional rehabilitation difficulties, including feeding dysfunction related to speech therapy and ongoing modification therapies when they grow and develop age-related skills over time. Hemiatrophy limbs can cause orthopedic problems, such as leg length discrepancy. Moreover, these patients may develop learning and behavior problems and require intervention by specialized pediatric rehabilitation and education teams. It is necessary to encourage patients' families and remind them of avoiding overprotection. What is more important is to treat the affected child as normally as possible.

7. Conclusion

With half of the world's population, stroke in Asia is important globally. With an aging population, there is an expected rise in numbers of stroke and a corresponding increase in the burden of stroke in Asia. Indeed, tremendous efforts have been made to increase public recognition of adult stroke, and similarly most of the studies have been directed to understanding and evaluating prevention and treatment strategies in adult stroke. In fact, there are important differences between adult and pediatric stroke that limit the applicability of data from adult research to this population. Therefore, multicenter collaborative databases are needed to have a global view on the causes, treatment approaches, and outcome of the stroke in the young people. In fact, strokes in the young still remain less noticeable even among clinicians. Given the far better potential for outcome and longer duration of disability in children with stroke compared with adults, further studies are needed to refine our understanding of underlying mechanisms and improve the development of rational therapies for pediatric stroke.

Acknowledgments

This work was supported by a research Grant (no. TSGH-C99-024) from the Tri-Service General Hospital. The authors thank Dr. Chang Kai-Ping (Department of Pediatrics, Veterans General Hospital, Taipei) and Dr. Peng Giia-Sheun (Department of Neurology, Tri-Service General Hospital, and National Defense Medical Center) for helpful suggestions and comments on the paper.

References

- [1] R. Bonita, S. Mendis, T. Truelsen, J. Bogousslavsky, J. Toole, and F. Yatsu, "The global stroke initiative," *The Lancet Neurology*, vol. 3, no. 7, pp. 391–393, 2004.
- [2] R. Bonita, R. Beaglehole, and J. D. K. North, "Event incidence and case fatality rates of cerebrovascular disease in Auckland, New Zealand," *American Journal of Epidemiology*, vol. 120, no. 2, pp. 236–243, 1984.
- [3] H. A. H. Abu Zeid, N. W. Choi, and N. A. Nelson, "Epidemiologic features of cerebrovascular disease in Manitoba: incidence by age, sex and residence, with etiologic implications," *Canadian Medical Association Journal*, vol. 113, no. 6, pp. 379–384, 1975.
- [4] N. E. Mayo, M. S. Goldberg, A. R. Levy, I. Danys, and N. Korner-Bitensky, "Changing rates of stroke in the province of Quebec, Canada: 1981–1988," *Stroke*, vol. 22, no. 5, pp. 590–595, 1991.
- [5] J. K. Lynch, D. G. Hirtz, G. DeVeber, and K. B. Nelson, "Report of the National Institute of Neurological Disorders and Stroke workshop on perinatal and childhood stroke," *Pediatrics*, vol. 109, no. 1, pp. 116–123, 2002.
- [6] C. C. Liao, T. C. Li, R. S. Lin, and F. C. Sung, "Urban and rural difference in prevalence and incidence of stroke in 2000 in Taiwan," *Taiwan Journal of Public Health*, vol. 25, no. 3, pp. 223–230, 2006.
- [7] H. Naess, H. I. Nyland, L. Thomassen, J. Aarseth, G. Nyland, and K. M. Myhr, "Incidence and short-term outcome of cerebral infarction in young adults in Western Norway," *Stroke*, vol. 33, no. 8, pp. 2105–2108, 2002.
- [8] M. Rasura, A. Spalloni, M. Ferrari et al., "A case series of young stroke in Rome," *European Journal of Neurology*, vol. 13, no. 2, pp. 146–152, 2006.
- [9] Y. Shinohara, "Regional differences in incidence and management of stroke—is there any difference between Western and Japanese guidelines on antiplatelet therapy?" *Cerebrovascular Diseases*, vol. 21, supplement 1, pp. 17–24, 2006.
- [10] D. Kromhout, "Epidemiology of cardiovascular diseases in Europe," *Public Health Nutrition*, vol. 4, no. 2B, pp. 441–457, 2001.
- [11] G. DeVeber, "Arterial ischemic strokes in infants and children: an overview of current approaches," *Seminars in Thrombosis and Hemostasis*, vol. 29, no. 6, pp. 567–573, 2003.
- [12] W. Lo, J. Stephens, and S. Fernandez, "Pediatric stroke in the United States and the impact of risk factors," *Journal of Child Neurology*, vol. 24, no. 2, pp. 194–203, 2009.
- [13] D. Fischer, J. Haentjes, G. Klein et al., "Transcatheter closure of patent foramen ovale (PFO) in patients with paradoxical embolism: procedural and follow-up results after implantation of the Amplatzer®-occluder device," *Journal of Interventional Cardiology*. In press.
- [14] G. Gaio, G. Santoro, M. T. Palladino et al., "Cardioembolic stroke: who is the guilty?" *Journal of Cardiovascular Medicine*. In press.
- [15] H. P. Mattle, B. Meier, and K. Nedeltchev, "Prevention of stroke in patients with patent foramen ovale," *International Journal of Stroke*, vol. 5, no. 2, pp. 92–102, 2010.
- [16] C. C. Menache, A. J. du Plessis, D. L. Wessel, R. A. Jonas, and J. W. Newburger, "Current incidence of acute neurologic complications after open-heart operations in children," *Annals of Thoracic Surgery*, vol. 73, no. 6, pp. 1752–1758, 2002.
- [17] T. Domi, D. S. Edgell, B. W. McCrindle et al., "Frequency, predictors, and neurologic outcomes of vaso-occlusive strokes associated with cardiac surgery in children," *Pediatrics*, vol. 122, no. 6, pp. 1292–1298, 2008.
- [18] P. Monagle and T. R. Karl, "Thromboembolic problems after the fontan operation," *Pediatric Cardiac Surgery Annual*, vol. 5, pp. 36–47, 2002.
- [19] M. Procelewska, J. Kolcz, K. Januszewska, T. Mroczek, and E. Malec, "Coagulation abnormalities and liver function after hemi-Fontan and Fontan procedures—the importance of hemodynamics in the early postoperative period," *European Journal of Cardio-Thoracic Surgery*, vol. 31, no. 5, pp. 866–872, 2007.
- [20] A. E. van den Bosch, J. W. Roos-Hesselink, R. van Domburg, A. J. J. C. Bogers, M. L. Simoons, and F. J. Meijboom, "Long-term outcome and quality of life in adult patients after the Fontan operation," *American Journal of Cardiology*, vol. 93, no. 9, pp. 1141–1145, 2004.
- [21] E. Meseguer, J. Labreuche, C. Durdilly et al., "Prevalence of embolic signals in acute coronary syndromes," *Stroke*, vol. 41, no. 2, pp. 261–266, 2010.
- [22] D. Georgiadis, R. W. Baumgartner, R. Karatschai, A. Lindner, and H. R. Zerkowski, "Further evidence of gaseous embolic material in patients with artificial heart valves," *Journal of Thoracic and Cardiovascular Surgery*, vol. 115, no. 4, pp. 808–810, 1998.

- [23] D. Gilden, R. J. Cohrs, R. Mahalingam, and M. A. Nagel, "Varicella zoster virus vasculopathies: diverse clinical manifestations, laboratory features, pathogenesis, and treatment," *The Lancet Neurology*, vol. 8, no. 8, pp. 731–740, 2009.
- [24] E. Miravet, N. Danchaiwitt, H. Basu, D. E. Saunders, and V. Ganesan, "Clinical and radiological features of childhood cerebral infarction following varicella zoster virus infection," *Developmental Medicine and Child Neurology*, vol. 49, no. 6, pp. 417–422, 2007.
- [25] M. A. Nagel, R. J. Cohrs, R. Mahalingam et al., "The varicella zoster virus vasculopathies: clinical, CSF, imaging, and virologic features," *Neurology*, vol. 70, no. 11, pp. 853–860, 2008.
- [26] M. A. Nagel, R. Mahalingam, R. J. Cohrs, and D. Gilden, "Virus vasculopathy and stroke: an under-recognized cause and treatment target," *Infectious Disorders—Drug Targets*, vol. 10, no. 2, pp. 105–111, 2010.
- [27] V. Ganesan, M. Prengler, M. A. McShane, A. M. Wade, and F. J. Kirkham, "Investigation of risk factors in children with arterial ischemic stroke," *Annals of Neurology*, vol. 53, no. 2, pp. 167–173, 2003.
- [28] R. Askalan, S. Laughlin, S. Mayank et al., "Chickenpox and stroke in childhood: a study of frequency and causation," *Stroke*, vol. 32, no. 6, pp. 1257–1262, 2001.
- [29] T. M. Berger, J. H. Caduff, and J. O. Gebbers, "Fatal varicella-zoster virus antigen-positive giant cell arteritis of the central nervous system," *Pediatric Infectious Disease Journal*, vol. 19, no. 7, pp. 653–656, 2000.
- [30] C. Barnes and G. DeVeber, "Prothrombotic abnormalities in childhood ischaemic stroke," *Thrombosis Research*, vol. 118, no. 1, pp. 67–74, 2006.
- [31] M. R. Golomb, D. L. MacGregor, T. Domi et al., "Presumed pre- or perinatal arterial ischemic stroke: risk factors and outcomes," *Annals of Neurology*, vol. 50, no. 2, pp. 163–168, 2001.
- [32] L. M. L. de Lau, F. W. G. Leebeek, M. P. M. de Maat, P. J. Koudstaal, and D. W. J. Dippel, "A review of hereditary and acquired coagulation disorders in the aetiology of ischaemic stroke," *International Journal of Stroke*, vol. 5, no. 5, pp. 385–394, 2010.
- [33] M. Martínez-Martínez, R. Cazorla-García, L. A. Rodríguez de Antonio, P. Martínez-Sánchez, B. Fuentes, and E. Díez-Tejedor, "Hypercoagulability and ischemic stroke in young patients," *Neurología*, vol. 25, no. 6, pp. 343–348, 2010.
- [34] J. A. Zeller, CH. C. Eschenfelder, and R. Stingle, "Coagulation disorders and strokeGerinnungsstörungen und Schlaganfall," *Hamostaseologie*, vol. 26, no. 4, pp. 309–315, 2006.
- [35] W. Z. Abdullah, S. Z. Idris, S. Bashkar, and R. Hassan, "Role of fibrinolytic markers in acute stroke," *Singapore Medical Journal*, vol. 50, no. 6, pp. 604–609, 2009.
- [36] G. Young, M. Manco-Johnson, J. C. Gill et al., "Clinical manifestations of the prothrombin G20210A mutation in children: a pediatric coagulation consortium study," *Journal of Thrombosis and Haemostasis*, vol. 1, no. 5, pp. 958–962, 2003.
- [37] D. C. Herak, M. R. Antolic, J. L. Krleza et al., "Inherited prothrombotic risk factors in children with stroke, transient ischemic attack, or migraine," *Pediatrics*, vol. 123, no. 4, pp. e653–e660, 2009.
- [38] I. Zak, B. Sarecka-Hujar, I. Kopyta et al., "The T allele of the 677C>T polymorphism of *methylenetetrahydrofolate reductase* gene is associated with an increased risk of ischemic stroke in Polish children," *Journal of Child Neurology*, vol. 24, no. 10, pp. 1262–1267, 2009.
- [39] E. Y. Yilmaz, M. B. Pritz, A. Bruno, A. Lopez-Yunez, and J. Biller, "Moyamoya: Indiana University Medical Center experience," *Archives of Neurology*, vol. 58, no. 8, pp. 1274–1278, 2001.
- [40] B. S. Schoenberg, J. F. Mellinger, and D. G. Schoenberg, "Moyamoya disease in children," *Southern Medical Journal*, vol. 71, no. 3, pp. 237–241, 1978.
- [41] M. V. Olds, R. W. Griebel, and H. J. Hoffman, "The surgical treatment of childhood moyamoya disease," *Journal of Neurosurgery*, vol. 66, no. 5, pp. 675–680, 1987.
- [42] K. Takeuchi and K. Shimizu, "Hypoplasia of the bilateral internal carotid arteries," *Brain Nerve*, vol. 9, pp. 37–43, 1957.
- [43] S. Levin, "Moyamoya disease," *Developmental Medicine and Child Neurology*, vol. 24, no. 6, pp. 850–853, 1982.
- [44] J. Suzuki and A. Takaku, "Cerebrovascular "moyamoya" disease. Disease showing abnormal net-like vessels in base of brain," *Archives of Neurology*, vol. 20, no. 3, pp. 288–299, 1969.
- [45] B. S. Schoenberg, J. F. Mellinger, D. G. Schoenberg, and F. S. Barringer, "Moyamoya disease presenting as a seizure disorder. A case report," *Archives of Neurology*, vol. 34, no. 8, pp. 511–512, 1977.
- [46] B. S. Schoenberg, J. F. Mellinger, and D. G. Schoenberg, "Cerebrovascular disease in infants and children: a study of incidence, clinical features, and survival," *Neurology*, vol. 28, no. 8, pp. 763–768, 1978.
- [47] K. Ueki, F. B. Meyer, and J. F. Mellinger, "Moyamoya disease: the disorder and surgical treatment," *Mayo Clinic Proceedings*, vol. 69, no. 8, pp. 749–757, 1994.
- [48] L. W. E. Fung, D. Thompson, and V. Ganesan, "Revascularisation surgery for paediatric moyamoya: a review of the literature," *Child's Nervous System*, vol. 21, no. 5, pp. 358–364, 2005.
- [49] T. H. Lee, W. C. Hsu, C. J. Chen, and S. T. Chen, "Etiologic study of young ischemic stroke in Taiwan," *Stroke*, vol. 33, no. 8, pp. 1950–1955, 2002.
- [50] K. C. Hsu, H. W. Kao, and S. J. Chen, "Backward somersault as a cause of childhood stroke: a case report of isolated middle cerebral artery dissection in an adolescent boy," *American Journal of Emergency Medicine*, vol. 26, no. 4, pp. 519–e3, 2008.
- [51] M. F. Rafay, D. Armstrong, G. DeVeber, T. Domi, A. Chan, and D. L. MacGregor, "Craniocervical arterial dissection in children: clinical and radiographic presentation and outcome," *Journal of Child Neurology*, vol. 21, no. 1, pp. 8–16, 2006.
- [52] L. R. MacClellan, W. Giles, J. Cole et al., "Probable migraine with visual aura and risk of ischemic stroke: the stroke prevention in young women study," *Stroke*, vol. 38, no. 9, pp. 2438–2445, 2007.
- [53] B. Morfin-Maciél, A. Medina, F. E. Rosales, R. Berrón, and J. Huerta López, "Central nervous system involvement in a child with polyarteritis nodosa and severe atopic dermatitis," *Revista Alergia Mexico*, vol. 49, no. 6, pp. 189–195, 2002.
- [54] C. E. Fields, T. C. Bower, L. T. Cooper et al., "Takayasu's arteritis: operative results and influence of disease activity," *Journal of Vascular Surgery*, vol. 43, no. 1, pp. 64–71, 2006.
- [55] W. D. Graf, J. M. Milstein, and D. D. Sherry, "Stroke and mixed connective tissue disease," *Journal of Child Neurology*, vol. 8, no. 3, pp. 256–259, 1993.
- [56] K. Honczarenko, L. Ostanek, H. Grzelec, A. Fabian, I. Fiedorowicz-Fabrycy, and C. Fryze, "Neurological deficits in patients with primary and secondary anticardiolipin

- syndrome," *Neurologia i Neurochirurgia Polska*, vol. 35, no. 3, pp. 395–404, 2001.
- [57] N. C. K. Tan, N. Venketasubramanian, S. M. Saw, and H. T. L. Tjia, "Hyperhomocyst(e)inemia and risk of ischemic stroke among young Asian adults," *Stroke*, vol. 33, no. 8, pp. 1956–1962, 2002.
- [58] M. N. Sheppard, "The heart in Fabry's disease," *Cardiovascular Pathology*, vol. 20, no. 1, pp. 8–14, 2011.
- [59] Z. Wang, X. K. Qi, S. Yao et al., "Phenotypic patterns of MELAS/LS overlap syndrome associated with m.13513G>A mutation, and neuropathological findings in one autopsy case," *Neuropathology*, vol. 30, no. 6, pp. 606–614, 2010.
- [60] R. Li and M. X. Guan, "Human mitochondrial leucyl-tRNA synthetase corrects mitochondrial dysfunctions due to the tRNA A3243G mutation, associated with mitochondrial encephalomyopathy, lactic acidosis, and stroke-like symptoms and diabetes," *Molecular and Cellular Biology*, vol. 30, no. 9, pp. 2147–2154, 2010.
- [61] D. Rea, J. F. Brandsema, D. Armstrong et al., "Cerebral arteriopathy in children with neurofibromatosis type 1," *Pediatrics*, vol. 124, no. 3, pp. e476–e483, 2009.
- [62] M. F. Rafay, A. M. Pontigon, J. Chiang et al., "Delay to diagnosis in acute pediatric arterial ischemic stroke," *Stroke*, vol. 40, no. 1, pp. 58–64, 2009.
- [63] D. K. Kiely, P. A. Wolf, L. A. Cupples, A. S. Beiser, and R. H. Myers, "Familial aggregation of stroke: the Framingham Study," *Stroke*, vol. 24, no. 9, pp. 1366–1371, 1993.
- [64] H. J. Fullerton, Y. W. Wu, S. Zhao, and S. C. Johnston, "Risk of stroke in children: ethnic and gender disparities," *Neurology*, vol. 61, no. 2, pp. 189–194, 2003.
- [65] I. Blom, E. L. L. M. De Schryver, L. J. Kappelle, G. J. E. Rinkel, A. Jennekens-Schinkel, and A. C. B. Peters, "Prognosis of haemorrhagic stroke in childhood: a long-term follow-up study," *Developmental Medicine and Child Neurology*, vol. 45, no. 4, pp. 233–239, 2003.
- [66] J. K. Lynch and C. J. Han, "Pediatric stroke: what do we know and what do we need to know?" *Seminars in Neurology*, vol. 25, no. 4, pp. 410–423, 2005.
- [67] W. D. Lo, J. Lee, J. Rusin, E. Perkins, and E. S. Roach, "Intracranial hemorrhage in children: an evolving spectrum," *Archives of Neurology*, vol. 65, no. 12, pp. 1629–1633, 2008.
- [68] T. J. Bernard and N. A. Goldenberg, "Pediatric arterial ischemic stroke," *Hematology/Oncology Clinics of North America*, vol. 24, no. 1, pp. 167–180, 2010.
- [69] D. A. Biehl, D. L. Stewart, N. H. Forti, and L. N. Cook, "Timing of intracranial hemorrhage during extracorporeal life support," *ASAIO Journal*, vol. 42, no. 6, pp. 938–941, 1996.
- [70] A. D. Meyer-Heim and E. Boltshauser, "Spontaneous intracranial haemorrhage in children: aetiology, presentation and outcome," *Brain and Development*, vol. 25, no. 6, pp. 416–421, 2003.
- [71] L. C. Jordan, J. T. Kleinman, and A. E. Hillis, "Intracerebral hemorrhage volume predicts poor neurologic outcome in children," *Stroke*, vol. 40, no. 5, pp. 1666–1671, 2009.
- [72] J. I. Suarez, R. W. Tarr, and W. R. Selman, "Aneurysmal subarachnoid hemorrhage," *The New England Journal of Medicine*, vol. 354, no. 4, pp. 387–396, 2006.
- [73] R. G. Wells, C. Vetter, and P. Laud, "Intracranial hemorrhage in children younger than 3 years: prediction of intent," *Archives of Pediatrics and Adolescent Medicine*, vol. 156, no. 3, pp. 252–257, 2002.
- [74] J. van Gijn and G. J. E. Rinkel, "Subarachnoid haemorrhage: diagnosis, causes and management," *Brain*, vol. 124, no. 2, pp. 249–278, 2001.
- [75] M. M. Adner, G. R. Fisch, S. G. Starobin, and R. H. Aster, "Use of "compatible" platelet transfusions in treatment of congenital isoimmune thrombocytopenic purpura," *The New England Journal of Medicine*, vol. 280, no. 5, pp. 244–247, 1969.
- [76] G. J. E. Rinkel and C. J. M. Klijn, "Prevention and treatment of medical and neurological complications in patients with aneurysmal subarachnoid haemorrhage," *Practical Neurology*, vol. 9, no. 4, pp. 195–209, 2009.
- [77] J. van Gijn, A. Hijdra, E. F. M. Wijdicks, M. Vermeulen, and H. van Crevel, "Acute hydrocephalus after aneurysmal subarachnoid hemorrhage," *Journal of Neurosurgery*, vol. 63, no. 3, pp. 355–362, 1985.
- [78] A. Chiriac, I. Poeta, J. Baldauf, and H. W. Schroeder, "Aneurysmal subarachnoid hemorrhage," *Revista medico-chirurgicala a Societatii de Medici si Naturalisti din Iasi*, vol. 114, no. 1, pp. 120–128, 2010.
- [79] J. W. Hop, G. J. E. Rinkel, A. Algra, and J. van Gijn, "Case-fatality rates and functional outcome after subarachnoid hemorrhage: a systematic review," *Stroke*, vol. 28, no. 3, pp. 660–664, 1997.
- [80] G. DeVeber, M. Andrew, C. Adams et al., "Cerebral sinovenous thrombosis in children," *The New England Journal of Medicine*, vol. 345, no. 6, pp. 417–423, 2001.
- [81] T. F. Barron, D. A. Gusnard, R. A. Zimmerman, and R. R. Clancy, "Cerebral venous thrombosis in neonates and children," *Pediatric Neurology*, vol. 8, no. 2, pp. 112–116, 1992.
- [82] K. S. Carvalho, J. B. Bodensteiner, P. J. Connolly, and B. P. Garg, "Cerebral venous thrombosis in children," *Journal of Child Neurology*, vol. 16, no. 8, pp. 574–580, 2001.
- [83] M. J. Rivkin, M. L. Anderson, and E. M. Kaye, "Neonatal idiopathic cerebral venous thrombosis: an unrecognized cause of transient seizures or lethargy," *Annals of Neurology*, vol. 32, no. 1, pp. 51–56, 1992.
- [84] A. Ameri and M. G. Bousser, "Cerebral venous thrombosis," *Neurologic Clinics*, vol. 10, no. 1, pp. 87–111, 1992.
- [85] A. K. Meena, K. S. Naidu, and J. M. K. Murthy, "Cortical sinovenous thrombosis in a child with nephrotic syndrome and iron deficiency anaemia," *Neurology India*, vol. 48, no. 3, pp. 292–294, 2000.
- [86] G. S bire, B. Tabarki, D. E. Saunders et al., "Cerebral venous sinus thrombosis in children: risk factors, presentation, diagnosis and outcome," *Brain*, vol. 128, no. 3, pp. 477–489, 2005.
- [87] S. L. Benedict, J. L. Bonkowsky, J. A. Thompson et al., "Cerebral sinovenous thrombosis in children: another reason to treat iron deficiency anemia," *Journal of Child Neurology*, vol. 19, no. 7, pp. 526–531, 2004.
- [88] T. H. Newton and C. A. Gooding, "Compression of superior sagittal sinus by neonatal calvarial molding," *Radiology*, vol. 115, no. 3, pp. 635–639, 1975.
- [89] D. Milhaud, C. Heroum, M. Charif, P. Saulnier, M. Pages, and J. M. Blard, "Dural puncture and corticotherapy as risks factors for cerebral venous sinus thrombosis," *European Journal of Neurology*, vol. 7, no. 1, pp. 123–124, 2000.
- [90] N. Muthukumar, "Uncommon cause of sinus thrombosis following closed mild head injury in a child," *Child's Nervous System*, vol. 21, no. 1, pp. 86–88, 2005.

- [91] S. O. Casey, R. A. Alberico, M. Patel et al., "Cerebral CT venography," *Radiology*, vol. 198, no. 1, pp. 163–170, 1996.
- [92] P. J. Macchi, R. I. Grossman, and J. M. Gomori, "High field MR imaging of cerebral venous thrombosis," *Journal of Computer Assisted Tomography*, vol. 10, no. 1, pp. 10–15, 1986.
- [93] M. D. Medlock, W. C. Olivero, W. C. Hanigan et al., "Children with cerebral venous thrombosis diagnosed with magnetic resonance imaging and magnetic resonance angiography," *Neurosurgery*, vol. 31, no. 5, pp. 870–876, 1992.
- [94] G. DeVeber, A. Chan, P. Monagle et al., "Anticoagulation therapy in pediatric patients with sinovenous thrombosis: a cohort study," *Archives of Neurology*, vol. 55, no. 12, pp. 1533–1537, 1998.
- [95] J. M. Ferro, P. Canhão, J. Stam, M. G. Bousser, and F. Barinagarrementeria, "Prognosis of cerebral vein and dural sinus thrombosis: results of the International Study on Cerebral Vein and Dural Sinus Thrombosis (ISCVT)," *Stroke*, vol. 35, no. 3, pp. 664–670, 2004.
- [96] S. Mehraein, K. Schmidtke, A. Villringer, J. M. Valdueza, and F. Masuhr, "Heparin treatment in cerebral sinus and venous thrombosis: patients at risk of fatal outcome," *Cerebrovascular Diseases*, vol. 15, no. 1-2, pp. 17–21, 2003.
- [97] J. S. Hutchison, R. Ichord, A. M. Guerguerian, and G. DeVeber, "Cerebrovascular disorders," *Seminars in Pediatric Neurology*, vol. 11, no. 2, pp. 139–146, 2004.
- [98] J. Hirsh, T. E. Warkentin, R. Raschke, C. Granger, E. M. Ohman, and J. E. Dalen, "Heparin and low-molecular-weight heparin: mechanisms of action, pharmacokinetics, dosing considerations, monitoring, efficacy, and safety," *Chest*, vol. 114, supplement 5, pp. 489S–510S, 1998.
- [99] L. Guédon-Moreau and S. Kacet, "Atrial fibrillation: challenge of antithrombotic treatment Les enjeux du traitement antithrombotique," *Annales de Cardiologie et d'Angéiologie*, vol. 58, no. 1, pp. S25–S30, 2009.
- [100] R. Kay, K. A. S. Wong, Y. L. Yu et al., "Low-molecular-weight heparin for the treatment of acute ischemic stroke," *The New England Journal of Medicine*, vol. 333, no. 24, pp. 1588–1593, 1995.
- [101] C. R. Burak, M. D. Bowen, and T. F. Barron, "The use of enoxaparin in children with acute, nonhemorrhagic ischemic stroke," *Pediatric Neurology*, vol. 29, no. 4, pp. 295–298, 2003.
- [102] G. DeVeber, "Paediatric stroke: who should be treated?" *Hamostaseologie*, vol. 29, no. 1, pp. 88–90, 2009.
- [103] M. D. Moharir, M. Shroff, D. Stephens et al., "Anticoagulants in pediatric cerebral sinovenous thrombosis a safety and outcome study," *Annals of Neurology*, vol. 67, no. 5, pp. 590–599, 2010.
- [104] I. Dawson, J. H. van Bockel, M. D. Ferrari, F. J. M. van der Meer, R. Brand, and J. L. Terpstra, "Ischemic and hemorrhagic stroke in patients on oral anticoagulants after reconstruction for chronic lower limb ischemia," *Stroke*, vol. 24, no. 11, pp. 1655–1663, 1993.
- [105] H. E. McCoy, C. C. Broder, and R. Lottenberg, "Streptokinases produced by pathogenic group C streptococci demonstrate species-specific plasminogen activation," *Journal of Infectious Diseases*, vol. 164, no. 3, pp. 515–521, 1991.
- [106] P. A. Andreasen, L. Kjølner, L. Christensen, and M. J. Duffy, "The urokinase-type plasminogen activator system in cancer metastasis: a review," *International Journal of Cancer*, vol. 72, no. 1, pp. 1–22, 1997.
- [107] A. Furlan, R. Higashida, L. Wechsler et al., "Intra-arterial prourokinase for acute ischemic stroke. The PROACT II study: a randomized controlled trial," *Journal of the American Medical Association*, vol. 282, no. 21, pp. 2003–2011, 1999.
- [108] C. S. Kase, A. J. Furlan, L. R. Wechsler et al., "Cerebral hemorrhage after intra-arterial thrombolysis for ischemic stroke: the PROACT II trial," *Neurology*, vol. 57, no. 9, pp. 1603–1610, 2001.
- [109] M. A. DeWood, J. Spores, and R. Notske, "Prevalence of total coronary occlusion during the early hours of transmural myocardial infarction," *The New England Journal of Medicine*, vol. 303, no. 16, pp. 897–902, 1980.
- [110] J. R. Marler, "Tissue plasminogen activator for acute ischemic stroke. The National Institute of Neurological Disorders and Stroke rt-PA Stroke Study Group," *The New England Journal of Medicine*, vol. 333, no. 24, pp. 1581–1587, 1995.
- [111] J. A. Zivin, P. D. Lyden, U. DeGirolami et al., "Tissue plasminogen activator. Reduction of neurologic damage after experimental embolic stroke," *Archives of Neurology*, vol. 45, no. 4, pp. 387–391, 1988.
- [112] H. Zeumer, H. J. Freitag, F. Zanella, A. Thie, and C. Arning, "Local intra-arterial fibrinolytic therapy in patients with stroke: urokinase versus recombinant tissue plasminogen activator (r-TPA)," *Neuroradiology*, vol. 35, no. 2, pp. 159–162, 1993.
- [113] K. L. Sullivan, G. A. Gardiner, M. J. Shapiro, J. Bonn, and D. C. Levin, "Acceleration of thrombolysis with a high-dose transthorbus bolus technique," *Radiology*, vol. 173, no. 3, pp. 805–808, 1989.
- [114] J. F. Meschia, D. A. Miller, and T. G. Brott, "Thrombolytic treatment of acute ischemic stroke," *Mayo Clinic Proceedings*, vol. 77, no. 6, pp. 542–551, 2002.
- [115] M. Wang, T. Hays, V. Balasa et al., "Low-dose tissue plasminogen activator thrombolysis in children," *Journal of Pediatric Hematology/Oncology*, vol. 25, no. 5, pp. 379–386, 2003.
- [116] D. W. Krieger and M. A. Yenari, "Therapeutic hypothermia for acute ischemic stroke: what do laboratory studies teach us?" *Stroke*, vol. 35, no. 6, pp. 1482–1489, 2004.
- [117] P. D. Gluckman, J. S. Wyatt, D. Azzopardi et al., "Selective head cooling with mild systemic hypothermia after neonatal encephalopathy: multicentre randomised trial," *The Lancet*, vol. 365, no. 9460, pp. 663–670, 2005.
- [118] T. S. Olsen, U. J. Weber, and L. P. Kammersgaard, "Therapeutic hypothermia for acute stroke," *The Lancet Neurology*, vol. 2, no. 7, pp. 410–416, 2003.
- [119] E. C. Wirrell, E. A. Armstrong, L. D. Osman, and J. Y. Yager, "Prolonged seizures exacerbate perinatal hypoxic-ischemic brain damage," *Pediatric Research*, vol. 50, no. 4, pp. 445–454, 2001.