

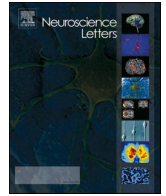


Since January 2020 Elsevier has created a COVID-19 resource centre with free information in English and Mandarin on the novel coronavirus COVID-19. The COVID-19 resource centre is hosted on Elsevier Connect, the company's public news and information website.

Elsevier hereby grants permission to make all its COVID-19-related research that is available on the COVID-19 resource centre - including this research content - immediately available in PubMed Central and other publicly funded repositories, such as the WHO COVID database with rights for unrestricted research re-use and analyses in any form or by any means with acknowledgement of the original source. These permissions are granted for free by Elsevier for as long as the COVID-19 resource centre remains active.

Contents lists available at [ScienceDirect](https://www.sciencedirect.com)

## Neuroscience Letters

journal homepage: [www.elsevier.com/locate/neulet](http://www.elsevier.com/locate/neulet)

## Neurological issues in children with COVID-19

Jieru E. Lin<sup>a,b</sup>, Arsenoi Asfour<sup>a,b</sup>, Taylor B. Sewell<sup>c</sup>, Benjamin Hooe<sup>c</sup>, Patrice Pryce<sup>c</sup>,  
 Chelsea Earley<sup>a,b</sup>, Min Ye Shen<sup>a,b</sup>, Mallory Kerner-Rossi<sup>a,b</sup>, Kiran T. Thakur<sup>d</sup>,  
 Wendy S. Vargas<sup>a</sup>, Wendy G. Silver<sup>a</sup>, Andrew S. Geneslaw<sup>c,\*</sup>

<sup>a</sup> Department of Neurology, Division of Child Neurology, Columbia University Irving Medical Center, New York, NY 10032, United States

<sup>b</sup> Department of Pediatrics, Columbia University Irving Medical Center, Morgan Stanley Children's Hospital, New York, NY 10032, United States

<sup>c</sup> Department of Pediatrics, Division of Pediatric Critical Care and Hospital Medicine, Columbia University Irving Medical Center, New York, NY 10032, United States

<sup>d</sup> Department of Neurology, Columbia University Irving Medical Center, New York, NY 10032, United States

## ARTICLE INFO

## Keywords:

COVID-19

Pediatrics

Multisystem inflammatory syndrome in children (MIS-C)

SARS-CoV-2

## ABSTRACT

Coronavirus disease 2019 (COVID-19) usually leads to a mild infectious disease course in children, but serious complications may occur in conjunction with both acute infection and associated phenomena such as the multisystem inflammatory syndrome in children (MIS-C). Neurological symptoms, which have been predominantly reported in adults, range from mild headache to seizure, peripheral neuropathy, stroke, demyelinating disorders, and encephalopathy. Similar to respiratory and cardiac manifestations of COVID-19, neurological complications present differently based on age and underlying comorbidities. This review provides a concise overview of the neurological conditions seen in the context of COVID-19, as well as potential mechanisms and long-term implications of COVID-19 in the pediatric population from literature reviews and primary data collected at NewYork-Presbyterian Morgan Stanley Children's Hospital.

## 1. Clinical observations in children

The severe acute respiratory syndrome coronavirus 2 (SARS-CoV-2) pandemic, causing coronavirus disease 2019 (COVID-19), has affected more than 30 million people worldwide [1]. More than 6 million cases have been reported in the United States as of September 2020 [1], with children comprising 8.4 % of reported cases [2]. Although respiratory symptoms and multisystem inflammatory syndrome in children (MIS-C) have predominated in both scientific and lay literature, neurological phenomena have also been associated with COVID-19. 28 % of pediatric COVID-19 patients in the United States experienced headaches [3]. Among children diagnosed with MIS-C in New York, 31–47 % experienced neurological symptoms, including headache, altered mental status, and encephalopathy [4,5]. Moreover, a multicenter study of children diagnosed with MIS-C across the United States found that 5 % suffered severe neurological complications, such as seizure, coma, encephalitis, demyelinating disorders, and aseptic meningitis [6]. In the United Kingdom, of 27 children with MIS-C, 4 had new-onset neurological symptoms, including encephalopathy, dysarthria, dysphagia, cerebellar ataxia, and peripheral neuropathy leading to global proximal

muscle weakness and reduced reflexes [7]. These children were between 8 and 15 years old, all had MRI or CT changes involving the splenium of the corpus callosum, and all presented with fever, shock, and rash. Reversible lesions of the corpus callosum have been observed in Kawasaki disease [8,9], as well as in other viral and inflammatory encephalopathies [10,11]. However, this UK case series did not include detailed information regarding the metabolic derangements experienced by these patients, which makes it somewhat challenging to interpret some of the more non-specific neurological symptoms, such as headache or fatigue (Fig. 1).

Encephalopathy has also been noted in infants and toddlers with COVID-19. Four out of five children younger than 3 months with positive nasal swabs for SARS-CoV-2 in a UK COVID-19 unit presented with axial hypotonia, drowsiness, or moaning. All five children had normal CSF studies, including cell counts, glucose and PCR for SARS-CoV-2, and were discharged within 3 days after rapid improvement [12]. At our own institution, a 6-week-old infant presented with one day of cough, fever, and 10-second episodes of leg stiffening with upward gaze deviation. Other than nasopharyngeal PCR swab positive for SARS-CoV-2 and an EEG showing temporal sharp waves and vertex delta slowing,

\* Corresponding author at: Section of Pediatric Critical Care Medicine, Division of Pediatric Critical Care and Hospital Medicine, Department of Pediatrics, Columbia University Irving Medical Center, CH 10N-24, 3959 Broadway, New York, NY 10032, United States.

E-mail address: [asg2195@cumc.columbia.edu](mailto:asg2195@cumc.columbia.edu) (A.S. Geneslaw).

<https://doi.org/10.1016/j.neulet.2020.135567>

Received 3 October 2020; Received in revised form 24 November 2020; Accepted 1 December 2020

Available online 19 December 2020

0304-3940/© 2020 Elsevier B.V. All rights reserved.

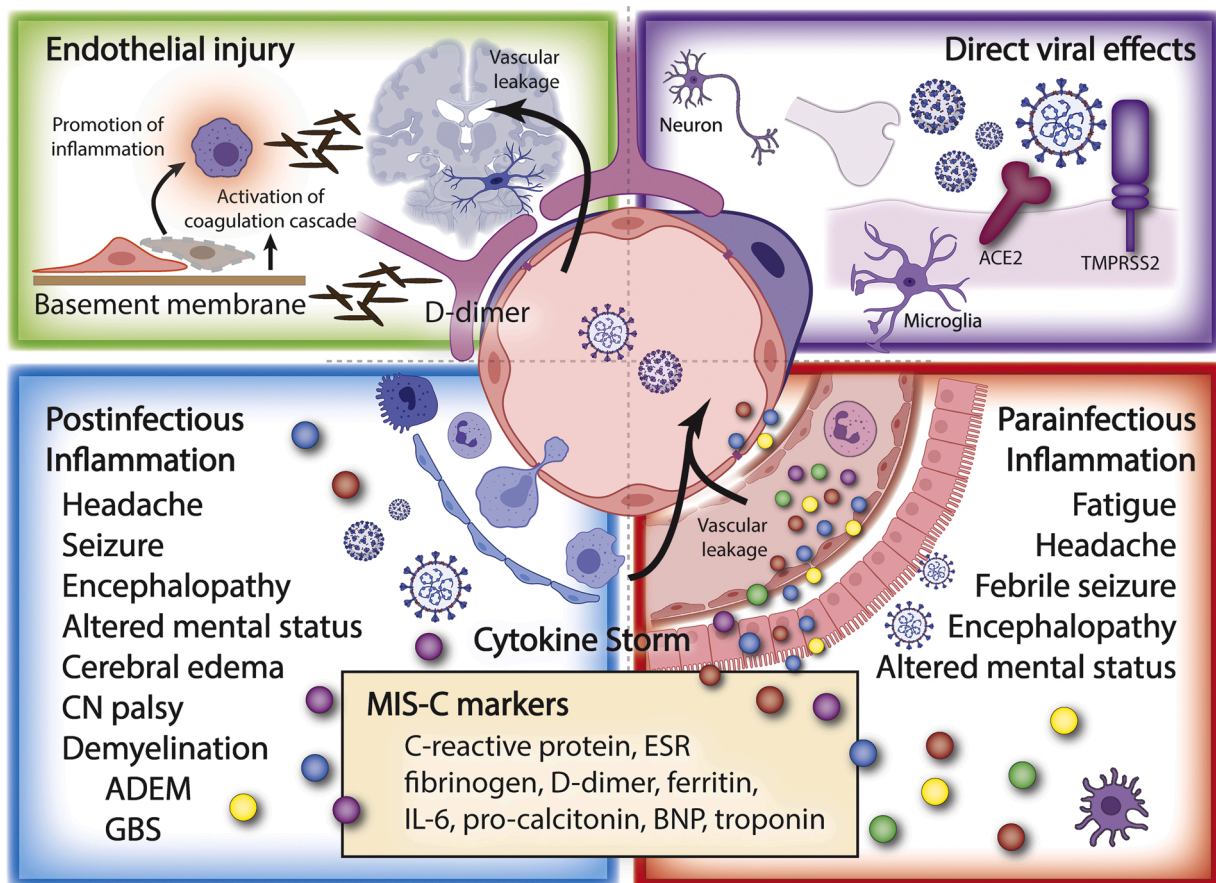
all other studies, including CSF and MRI, were unremarkable [13]. Also at our own institution, a 33-month old previously healthy boy was hospitalized with fever, rash, vomiting, pleural effusions, and decreased left ventricular function, and was diagnosed with MIS-C after COVID serology testing returned positive [14]. Six days into his hospitalization, he became somnolent, diffusely hypotonic, and weak. His CSF was unremarkable (including PCR testing for SARS-CoV-2), but EEG showed diffuse slowing, and MRI revealed diffusion restriction bilaterally in the lateral thalamic nuclei, consistent with a diagnosis of encephalopathy. His symptoms, imaging, and EEG findings improved over time and with ongoing treatment of MIS-C according to our institutional guideline, which involved steroids, intravenous immunoglobulin (IVIG), and anakinra.

More focal intracranial pathology, ranging from relatively benign to emergent, has been reported. Idiopathic intracranial hypertension and pseudotumor cerebri were noted in a 14-year-old girl with MIS-C and respiratory failure [15]. Another case report outlines devastating neurological sequelae possibly associated with pediatric COVID-19: a previously healthy 16-year-old boy positive for SARS-CoV-2 presented with aseptic meningitis, sphenoidal sinusitis, and cavernous sinus thrombosis on MRI. He sustained a middle cerebral artery stroke and despite adequate treatment for concurrent bacteremia, progressed to coma and ultimately brain death due to intracranial hypertension secondary to stenosis of all cerebral vessels [16].

A brief review of our own institution's records (approved by the Columbia University Irving Medical Center Institutional Review Board) shows that of 82 children (aged 5 days to 18 years) hospitalized between March 11th and June 10th, 2020 with laboratory-confirmed evidence of COVID-19, 35 (43 %) developed neurological symptoms. The most common symptoms included headache (n = 12, 34 %), fatigue or malaise (n = 9, 25 %), altered mental status (n = 8, 23 %), weakness (n = 5, 14 %), and seizure (n = 4, 11 %). Of note, 3 patients presented with cranial nerve VI palsy. Two of these patients also had intracranial hypertension. Only 2 patients reported dysgeusia or ageusia and only 1 patient suffered from a stroke. It should be noted that the median patient age was 9 years (IQR 4-15), which may affect the types of symptoms these patients and their parents can describe. Among patients with neurological symptoms, 12 (34 %) had PCR evidence of active SARS-CoV-2 infection, 19 (54 %) had a positive antibody test, and 4 (11 %) were simultaneously PCR- and antibody-positive. Among patients lacking neurological symptoms, 32 (68 %) had infection detected solely via SARS-CoV-2 PCR, whereas 6 (13 %) had a positive antibody test, and 9 (19 %) had both tests simultaneously positive. No children (0/10) had CSF that was positive for viral RNA via PCR testing.

## 2. Pathophysiology

Two cell membrane proteins are the major targets necessary for



**Fig. 1.** Hypothesized mechanisms of COVID-19 neurological manifestations.

Direct viral effects upon the nervous system, endothelial injury, and downstream effects of para- and post-infectious inflammation, have each been proposed as potential etiologies of the neurological manifestations of Coronavirus disease 2019 (COVID-19). Severe acute respiratory syndrome coronavirus 2 (SARS-CoV-2) may cross into the central nervous system (CNS) via a variety of mechanisms. Endothelial injury may precipitate thrombotic events, as well as release of virus and inflammatory mediators. Cytokine release due to pulmonary or systemic infection may instigate neurological sequelae. And, post-infectious inflammation induced by SARS-CoV-2 may trigger autoimmune phenomena, such as demyelinating disease and encephalopathy. The multisystem inflammatory syndrome in children associated with SARS-CoV-2 may represent a spectrum of para- and post-infectious complications, separate but similar to other inflammatory conditions in children known to sometimes present with neurological sequelae. ESR (erythrocyte sedimentation rate); BNP (B-type natriuretic peptide); IL-6 (interleukin 6).

SARS-CoV-2 invasion: angiotensin-converting enzyme 2 (ACE2) receptor, and transmembrane serine protease 2 (TMPRSS2) [17]. Both proteins can be expressed within the CNS, although the degree of expression is unclear. Animal models have demonstrated that neurons and glial cells express ACE2, and some glial cells express TMPRSS2 [18]. Transcriptomic work has shown low but consistent expression in various regions of the human brain [19] ACE2 has been demonstrated within vascular pericytes in the olfactory bulb [20] as well as the olfactory neuroepithelium [21]. In general, human data are lacking at this time. Extrapolating from these animal and basic science studies has led to proposed mechanisms by which COVID-19 might manifest neurological symptoms, including direct infection of the nervous system [22] and its vasculature, and inflammatory responses secondary to local and/or systemic infection [23,24]. Other proposed mechanisms include more indirect effects via cardiovascular complications [21], and cerebral hypoxia due to respiratory failure [25]. It is not currently known which of these mechanisms predominates in children, and we would stress that each is hypothesized and largely untested at this time.

### 2.1. Direct viral injury to neural cells

The virus has been hypothesized to directly invade olfactory nerves and cross into the CNS via the cribriform plate [26]. This has been experimentally demonstrated in other coronaviruses, such as Human Coronavirus OC43 (HCoV-OC43), which rapidly spreads throughout mouse CNS after intranasal inoculation, causing encephalitis and transient flaccid paralysis [27]. Similarly, severe acute respiratory syndrome coronavirus (SARS-CoV-1), which has 79 % homology with SARS-CoV-2 and very similar receptor-binding domain structure [28], rapidly spreads throughout the brains of transgenic mice after intranasal inoculation [29]. SARS-CoV-1 has also been frequently found in brain autopsy specimens of patients who succumbed to the SARS outbreak of 2003 [30]. Hypotheses based upon mechanisms of CNS damage by other viruses include delivery of virus by retrograde and anterograde transport through trigeminal and vagus nerves, dissemination from infected leukocytes after passing through the blood-brain barrier (BBB), and deployment from the epithelial or endothelial cells of the CNS vasculature and BBB after infection [31–33]. The development and maintenance of the BBB are supported and regulated by astrocytes, pericytes, microglia and extracellular matrix. The BBB and its constituent neurovascular units change both morphologically and on the molecular level with age [34]. These age-based changes represent another potential mechanism for differences in neurological effects between children and adults. The effect of direct SARS-CoV-2 infection on the BBB thus provides an interesting area of study. In particular, microglial development across the lifespan may provide insight into the mechanism of neuroplasticity and damage in childhood, given that microglia take on a phenotype consistent with a proinflammatory response as humans age [35].

Furthermore, the capillaries of the circumventricular organs are physiologically fenestrated, which could lead to vulnerability to both direct viral infection and inflammatory insults in the neurons and neuroglia in these areas [31,32]. However, this mechanism in particular should lead to caution when interpreting reports of viral antigen within CNS samples. Migration of immune cells that have engulfed any SARS-CoV-2 particles before entering the CNS could result in detection of viral material within the nervous system. Thus, the presence of SARS-CoV-2 RNA or protein fragments in the CNS does not necessarily imply neuroinvasive or neurotropic properties, nor causality of neurological symptoms. Underscoring this detail is that none of the pediatric patients at our institution (and to our knowledge, few if any in the literature) had detectable SARS-CoV-2 PCR from CSF samples. While quantitative reverse-transcriptase PCR (qRT-PCR) assays for SARS-CoV-2 are widely used and have standard curves indicating limits of detection (100 % sensitivity with  $10^{0.5}$  viral RNA copies per  $\mu\text{L}$ ) [36], it should be noted that these tests are validated for use in respiratory

samples and not in CSF. If SARS-CoV-2 is present in CSF in patients with neurological manifestations, it remains to be determined whether sufficient viral copies are present for detection, and whether lumbar puncture is performed at an optimal time to detect these viral copies. Other testing modalities, such as antibody detection, may in fact be more appropriate.

### 2.2. Vascular endothelial injury

COVID-19 has also been associated with cerebrovascular phenomena [37]. As outlined above, SARS-CoV-2 interacts with the ACE2 receptors expressed on vascular endothelial cells, which are expressed in varying levels in the CNS. These interactions between the virus and ACE receptors may trigger both pro-inflammatory and pro-coagulable states by initiating vasculitis and disruption of vascular integrity, perpetuating exposure of thrombogenic basement membrane, and activation of the clotting cascade [37,38]. Additionally, ACE-2 receptors in the CNS regulate the sympathoadrenal systems. Viral interference with ACE2 function in the CNS vasculature may disrupt the autoregulation of intracranial and systemic blood pressure [39]. While reports of thrombotic events in COVID-19 abound, with particular alarm raised regarding younger patients [24,40,41], it is unclear whether rates of ischemic stroke even in older adults are greatly elevated after adjusting for other, conventional cardiovascular risk factors such as hypertension and diabetes [42]. Regardless, these vascular phenomena have also been documented in children and young adults without past medical history [23], including one toddler with a pontine stroke at our own institution (unpublished data), but this association has yet to be confirmed by large studies or registries.

### 2.3. Inflammatory and autoimmune injury

The severity of COVID-19 and its sequelae correlate with aberrant and excessive inflammation mediated by innate and adaptive immune activation [43,44]. These para- and post-infectious inflammatory responses could potentially manifest as neurological symptoms. MIS-C is thought to be the consequence of hyperinflammatory responses after SARS-CoV-2 infection in genetically susceptible individuals [45]. Investigations of MIS-C have reported neurological symptoms in 12–58 % of affected children [46], but have rarely delved into the types of symptoms or whether they are out of proportion with illness severity. It does seem apparent that the metabolic and antibody responses present in children with SARS-CoV-2 and MIS-C differ, with the MIS-C group displaying different inflammatory profiles, antibody subtypes, and lower neutralizing antibody activity [47,48]. Children with delayed type I and type III interferon (IFN) responses after coronavirus infection may have a higher risk of developing cytokine storm and MIS-C [48]. High levels of interleukin-1 $\beta$  (IL-1 $\beta$ ), IL-6, IL-8, IL-10, IL-17, IFN- $\gamma$ , and differential T and B cell subset lymphopenia distinct from Kawasaki disease were observed in children during the acute phase of MIS-C [49]. Despite similarities in presentation between MIS-C and Kawasaki disease, this difference in immunophenotypes may explain the observed discrepancies in ethnic and age susceptibilities between the two diseases [5,50]. This hypothesized mechanism differs from the antibody-dependent enhancement (ADE) observed in Dengue virus, Human Immunodeficiency Virus, Ebola virus, Middle East Respiratory Syndrome Coronavirus (MERS-CoV), and SARS-CoV-1 [51]. In this model, pre-existing immunoglobulins with affinity for both virus and Fc receptors may function as a bridge to facilitate viral uptake and systemic dissemination after replication [52]. Although antibodies to the S proteins of SARS-CoV-1, MERS-CoV, and SARS-CoV-2 can cross-react, the low overall spread of the prior two illnesses makes investigating rates of ADE in world regions that suffered from these outbreaks challenging [53]. Arguing against ADE, however, is the observation that worsening of COVID-19 has not been reported in patients who received convalescent plasma, and that world regions that did undergo prior outbreaks of novel

coronaviruses have not generally experienced more severe COVID-19 than the rest of the world. [1,54].

The immune system hyperactivity that seems to characterize MIS-C is associated with high levels of inflammatory markers, such as C-reactive protein (CRP), erythrocyte sedimentation rate, fibrinogen, D-dimer, ferritin, IL-6, and and pro-calcitonin [4,5,49]. High levels of acute innate inflammatory markers have been associated with severe neurological insults in adult COVID-19 [55,56]. Pro-inflammatory cytokines, including IL-1 $\beta$ , IL-6, TNF $\alpha$ , and IL-17, can disrupt the BBB [57], activate glial cells, and further instigate neuroinflammation [55,56], leading to neuronal hyperexcitation and seizures [58], functional disturbance, fatigue, encephalopathy, loss of synapses, and even neuronal death [59]. Recent data have emerged linking severe COVID-19 in adults with autoantibodies against members of the type-I IFN family, which neutralized and prevented these cytokines from binding to their target receptors [60]. In some cases, these autoantibodies were present prior to infection, implying that some patients may have particular genetic or immune susceptibility to severe COVID-19. Whether this mechanism extends to other antibody-mediated phenomena, such as neurological injury, remains to be determined. Molecular mimicry may play a role in autoimmunity, and recent work has indicated that the SARS-CoV-2 spike protein is cross-reactive with myelin basic protein and S100B, among other proteins [58]. Lymphopenia may be the result of either bone marrow suppression [61,62] or migration into target tissues. Hypoxia, whether due to pulmonary or systemic disease, can also trigger an inflammatory CNS response without direct viral infection [63]. Chronic sequelae may ensue, as has been observed after past viral pandemics [64]. Neuroinflammation may precipitate depression and post-traumatic stress disorder (PTSD) by upregulating tryptophan degradation, resulting in a sequential decrease in 5-hydroxytryptamine and serotonin level, as well as dysregulating *N*-methyl-D-aspartate receptor activities [65].

The BBB was previously mentioned in the discussion of direct viral injury, but it also may be involved in inflammatory models of COVID-19 neurological manifestations. ACE2 is involved in the crosstalk between astrocytes and endothelium for BBB maintenance via posttranslational modification of occludin (a component of the tight junction) and its subcellular accumulation in lipid rafts [66,67]. Vessel-associated microglia maintain BBB integrity directly via tight-junction proteins and indirectly via interplay with its cellular and non-cellular components. Microglia activated by systemic inflammation are known to play an important role in disruption of the blood brain barrier [68]. In particular, the BBB is involved in multiple pathophysiological processes in neurodegenerative diseases and neurodevelopment [69], implying differential effects based upon patient age.

Guillain-Barré syndrome (GBS), a peripheral nervous system (PNS) demyelinating disease mediated by post-infectious autoimmune responses, has been associated with SARS-CoV-2 [70] and was responsive to typical intravenous immunoglobulin treatment [70,71]. Interestingly, the SARS-CoV-2 spike protein binds to sialic acid-containing glycoproteins and gangliosides on cell surfaces. Molecular mimicry between SARS-CoV-2 and gangliosides on the peripheral nerves may lead to autoimmunity [71]. Other coronaviruses have been documented in the acute brain lesions of patients with multiple sclerosis (MS) [72], and antibodies against Human Coronavirus (HCoV)-OC43 and HCoV-229E were isolated from CSF in MS patients [73]. T-cells cross-reacting with coronavirus and myelin basic protein may also contribute to demyelination [72].

### 3. Conclusions and future directions

Multiple reports in both adults and children have associated COVID-19 with a variety of central and peripheral neurological insults, ranging from mild symptoms such as headache and anosmia, to severe manifestations like stroke, seizure, and encephalopathy. While there may be commonalities among the effects of SARS-CoV-2 upon pediatric versus

adult populations, based only upon the staggering numbers of deceased and debilitated adults compared to the overall small number of affected children, it seems apparent that this disease affects adults and children differently. Some of this difference may be attributed to the generally milder course of pulmonary disease and fewer comorbidities in children. However, the ongoing development of a child's nervous system, with differential expression of cell receptor targets over time, suggests that there are likely windows of susceptibility to the various infectious and post-infectious mechanisms of COVID-19-related neurological injury. This necessitates studying these complications in the pediatric population, in conjunction with but separately from adults, as many aspects of the illness course may differ greatly. Indeed, the Global Consortium Study of Neurological Dysfunction in COVID-19 (GCS-NeuroCOVID), a multi-center investigation with which we partner, is engaged in precisely this type of research [18].

As opposed to the adult population, in whom pulmonary disease predominates, severe childhood COVID-19 seems more typified by an immune-mediated inflammatory response, with or without associated MIS-C. Our own institution's data supports this: two-thirds of patients with neurological manifestations had positive COVID-19 antibody testing, whether in isolation or in combination with PCR testing; whereas two-thirds of patients without neurological manifestations had only positive PCR testing, which is likely more indicative of active infection. Like many immune-mediated illnesses, symptoms may persist long after the acute viral trigger has cleared and may manifest in surprising ways. Underlying CNS or PNS diseases could be exacerbated via pathophysiological pathways involving inflammation, microglia activation, or concurrent viral or bacterial infections. The gut microbiome has been implicated in a range of neuropsychiatric diseases, including autism disorder, depression, attention deficit hyperactivity disorder, PTSD, multiple sclerosis, and certain types of leukodystrophy [74,75], with unresolved mechanisms in each. Disruptions of normal microbiota may similarly be involved in the neurological sequelae of COVID-19 infection.

The long-term impact on neurodevelopment after COVID-19 deserves further investigation. The timeline for resolution of neurological injury and emergence of long-term dysfunction, should it present, is still largely unclear, as this disease has been known to the world for less than a year. As time elapses and we broaden our understanding of this protean disease, we can only hope to offer patients both treatment for their symptoms and insight regarding their prognoses.

### Disclosures

All authors report that they have no disclosures relevant to this manuscript.

### Funding sources

This research did not receive any specific grant from funding agencies in the public, commercial, or not-for-profit sectors.

### Author contributions

Manuscript writing and revision: Lin, JE; Geneslaw, AS; Asfour, A; Silver, WG; Vargas, WS, Thakur, KT; Sewell, TB

Data collection and analysis: Geneslaw, AS; Hooe, B; Sewell, TB; Silver, WG; Vargas, WS; Earley, C; Shen, MY; Lin, JE; Asfour, A; Kerner-Rossi, M; Pryce, P.

### References

- [1] Johns Hopkins Coronavirus Resource Center, COVID-19 Dashboard by the center of systems Science and Engineering (CSSE) at John Hopkins University (JHU), <https://coronavirus.jhu.edu/map.html>, September 20, 2020.
- [2] Center of disease control and prevention, CDC COVID Data Tracker, <https://covid.cdc.gov/covid-data-tracker/#demographics>, September 20, 2020.

- [3] C.C.-R. Team, M.A. Jorden, S.L. Rudman, E. Villarino, S. Hoferka, M.T. Patel, K. Bemis, C.R. Simmons, M. Jespersen, J. Iberg Johnson, E. Mytty, K.D. Arends, J. J. Henderson, R.W. Mathes, C.X. Weng, J. Duchin, J. Lenahan, N. Close, T. Bedford, M. Boeckh, H.Y. Chu, J.A. England, M. Famulare, D.A. Nickerson, M.J. Rieder, J. Shendure, L.M. Starita, Evidence for limited early spread of COVID-19 within the United States, January–February 2020, *MMWR Morb. Mortal. Wkly. Rep.* 69 (2020) 680–684.
- [4] E.W. Cheung, P. Zachariah, M. Gorelik, A. Boneparth, S.G. Kernie, J.S. Orange, J. D. Milner, Multisystem inflammatory syndrome related to COVID-19 in previously healthy children and adolescents in New York City, *JAMA* 324 (2020) 294–296.
- [5] E.M. Dufort, E.H. Koumans, E.J. Chow, E.M. Rosenthal, A. Muse, J. Rowlands, M. A. Barranco, A.M. Maxted, E.S. Rosenberg, D. Easton, T. Udo, J. Kumar, W. Pulver, L. Smith, B. Hutton, D. Blog, H. Zucker, S. New York, C. Centers for Disease, T. Prevention Multisystem Inflammatory Syndrome in Children Investigation, Multisystem inflammatory syndrome in children in New York State, *N. Engl. J. Med.* 383 (2020) 347–358.
- [6] L.R. Feldstein, E.B. Rose, S.M. Horwitz, J.P. Collins, M.M. Newhams, M.B.F. Son, J. W. Newburger, L.C. Kleinman, S.M. Heidemann, A.A. Martin, A.R. Singh, S. Li, K. M. Tarquinio, P. Jaggi, M.E. Oster, S.P. Zackai, J. Gillen, A.J. Ratner, R.F. Walsh, J. C. Fitzgerald, M.A. Keenaghan, H. Alharash, S. Doymaz, K.N. Clouser, J. S. Giuliano Jr., A. Gupta, R.M. Parker, A.B. Maddux, V. Havalad, S. Ramsingh, H. Bukulmez, T.T. Bradford, L.S. Smith, M.W. Tenforde, C.L. Carroll, B.J. Riggs, S. J. Gertz, A. Daube, A. Lansell, A. Coronado Munoz, C.V. Hobbs, K.L. Marohn, N. B. Halasa, M.M. Patel, A.G. Randolph, C.-I. Overcoming, C.C.-R. Team, Multisystem inflammatory syndrome in U.S. children and adolescents, *N. Engl. J. Med.* 383 (2020) 334–346.
- [7] O. Abdel-Mannan, M. Eyre, U. Lobel, A. Bamford, C. Eltze, B. Hameed, C. Hemingway, Y. Hachohen, Neurologic and radiographic findings associated with COVID-19 infection in children, *JAMA Neurol.* (2020).
- [8] T. Sato, Y. Ushiroda, T. Oyama, A. Nakatomi, H. Motomura, H. Moriuchi, Kawasaki disease-associated MERS: pathological insights from SPECT findings, *Brain Dev.* 34 (2012) 605–608.
- [9] J. Takanashi, K. Shirai, Y. Sugawara, Y. Okamoto, T. Obonai, H. Terada, Kawasaki disease complicated by mild encephalopathy with a reversible splenic lesion (MERS), *J. Neurol. Sci.* 315 (2012) 167–169.
- [10] G.S. Soon, L.H. Rodan, S. Laughlin, R.M. Laxer, S. Benseler, E.D. Silverman, Reversible splenic lesion syndrome in pediatric systemic lupus erythematosus, *J. Rheumatol.* 39 (2012) 1698–1699.
- [11] H. Tada, J. Takanashi, A.J. Barkovich, H. Oba, M. Maeda, H. Tsukahara, M. Suzuki, T. Yamamoto, T. Shimono, T. Ichiyama, T. Taoka, O. Sohma, H. Yoshikawa, Y. Kohno, Clinically mild encephalitis/encephalopathy with a reversible splenic lesion, *Neurology* 63 (2004) 1854–1858.
- [12] N. Nathan, B. Prevost, H. Corvol, Atypical presentation of COVID-19 in young infants, *Lancet* 395 (2020) 1481.
- [13] R. Dugue, K.C. Cay-Martinez, K.T. Thakur, J.A. Garcia, L.V. Chauhan, S. H. Williams, T. Briese, K. Jain, M. Foca, D.K. McBrien, J.M. Bain, W.I. Lipkin, N. Mishra, Neurologic manifestations in an infant with COVID-19, *Neurology* 94 (2020) 1100–1102.
- [14] D. Abel, M.Y. Shen, Z. Abid, C. Hennigan, A. Boneparth, E.H. Miller, A. C. Uhlemann, D.K. McBrien, K. Thakur, W. Silver, J.M. Bain, Encephalopathy and bilateral thalamic lesions in a child with MIS-C associated with COVID-19, *Neurology* (2020).
- [15] L.D. Verkuil, G.T. Liu, V.L. Brahma, R.A. Avery, Pseudotumor cerebri syndrome associated with MIS-C: a case report, *Lancet* 396 (2020) 532.
- [16] M. Oualha, M. Bendavid, L. Berteloot, A. Corsia, F. Lesage, M. Vedrenne, E. Salvador, M. Grimaud, J. Chareyre, C. de Marcellus, L. Dupic, L. de Saint Blanquat, C. Heilbronner, D. Drummond, M. Castelle, R. Berthaud, F. Angoulvant, J. Toubiana, Y. Pinhas, P. Frange, G. Cheron, J. Fourgeaud, F. Moulin, S. Renolleau, Severe and fatal forms of COVID-19 in children, *Arch. Pediatr.* 27 (2020) 235–238.
- [17] M. Hoffmann, H. Kleine-Weber, S. Schroeder, N. Kruger, T. Herrler, S. Erichsen, T. S. Schiergens, G. Herrler, N.H. Wu, A. Nitsche, M.A. Muller, C. Drosten, S. Pohlmann, SARS-CoV-2 cell entry depends on ACE2 and TMPRSS2 and is blocked by a clinically proven protease inhibitor, *Cell* 181 (2020) 271–280, e278.
- [18] J. Frontera, S. Mainali, E.L. Fink, C.L. Robertson, M. Schober, W. Ziai, D. Menon, P. M. Kochanek, J.I. Suarez, R. Helbok, M. McNett, S.H. Chou, G.C.-N. Study, Global consortium study of neurological dysfunction in COVID-19 (GCS-NeuroCOVID): study design and rationale, *Neurocrit. Care* 33 (2020) 25–34.
- [19] R. Chen, K. Wang, J. Yu, D. Howard, L. French, Z. Chen, C. Wen, Z. Xu, The spatial and cell-type distribution of SARS-CoV-2 receptor ACE2 in human and mouse brain, *bioRxiv* (2020), 2020.2004.2007.030650.
- [20] D.H. Brann, T. Tsukahara, C. Weinreb, M. Lipovsek, K. Van den Berge, B. Gong, R. Chance, I.C. Macaulay, H.-j. Chou, R. Fletcher, D. Das, K. Street, H.R. de Bezieux, Y.-G. Choi, D. Risso, S. Dudoit, E. Purdom, J.S. Mill, R.A. Hachem, H. Matsunami, D.W. Logan, B.J. Goldstein, M.S. Grubb, J. Ngai, S.R. Datta, Non-neuronal expression of SARS-CoV-2 entry genes in the olfactory system suggests mechanisms underlying COVID-19-associated anosmia, *bioRxiv* (2020), 2020.2003.2025.009084.
- [21] Gupta, M.V. Madhavan, K. Sehgal, N. Nair, S. Mahajan, T.S. Sehrawat, B. Bickdeli, N. Ahluwalia, J.C. Ausiello, E.Y. Wan, D.E. Freedberg, A.J. Kirtane, S.A. Parikh, M. S. Maurer, A.S. Nordvig, D. Accilli, J.M. Bathon, S. Mohan, K.A. Bauer, M.B. Leon, H.M. Krumholz, N. Uriel, M.R. Mehra, M.S.V. Elkind, G.W. Stone, A. Schwartz, D. D. Ho, J.P. Bilezikian, D.W. Landry, Extrapulmonary manifestations of COVID-19, *Nat. Med.* 26 (2020) 1017–1023.
- [22] E. Song, C. Zhang, B. Israelow, A. Lu-Culligan, A.V. Prado, S. Skriabine, P. Lu, O.-E. Weizman, F. Liu, Y. Dai, K. Szigeti-Buck, Y. Yasumoto, G. Wang, C. Castaldi, J. Heltko, E. Ng, J. Wheeler, M.M. Alfajaro, E. Levvasseur, B. Fontes, N. G. Ravindra, D. Van Dijk, S. Mane, M. Gunel, A. Ring, S.A. Jaffar Kazmi, K. Zhang, C.B. Wilen, T.L. Horvath, I. Plu, S. Haik, J.-L. Thomas, A. Louvi, S.F. Farhadian, A. Huttner, D. Seilhean, N. Renier, K. Bilguvar, A. Iwasaki, Neuroinvasion of SARS-CoV-2 in human and mouse brain, *bioRxiv* (2020), 2020.2006.2025.169946.
- [23] E. Gulko, P. Overby, S. Ali, H. Mehta, F. Al-Mufti, W. Gomes, Vessel wall enhancement and focal cerebral arteriopathy in a pediatric patient with acute infarct and COVID-19 infection, *AJNR Am. J. Neuroradiol.* (2020).
- [24] F.A. Klok, M. Kruip, N.J.M. van der Meer, M.S. Arbous, D. Gommers, K.M. Kant, F. H.J. Kaptein, J. van Paassen, M.A.M. Stals, M.V. Huisman, H. Endeman, Incidence of thrombotic complications in critically ill ICU patients with COVID-19, *Thromb. Res.* 191 (2020) 145–147.
- [25] H.R. Niazkar, B. Zibae, A. Nasimi, N. Bahri, The neurological manifestations of COVID-19: a review article, *Neurol. Sci.* 41 (2020) 1667–1671.
- [26] Whittaker, M. Anson, A. Harky, Neurological Manifestations of COVID-19: a systematic review and current update, *Acta Neurol. Scand.* 142 (2020) 14–22.
- [27] H. Jacomy, P.J. Talbot, Vacuolating encephalitis in mice infected by human coronavirus OC43, *Virology* 315 (2003) 20–33.
- [28] R. Lu, X. Zhao, J. Li, P. Niu, B. Yang, H. Wu, W. Wang, H. Song, B. Huang, N. Zhu, Y. Bi, X. Ma, F. Zhan, L. Wang, T. Hu, H. Zhou, Z. Hu, W. Zhou, L. Zhao, J. Chen, Y. Meng, J. Wang, Y. Lin, J. Yuan, Z. Xie, J. Ma, W.J. Liu, D. Wang, W. Xu, E. C. Holmes, G.F. Gao, G. Wu, W. Chen, W. Shi, W. Tan, Genomic characterisation and epidemiology of 2019 novel coronavirus: implications for virus origins and receptor binding, *Lancet* 395 (2020) 565–574.
- [29] J. Netland, D.K. Meyerholz, S. Moore, M. Cassell, S. Perlman, Severe acute respiratory syndrome coronavirus infection causes neuronal death in the absence of encephalitis in mice transgenic for human ACE2, *J. Virol.* 82 (2008) 7264–7275.
- [30] J. Gu, E. Gong, B. Zhang, J. Zheng, Z. Gao, Y. Zhong, W. Zou, J. Zhan, S. Wang, Z. Xie, H. Zhuang, B. Wu, H. Zhong, H. Shao, W. Fang, D. Gao, F. Pei, X. Li, Z. He, D. Xu, X. Shi, V.M. Anderson, A.S. Leong, Multiple organ infection and the pathogenesis of SARS, *J. Exp. Med.* 202 (2005) 415–424.
- [31] M. Marshall, How COVID-19 can damage the brain, *Nature* 585 (2020) 342–343.
- [32] C. Bryce, Z. Grimes, E. Pujadas, S. Ahuja, M.B. Beasley, R. Albrecht, T. Hernandez, A. Stock, Z. Zhao, M. Al Rasheed, J. Chen, L. Li, D. Wang, A. Corben, K. Haines, W. Westra, M. Umphlett, R.E. Gordon, J. Reidy, B. Petersen, F. Salem, M. Fiel, S. M. El Jamil, N.M. Tsankova, J. Houldsworth, Z. Mussa, W.-C. Liu, B. Veremis, E. Sordillo, M. Gitman, M. Nowak, R. Brody, N. Harpaz, M. Merad, S. Gnjatic, R. Donnelly, P. Seigler, C. Keys, J. Cameron, I. Moultrie, K.-L. Washington, J. Treatman, R. Sebra, J. Jhang, A. Firpo, J. Lednicki, A. Paniz-Mondolfi, C. Cordon-Cardo, M. Fowkes, Pathophysiology of SARS-CoV-2: targeting of endothelial cells renders a complex disease with thrombotic microangiopathy and aberrant immune response. The Mount Sinai COVID-19 autopsy experience, *medRxiv* (2020), 2020.2005.2018.20099960.
- [33] Pezzini, A. Padovani, Lifting the mask on neurological manifestations of COVID-19, *Nat. Rev. Neurol.* (2020).
- [34] F. Erdo, L. Denes, E. de Lange, Age-associated physiological and pathological changes at the blood-brain barrier: a review, *J. Cereb. Blood Flow Metab.* 37 (2017) 4–24.
- [35] L. Sominsky, S. De Luca, S.J. Spencer, Microglia: Key players in neurodevelopment and neuronal plasticity, *Int. J. Biochem. Cell Biol.* 94 (2018) 56–60.
- [36] CDC 2019-Novel Coronavirus (2019-nCoV) Real-Time RT-PCR Diagnostic Panel, Instructions For Use. Centers for Disease Control and Prevention, Division of Viral Diseases. Atlanta, GA. CDC-006-00019: Revision 5. <https://www.fda.gov/media/134922/download>.
- [37] N. Labo, H. Ohnuki, G. Tosato, Vasculopathy and coagulopathy associated with SARS-CoV-2 infection, *Cells* 9 (2020).
- [38] L.A. Teuwen, V. Geldhof, A. Pasut, P. Carmeliet, COVID-19: the vasculature unleashed, *Nat. Rev. Immunol.* 20 (2020) 389–391.
- [39] J.M. Saavedra, Brain angiotensin II: new developments, unanswered questions and therapeutic opportunities, *Cell. Mol. Neurobiol.* 25 (2005) 485–512.
- [40] S. Nopp, F. Moik, B. Jilma, I. Pabinger, C. Ay, Risk of venous thromboembolism in patients with COVID-19: A systematic review and meta-analysis, *Research and Practice in Thrombosis and Haemostasis* n/a.
- [41] T.J. Oxley, J. Mocco, S. Majidi, C.P. Kellner, H. Shoirah, I.P. Singh, R.A. De Leacy, T. Shigematsu, T.R. Ladner, K.A. Yeager, M. Skliut, J. Weinberger, N.S. Dangayach, J.B. Bederson, S. Tuhim, J.T. Fifi, Large-vessel stroke as a presenting feature of Covid-19 in the young, *N. Engl. J. Med.* 382 (2020) e60.
- [42] Rothstein, O. Oldridge, H. Schwennesen, D. Do, B.L. Cucchiara, Acute cerebrovascular events in hospitalized COVID-19 patients, *Stroke* 51 (2020) e219–e222.
- [43] Huang, Y. Wang, X. Li, L. Ren, J. Zhao, Y. Hu, L. Zhang, G. Fan, J. Xu, X. Gu, Z. Cheng, T. Yu, J. Xia, Y. Wei, W. Wu, X. Xie, W. Yin, H. Li, M. Liu, Y. Xiao, H. Gao, L. Guo, J. Xie, G. Wang, R. Jiang, Z. Gao, Q. Jin, J. Wang, B. Cao, Clinical features of patients infected with 2019 novel coronavirus in Wuhan, China, *Lancet* 395 (2020) 497–506.
- [44] G. Schett, M. Sticherling, M.F. Neurath, COVID-19: risk for cytokine targeting in chronic inflammatory diseases? *Nat. Rev. Immunol.* 20 (2020) 271–272.
- [45] A.H. Rowley, Understanding SARS-CoV-2-related multisystem inflammatory syndrome in children, *Nat. Rev. Immunol.* 20 (2020) 453–454.
- [46] Kaushik, S. Gupta, M. Sood, S. Sharma, S. Verma, A systematic review of multisystem inflammatory syndrome in children associated with SARS-CoV-2 infection, *Pediatr. Infect. Dis. J.* (2020).
- [47] C.N. Gruber, R.S. Patel, R. Trachtman, L. Lepow, F. Amanat, F. Krammer, K. M. Wilson, K. Onel, D. Geanon, K. Tuballes, M. Patel, K. Mouskas, T. O'Donnell, E. Merritt, N.W. Simons, V. Barcessat, D.M. Del Valle, S. Udendem, G. Kang, S. Gangadharan, G. Ofori-Amanfo, U. Laserson, A. Rahman, S. Kim-Schulze, A. W. Charney, S. Gnjatic, B.D. Gelb, M. Merad, D. Bogunovic, Mapping systemic

- inflammation and antibody responses in multisystem inflammatory syndrome in children (MIS-C), *Cell* (2020).
- [48] S.P. Weisberg, T. Connors, D.L. Farber, et al., Distinct antibody responses to SARS-CoV-2 in children and adults across the COVID-19 clinical spectrum, *Nat. Immunol.* 22 (2021) 25–31, <https://doi.org/10.1038/s41590-020-00826-9>.
- [49] M.J. Carter, M. Fish, A. Jennings, K.J. Doores, P. Wellman, J. Seow, S. Acors, C. Graham, E. Timms, J. Kenny, S. Neil, M.H. Malim, S.M. Tibby, M. Shankar-Hari, Peripheral immunophenotypes in children with multisystem inflammatory syndrome associated with SARS-CoV-2 infection, *Nat. Med.* (2020).
- [50] Vepa, J.P. Bae, F. Ahmed, M. Pareek, K. Khunti, COVID-19 and ethnicity: a novel pathophysiological role for inflammation, *Diabetes Metab. Syndr.* 14 (2020) 1043–1051.
- [51] Y. Wan, J. Shang, S. Sun, W. Tai, J. Chen, Q. Geng, L. He, Y. Chen, J. Wu, Z. Shi, Y. Zhou, L. Du, F. Li, Molecular mechanism for antibody-dependent enhancement of coronavirus entry, *J. Virol.* 94 (2020).
- [52] H. Ulrich, M.M. Pillat, A. Tarnok, Dengue fever, COVID-19 (SARS-CoV-2), and antibody-dependent enhancement (ADE): a perspective, *Cytometry A* 97 (2020) 662–667.
- [53] A.M. Arvin, K. Fink, M.A. Schmid, A. Cathcart, R. Spreafico, C. Havenar-Daughton, A. Lanzavecchia, D. Corti, H.W. Virgin, A perspective on potential antibody-dependent enhancement of SARS-CoV-2, *Nature* 584 (2020) 353–363.
- [54] E.H. Lau, C.A. Hsiung, B.J. Cowling, C.H. Chen, L.M. Ho, T. Tsang, C.W. Chang, C. A. Donnelly, G.M. Leung, A comparative epidemiologic analysis of SARS in Hong Kong, Beijing and Taiwan, *BMC Infect. Dis.* 10 (2010) 50.
- [55] F.A. Lagunas-Rangel, Neutrophil-to-lymphocyte ratio and lymphocyte-to-C-reactive protein ratio in patients with severe coronavirus disease 2019 (COVID-19): a meta-analysis, *J. Med. Virol.* (2020).
- [56] J. Helms, S. Kremer, H. Merdji, R. Clere-Jehl, M. Schenck, C. Kummerlen, O. Collange, C. Boulay, S. Fafi-Kremer, M. Ohana, M. Anheim, F. Meziani, Neurologic features in severe SARS-CoV-2 infection, *N. Engl. J. Med.* 382 (2020) 2268–2270.
- [57] R. Dantzer, Neuroimmune interactions: from the brain to the immune system and vice versa, *Physiol. Rev.* 98 (2018) 477–504.
- [58] Rana, A.E. Musto, The role of inflammation in the development of epilepsy, *J. Neuroinflammation* 15 (2018) 144.
- [59] M. Schwartz, A. Deczkowska, Neurological disease as a failure of brain-immune crosstalk: the multiple faces of neuroinflammation, *Trends Immunol.* 37 (2016) 668–679.
- [60] P. Bastard, L.B. Rosen, Q. Zhang, E. Michailidis, H.H. Hoffmann, Y. Zhang, K. Dorgham, Q. Philippot, J. Rosain, V. Beziat, J. Manry, E. Shaw, L. Haljasmagi, P. Peterson, L. Lorenzo, L. Bizien, S. Trouillet-Assant, K. Dobbs, A.A. de Jesus, A. Belot, A. Kallaste, E. Catherinot, Y. Tandjaoui-Lambiotte, J. Le Pen, G. Kerner, B. Bigio, Y. Seeleuthner, R. Yang, A. Bolze, A.N. Spaan, O.M. Delmonte, M.S. Abers, A. Aiuti, G. Casari, V. Lampasona, L. Piemonti, F. Ciceri, K. Bilguvar, R.P. Lifton, M. Vasse, D.M. Smadja, M. Migaud, J. Hadjadj, B. Terrier, D. Duffy, L. Quintana-Murci, D. van de Beek, L. Rousset, D.C. Vinh, S.G. Tangye, F. Haerynck, D. Dalmau, J. Martinez-Picado, P. Brodin, M.C. Nussenzweig, S. Boisson-Dupuis, C. Rodriguez-Gallego, G. Vogt, T.H. Mogensen, A.J. Oler, J. Gu, P.D. Burbelo, J.I. Cohen, A. Biondi, L.R. Bettini, M. D'Angio, P. Bonfanti, P. Rossignol, J. Mayaux, F. Rieux-Laucat, E.S. Husebye, F. Fusco, M.V. Ursini, L. Imberti, A. Sottini, S. Paghera, E. Quiros-Roldan, C. Rossi, R. Castagnoli, D. Montagna, A. Licari, G.L. Marseglia, X. Duval, J. Ghosh, H. Lab, N.-U.I.R.t.C. Group, C. Clinicians, C.-S. Clinicians, C.G. Imagine, C.C.S.G. French, C. Milieu Interieur, V.C.C. Co, U.M.C.C.-B. Amsterdam, C. H.G. Effort, J.S. Tsang, R. Goldbach-Mansky, K. Kisand, M.S. Lionakis, A. Puel, S. Y. Zhang, S.M. Holland, G. Gorochov, E. Jouanguy, C.M. Rice, A. Cobat, L. D. Notarangelo, L. Abel, H.C. Su, J.L. Casanova, Autoantibodies against type I IFNs in patients with life-threatening COVID-19, *Science* 370 (2020).
- [61] R. Sankowski, S. Mader, S.I. Valdes-Ferrer, Systemic inflammation and the brain: novel roles of genetic, molecular, and environmental cues as drivers of neurodegeneration, *Front. Cell. Neurosci.* 9 (2015) 28.
- [62] H. Kettenmann, U.K. Hanisch, M. Noda, A. Verkhratsky, Physiology of microglia, *Physiol. Rev.* 91 (2011) 461–553.
- [63] C.T. Taylor, G. Doherty, P.G. Fallon, E.P. Cummins, Hypoxia-dependent regulation of inflammatory pathways in immune cells, *J. Clin. Invest.* 126 (2016) 3716–3724.
- [64] E.A. Troyer, J.N. Kohn, S. Hong, Are we facing a crashing wave of neuropsychiatric sequelae of COVID-19? Neuropsychiatric symptoms and potential immunologic mechanisms, *Brain Behav. Immun.* 87 (2020) 34–39.
- [65] H. Hori, Y. Kim, Inflammation and post-traumatic stress disorder, *Psychiatry Clin. Neurosci.* 73 (2019) 143–153.
- [66] B. Obermeier, R. Daneman, R.M. Ransohoff, Development, maintenance and disruption of the blood-brain barrier, *Nat. Med.* 19 (2013) 1584–1596.
- [67] K. Wosik, R. Cayrol, A. Dodelet-Devillers, F. Berthelet, M. Bernard, R. Mounjdjian, A. Bouthillier, T.L. Reudelhuber, A. Prat, Angiotensin II controls occludin function and is required for blood brain barrier maintenance: relevance to multiple sclerosis, *J. Neurosci.* 27 (2007) 9032–9042.
- [68] H. Thurgur, E. Pinteaux, Microglia in the neurovascular unit: blood-brain barrier-microglia interactions after central nervous system disorders, *Neuroscience* 405 (2019) 55–67.
- [69] M.D. Sweeney, Z. Zhao, A. Montagne, A.R. Nelson, B.V. Zlokovic, Blood-brain barrier: from physiology to disease and back, *Physiol. Rev.* 99 (2019) 21–78.
- [70] S. Abu-Rumeileh, A. Abdelhak, M. Foschi, H. Tuman, M. Otto, Guillain-Barre syndrome spectrum associated with COVID-19: an up-to-date systematic review of 73 cases, *J. Neurol.* (2020).
- [71] M.C. Dalakas, Guillain-Barre syndrome: the first documented COVID-19-triggered autoimmune neurologic disease: more to come with myositis in the offing, *Neurol. Neuroimmunol. Neuroinflamm.* 7 (2020).
- [72] M. Cataldi, G. Pignataro, M. Tagliatela, Neurobiology of coronaviruses: potential relevance for COVID-19, *Neurobiol. Dis.* 143 (2020), 105007.
- [73] Salmi, B. Ziola, T. Hovi, M. Reunanen, Antibodies to coronaviruses OC43 and 229E in multiple sclerosis patients, *Neurology* 32 (1982) 292–295.
- [74] T. Zuo, F. Zhang, G.C.Y. Lui, Y.K. Yeoh, A.Y.L. Li, H. Zhan, Y. Wan, A.C.K. Chung, C.P. Cheung, N. Chen, C.K.C. Lai, Z. Chen, E.Y.K. Tso, K.S.C. Fung, V. Chan, L. Ling, G. Joynt, D.S.C. Hui, F.K.L. Chan, P.K.S. Chan, S.C. Ng, Alterations in gut microbiota of patients with COVID-19 during time of hospitalization, *Gastroenterology* 159 (2020) 944–955, e948.
- [75] J.F. Cryan, K.J. O'Riordan, K. Sandhu, V. Peterson, T.G. Dinan, The gut microbiome in neurological disorders, *Lancet Neurol.* 19 (2020) 179–194.