

Case Report

Supraglottic NUT Carcinoma: A Case Report and Literature Review

Masaaki Higashino^a Ichita Kinoshita^a Yoshitaka Kurisu^b Ryo Kawata^a

^aDepartment of Otorhinolaryngology, Head and Neck Surgery, Osaka Medial and Pharmaceutical University, Takatsuki City, Osaka, Japan; ^bDepartment of Pathology, Osaka Medial and Pharmaceutical University, Takatsuki City, Osaka, Japan

Keywords

NUT carcinoma · Larynx · Ovarian metastasis

Abstract

Nuclear protein of the testis (NUT) carcinoma is a very rare cancer that occurs in relatively young patients. In this study, we experienced a case of laryngeal NUT carcinoma that followed a rapid course. A 22-year-old woman was diagnosed with supraglottic squamous cell carcinoma, cT3N2bM0. She underwent chemoradiotherapy (CRT) (total dose, 70 Gy; 2 Gy × 35 Fr; 80 mg/m² every 3 weeks with CDDP) as a curative treatment and achieved a complete response. However, 3 weeks after the completion of CRT, she presented to the outpatient clinic complaining of abdominal pain. Magnetic resonance imaging revealed a huge neoplastic lesion in the right ovary. Abdominal right adnexal resection plus partial retreatment was performed. The pathology of ovarian tumor was poorly differentiated squamous cell carcinoma, and NUT protein was positive. The laryngeal carcinoma was also positive for NUT protein; therefore, we diagnosed ovarian tumor is metastasis from supraglottic carcinoma. Peritoneal dissemination was observed in the early postoperative period. She was refractory to subsequent chemotherapy and had a rapid progression. Subsequently, CT showed further thickening of the peritoneum, increased ascites, and increased metastases. She died 32 weeks after initial diagnosis and 14 weeks after abdominal surgery. NUT carcinoma is difficult to diagnose without suspicion. Therefore, the possibility of NUT carcinoma should be considered in young patients with laryngeal carcinoma.

© 2022 The Author(s).
Published by S. Karger AG, Basel

Introduction

Laryngeal cancer is rare among young women but more common in men in their 60s and 70s because of risk factors, such as smoking and drinking. Nuclear protein of the testis (NUT) carcinoma, which is positive for the NUT gene, has been attracting attention recently [1]. NUT carcinoma is characterized by a high supradiaphragmatic midline incidence in relatively young patients. Histopathologically, it resembles a poorly differentiated squamous cell carcinoma. Generally, NUT carcinomas are resistant to anticancer drugs. In this study, we report a case of NUT carcinoma in a woman in her 20s, who underwent chemoradiotherapy (CRT) for laryngeal cancer and developed CR with subsequent ovarian metastasis.

Case Report

The patient was a 22-year-old woman who had visited our department for a sore throat in the past 2 weeks. She had no history of smoking or alcohol consumption. She also had no history of exposure to secondhand smoke. Laryngoscopy revealed an ulcerated mass on the right laryngeal arytenoid (Fig. 1a). The vocal fold movement was good. Suspecting upper respiratory tract inflammation, antibacterial agents and steroids were administered; however, a laryngoscopy done 2 weeks later revealed an enlarged tumor. Blood tests at the first visit showed WBC 3560/ μ L (neutrophils 56.8%, lymphocytes 33.4%), CRP 0.01 mg/dL, SCC 0.9 ng/mL

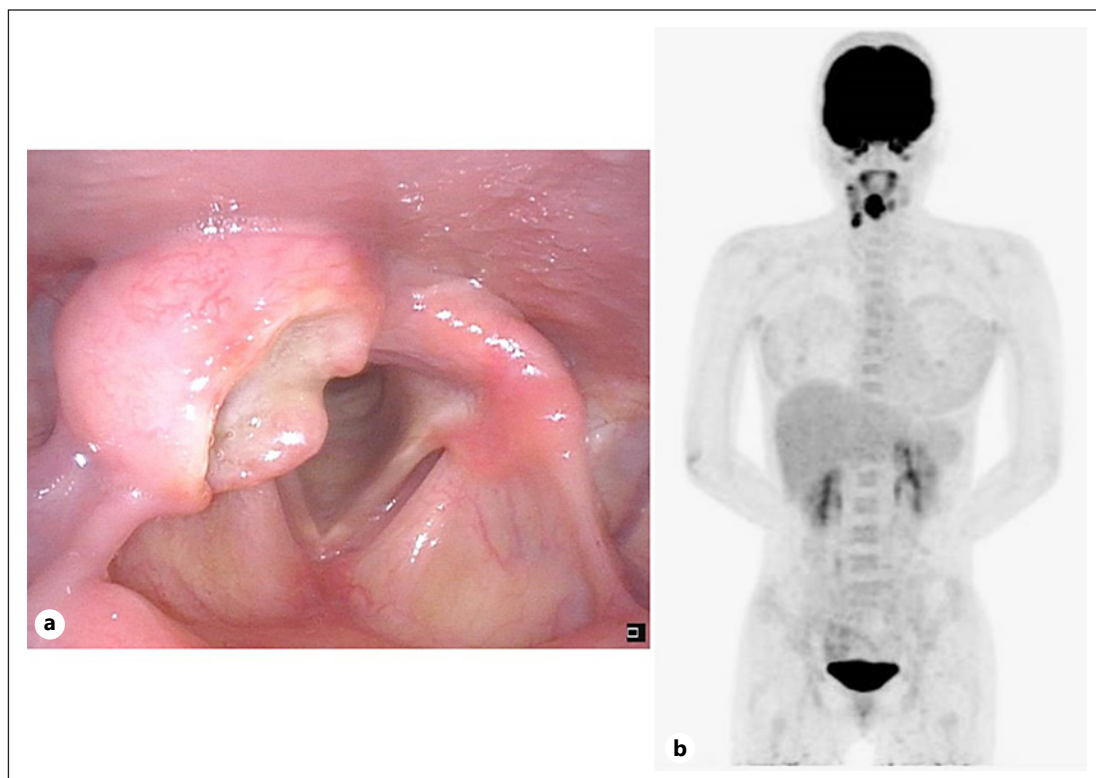


Fig. 1. Findings on initial examination. Ulcerated swelling in the right laryngeal arytenoid shown by laryngeal endoscopy (shown in **a**). SUVmax of the larynx (early 11.15, late 12.63), multiple SUVmax values of the right cervical lymph nodes (Lv II: early 6.02, late 6.79 Lv III: early 9.72, late 10.84), and FDG accumulation in pretreatment FDG-PET (shown in **b**).

(<1.5 ng/mL), sIL-2R 239 U/mL (122-496 u/mL), and no inflammatory findings. A laryngeal endoscopic biopsy was performed under local anesthesia; however, no malignant findings were obtained. Therefore, a biopsy was performed under general anesthesia 4 weeks after the initial diagnosis.

On admission, her right vocal fold was fixed. Under general anesthesia, a biopsy of the right laryngeal arytenoid was obtained, and histopathological examination revealed possible squamous cell carcinoma with poorly differentiated or undifferentiated histology (Fig. 4a). Immunostaining was positive for pan-CK, CD34, p40, p53, and p16; negative for EBER, TTF-1, CD56, synaptophysin, and chromogranin. Fluorodeoxyglucose positron emission tomography (FDG-PET) showed FDG accumulation in the larynx and right neck with no other accumulations (Fig. 1b). Therefore, she was diagnosed with a right supraglottic carcinoma, cT3N2bM0. Chemoradiotherapy (CRT) (total dose, 70 Gy; 2 Gy × 35 Fr; 80 mg/m² every 3 weeks with CDDP) was performed. At the end of CRT, laryngoscopy findings showed CR.

Three weeks after the completion of CRT, she presented to the outpatient clinic complaining of abdominal pain that was diagnosed as nonsteroidal anti-inflammatory drug-induced acute gastritis. However, the abdominal pain worsened. Upper gastrointestinal endoscopy revealed no abnormalities. Three days later, she visited the emergency room because of worsening abdominal pain. Magnetic resonance imaging revealed a huge neoplastic lesion in the right ovary (Fig. 2). Blood tests showed CA125 of 125.0 U/mL (≤35.0), SCC (1.4 ng/mL, CA19-9 (30.8 U/mL (≤37.0), AFP of 2.2 U/mL (≤7.0), and CEA of 1.3 ng/mL (≤5.0). The following day, abdominal right adnexal resection plus partial retreatment was performed. Histopathological results showed overall undifferentiated and monotonous cell proliferation with no squamous cell carcinoma component. However, AE1/AE, CD34, p40, and p53 were positive; CK20, TTF-1, PAX-8, inhibin, CD30, CD56, synaptophysin, and chromogranin were negative; and the Ki-67 index was 70%. Since the poorly differentiated area of the laryngeal and ovarian tumor had similar morphology with poorly differentiated cells with a high N/C ratio (Fig. 4b) and similar immunostaining findings, a diagnosis of ovarian metastasis of supraglottic carcinoma was made.

A CT scan taken 3 weeks after abdominal surgery showed findings suggestive of peritoneal dissemination. Laryngeal endoscopy revealed no residual tumors. FDG-PET performed 4 weeks after surgery showed that the accumulation in the larynx and right neck had disappeared; however, accumulations were seen in the intra-abdominal lymph nodes, periaortic lymph nodes, liver, and the left venous angle. We made a diagnosis of multiple intra-abdominal recurrences and Virchow's metastases (Fig. 3a, b). Cetuximab and paclitaxel were administered 2 weeks after FDG-PET. After the administration of cetuximab, she experienced an infusion reaction and required intramuscular adrenaline. Nivolumab 240 mg/2 weeks was started the following week. However, she readmitted 3 weeks after the initiation of nivolumab therapy because of worsening abdominal pain and dyspnea. Immunohistochemical staining for NUT protein was performed on the laryngeal and ovarian tumors, and both were positive for the NUT protein (Fig. 4c, d). Subsequently, CT showed further thickening of the peritoneum, increased ascites, and increased metastases. She died 32 weeks after initial diagnosis and 14 weeks after abdominal surgery.

Discussion/Conclusion

The laryngeal cancer is more common in elderly men who smoke and consume alcohol. In a report of the Head and Neck Cancer Registry of Japan for the 5-year period, from 2013 to 2017, there were 10,474 cases of laryngeal cancer, and only 745 (7.1%) were women [2]. Only 39 (0.37%) cases of laryngeal cancer were found in the younger age-groups: 2 cases were younger than 10 years, 1 case was between 10 and 19 years, 3 cases were between 20 and

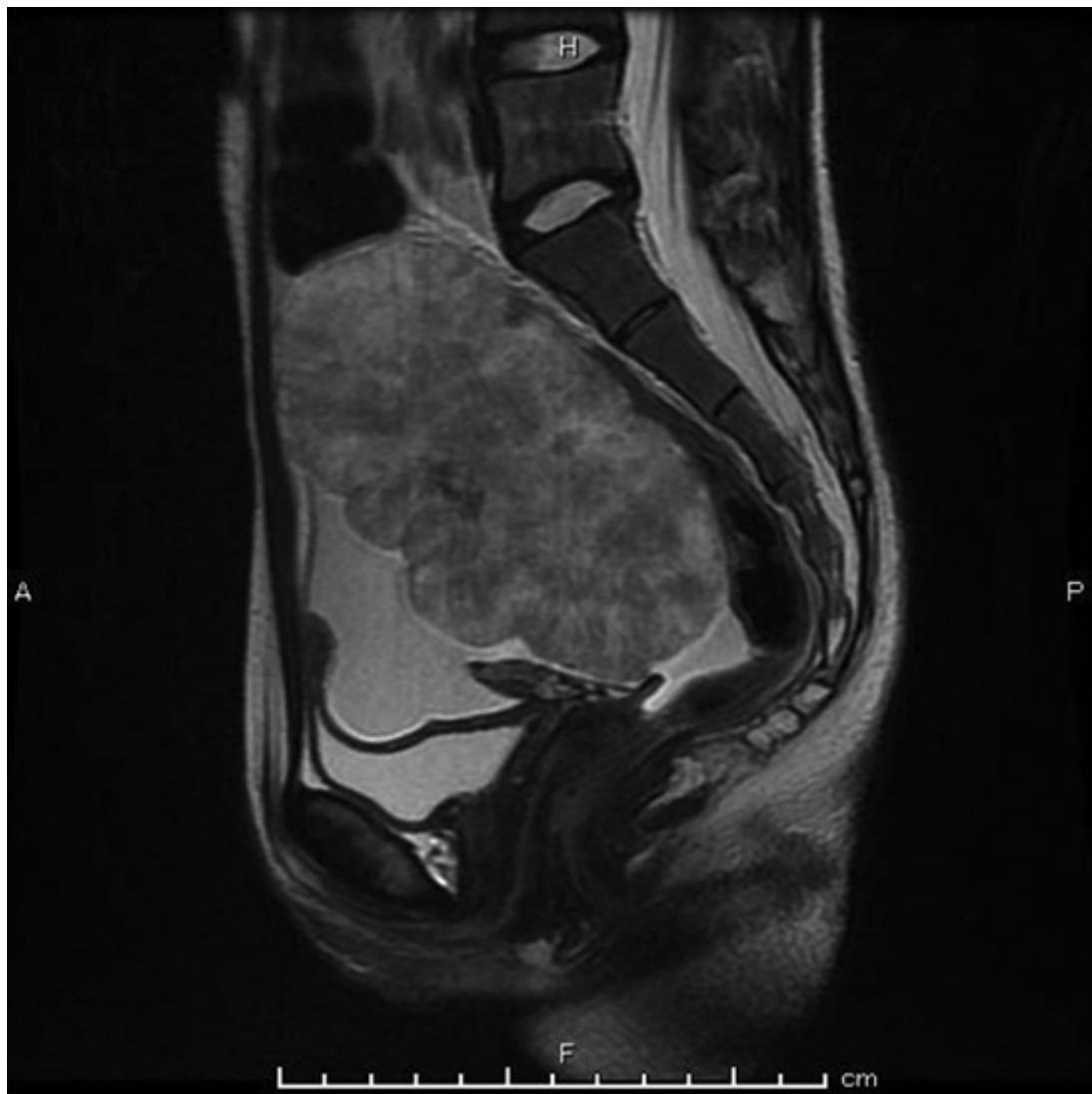


Fig. 2. Contrast-enhanced MRI of the abdomen. A large neoplastic lesion, approximately 12 cm in size, with a heterogeneous contrast effect was observed in the right ovary (shown in Fig. 2). MRI, magnetic resonance imaging.

29 years, and 33 cases were between 30 and 39 years. Among the 39 patients aged <40 years, 11 (28.2%) were female, which is a relatively high percentage. As for the subsite, only 5 cases (12.8%) were supraglottic. In the SEER database of 24,827 patients, young laryngeal carcinoma was relatively more common in women, and the glottic type was the most common. Although advanced carcinoma is more common in young patients, prognosis is good due to less distant metastasis and better response to RT [3]. In the present case, she had supraglottic carcinoma, no history of smoking, and no previous medical history.

In head and neck cancer, distant metastasis is usually rare at the initial treatment stage, and even in locally advanced squamous cell carcinoma of the head and neck, the 5-year distant control rate is 85% [4]. The most common sites of distant metastases from the head and neck region are the lungs (80%), bones (30%), lymph nodes other than those of the neck and liver (20%), skin, and pleura (10%) [5]. In contrast, NUT carcinoma progresses rapidly and is often widely metastatic at the time of diagnosis. Prognosis is extremely poor, with most high-grade

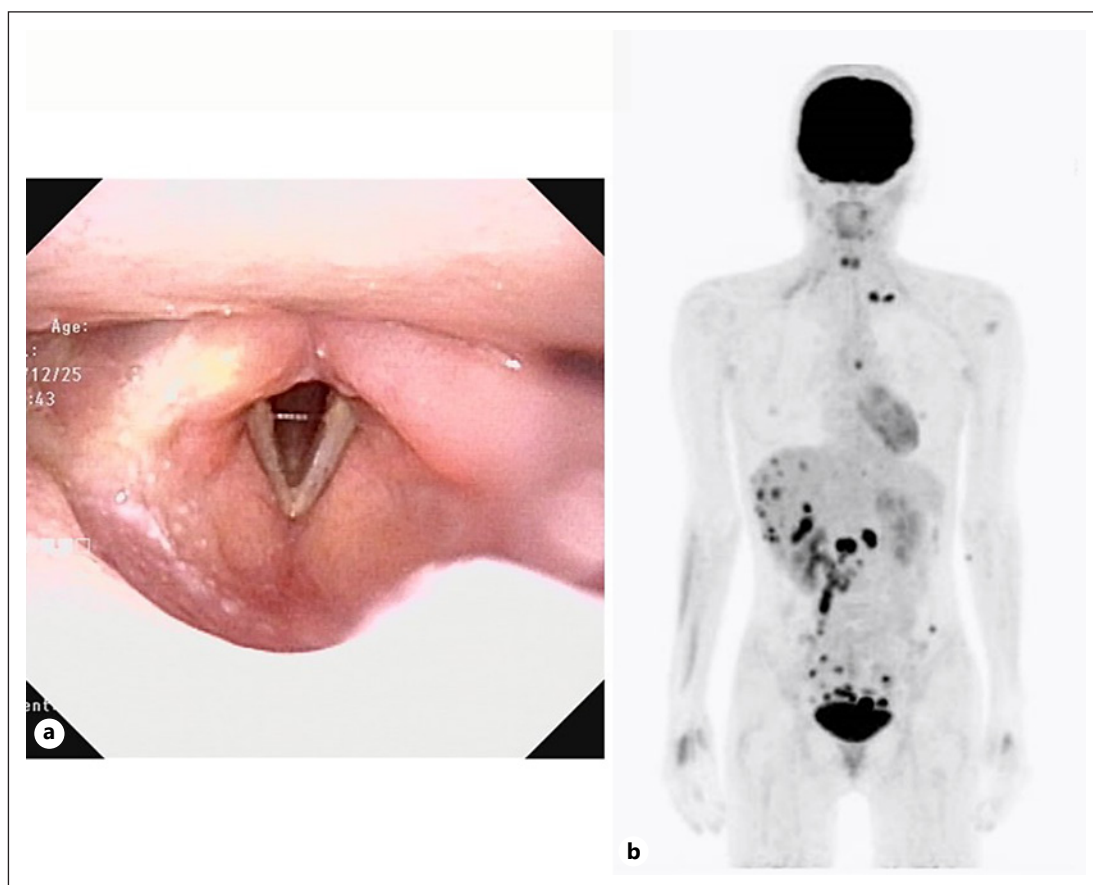


Fig. 3. Two months after CRT and 1 month after abdominal surgery. The tumor in the right laryngeal region disappeared, and vocal fold movement was good by laryngeal endoscopy (shown in **a**). FDG accumulation in the larynx and right neck disappeared in posttreatment FDG-PET. However, FDG accumulation was found in the intra-abdominal lymph nodes, periaortic lymph nodes, liver, and the left venous angle. Multiple intra-abdominal recurrences and Virchow metastases were diagnosed (shown in **b**).

tumors resulting in death within 6 months. Most tumors develop at an advanced stage (lymph node metastasis, bone metastasis, and carcinomatous pleurisy) [6]. At time of initial treatment of NUT carcinoma, 39.8% of patients had distant metastasis; its presence was associated with a significantly worse prognosis [7]. Subsequently, distant recurrence is observed in approximately 80% of recurrent cases that can be confirmed [8]. NUT carcinoma is characterized by a median age of 23 years, with a high prevalence of patients in their 20s; however, there is no gender difference [7]. The most common primary sites of NUT carcinoma are the lungs, head, neck, and mediastinum. Among the head and neck regions, the nasal sinuses are the most common, and laryngeal primary NUT carcinoma is very rare [9]. The laryngeal primary subsite is all over the glottis [10]. The median survival time for head and neck NUT carcinomas is 5 months, with a 1-year survival rate of 29.26% and a 5-year survival rate of 0% [7]. NUT carcinomas are epithelial tumors caused by translocation of the NUT gene on the long arm of chromosome 15, mainly due to BRD4-NUT gene fusion. Since reconstitution of the NUT gene alone also causes tumorigenesis, it has been speculated that the NUT gene, not the BRD4 protein, is responsible for tumorigenesis [11]. On the other hand, BRD4 is a chromatin-binding bromodomain and extra-terminal (BET) protein, which points to its potential as a BET inhibitor [12, 13]. When poorly differentiated squamous cell carcinomas

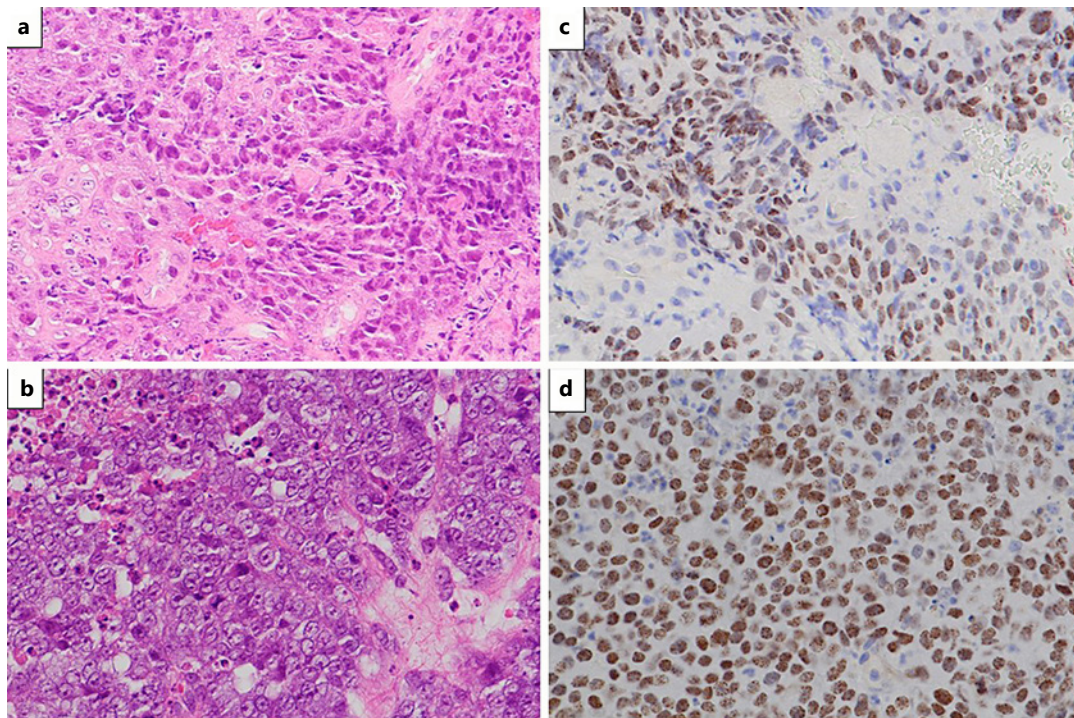


Fig. 4. Pathology of laryngeal and metastatic ovarian tumors. Histology of the laryngeal tumor: On the left side, large cells with eosinophilic cytoplasm are arranged in part, in a paving stone pattern. On the right side, small cells with a high nucleocytoplasmic ratio were observed, resembling poorly differentiated squamous cell carcinoma ($\times 200$) (shown in **a**). Histological findings of an ovarian tumor: diffuse growth of cells with a high nucleocytoplasmic ratio and large nuclei ($\times 400$) (shown in **b**). Immunostaining of laryngeal tumor with the NUT antibody; many cells were positive in the nucleus ($\times 200$) (shown in **c**). Immunostaining of ovarian tumor with the NUT antibody. Most of the nuclei show a positive image with a speckled pattern ($\times 400$) (shown in **d**).

and adenocarcinomas are reviewed, some are diagnosed as NUT carcinomas. In a review of 46 cases of head and neck NUT carcinoma, it was reported that only 35% were diagnosed as NUT carcinoma at the time of initial diagnosis, and the rest were diagnosed as poorly differentiated carcinoma, poorly differentiated squamous cell carcinoma, or undifferentiated carcinoma [14]. In the present case, the biopsy tissue of the larynx was also diagnosed as poorly differentiated squamous cell carcinoma.

The coexistence of laryngeal preservation and radical cure is a major issue in the treatment of advanced laryngeal cancer. In this case, she and her family strongly desired laryngeal preservation; hence, RT with CDDP was performed. After the first dose of CDDP, the tumor rapidly reduced, vocal fold movement improved, and the regional and metastatic lymph nodes were in CR after CRT. Therefore, it can be considered that the sensitivity to CDDP and RT was good in this case. However, metastasis to the ovaries soon occurred. Although the ovary is a common site for metastasis of tumors originating from other organs, reports of ovarian metastasis from the head and neck region are extremely rare. Only 1 case of mucoepidermoid carcinoma of the parotid gland has been reported [15]; thus, this is the first report on ovarian metastasis of head and neck squamous cell carcinoma. This may be because squamous cell carcinoma of the head and neck is often associated with smoking and drinking and is more common in elderly men. In the present case, she was refractory to drug treatment for distant metastasis. Subsequently, peritoneal dissemination and Virchow's metastasis were observed, and she died 8 months after initial diagnosis.

In conclusion, we report the case of a young woman with supraglottic carcinoma. It is a rare primary laryngeal NUT carcinoma. She developed ovarian metastasis at an early stage, which was refractory to treatment. Therefore, it is necessary to consider the possibility of NUT carcinoma in young patients with supraglottic carcinoma.

Statement of Ethics

The protocol for this human study was approved by the Ethics Committee of the Osaka Medical and Pharmaceutical University, Takatsuki, Japan (Approval number: 2032-2), as per the Helsinki Declaration of 1975, which was revised in 1983. Written informed consent was obtained from the patient and patient's next of kin for the publication of this case report and the accompanying images.

Conflict of Interest Statement

The authors have no conflicts of interest to declare.

Funding Sources

There is no funding.

Author Contributions

Masaaki Higashino contributed to the design of the report, collected data, and drafted the manuscript. Ichita Kinoshita collected data. Yoshitaka Kurisu collected the pathological data, and Ryo Kawata approved the final version of the manuscript.

Data Availability Statement

All data generated or analyzed during this study are included in this article. Further inquiries can be directed to the corresponding author.

References

- 1 Bhajjee F, Pepper DJ, Pitman KT, Bell D. New developments in the molecular pathogenesis of head and neck tumors: a review of tumor-specific fusion oncogenes in mucoepidermoid carcinoma, adenoid cystic carcinoma, and NUT midline carcinoma. *Ann Diagn Pathol*. 2011;15:69-77.
- 2 Japan Society for Head and Neck Cancer. Report of head and neck cancer Registry of Japan, clinical statistics of registered patients. 2016. Available from: <http://www.jshnc.umin.ne.jp/report.html>.
- 3 Li R, Yu S, Zhu W, Wang S, Yan L. Studying the impact of young age on prognosis and treatment in laryngeal squamous cell carcinomas using the SEER Database. *PeerJ*. 2019;7(7):e7368.
- 4 Pignon JP, le Maître A, Maillard E, Bourhis J. Meta-analysis of chemotherapy in head and neck cancer (MACH-NC): an update on 93 randomised trials and 17,346 patients. *Radiother Oncol*. 2009;92(1):4-14.
- 5 Duprez F, Berwouts D, De Neve W, Bonte K, Boterberg T, Deron P, et al. Distant metastases in head and neck cancer. *Head Neck*. 2017;39(9):1733-43.
- 6 Stelow EB. A review of NUT midline carcinoma. *Head Neck Pathol*. 2011;5(1):31-5.
- 7 Giridhar P, Mallick S, Kashyap L, Rath GK. Patterns of care and impact of prognostic factors in the outcome of NUT midline carcinoma: a systematic review and individual patient Data analysis of 119 cases. *Eur Arch Otorhinolaryngol*. 2018;275(3):815-21.

- 8 French CA. NUT Carcinoma: clinicopathologic features, pathogenesis, and treatment. *Pathol Int*. 2018;68:583–95.
- 9 Stelow EB, Bellizzi AM, Taneja K, Mills SE, Legallo RD, Kutok JL, et al. NUT rearrangement in undifferentiated carcinomas of the upper aerodigestive tract. *Am J Surg Pathol*. 2008;32:828–34.
- 10 Hellquist H, French CA, Bishop JA, Coca-Pelaz A, Propst EJ, Paiva Correia AP, et al. NUT midline carcinoma of the larynx: an international series and review of the literature. *Histopathology*. 2017;70(6):861–8.
- 11 Napolitano M, Venturelli M, Molinaro E, Toss A. NUT midline carcinoma of the head and neck: current perspectives. *Onco Targets Ther*. 2019;12:3235–44.
- 12 Piha-Paul SA, Hann CL, French CA, Cousin S, Braña I, Cassier PA, et al. Phase 1 Study of Molibresib (GSK525762), a bromodomain and extra-terminal domain protein inhibitor, in NUT carcinoma and other solid tumors. *JNCI Cancer Spectr*. 2019;64(2):pkz093.
- 13 Eagen KP, French CA. Supercharging BRD4 with NUT in carcinoma. *Oncogene*. 2021;40(8):1396–408.
- 14 Chau NG, Hurwitz S, Mitchell CM, Aserlind A, Grunfeld N, Kaplan L, et al. Intensive treatment and survival outcomes in NUT midline carcinoma of the head and neck. *Cancer*. 2016;122(23):3632–40.
- 15 Buyukkurt S, Altintas A, Gumurdulu D, Zeren Z, Guzel B. Mucoepidermoid carcinoma of the parotid gland with ovarian and peritoneal metastasis. *J Obstet Gynaecol Res*. 2008;34(2):271–3.