

Safe and accurate placement of thoracic and thoracolumbar percutaneous pedicle screws without image-navigation

Shahid M. Nimjee, Isaac O. Karikari¹, A. B. Carolyn A. Hardin¹, Jonathan Choi¹, Ciaran J. Powers, Christopher R. Brown², Robert E. Isaacs¹

Department of Neurosurgery, Ohio State University, Columbus, Ohio, ¹Department of Surgery, Division of Neurosurgery, ²Department of Orthopaedic Surgery, Duke University Medical Center, Durham, North Carolina, USA

ABSTRACT

Background: Percutaneous pedicle screw placement is now commonly used to treat spinal instability. It is imperative, especially at thoracic levels, to avoid damage to adjacent neurovascular structures. Although more technically demanding when compared with the lumbar spine, we believe that the percutaneous placement of thoracic pedicle screws can be performed safely without image-navigation.

Purpose: The purpose was to evaluate the safety of percutaneous pedicle screw placement in the thoracic and thoracolumbar spine without image-navigation.

Study Design/Setting: A retrospective study at a single institution.

Patient Sample: Patients over the age of 18 years who presented with degenerative disease, trauma or tumor that required surgical stabilization.

Outcome Measures: Our outcomes included postoperative plain film X-rays and computerized tomography (CT).

Materials and Methods: We performed a retrospective study of patients who underwent percutaneous pedicle screw placement without image-navigation between T2 and L2.

Results: Between 2005 and 2011, a total of 507 pedicle screws were placed in 120 patients. The indications included trauma (17%), tumor (8%), and degenerative conditions (75%). The mean age was 61.3 years (range: 20–81 years). Fifty-seven percent were male, and 43% were female. The mean blood loss was 297 ± 40 ml. All patients underwent postoperative anterior-posterior and lateral films that showed safe placement of pedicle screws. Moreover, 57% of patients underwent postoperative CT imaging. There was 1 (0.4%) medial breach and 13 (5%) lateral breaches of the pedicle screw patients who underwent CT imaging as read by an independent neuroradiologist. None of the breaches resulted in adverse neurological sequelae either immediately after or at most recent follow-up.

Conclusion: Thoracic and thoracolumbar percutaneous pedicle screw placement can be performed safely and accurately without image-navigation.

Key words: Pedicle screw, percutaneous, thoracic spine

Access this article online

Quick Response Code:



Website:

www.asianjns.org

DOI:

10.4103/1793-5482.162700

Introduction

Percutaneous pedicle screw placement was first described by Magerl.^[1] Since his description, the use of percutaneous pedicle screws has been expanded to include the treatment of spinal instability secondary to trauma, degenerative disease and metastases.^[2,3] Percutaneous pedicle screw placement has theoretical advantages over open surgery, including decreased tissue dissection, less blood loss and less postoperative pain.^[4] Not infrequently, percutaneous pedicle screws are placed using intra-operative navigation.^[5-9]

Address for correspondence:

Dr. Shahid M. Nimjee, 410 W 10th Avenue Columbus, Ohio 43210, USA. E-mail: shahid.nimjee@osumc.edu

Recent evidence shows that percutaneous pedicle screws can be placed without intraoperative navigation, and that single c-arm fluoroscopy is sufficient for successful placement at the lumbar and the lumbosacral junction.^[2,10,11] In this study, we present our experience with the safety and accuracy of placing percutaneous pedicle screws at the thoracic and thoracolumbar spine without the aid of a navigation system.

Materials and Methods

We performed a retrospective study of 120 patients that underwent 507 percutaneous pedicle screw placements between 2005 and 2011. The procedures were all performed at a single institution by the senior author REI and CB. This study was approved by the Institutional Review Board at Duke University Medical Center.

Patient selection

Patients were selected for minimally-invasive surgery based on preoperative plain films, computerized tomography (CT) and/or magnetic resonance imaging studies. The indications included trauma, neoplasm (including primary and metastatic lesions), and degenerative disease. Within each indication, diagnoses included burst fracture, chance fracture, fracture-dislocation, scoliosis, spondylolisthesis, adjacent-level disease, failed back syndrome, recurrent disc herniation, nonunion, tumor, and pathologic compression fracture.

Screw placement was performed in a standard operating room with only the aid of single plane fluoroscopy as previously described.^[2]

All patients underwent standard postoperative anterior-posterior (A-P) and lateral load-bearing films, which included sitting or standing X-rays. Although we do not routinely obtain postoperative CT scan to evaluate hardware placement, in 57% of patients in this study we obtained CT images as part of the assessment of fusion or for some other indication.

Procedure

Percutaneous pedicle screw placement was performed as outlined by Powers *et al.*^[2] Briefly, patients were placed in the prone position on a Jackson table. The superior end plate of the level of instrumentation, or Ferguson angle was obtained using fluoroscopy. After marking this, an A-P view, or on-pedicle view was obtained and recorded. This process was repeated for every level requiring instrumentation. Finally, an oblique image of each pedicle was obtained that was 10° lateral, otherwise known as an owl-eye view was obtained in order to insert the K-wires for pedicle screw placement.

Using the owl-eye view, a Jamsheedi needle was placed in the center of the pedicle and slightly countersunk in order to provide a guide for K-wire insertion. The K-wire was advanced 2 cm into the pedicle. Placement was verified using

A-P and lateral films. Once verified, the fluoroscope was kept in the lateral position, and the K-wires were advanced to mid-vertebral body.

The screws were placed over the K-wires. Briefly, the paraspinal musculature was dilated, and an awl was used to breach the cortical bone of the pedicle. A path for the screw was made using a cannulated tap and then the screw itself was placed. This was verified using a lateral fluoroscopic image. The K-wire was then removed. The screw was then advanced into final position.

Imaging

All of the patients underwent load-bearing, upright A-P and lateral X-rays postoperatively. In addition, approximately 57% underwent CT scans at some point during their postoperative course. All imaging was reviewed independently by a neuroradiologist.

Follow-up

All patients were seen postoperatively to assess their wound and clinical outcome.

Statistical analysis

Where appropriate, all averages were expressed as a mean \pm standard error of the mean.

Results

From May 2005 to November 2011, CRB and REI operated on 120 patients and placed 507 percutaneous pedicle screws without image-navigation [Table 1]. Sixty-eight patients

Table 1: Demographics of patients undergoing percutaneous pedicle screw placement

	(%)
Pedicle screws (number)	507
Patients	120
Indication	
Trauma	20 (17)
Tumor	10 (8)
Degenerative	90 (75)
Age (years)	
Mean	61.3
Range	20-81
Sex	
Male	68 (57)
Female	52 (43)
Blood loss (ml)	
Mean	297
CT (number)	68 (57)
Medial breach	1 (0.4)
Lateral breach	13 (5)
Follow-up (weeks)	36.4
Range	1-203

CT – Computerized tomography

were male, and 52 patients were female. The mean age was 61.3 years (range: 20–81 years). Indications for surgery included trauma (20), tumor (10) and degenerative (90).

The levels included in this series were between T2 and L2 [Figure 1]. There were a total of 230 thoracic pedicle screws placed (T2 = 2, T3 = 5, T4 = 6, T5 = 2, T6 = 6, T7 = 12, T8 = 14, T9 = 22, T10 = 38, T11 = 54, T12 = 69). There were 277 lumbar pedicle screws placed (L1 = 108, L2 = 169).

The average blood loss was 297 ± 40 ml. Three patients in this study received blood intraoperatively. One patient was anemic preoperatively with a hematocrit of 31 and lost 500 ml of blood intraoperatively. The other two had normal hematocrit levels and intraoperative blood loss > 1000 ml.

All the patients underwent A-P and lateral films, and showed appropriate placement of all hardware [Figure 2]. Sixty-eight patients (57%) underwent CT scans at some point in their postoperative course [Figure 3]. This accounted for 249 (49%) of the 507 screws. Imaging was evaluated independently by a neuroradiologist. There was 1 (0.4%) medial breach and 13 (5%) lateral breaches. The mean follow-up was 36.4 weeks (range: 1–203 weeks). There were no neural, vascular, visceral complications or deaths. There was no screw malposition that required reoperation, and none of the patients experienced new neurological symptoms at the level of surgery postoperatively or at follow-up.

Discussion

The ability to perform percutaneous pedicle screw placement at spinal cord levels safely and accurately without complex image-navigation presents several advantages over the traditional approaches. Our results demonstrate the feasibility of achieving spinal cord level pedicle screw instrumentation without navigation.

While plain X-rays do not definitely determine the accuracy of placement of screws, gross malposition can be easily noticed and can serve as adequate means of evaluating hardware postoperatively. In a patient with new neurological symptoms or worsening back pain however, it may be prudent to obtain CT images to better visualize the accuracy of screw placement. In this study, we did not encounter any obvious malposition of screws on postoperative plain X-rays. Our series revealed 0.4% medial breach and 5% lateral breach incidence in patients who underwent CT scans. While many will agree that thoracic pedicle screw placement is technically demanding given the size of the pedicles and nearby vital neurovascular structures, we did not experience any neurovascular or visceral injuries. Ringel *et al.* had a large series that revealed that 3% of the screws placed were deemed “unacceptable.”^[12] In our previous series that focused on the lumbosacral junction, there was medial or lateral breach of 0.35%.^[2]

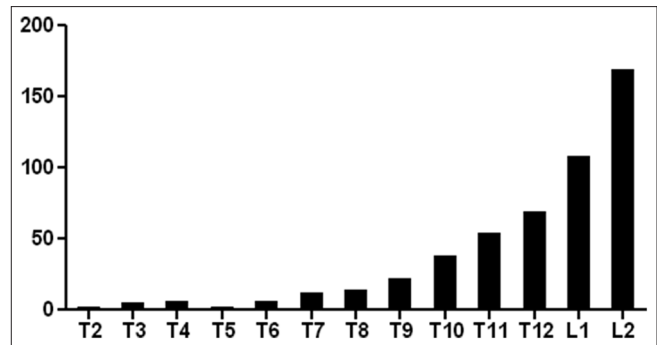


Figure 1: Distribution of percutaneous pedicle screw placement along thoracic and thoracolumbar spine

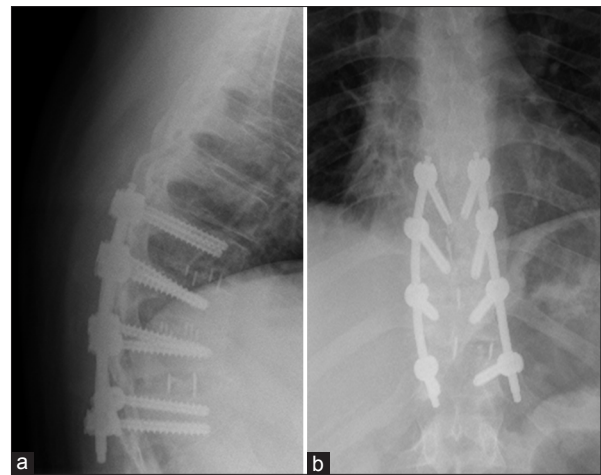


Figure 2: Postoperative plain films: (a) Lateral and (b) anterior-posterior

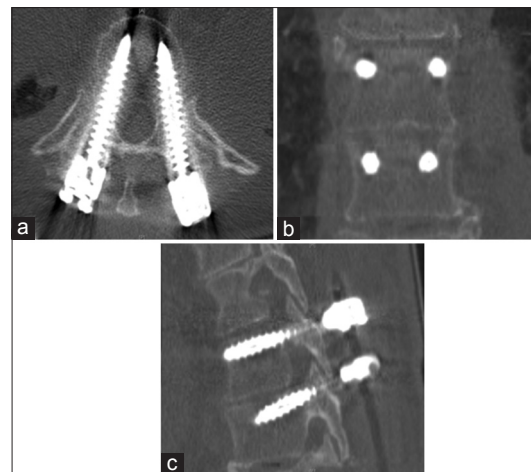


Figure 3: Computed tomography scan of pedicle screw placement: (a) Axial, (b) coronal and (c) sagittal

The indications for surgery included trauma, degenerative and metastatic disease resulting in spinal instability. The mean intraoperative blood loss was 297 ml. Moreover, only three patients required blood transfusions intra-operatively. This was in the setting of multiple level constructs every case. Case series involving open techniques report blood loss almost twice as much.^[13]

While this study did not use intra-operative navigation, a single c-arm fluoroscope was utilized. The free-hand technique is another technique that does not utilize image-navigation. This however, requires an open procedure to assess the anatomy. Even with visualization of transverse process and other landmarks, cadaveric studies have shown placement as high as 21%.^[14] Moreover, clinical studies have yielded unacceptable screw placement between 21% and 50%.^[15,16] Using intra-operative fluoroscopy provides a balance between cumbersome and costly navigation systems and open free-hand techniques, which, in addition to being an open procedure, has a higher incidence of screw misplacement.^[14-16]

This retrospective study shows that minimally-invasive posterior spinal stabilization can be performed without image-navigation and can be performed safely and accurately in multiple disease settings including trauma, degenerative and metastatic disease. As is well-illustrated in the literature, a minimally-invasive approach offers spinal stabilization to patients who may not be able to tolerate an open procedure secondary to medical comorbidities or not being able to tolerate the blood loss seen in open procedures. This study also supports our contention that even at the level of the thoracic spine and thoracolumbar junction, instrumentation can be completed effectively and efficiently without the aid of costly intraoperative navigation systems and with a higher safety profile than the free-hand technique.

References

- Magerl F. Early surgical therapy of traumatic injuries of the spinal cord (author's transl). *Orthopade* 1980;9:34-44.
- Powers CJ, Podichetty VK, Isaacs RE. Placement of percutaneous pedicle screws without imaging guidance. *Neurosurg Focus* 2006;20:E3.
- Wiesner L, Kothe R, Schulitz KP, Rütger W. Clinical evaluation and computed tomography scan analysis of screw tracts after percutaneous insertion of pedicle screws in the lumbar spine. *Spine (Phila Pa 1976)* 2000;25:615-21.
- Kim DY, Lee SH, Chung SK, Lee HY. Comparison of multifidus muscle atrophy and trunk extension muscle strength: Percutaneous versus open pedicle screw fixation. *Spine (Phila Pa 1976)* 2005;30:123-9.
- Foley KT, Holly LT, Schwender JD. Minimally invasive lumbar fusion. *Spine (Phila Pa 1976)* 2003;28:S26-35.
- Holly LT, Foley KT. Three-dimensional fluoroscopy-guided percutaneous thoracolumbar pedicle screw placement. Technical note. *J Neurosurg* 2003;99:324-9.
- Holly LT, Foley KT. Intraoperative spinal navigation. *Spine (Phila Pa 1976)* 2003;28:S54-61.
- Holly LT, Foley KT. Percutaneous placement of posterior cervical screws using three-dimensional fluoroscopy. *Spine (Phila Pa 1976)* 2006;31:536-40.
- Wang MY, Kim KA, Liu CY, Kim P, Apuzzo ML. Reliability of three-dimensional fluoroscopy for detecting pedicle screw violations in the thoracic and lumbar spine. *Neurosurgery* 2004;54:1138-42.
- Carbone JJ, Tortolani PJ, Quartararo LG. Fluoroscopically assisted pedicle screw fixation for thoracic and thoracolumbar injuries: Technique and short-term complications. *Spine (Phila Pa 1976)* 2003;28:91-7.
- Kuntz C 4th, Maher PC, Levine NB, Kurokawa R. Prospective evaluation of thoracic pedicle screw placement using fluoroscopic imaging. *J Spinal Disord Tech* 2004;17:206-14.
- Ringel F, Stoffel M, Stürer C, Meyer B. Minimally invasive transmuscular pedicle screw fixation of the thoracic and lumbar spine. *Neurosurgery* 2006;59:ONS361-6.
- Takaso M, Nakazawa T, Imura T, Okada T, Toyama M, Ueno M, *et al.* Two-year results for scoliosis secondary to Duchenne muscular dystrophy fused to lumbar 5 with segmental pedicle screw instrumentation. *J Orthop Sci* 2010;15:171-7.
- Cinotti G, Gumina S, Ripani M, Postacchini F. Pedicle instrumentation in the thoracic spine. A morphometric and cadaveric study for placement of screws. *Spine (Phila Pa 1976)* 1999;24:114-9.
- Liljenqvist UR, Halm HF, Link TM. Pedicle screw instrumentation of the thoracic spine in idiopathic scoliosis. *Spine (Phila Pa 1976)* 1997;22:2239-45.
- Weinstein JN, Spratt KF, Spengler D, Brick C, Reid S. Spinal pedicle fixation: Reliability and validity of roentgenogram-based assessment and surgical factors on successful screw placement. *Spine (Phila Pa 1976)* 1988;13:1012-8.

How to cite this article: Nimjee SM, Karikari IO, Carolyn A. Hardin AB, Choi J, Powers CJ, *et al.* Safe and accurate placement of thoracic and thoracolumbar percutaneous pedicle screws without image-navigation. *Asian J Neurosurg* 2015;10:272-5.

Source of Support: Nil, **Conflict of Interest:** None declared.