

Contents lists available at [ScienceDirect](#)

Journal of Hand Surgery Global Online

journal homepage: www.JHSGO.org

Original Research

Triquetral Motion Is Limited *In Vivo* After Lunocapitate Arthrodesis

Thorsten Schriever, MD,* Henrik Olivecrona, MD, PhD,† Maria Wilcke, MD, PhD*

* Karolinska Institute, Department of Clinical Science and Education, Södersjukhuset, Stockholm, Sweden

† Department of Molecular Medicine and Surgery, Karolinska Institutet, Stockholm, Sweden



ARTICLE INFO

Article history:

Received for publication August 6, 2019

Accepted in revised form September 15, 2019

Available online October 25, 2019

Key words:

lunatocapitate arthrodesis
osteoarthritis
scapholunate advanced collapse
scaphoid nonunion advanced collapse
triquetrum

Purpose: Lunocapitate arthrodesis is a motion-preserving salvage procedure for painful wrist osteoarthritis. Because the arthrodesis is limited to the capitate and the lunate, the adaptive motion of the triquetrum is theoretically maintained. We aimed to examine whether triquetral motion is sustained *in vivo* after lunocapitate arthrodesis.

Methods: We examined 7 patients after lunocapitate arthrodesis at least 1 year earlier, with computed tomography at 2 wrist positions: maximal radial extension and maximal ulnar flexion. Triquetral motion *in vivo* was analyzed using volume registration technique of the paired computed tomography scans and compared with the contralateral side.

Results: The triquetrum moved in all patients, but the degree of motion was small compared with the nonsurgical wrist. A minor degree of motion of the hamate relative to the fused lunocapitate could also be demonstrated.

Conclusions: Triquetral motion is limited after lunocapitate arthrodesis.

Type of study/level of evidence: Therapeutic IV.

Copyright © 2019, THE AUTHORS. Published by Elsevier Inc. on behalf of The American Society for Surgery of the Hand. This is an open access article under the CC BY-NC-ND license (<http://creativecommons.org/licenses/by-nc-nd/4.0/>).

Lunocapitate arthrodesis and 4-corner arthrodesis are motion-preserving salvage procedures for painful wrist osteoarthritis such as scaphoid nonunion advanced collapse and scapholunate advanced collapse. After excision of the osteoarthritic scaphoid, the midcarpal joint is stabilized to prevent radial dislocation of the capitate and development of arthritis between the capitate and the lunate. In 4-corner arthrodesis, the lunate, triquetrum, capitate, and hamate are fused, whereas in lunocapitate arthrodesis, the fusion is limited to the capitate and the lunate.

The dart-throwing motion from radial extension to ulnar flexion is the primary functional direction of radiocarpal motion wrist motion.¹ In a normal wrist, the triquetrum rotates along the ellipsoidal surface of the hamate during the dart-throwing motion² and adapts to the varying ulnocarpal gap by its shape.³ After 4-corner

arthrodesis, this adaptive motion is inhibited; as a result, ulnocarpal impingement in ulnar deviation and an abnormal radioulnar gap in radial deviation may occur.³ Theoretically, after lunocapitate arthrodesis, the adaptive motion of the triquetrum should be maintained. However, it has not been shown *in vivo* whether the motion of the triquetrum is sustained after lunocapitate arthrodesis.

Analysis of multiple computed tomography (CT) images of the wrist with volume registration techniques is a noninvasive method that has increased understanding about the 3-dimensional kinematics of the carpal.^{2,4–6} Still, there is much to learn about functional carpal kinematics.¹

The aim of this study was to examine whether the triquetrum shifts position (ie, moves relative to the lunocapitate complex from radial extension to ulnar flexion after lunocapitate arthrodesis) by comparing paired CT scans using a bone volume registration technique that requires only 2 CT scans.

Materials and Methods

Patients

We aimed to include all patients with a unilateral lunocapitate arthrodesis owing to scapholunate advanced collapse or scaphoid

Declaration of conflicting interests: Dr Olivecrona is occasionally engaged by Sectra as an independent consultant for software development. Dr Wilcke and Dr Schriever received support from the AFA Research Fund. No benefits in any form have been received or will be received by the other authors related directly or indirectly to the subject of this article.

Corresponding author: Maria Wilcke, MD, PhD, Karolinska Institute, Department of Clinical Science and Education, Södersjukhuset 10, S-118 83 Stockholm, Sweden.

E-mail address: maria.wilcke@sl.se (M. Wilcke).

<https://doi.org/10.1016/j.jhsg.2019.09.009>

2589-5141/Copyright © 2019, THE AUTHORS. Published by Elsevier Inc. on behalf of The American Society for Surgery of the Hand. This is an open access article under the CC BY-NC-ND license (<http://creativecommons.org/licenses/by-nc-nd/4.0/>).

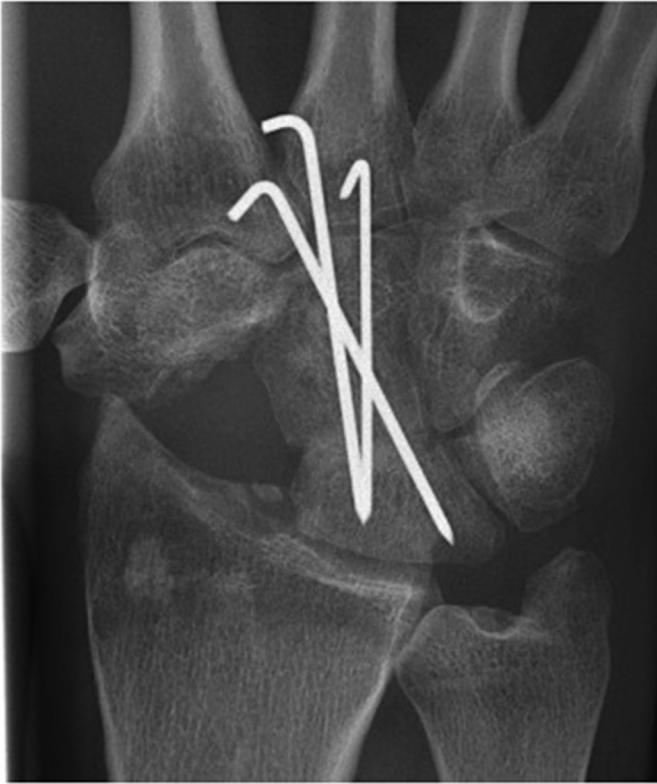

Figure 1. Radiograph of a lunocapitate arthrodesis.

nonunion advanced collapse operated on at least 1 year earlier at our clinic ($n = 10$). Two patients had nonunion of the fusion ($n = 2$) and were excluded. One patient declined participation owing to a lack of time. Thus, 7 patients were examined. Lunocapitate arthrodesis had been performed by a dorsal approach through the third and fourth extensor tendon compartments; the posterior interosseous nerve was sectioned and the wrist capsule was opened as described by Berger.⁷ The scaphoid was resected and the distal articular surface of the lunate and the proximal pole of the capitate were prepared by removing the cartilage and subchondral bone. Bone was grafted from the scaphoid, radius, or iliac crest, and the fusion was stabilized with 2 to 3 Kirschner wires (Fig. 1), taking care to reduce the lunate from extension. The capitolunate, lunotriquetral, and arcuate ligaments were not violated. After surgery, patients wore a short plaster cast or a hard wrist orthosis for 6 to 14 weeks. Full loading was permitted after the fusion was clinically and radiologically healed and the Kirschner wires had been removed.

This study was approved by the regional ethical review board.

Computed tomography scan

We obtained CT scans from bilateral wrists at 2 wrist positions, maximum radial extension and maximal ulnar flexion, aiming for the opposing positions of the dart-throwing motion. In the CT scanner, the wrists were held in position with adjustable plastic orthoses that were adjusted for each patient to achieve the anticipated wrist position and reduce motion artefacts.

Data volumes were acquired according to the protocol used for standard imaging of the wrist (ie, a helical scan, 0.6-mm collimation, pitch of 0.8, 1.0 revolutions/s at approximately 75 mA [dose regulation] and 120 kV). Slices were reconstructed at 1.0 mm

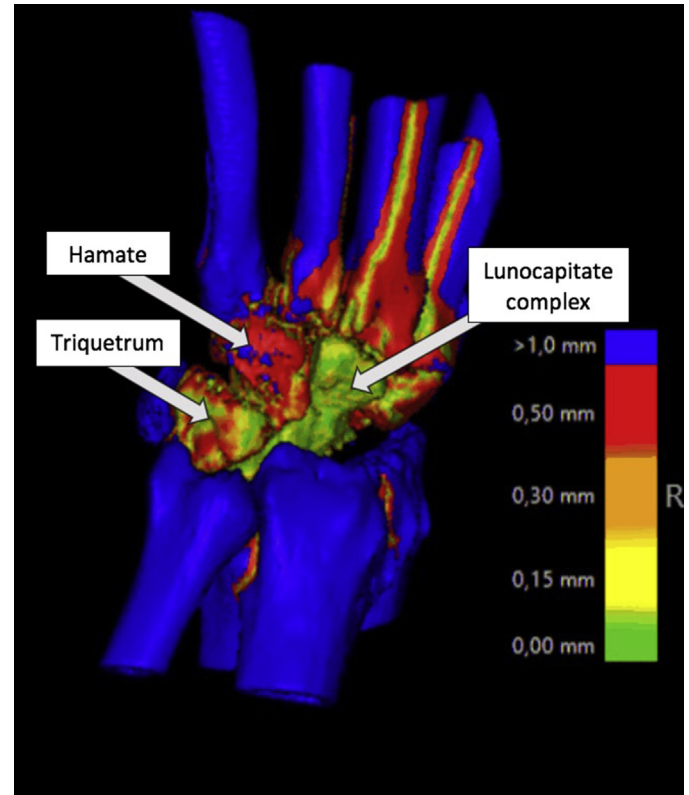


Figure 2. Bone volume registration technique analysis. Blue and red colors indicate motion in relation to the fixed segment (ie, lunocapitate complex). Green and yellow areas indicate no motion. In this case, the triquetrum and hamate exhibit red and even blue areas indicating motion.

thickness with 1.0-mm increments using a bone reconstruction algorithm in 3 planes (axial, coronal, and sagittal).

Motion analysis

Images were analyzed using a volume registration tool (CT-based Implant Micromotion Analysis, Sectra, Linköping, Sweden). This software was developed to detect early loosening of joint replacement implants by comparing sequential CT scans.⁸ Using this tool, pairs of CT volumes were registered so that the lunocapitate complex was brought into spatial alignment (ie, registered as fixed). Thereafter, the triquetrum and hamate were respectively registered and would shift position between scans only if there was a shift of position relative to the fused lunocapitate during the dart-throwing motion (Fig. 2). In the nonsurgical contralateral wrists, the capitate was registered as the fixed segment. This provided the software with input data to calculate total rigid body motion automatically between the bones. The motion of arbitrary points in the moving object was tracked in 6 degrees of freedom (translations and rotations around and along 3 orthogonal cardinal axes. Motion was expressed as the total degree of rotation in space. This does not determine the direction of motion but gives a simple and understandable expression of the magnitude of motion.

Accuracy of the motion analysis (ie, the measurement error) was determined in all patients by registering the proximal and distal parts of the lunocapitate complex separately and calculating the motion between these poles. Because no motion should occur within the fused complex, the value should ideally be 0.

Table 1
Radiographic Results

Patient	Indication	Error or Accuracy (degrees)	Triquetral Motion for Operated Wrist (degrees)	Triquetral Motion for Nonsurgical Wrist (degrees)	Hamate Motion for Operated Wrist (degrees)	Hamate Motion for Nonsurgical Wrist (degrees)	Lunate Type
1	SLAC	1.1	1.5	27.0	3.5	4.0	1
2	SNAC	0.1	1.5	39.7	3.0	7.0	1
3	SNAC	0.4	3.6	39.1	3.3	6.6	1
4	SNAC	0.5	0.8	34.9	1.8	7.0	2
5	SLAC	1.1	3.7	33.4	3.3	5.9	2
6	SNAC	0.6	0.7	24.6	0.3	4.9	2
7	SLAC	0.5	1.6	23.6	1.8	1.6	1

SLAC, scapholunate advanced collapse; SNAC, scaphoid nonunion advanced collapse.

The numerical detection limit for triquetral and hamate motion relative to the lunocapitate complex was set to more than the determined measurement error (0.1–1.1°).

Results

In the nonsurgical wrists, considerable triquetral motion in relation to the capitate was confirmed in all patients. The hamate also moved relative the capitate, but to a much lesser degree (Table 1).

We found motion of the triquetrum relative to the fused lunocapitate in all operated wrists. The degree of motion of the triquetrum varied and was small compared with the nonsurgical wrist. Motion of the hamate in relation to the lunocapitate complex was detected in 6 patients. In most patients, the hamate showed less motion than in the surgical wrist.

Discussion

It has been suggested that range of motion may be better preserved after lunocapitate arthrodesis compared with 4-corner arthrodesis as a result of the ability of the triquetrum to adapt its position and adjust during wrist motion.³ To our knowledge, there have been no reports on the kinetics of the triquetrum after lunocapitate arthrodesis. We found that the triquetrum moved in all patients, but only to a small degree during the dart-throwing motion. After a midcarpal arthrodesis, wrist motion is reduced; consequently, we expected a lesser degree of triquetral motion than in the nonsurgical wrist. However, triquetral motion was far more limited than expected. We consider postoperative scarring to be a reasonable explanation for the limited motion of the triquetrum after lunocapitate arthrodesis. Hypothetically, fixation of the lunocapitate arthrodesis with screws allowing earlier mobilization might have resulted in greater motion of the wrist and triquetrum than after Kirschner wire fixation. Also, when the lunate is fused to the capitate, triquetral motion is probably prevented to some extent by the strong lunotriquetral ligaments.

The small triquetral motion that actually occurs after lunocapitate arthrodesis may still be favorable for the wrist function. By not fusing or excising the triquetrum, if the posterior interosseous nerve is spared, the proprioceptive role of the radiotriquetral ligaments may be maintained, which is potentially important for wrist proprioception and stability.⁹ Excision of the triquetrum has been shown to increase wrist motion after midcarpal arthrodesis in cadavers.¹⁰ However, this has not yet been demonstrated clinically.¹¹ Also, the merit of triquetral excision is debatable, because it seems to increase the load on the radiolunate joint.¹²

The hamate is believed to move as a unit with the capitate.¹ Hence, we did not expect the hamate to move relative to the fused lunocapitate. However, motion analysis showed that the hamate moved to a small degree both in the healthy wrists (relative

to the capitate) and in most patients with lunocapitate arthrodesis. These findings confirm the complexity and individual variance of carpal kinetics.

Hamatolunate articulation has been suggested as a possible focal point for ulnar pain in type 2 lunate wrists (ie, with a lunate facet toward the hamate).¹³ In view of our observation of a small degree of hamate motion relative to the fused lunocapitate, it can be questioned whether a lunocapitate arthrodesis is appropriate for patients with a type 2 lunate, assuming a potential risk for arthritis between the nonfused hamate and fused lunate. However, it is not known whether arthritis of the hamatolunate articulation is of clinical importance.

This study had several limitations. Motion analysis based on static CT scans is an indirect assessment of the change in position of the bones relative to each other and may be subject to errors. Hence, the absolute values of the degree of motion in this study must be interpreted with caution, and the method is limited to answering whether bones move relative to each other. Another limitation was the small sample of 7 patients. Furthermore, the adjustable plastic orthoses may not have held the wrist in true maximal radial extension or ulnar flexion in the CT scanner. Also, the actual wrist position was not measured in the orthoses.

We studied only the end positions and not the intermediary positions during the dart-throwing motion path. Although this presents an additional limitation, our intention was to test whether motion analysis of the carpals based on 2 CT scans was possible, because this would offer a clinically feasible assessment. Multiple CT scans generate more radiation and produce large data volume. Dynamic, 4-dimensional CT is a more sophisticated technology for assessing carpal kinematics and offers a real-time visual approximation of wrist dynamics,^{14,15} but it is not readily available to the clinician. Bone volume registration analysis of paired CT scans may potentially be applicable for wrist diagnostics, such as in diagnosing nonunion or assessing scapholunate instability.

A small degree of triquetral motion is preserved after lunocapitate arthrodesis. We found that the hamate also moves to a small degree relative to the capitate after intercarpal arthrodesis.

Acknowledgments

This study was funded by the AFA Research Fund and funding for clinical research at Karolinska Institute at Södersjukhuset.

References

- Rainbow MJ, Wolff AL, Crisco JJ, Wolfe SW. Functional kinematics of the wrist. *J Hand Surg Eur Vol.* 2016;41(1):7–21.
- Kamal RN, Rainbow MJ, Akelman E, Crisco JJ. In vivo triquetrum-hamate kinematics through a simulated hammering task wrist motion. *J Bone Joint Surg Am.* 2012;94(12):e85.
- Ferreres A, Garcia-Elias M, Plaza R. Long-term results of lunocapitate arthrodesis with scaphoid excision for SLAC and SNAC wrists. *J Hand Surg Eur Vol.* 2009;34(5):603–608.

4. Moojen TM, Snel JG, Ritt MJ, Kauer JM, Venema HW, Bos KE. Three-dimensional carpal kinematics in vivo. *Clin Biomech (Bristol, Avon)*. 2002;17(7):506–514.
5. Crisco JJ, Coburn JC, Moore DC, Akelman E, Weiss AP, Wolfe SW. In vivo radiocarpal kinematics and the dart thrower's motion. *J Bone Joint Surg Am*. 2005;87(12):2729–2740.
6. Lee S, Kim YS, Park CS, et al. CT-based three-dimensional kinematic comparison of dart-throwing motion between wrists with malunited distal radius and contralateral normal wrists. *Clin Radiol*. 2014;69(5):462–467.
7. Berger RA. A method of defining palpable landmarks for the ligament splitting dorsal wrist capsulotomy. *J Hand Surg Am*. 2007;32(8):1291–1295.
8. Olivecrona H, Noz ME, Maguire GQ Jr, Zeleznik MP, Sollerman C, Olivecrona L. A new computed tomography-based radiographic method to detect early loosening of total wrist implants. *Acta Radiol*. 2007;48(9):997–1003.
9. Hagert E, Garcia-Elias M, Forsgren S, Ljung BO. Immunohistochemical analysis of wrist ligament innervation in relation to their structural composition. *J Hand Surg Am*. 2007;32(1):30–36.
10. Bain GI, Sood A, Ashwood N, Turner PC, Fogg QA. Effect of scaphoid and triquetrum excision after limited stabilisation on cadaver wrist movement. *J Hand Surg Eur Vol*. 2009;34(5):614–617.
11. Gaston RG, Greenberg JA, Baltera RM, Mih A, Hastings H. Clinical outcomes of scaphoid and triquetral excision with capitulate arthrodesis versus scaphoid excision and four-corner arthrodesis. *J Hand Surg Am*. 2009;34(8):1407–1412.
12. Scobercea RG, Budoff JE, Hipp JA. Biomechanical effect of triquetral and scaphoid excision on simulated midcarpal arthrodesis in cadavers. *J Hand Surg Am*. 2009;34(3):381–386.
13. Viegas SF, Wagner K, Patterson R, Peterson P. Medial (hamate) facet of the lunate. *J Hand Surg Am*. 1990;15(4):564–571.
14. Garcia-Elias M, Alomar Serrallach X, Monill Serra J. Dart-throwing motion in patients with scapholunate instability: a dynamic four-dimensional computed tomography study. *J Hand Surg Eur Vol*. 2014;39(4):346–352.
15. Kakar S, Breighner RE, Leng S, et al. The role of dynamic (4D) CT in the detection of scapholunate ligament injury. *J Wrist Surg*. 2016;5(4):306–310.