



# Disseminated infection by *Mycobacterium genavense* in an HIV-1 infected patient

Tomás Robalo Nunes<sup>a,\*</sup>, Ana Calderón<sup>b</sup>, Clara Barroso<sup>c</sup>, Nuno Marques<sup>d</sup>

<sup>a</sup>Infectious Diseases Resident, Infectious Diseases Department, Hospital Garcia de Orta, Almada, Portugal

<sup>b</sup>Pathology Resident, Histopathology Department, Hospital Garcia de Orta, Almada, Portugal

<sup>c</sup>Consultant in Pneumology, Centro de Diagnóstico Pneumológico, Almada, Portugal

<sup>d</sup>Head of Department of Infectious Diseases, Infectious Diseases Department, Hospital Garcia de Orta, Almada, Portugal

## ARTICLE INFO

### Article history:

Received 9 June 2020

Received in revised form 23 July 2020

Accepted 23 July 2020

### Keywords:

*Mycobacterium genavense*

HIV infection

Opportunistic infections

## ABSTRACT

Opportunistic infections are an important cause of death and morbidity among HIV infected patients. Disseminated infections by nontuberculous mycobacteria are a diagnostic to consider among these patients with a high level of immunosuppression.

A 64 year old Caucasian man, born in Angola, living in Portugal since 1975, presented in the emergency room with generalized malaise, weight loss, vesperal temperatures of around 37.5 °C with night sweats for two months, and epigastric abdominal pain with liquid stools in the 2 previous weeks. Laboratory study revealed a previously undiagnosed HIV-1 infection with 42 Lymphocytes CD4+/uL and viremia of 61,249 copies/mL. The abdominal-pelvic CT scan showed multiple necrotic ganglia in the mesenterium and mesenteric vases, which were biopsied revealing positive PCR for a nontuberculous mycobacteria; duodenal biopsies showed similar results. The bone marrow blood culture yeald the growth of *Mycobacterium genavense*. Antimicrobial treatment was started and after six months he showed imagiological deterioration and the antibiogram revealed resistance to all antimycobacterial agents. The therapeutic scheme was empirically changed and the patient kept under vigilance with chronic therapy.

This rare clinical case is both a diagnostic and therapeutic challenge.

© 2020 The Authors. Published by Elsevier Ltd. This is an open access article under the CC BY-NC-ND license (<http://creativecommons.org/licenses/by-nc-nd/4.0/>).

## Introduction

Infection by the human immunodeficiency virus (HIV) is an important cause of death worldwide. Even nowadays, in the era of the highly active antiretroviral therapy (HAART), most deaths in this population are related to AIDS-defining conditions [1].

Disseminated infection by nontuberculous mycobacteria is considered an AIDS-defining condition [2], that continues to have a high mortality in this population [3]. *Mycobacterium genavense* is a nontuberculous mycobacteria that infects mostly patients with HIV-1 with severe immunodepression, with lower than 100 Lymphocytes CD4+/uL, [4] but it has also been described in non-HIV immunodepressed patients [5–7].

The disseminated infection by *Mycobacterium genavense* is clinically very similar with the more common *Mycobacterium avium* complex infection. In addition, it is a very fastidious

microorganism, which is very difficult to grow in cultures, contributing to the diagnostic challenge of this condition. [5] There are no standardized guidelines for the treatment of this infection.

We present a case of disseminated infection by *Mycobacterium genavense* in an HIV-1 infected patient with severe immunosuppression with poor response to antibiotic therapy.

## Case

A 64 year old Caucasian man presented to the Emergency Room in 2016 with approximately 2 months of generalized malaise, weight loss (7 kg), anorexia and vesperal temperatures of around 37.5 °C. He also noticed epigastric abdominal pain, liquid stools (once a day, without blood or mucous) and night sweats in the two previous weeks. He denied increased ganglia, increased abdominal volume, vomits or respiratory symptoms.

The patient was born in Angola (Sub-saharan Africa), but was living in Portugal since 1975 and denied any trip abroad since then. His past medical history was not remarkable.

On clinical presentation, he was underweight and febrile (temperature of 38.1 °C). Skin was colored and hydrated.

\* Corresponding author at: Infectious Diseases Department, Hospital Garcia de Orta, Aveninda Torrado da Silva, Almada, 2805-267, Portugal.

E-mail addresses: [tomasrobalonunes@gmail.com](mailto:tomasrobalonunes@gmail.com) (T. Robalo Nunes), [anaisabelcalderon@gmail.com](mailto:anaisabelcalderon@gmail.com) (A. Calderón), [clara.barroso@arslvt.min-saude.pt](mailto:clara.barroso@arslvt.min-saude.pt) (C. Barroso), [nuno.silva.marques@hgo.min-saude.pt](mailto:nuno.silva.marques@hgo.min-saude.pt) (N. Marques).

Cardiopulmonary auscultation was normal. Abdominal palpation was slightly painful in the epigastric region. Hepatosplenomegaly or peripheric adenopathy were not found. The fundoscopy was normal. No additional clinical findings were noticed.

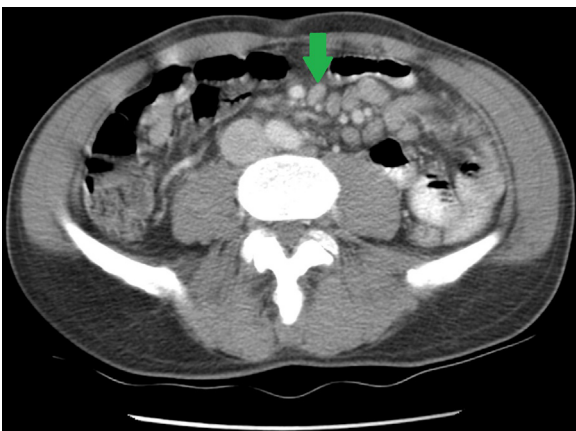
The laboratory study revealed mild thrombocytopenia and slightly elevated C-Reactive Protein. The HIV screening was positive with ELISA and Western blot for infection with HIV-1. The patient was unaware of this condition. Immunologically the patient presented with CD4+ T-cel count of 64.8/uL (6,4 %) and HIV-1 viral load of 61,249 copies/mL.

The abdominal ultrasound revealed multiple ganglia in the emergence of the celiac trunk (the largest one with approximately 20 mm). The CT scan confirmed the presence of this multiple adenopathy, sometimes necrotic and coalescent, diffusely distributed in the mesentrium, the largest with 2 cm in diameter (Fig. 1). There were also multiple adenopathy around the mesenteric vessels and around the aorta and inferior vena cava, predominantly in the emergence of the renal vessels and in the retrocural region.

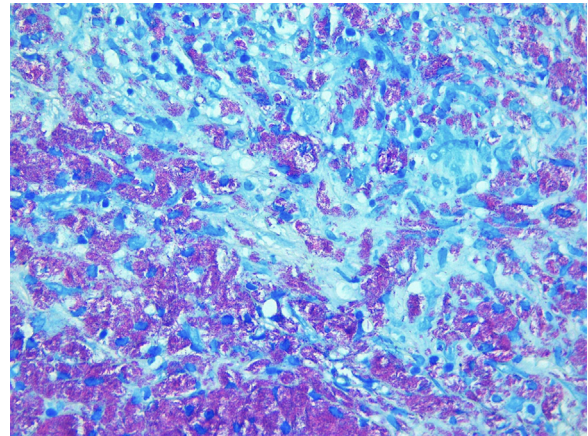
As imagiological findings suggested lymphoproliferative disease, a bone marrow aspiration was performed. It failed to detect abnormal lymphoid populations, showing a normal ratio of the myeloid/erythroid lineage and the molecular study using RT-PCR for nontuberculous mycobacteria (NTM) and *Mycobacterium tuberculosis* (MTB) was negative. Bone marrow mycobacterial culture was ensued yielding the growth of *Mycobacterium genavense* six weeks later.

The patient was also submitted to laparoscopic mesenteric ganglia biopsy. Molecular biological analysis using RT-PCR was positive for NTM and negative for MTB; mycobacterial cultures were negative. The histopathological examination showed an alteration of the ganglia architecture, filled with histiocytes and numerous Ziehl-Neelsen+, PAS- microorganisms (Fig. 2), which was compatible with an atypical mycobacteriosis. Upper endoscopy revealed focal hyperemia and loss of the vascular appearance in the duodenum; the stomach antrum was atrophic with reduction of the vascular supply. Histopathological examination of the duodenum mucosa showed infiltration by histiocytes (CD68+, S100-, PAS-), filled with numerous mycobacteria (Ziehl Neelsen and FITE+) (Fig. 3). The diagnosis of a disseminated mycobacteriosis by *Mycobacterium genavense* was then confirmed.

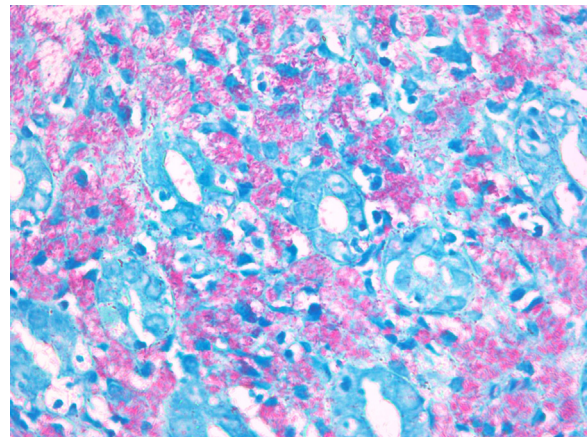
As the HLAB5701 was not present and the HIV drug resistance test was negative, antiretroviral therapy was initiated with a single tablet regimen containing abacavir, lamivudine and dolutegravir with good tolerance and adherence. Due to severe immunosuppression trimethoprim/sulfamethoxazole prophylaxis was also



**Fig. 1.** Abdominal CT Scan - multiple adenopathy, necrotic and coalescent, diffusely distributed in the mesentrium and around the mesenteric vessels, the largest with 2 cm in diameter.



**Fig. 2.** Ganglia biopsy - alteration of the ganglia architecture, filled with histiocytes and numerous Ziehl-Neelsen+, PAS- microorganisms, compatible with an atypical mycobacteriosis. Ziehl-Nielsen and Fite. 40 × .



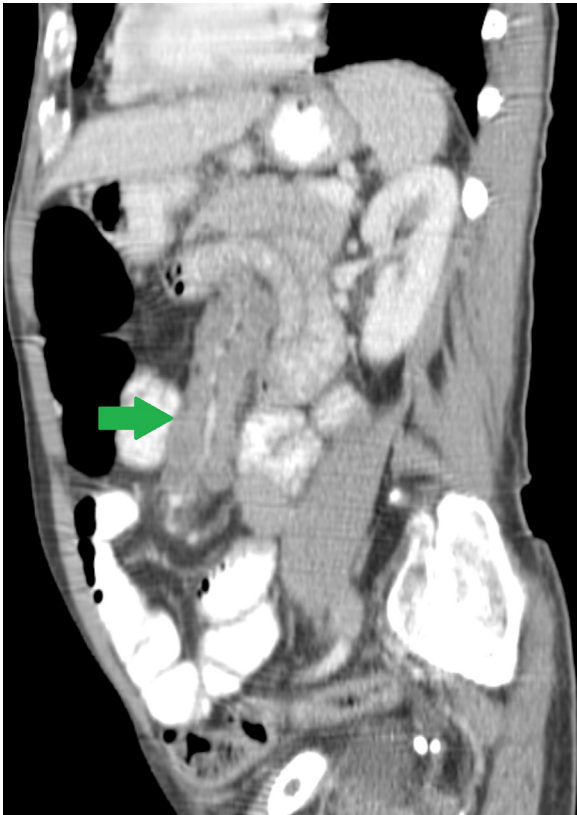
**Fig. 3.** Duodenum sample - infiltration by histiocytes (CD68+, S100-, PAS-), filled with numerous mycobacteria. Ziehl Neelsen and FITE + . 60x.

initiated. Antimycobacterial treatment was started empirically with rifabutin, ethambutol and clarithromycin.

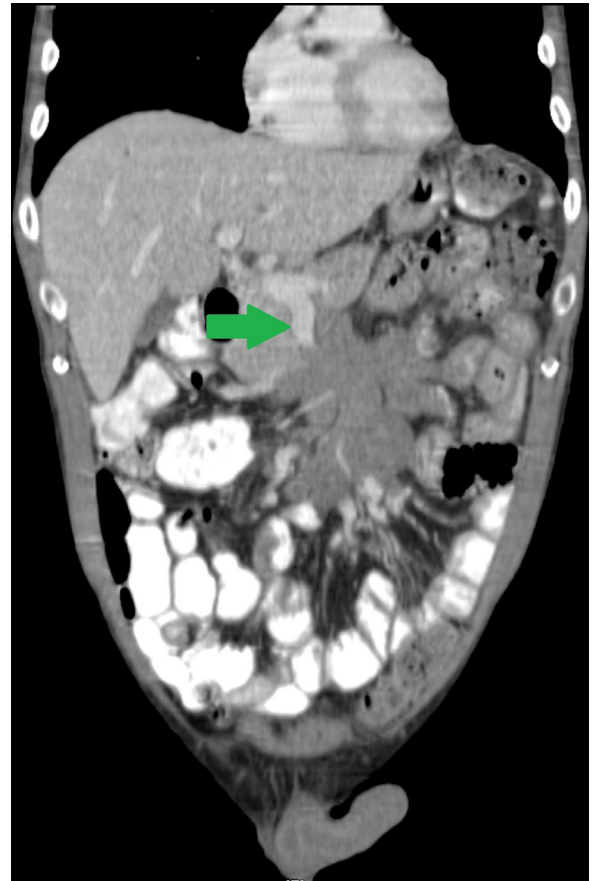
After 4 months under the antimycobacterial treatment, the patient, although clinically stable and with no signs of immune reconstitution inflammatory syndrome (CD4 + T-cel count of 94/uL and HIV viral load of 0 copies/mL), showed imagiological deterioration of the adenopathy, with presence of the “sandwich sign” (Fig. 4), meaning the mesenteric ganglia compressing the superior mesenteric vein. After 6 months of treatment, we had access to the drug susceptibility testing, which showed resistance to all first and second lines antibacillary drugs (ethambutol, linezolid, amikacin, rifampicin, rifabutin, ofloxacin, olarithromycin, Isoniazid, ciprofloxacin). At the time, the patient was kept under the antimycobacterial treatment described before as the drug susceptibility testing is not clearly validated for this microorganism.

After 9 months of treatment, the patient still complained about abdominal pain and presented with CD4 + T cel count of 204/uL and undetectable HIV viral load. Another abdominal CT scan was performed, presenting similar findings as the ones previously described and thrombosis of the inferior mesenteric vena (Fig. 5).

To exclude the presence of another HIV-associated infection or lymphoproliferative disease, a second mesenteric ganglia biopsy was performed, which revealed persistence of the atypical mycobacteriosis on the histopathological examination. Bone



**Fig. 4.** Abdominal CT scan - "Sandwich sign" - compression of the superior mesenteric vein by the mesenteric ganglia.



**Fig. 5.** Abdominal CT Scan - thrombosis of the inferior mesenteric vena.

marrow aspiration was also repeated. Both products were negative for culture and RT-PCR of NTB and MTB.

Because of the imagiological deterioration and antibacterial resistance pattern, it was considered the possibility of non-response and treatment was revised at that time for amikacin, rifampicin, moxifloxacin and clarithromycin and enoxaparin. Due to drug interactions, dolutegravir was changed to efavirenz with good tolerance. The patient was kept under this antimycobacterial treatment for 3 months, but due to intolerance to the amikacin (local injection site pain), this drug was discontinued. After more than 3 years, the patient is currently alive, clinically stable, with no imagiological deterioration, although he is still on antimycobacterial treatment with rifampicin, moxifloxacin and clarithromycin.

## Discussion

*Mycobacterium genavense* is a fastidious acid fast NTM, which was first isolated in 1990, [8] but only classified as a new species and described in 1992–1993 [8–10]. Infection by this microorganism occurs mostly in HIV infected patients with severe immunodeficiency (lower than 100 Lymphocytes CD4+/uL) [4], and it has a similar pathogenicity with *Mycobacterium avium-intracellulare* [8,11]. *Mycobacterium genavense* infection has also been described in non-HIV immunosuppressed patients, [5–7] as solid organ transplant recipients, sarcoidosis or hematopoietic stem cell transplantation [6], or even other immunodeficiency syndromes, as the presence of neutralizing anti-interferon- $\gamma$  (anti-IFN- $\gamma$ ) autoantibodies [12]. The gastrointestinal route is the most probable source of infection [13,14], as *Mycobacterium genavense* was detected in intestinal biopsies from HIV-negative healthy individuals [15].

According to a retrospective multicentric study performed in France between 1996–2007, patients with disseminated infection

by *Mycobacterium genavense* presented commonly with weight loss, fever, abdominal pain and splenomegaly [5]. Similar results were found in other reports [11,14]. These clinical findings were all present in our patient, as previously described. It is important to notice that, according to Thomsen et al., abdominal pain was the only symptom found significantly more often in the disseminated infection by *Mycobacterium genavense* than by *Mycobacterium avium complex*, which can be used as a clinical clue to differentiate these two agents [16].

In this case report, we describe the presence of multiple adenopathy diffusely distributed in the mesentery and around the mesenteric vessels. According to Charles, P. et al., 62.5 % of the patients of his series had visceral (mainly abdominal) adenopathies which seems to agree with our observations [5]. In fact, in a retrospective study performed in Barcelona, all patients with disseminated infection by *Mycobacterium genavense* also had multiple mesenteric and retroperitoneal ganglia [17]. Histopathological examination of the duodenum mucosa and from the mesenteric adenopathies revealed infiltration by histiocytes filled with numerous mycobacteria, comparable with the findings described by other authors [5,8,13,14]. Due to its characteristics, *Mycobacterium genavense* is difficult to grow and can be missed by routine cultures [5,13,18,19]. In fact, it can take more than 6 weeks of incubation to isolate this microorganism [20], with recommended incubation times of at least 8–12 weeks according to the American Thoracic Society guidelines [18]. Like other NTM, it is usually cultured in liquid and solid media. However, supplementation with siderophore mycobactin j is specifically required for the recovery of *Mycobacterium genavense* in culture [18]. Many times, only through molecular methods, as RT-PCR or 16S ribosomal RNA gene sequencing, it is possible to identify the specific

microorganism [5,8,13]. To our knowledge, this is the first clinical case with cultural isolation of *Mycobacterium genavense* in Portugal. A previous case identified the microorganism through molecular biology with RT-PCR [13].

There are no specific guidelines for the treatment of the disseminated infection by *Mycobacterium genavense*. According to the American Thoracic Society, amikacin, rifamycins, fluoroquinolones, streptomycin and macrolides have been reported as good options [18]. In Thomsen's study, all isolated microorganisms were susceptible to rifampin, rifabutin, roxithromycin, clarithromycin, azithromycin and fusidic acid and most were susceptible to amikacin, ciprofloxacin and ofloxacin [16]. According to the American Thoracic Society, multidrug schemes with clarithromycin are probably more effective than the ones without it and ethambutol and isoniazid have limited activity against *M. genavense* [18]. However, there is still some controversy on whether ethambutol is or not effective [16]. Charles, P. et al. described the association of clarithromycin, ethambutol and rifabutin as the most common scheme [5], and was the one used initially in our patient and the choice in the other portuguese case report [13].

During the initial treatment with this triple-drug scheme, we were informed that the *M. genavense* isolated in our patient's bone marrow blood was resistant to all antimycobacterial antibiotics. However, because of the difficulties in growing this mycobacteria in culture, there are no standardized guidelines for testing the antibiotic susceptibility of the *Mycobacterium genavense* [18,20]. Therefore, it is not possible to know if this in vitro resistance has a clinical impact. The ATS guidelines recommend that many patients may be kept in long life treatment; suspension can be considered according to the clinical evolution and immune restoration of the patient [18].

The patient is currently clinically stable, under chronic antibiotic therapy. This represents a rare clinical case with a challenging diagnostic and therapeutic approach.

#### Author statement

I am writing this Author Statement as it is specifically required in the reviewing process of the case report "Disseminated infection by *Mycobacterium genavense* in an HIV-1 infected patient" that is under consideration for Infectious Diseases Cases.

As previously stated in the ID cases authorship form, me (Tomás Nunes), Clara Barroso, MD and Nuno Marques, MD, PhD, were the main medical doctors providing medical assistance in the described case. The case was written and revised equally by the three of us before the first submission. Ana Calderón was crucial in the pathology department, was crucial in the diagnostic process, in the case discussion and imaging description submitted in the manuscript.

#### Declarations

Ethics approval and consent to participate: Not applicable

#### Consent for publication

The patient consented for publication all the exposed data including images

#### Funding

Not applicable

#### Declaration of Competing Interest

All authors declare that they have no competing interests

#### Acknowledgements

Pathology and Radiology Departments for the support interpreting the diagnostic tests performed in this case.

#### References

- [1] Croxford S, Kitching MFP, A, Desai S, Kall M, Edelstein MFP, Skingsley MRCP A, et al. Mortality and causes of death in people diagnosed with HIV in the era of highly active antiretroviral therapy compared with the general population: an analysis of a national observational cohort. *Lancet Public Heal* 2017;2:e35–46, doi:[http://dx.doi.org/10.1016/S2468-2667\(16\)30020-2](http://dx.doi.org/10.1016/S2468-2667(16)30020-2).
- [2] Revised Surveillance Case Definitions for HIV Infection Among Adults, Adolescents, and Children Aged <18 Months and for HIV Infection and AIDS Among Children Aged 18 Months to <13 Years – United States. 2008. . </FONT> n.d.(Accessed June 9, 2020) <https://www.cdc.gov/mmwr/preview/mmwrhtml/rr5710a1.htm>.
- [3] Varley CD, Ku JH, Henkle E, Schafer SD, Winthrop KL. Disseminated nontuberculous mycobacteria in HIV-infected patients, Oregon, USA, 2007–2012. *Emerg Infect Dis* 2017;23:533–5, doi:<http://dx.doi.org/10.3201/eid2303.161708>.
- [4] Hoefsloot W, van Ingen J, Peters EJG, Magis-Escurra C, Dekhuijzen PNR, Boeree MJ, et al. *Mycobacterium genavense* in the Netherlands: an opportunistic pathogen in HIV and non-HIV immunocompromised patients. An observational study in 14 cases. *Clin Microbiol Infect* 2013;19:432–7, doi: <http://dx.doi.org/10.1111/j.1469-0691.2012.03817.x>.
- [5] Charles P, Lortholary O, Dechartres A, Doustdar F, Viard JP, Lecuit M, et al. *Mycobacterium genavense* infections: a retrospective multicenter study in France, 1996–2007. *Medicine (Baltimore)* 2011;90:223–30, doi:<http://dx.doi.org/10.1097/MD.0b013e318225ab89>.
- [6] Mahmood M, Ajmal S, Abu Saleh OM, Bryson A, Marcelin JR, Wilson JW. *Mycobacterium genavense* infections in non-HIV immunocompromised hosts: a systematic review. *Infect Dis (Auckl)* 2018;50:329–39, doi:<http://dx.doi.org/10.1080/23744235.2017.1404630>.
- [7] Santos M, Gil-Brusola A, Escandell A, Blanes M, Gobernado M. *Mycobacterium genavense* infections in a tertiary hospital and reviewed cases in non-HIV patients. *Patholog Res Int* 2014;2014, doi:<http://dx.doi.org/10.1155/2014/371370>.
- [8] Boettger E, Teske A, Kirschner P, Bost S, Hirschel B, Chang H, et al. Disseminated "Mycobacterium genavense" infection in patients with AIDS. *Lancet* 1992;340:76–80, doi:[http://dx.doi.org/10.1016/0140-6736\(92\)90397-L](http://dx.doi.org/10.1016/0140-6736(92)90397-L).
- [9] Coyle M, Carlson LD, Wallis C, Leonard R, Raisys V, Kilburn J, et al. Laboratory aspects of "mycobacterium genavense," a proposed species isolated from aids patients. *J Clin Microbiol* 1992;30.
- [10] Bottger EC, Hirschel B, Coyle M. *Mycobacterium genavense* sp. Nov. *Int J Syst Bacteriol* 1993;43.
- [11] Pechère M, Opravil M, Wald A, Chave J, Bessesen M, Sievers A, et al. Clinical and epidemiologic features of infection with *Mycobacterium genavense*. *Arch Intern Med* 1995;155:400–4.
- [12] Asakura T, Namkoong H, Sakagami T, Hasegawa N, Ohkusu K, Nakamura A. Disseminated *Mycobacterium genavense* infection in patient with adult-onset immunodeficiency. *Emerg Infect Dis* 2017;23:1208–10, doi:<http://dx.doi.org/10.3201/eid2307.161677>.
- [13] Tribuna C, Ângela C, Eira I, Carvalho A. Pulmonary Kaposi sarcoma and disseminated *Mycobacterium genavense* infection in an HIV-infected patient. *BMJ Case Rep* 2015;2015, doi:<http://dx.doi.org/10.1136/bcr-2015-211683>.
- [14] Tortoli E, Brunello F, Cagni AE, Colombrita D, Dionisio D, Grisendi L, et al. *Mycobacterium genavense* in AIDS patients, report of 24 cases in Italy and review of the literature. *Eur J Epidemiol* 1998;14:219–24, doi:<http://dx.doi.org/10.1023/A:1007401305708>.
- [15] Dumonceau JM, Fonteyne PA, Realini L, Van Gossuin A, Van Vooren - JP, Portaels F. Species-specific *Mycobacterium genavense* DNA in intestinal tissues of individuals not infected with human immunodeficiency virus. *J Clin Microbiol* 1995;33:2514–5.
- [16] Thomsen VØ, Dragsted UB, Bauer J, Fuursted K, Lundgren J. Disseminated infection with *Mycobacterium genavense*: a challenge to physicians and mycobacteriologists. *J Clin Microbiol* 1999;37:3901–5.
- [17] Monill JM, Franquet T, Sarnat MA, Martínez-Noguera A, Villalba J. *Mycobacterium genavense* infection in AIDS: imaging findings in eight patients. *Eur Radiol* 2001;11:193–6, doi:<http://dx.doi.org/10.1007/s003300000606>.
- [18] Griffith DE, Aksamit T, Brown-Elliott BA, Catanzaro A, Daley C, Gordin F, et al. An official ATS/IDSA statement: diagnosis, treatment, and prevention of nontuberculous mycobacterial diseases. *Am J Respir Crit Care Med* 2007;175:367–416, doi:<http://dx.doi.org/10.1164/rccm.200604-571ST>.
- [19] Shafran SD, Taylor GD, Talbot JA, Mackenzie WC, Centre HS, Shafran-S.D. *Tubercle-and-Lung-Disease\_1995\_TUBERCLE-LUNG-DIS.pdf*. . p. 168–70.
- [20] Brown-Elliott BA, Nash KA, Wallace RJ. Antimicrobial susceptibility testing, drug resistance mechanisms, and therapy of infections with nontuberculous mycobacteria. *Clin Microbiol Rev* 2012;25:545–82, doi:<http://dx.doi.org/10.1128/CMR.05030-11>.