

Single Case – General Neurology

Case Report: Treatment of Akinetic Mutism after Unilateral Anterior Cerebral Artery Infarction with Methylphenidate and Levodopa/Benserazide

Julia Zibold Moritz Luigi Schmidbauer Johannes Wischmann
Konstantinos Dimitriadis

Department of Neurology, LMU University Hospital, LMU Munich, Munich, Germany

Keywords

Akinetic mutism · Stroke · Methylphenidate · Case report

Abstract

Introduction: Akinetic mutism is a severe state of impaired volition that can result from a stroke. Its therapeutic evidence relies on single case reports that used atomoxetine or levodopa with variable latency and efficacy. **Case Presentation:** We present the case of a 54-year-old woman who developed akinetic mutism after infarction in the territory of the right anterior cerebral artery, successfully treated with methylphenidate and levodopa/benserazide. Clinical examination showed a patient lacking any spontaneous speech and movement while opening her eyes and fixating. Suspecting akinetic mutism after a comprehensive diagnostic work-up, we started an individual therapy attempt with methylphenidate 10 mg and levodopa/benserazide 100/25 mg twice daily. Both drugs affect the dopaminergic and noradrenergic transmission in the frontal-subcortical circuit, compromised in akinetic mutism. We saw rapid and sustained improvement in her volitional actions, devoid of side effects. Finally, the patient was actively communicating and moving her limbs. **Conclusion:** We discuss the patient's favorable clinical course in response to the synergistic combination of methylphenidate and levodopa/benserazide, emerging as a promising treatment strategy, and provide a brief literature review of treatment options in akinetic mutism following stroke.

© 2024 The Author(s).
Published by S. Karger AG, Basel

Correspondence to:
Julia Zibold, julia.zibold@med.uni-muenchen.de

Introduction

Akinetic mutism (AM) is a rare but severe condition of motivational and emotional dysfunction due to frontal-subcortical affection caused by neuroanatomically distinct lesions [1]. Among others, occlusion of the anterior cerebral artery (ACA) may result in AM [1].

Clinical presentation includes the absence of speech or spontaneous movement, while eye-opening, fixation, and visual tracking are often present [2]. It delimits from conditions with alteration in consciousness or in neuromuscular function [1]. Yet other authors consider the term AM outdated and subclassify this state within the minimally conscious state [3].

Even though AM was first described in 1941, little is known about effective medical treatment. No guideline recommendations exist, and neither dosage nor duration of medication intake is validated [1]. We present a case of AM due to unilateral ACA infarction treated with methylphenidate and levodopa/benserazide (LD/BZ), which induced rapid clinical improvement after drug administration and showed sustained efficacy.

Case Presentation

A 54-year-old woman was referred to our emergency department with acute loss of strength in her left extremities. Previously, the patient managed to live by herself and was mobile on foot. She had a past medical history of a previous stroke without any residual functional deficits or subsequent mood disorders, arterial hypertension, diabetes mellitus type II, and obesity. No previous psychiatric history was known. Her medication included metformin, baclofen, and vinpocetine.

The neurological examination revealed a left-sided hemiparesis accentuated on the lower extremity with a strength of 2–3/5 and hemihypesthesia, thus scoring 10 points on the National Institutes of Health Stroke Scale (NIHSS). Basic laboratory results were unremarkable.

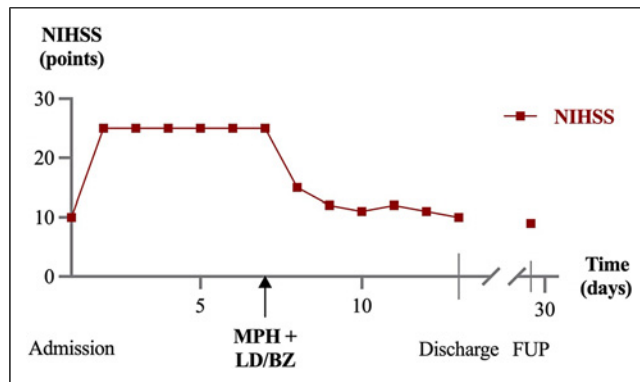
CT of the brain demonstrated an old defect in the right corona radiata as a radiological correlate of her previous stroke. CT angiography showed distal occlusion of the right ACA, and CT perfusion revealed a corresponding perfusion deficit with a 90% mismatch of cerebral blood flow and volume. After intravenous thrombolysis with 90 mg of alteplase, subsequent digital subtraction angiography in conscious sedation visualized a high-grade A2 stenosis, successfully treated with endovascular therapy. After recovery from sedation, we admitted the patient to our stroke unit in a neurologically unchanged condition (NIHSS 10).

The following day, the patient considerably worsened. She did not speak spontaneously, on command, or to painful stimuli. Moreover, we observed no volitional movements of her limbs. However, she appeared to be awake, which discriminated her condition from disorders of consciousness with lack of arousal. Her pupils were round, equal in size, responsive to light, and focused on the examiner. Accordingly, the absence of communication and volitional actions resulted in a high NIHSS score of 25 points (shown in Fig. 1).

A control CT scan of the brain visualized subacute ACA infarction and occlusion of the previously recanalized right A2 segment with poor collateral vessel status. CT perfusion demonstrated a matched perfusion deficit.

For the next 5 days, the patient remained without any attempt to speak, move, or interact with the examiners. Suspecting AM clinically, we ruled out other possible underlying etiologies for her state using comprehensive laboratory testing. CSF analysis showed mild granulocytic pleocytosis and increased total protein (13 cells/L, 76 mg/dL protein) without evidence of neuroinfectious or autoimmune origin, thus attributable to postischemic processes [4]. EEG ruled out status epilepticus and showed an encephalopathic condition (theta

Fig. 1. Clinical course of the patient with AM after right ACA infarction, as assessed by the National Institutes of Health Stroke Scale (NIHSS). Administration of methylphenidate (MPH) and levodopa/benserazide (LD/BZ) markedly improved the patient's condition, including at follow-up (FUP).



activity). A native CT scan on day six excluded new pathologies, whereas the demarcated right-sided ACA infarct was visible (shown in Fig. 2).

We diagnosed AM based on the matching clinical and imaging findings and the exclusion of infectious, metabolic, epileptic, or other cerebrovascular causes. We started an individual therapeutic approach with 10 mg methylphenidate hydrochloride and 100/25 mg LD/BZ orally twice daily on day seven after admission. Approximately 5 hours after the drug application, the patient started to speak spontaneously. In the following days, she steadily improved. The patient reacted to verbal interaction and maintained brief eye contact. She also continued speaking some words and moving her right-sided limbs. Continuous monitoring of vital signs revealed no medication-related alterations, and regular clinical and laboratory examinations ruled out any adverse events.

When subsequently transferred to an early rehabilitation clinic, the patient was awake and following commands, while her sensorimotor deficit remained (NIHSS score 10). The combination of methylphenidate and LD/BZ was discontinued 3 weeks after initiation due to largely restored volitional actions. No consecutive worsening of her clinical condition was observed. Reassessed 4 weeks after initially commencing the medication, she was even more proactive by engaging in conversations and demonstrating increased volitional movements. This impression corresponded to the patient's subjective feeling. However, due to persistent dysphagia and hemiparesis, she was still highly dependent on nursing care in her daily activities (modified Rankin Scale 5). The CARE Checklist has been completed by the authors for this case report and is attached as online supplementary material (for all online suppl. material, see <https://doi.org/10.1159/000539033>).

Discussion

We herein describe a patient with AM after unilateral ACA infarction who benefited significantly from an individual therapeutic approach with the combination of methylphenidate and LD/BZ. Both drugs affect the synaptic concentration of AM-relevant neurotransmitters in the frontal-subcortical circuit [1]. By counteracting the compromised dopaminergic uptake and restoring dysregulated signaling in the striatum and (pre-) frontal area, dopamine agonists may improve behavioral, motivational, and attentional dysfunction [1]. Levodopa acts as a presynaptic dopamine agonist, and methylphenidate is a dopamine and norepinephrine reuptake inhibitor [1]. Their plasma levels peak about one to 2 h after administration and last up to 6 h.

This specific drug combination has been studied only in poststroke patients in general, regardless of whether AM is present or not. A randomized controlled trial examining patients

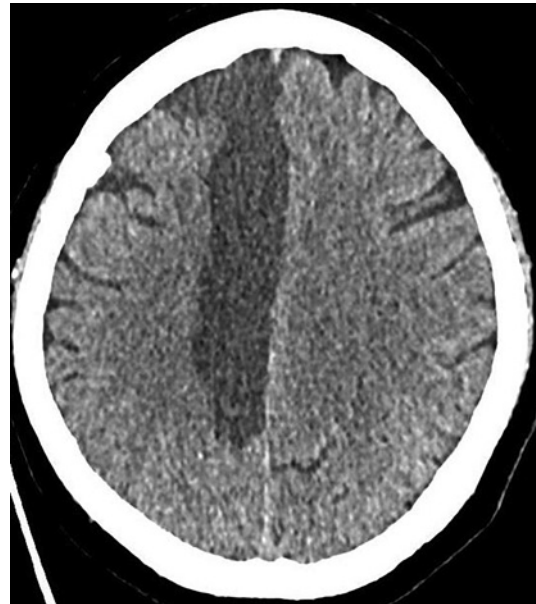

Fig. 2. A native CT scan of the brain on day six showed a hypodensity indicating the infarction in the territory of the right ACA.

undergoing early rehabilitation after stroke demonstrated that its co-administration significantly improved mood, activities of daily living, and stroke severity compared with the medication of either drug alone or placebo [5, 6].

Previous cases of AM after unilateral or bilateral damage in the ACA territory reported that either atomoxetine, levodopa alone, or in combination with carbidopa improved the patient's condition [7–10]. Yet, latency and degree of improvement were quite variable, in most cases gradually over days to weeks. Clinical enhancements included speech with the initiative to engage in conversation, volitional movements, and extended cognitive function.

We observed a pronounced positive clinical effect already within a few hours after drug application and steady improvement with daily continuation. The patient's clinical response demonstrated an increase in communication and volitional activity, whereas no motor improvement was evident. Considering the Bradford-Hill criteria for assessing causation, causal attribution between the medication and the clinical improvement is reasonable given the temporal proximity of the apparent effect, which is consistent with the pharmacokinetic properties of the drugs, the consistency, and the analogy of the clinical phenomenon when looking at previous case reports on AM. Further support provides its biological plausibility and coherence with the literature implying involvement of the frontal-subcortical circuit in both AM and the applied medication with methylphenidate and LD/BZ. However, because this is a single individual case, a coincidental clinical improvement unrelated to the therapeutic approach cannot be conclusively ruled out.

One previous case report of AM after right frontal intracerebral hemorrhage attempted combined drug therapy with daily high doses of 40 mg methylphenidate, 450/112.5 mg LD/BZ, and 40 mg atomoxetine: apart from improved cognitive abilities and voluntary movements over time, serotonin syndrome, a severe side effect due to overdosing, ultimately forced an abrupt discontinuation [11].

We dosed the drugs based on the literature on their proven efficacy and safety in stroke patients [5, 6]. Our patient showed no drug-related clinical or laboratory changes or seriously altered vital signs during continuous monitoring. Therefore, we continued the medication regimen for 3 weeks without clinical deterioration after discontinuation. However, we lack the ideal point in time beyond which treatment cessation would be advisable.

In conclusion, this case report demonstrates that treatment with 10 mg methylphenidate and 100/25 mg LD/BZ twice daily was both safe and effective in AM following ACA infarction. We speculate that this combination might be even more beneficial than the previously described AM therapy due to its synergistic pharmacological effect. Given the limitations inherent in a single case study, further prospective cohort studies are necessary to validate and generalize these findings.

Statement of Ethics

Written informed consent was obtained from the patient's legal representative for publication of the details of their medical case and any accompanying images. Ethical approval was not required for this study in accordance with local guidelines.

Conflict of Interest Statement

The authors have no conflicts of interest to declare.

Funding Sources

The authors obtained no specific grant for this research from any funding agency in the public, commercial, or not-for-profit sectors.

Author Contributions

J.Z.: conceptualization; resources; writing – original draft; and writing – review and editing. M.L.S.: conceptualization; writing – review and editing. J.W.: writing – review and editing. K.D.: conceptualization; methodology; supervision; and writing – review and editing.

Data Availability Statement

All data generated or analyzed during this study are included in this article and its online supplementary material files. Further inquiries can be directed to the corresponding author.

References

- 1 Arnts H, van Erp WS, Lavrijsen JCM, van Gaal S, Groenewegen HJ, van den Munckhof P. On the pathophysiology and treatment of akinetic mutism. *Neurosci Biobehav Rev.* 2020;112:270–8. <https://doi.org/10.1016/j.neubiorev.2020.02.006>
- 2 ACoRM. American Congress of Rehabilitation Medicine. Recommendations for use of uniform nomenclature pertinent to patients with severe alterations in consciousness. *Arch Phys Med Rehabil.* 1995;76(2):205–9. [https://doi.org/10.1016/s0003-9993\(95\)80031-x](https://doi.org/10.1016/s0003-9993(95)80031-x)
- 3 Laureys S, Faymonville M-E, Boly M, Schnakers C, Vanhaudenhuyse A, Bruno M, et al. Bewusstseinsstörungen — Diagnose und Prognose; 2008; p. 3–16.
- 4 Otto F, Harrer C, Pilz G, Wipfler P, Harrer A. Role and relevance of cerebrospinal fluid cells in diagnostics and research: state-of-the-art and underutilized opportunities. *Diagnostics.* 2021;12(1):79. <https://doi.org/10.3390/diagnostics12010079>

- 5 Delbari A, Salman-Roghani R, Lokk J. Effect of methylphenidate and/or levodopa combined with physiotherapy on mood and cognition after stroke: a randomized, double-blind, placebo-controlled trial. *Eur Neurol.* 2011; 66(1):7–13. <https://doi.org/10.1159/000329275>
- 6 Lokk J, Salman Roghani R, Delbari A. Effect of methylphenidate and/or levodopa coupled with physiotherapy on functional and motor recovery after stroke: a randomized, double-blind, placebo-controlled trial. *Acta Neurol Scand.* 2011;123(4):266–73. <https://doi.org/10.1111/j.1600-0404.2010.01395.x>
- 7 Kim YW, Shin JC, An YS. Treatment of chronic akinetic mutism with atomoxetine: subtraction analysis of brain f-18 fluorodeoxyglucose positron emission tomographic images before and after medication: a case report. *Clin Neuropharmacol.* 2010;33(4):209–11. <https://doi.org/10.1097/WNF.0b013e3181dca948>
- 8 Guery D, Ong E, Nighoghossian N. Akinetic mutism reversibility after L-dopa therapy in unilateral left anterior cerebral artery infarction. *Neurocase.* 2017;23(2):171–2. <https://doi.org/10.1080/13554794.2017.1319493>
- 9 Combarros O, Infante J, Berciano J. Akinetic mutism from frontal lobe damage responding to levodopa. *J Neurol.* 2000;247(7):568–9. <https://doi.org/10.1007/s004150070161>
- 10 Yang CP, Huang WS, Shih HT, Lin CY, Lu MK, Kao CH, et al. Diminution of basal ganglia dopaminergic function may play an important role in the generation of akinetic mutism in a patient with anterior cerebral arterial infarct. *Clin Neurol Neurosurg.* 2007;109(7):602–6. <https://doi.org/10.1016/j.clineuro.2007.04.012>
- 11 Jeon DG, Kim YW, Kim NY, Park JH. Serotonin syndrome following combined administration of dopaminergic and noradrenergic agents in a patient with akinetic mutism after frontal intracerebral hemorrhage: a case report. *Clin Neuropharmacol.* 2017;40(4):180–2. <https://doi.org/10.1097/WNF.0000000000000220>