



Contents lists available at ScienceDirect

Asia-Pacific Journal of Sports Medicine, Arthroscopy, Rehabilitation and Technology

journal homepage: www.ap-smart.com

Original Article

Sequential analysis of three-dimensional tibiofemoral relationship through anatomic anterior cruciate ligament reconstruction with gravity-assisted radiographic technique in prone position

Yuta Tachibana^a, Tatsuo Mae^{a, *}, Konsei Shino^b, Tomohiko Matsuo^a,
Kazuomi Sugamoto^a, Hideki Yoshikawa^a, Ken Nakata^a

^a Department of Orthopaedic Surgery, Osaka University Graduate School of Medicine, 2-2, Yamada-oka, Suita-city, Osaka, 565-0871, Japan

^b Sports Orthopaedic Center, Osaka Yukioka Hospital, 2-2-3 Ukita, Kita-ku, Osaka, Osaka, 530-0021, Japan

ARTICLE INFO

Article history:

Received 21 February 2019

Received in revised form

10 July 2019

Accepted 28 August 2019

Available online 19 September 2019

Keywords:

Anatomic triple-bundle

Anterior cruciate ligament reconstruction

Computed tomography

Prone position

Tibiofemoral relationship

Three-dimensional

ABSTRACT

Background/objectives: It is important to restore the tibiofemoral relationship as well as the anterior knee laxity for more successful anterior cruciate ligament (ACL) reconstruction, since a residual abnormality in the tibiofemoral relationship would lead an abnormal stress on the articular cartilages/menisci and consequently increase the risk of osteoarthritis in the future. This study aimed to sequentially clarify the three-dimensional tibiofemoral relationship before and after anatomic anterior cruciate ligament (ACL) reconstruction under an anterior tibial load with a gravity-assisted radiographic technique in the prone position.

Methods: Fifteen patients with unilateral ACL injury participated in the study. Anatomic triple-bundle ACL reconstruction was performed using semitendinosus tendon autografts. During the computed tomography scans that were performed preoperatively, and those performed at 3 weeks and at 6 months postoperatively, the patients lay in the prone position with the knee flexed at 15°, wherein the calf weight could exert an anterior drawer force on the tibia due to gravity. Three-dimensional the tibial position relative to the femur were evaluated for each time point, followed by calculation of side-to-side differences in the parameters between the ACL-deficient/ACL-reconstructed knees and the contralateral intact knees. Seven healthy volunteers were enrolled in the control group and the side-to-side differences (right minus left) in these parameters were calculated.

Results: The tibia in the ACL-deficient knee was located anteriorly by 3.5 ± 1.1 mm and rotated internally by $2.4^\circ \pm 2.3^\circ$; these values were significantly larger than the corresponding values of -0.2 ± 1.5 mm and $0.1^\circ \pm 2.2^\circ$ in the control group. However, at 3 weeks postoperatively, the tibia in the ACL-reconstructed knee was over-constrained as compared to that in the control group; it was located posteriorly by 2.5 ± 1.4 mm and rotated externally by $3.4^\circ \pm 3.4^\circ$. At 6 months postoperatively, no significant difference was observed in the tibial displacements/rotations between the patient and control groups. The side-to-side difference in the anterior knee laxity at the manual maximum anterior load was 0.1 ± 1.2 mm at 6 months postoperatively, with a significant improvement over the preoperative value of 7.4 ± 2.5 mm.

Conclusions: Anatomic ACL reconstruction could restore not only the normal anterior knee laxity, but also the normal tibiofemoral relationship even under an anterior tibial load.

© 2019 Asia Pacific Knee, Arthroscopy and Sports Medicine Society. Published by Elsevier (Singapore) Pte Ltd. This is an open access article under the CC BY-NC-ND license (<http://creativecommons.org/licenses/by-nc-nd/4.0/>).

Introduction

Anterior cruciate ligament (ACL) reconstruction is the gold standard treatment for ACL injury. Some studies have focused on the tibiofemoral relationship in ACL-deficient or ACL-reconstructed

knees.^{1–13} However, abnormal tibiofemoral relationship persisted after a conventional single-bundle procedure despite favorable clinical outcomes,^{1,6,10,13} and this residual abnormality in the tibiofemoral relationship could lead to the osteoarthritis.^{6,14} Therefore, it is important to restore the tibiofemoral relationship as well as the knee laxity normally for more successful ACL reconstruction. ACL reconstruction has been improved from the conventional procedure to the anatomical procedure with better biomechanical characteristics.^{15,16} Moreover, some studies have

* Corresponding author. Dept. of Orthop. Surg., Osaka Univ. Graduate School of Med, Japan, 2-2, Yamada-oka, Suita-city, Osaka, 565-0871, Japan.

E-mail address: ta-mae@umin.ac.jp (T. Mae).

demonstrated that the tibiofemoral relationship was restored to normal at 4–6 months after anatomic ACL reconstruction.^{7,9,12} In those studies, the patients were set in the supine position with the knee extended wherein the tibia translated anteriorly in the ACL-deficient knee.^{4,8} Recently, using plain radiographs, Mae et al. showed the anterior tibial displacement in the ACL-deficient knee could be significantly enhanced in the prone position rather than in the standard supine position because the calf weight of the subject could exert an anterior drawer force on the tibia due to gravity without any special instruments.¹⁷ They also indicated that this gravity-assisted radiographic technique would be equally efficient in weight-bearing conditions^{2,3,11} in the anterior tibial displacement in ACL injury. However, to our knowledge, no study has investigated whether anatomic ACL reconstruction could restore the tibiofemoral relationship normally even under a loaded condition. Moreover, three-dimensional (3-D) computed tomography (CT) is useful for the evaluation of the tibiofemoral relationship in detail, including rotation. The present study aimed to clarify the tibiofemoral relationship before and after anatomic ACL reconstruction in the prone position using 3-D computer models constructed using CT images. We hypothesized that the tibiofemoral relationship could be returned to normal even under an anterior tibial load at 6 months after anatomic ACL reconstruction.

Material and methods

The appropriate institutional review board of our institution for human subject research approved the study protocol (ID: 09157-2). Informed consent was obtained from all individual participants included in the study. From January 2012 to December 2013, 15 patients with primary unilateral ACL rupture consented for study participation. The study population included nine men and six women. Their ages ranged from 16 to 44 years, and their mean age was 24.9 years at the time of surgery. The average interval from injury to surgery was 16.8 weeks, range: 3–49 weeks. For medial meniscal tears, 5 patients underwent meniscal repair for longitudinal tears. For lateral meniscal tears, 3 patients underwent meniscal repair for longitudinal tears, while one underwent partial meniscectomy because of incomplete radial tear in the middle segment. We excluded revision cases, multi-ligamentous injury cases, and cases with apparent radiographic osteoarthritis. Severe articular cartilage damage greater than grade III in Outerbridge classification was not observed in any patient. Moreover, seven healthy volunteers were also evaluated as the control group (Table 1).

Surgical technique

In this study, all the patients were treated with an anatomic

Table 1
Demographic data of the patient and control groups.

	Patient	Control	P
Number	15	7	
Age	24.9 ± 9.2	30.5 ± 1.8	0.076
Sex (male/female)	9/6	7/0	0.121
Height (cm)	165.9 ± 8.4	172.5 ± 4.1	0.078
Weight (kg)	65.3 ± 11.2	68.4 ± 9.1	0.549
Tegner activity level	7 (3–8)	4 (3–4)	0.001*
Posterior tibial slope (deg.)			
Medial compartment	9.1 ± 2.6	9.9 ± 1.5	0.341
Lateral compartment	8.8 ± 2.5	9.1 ± 2.9	0.805

deg.: degree.

Data are shown as mean ± standard deviation values, except the Tegner activity level that is presented as median (range).

Posterior tibial slope was shown in the affected knee of the patient group, while in the left knee of the control group.

triple-bundle (ATB) procedure.^{18,19} The concept of this surgical technique is to more precisely pursue the morphology of natural ACL fiber arrangement comprising three fiber bundles^{20–22} with the C-shaped tibial footprint.²³ We cleared the soft tissues, including the remnants of the torn ACL on the femoral side. Two guide pins were inserted in the femoral ACL footprint with a clear vision of a nearly longitudinal linear resident's ridge and proximal/posterior cartilage margins as the landmarks for the ACL femoral footprint.²⁴ For the tibia, three guide pins were inserted in the C-shaped tibial ACL footprint²³ surrounded by the anterior/medial intercondylar ridges and the anterior horn of the lateral meniscus.^{25,26} These guide pins were subsequently over-drilled to match the grafts' diameters. The autogenous semitendinosus tendon was previously harvested and transected into two double-looped grafts. Two Endobutton-CLs® (Smith & Nephew Endoscopy, Andover, MA, USA) were connected to each loop end of the graft and were fixed while turning the Endobuttons on the cortex of the lateral femoral condyle. The suture from the posterolateral (PL) graft was connected to one Double Spike Plate® (DSP; Smith & Nephew Endoscopy, Andover, MA, USA), and the sutures from the medial/lateral portions of the anteromedial (AM-M/AM-L) grafts were connected to the other DSP. These DSPs were then tied to the tensioners installed in a tensioning boot and were fixed to the tibia under a total initial tension of 20 N (10 N for the AM-M/AM-L grafts and 10 N for the PL graft) at 20° of knee flexion after removing the creep of the knee construct. All the operative procedures were performed by two surgeons with over 20-year experience (T.M and K.N).

Rehabilitation programs

After brace immobilization for 2 weeks, range-of-motion exercises were started. Full extension was not allowed until 3–4 weeks because the tension of ACL significantly increases in hyperextension.²⁷ Flexion angle exceeding 135° was allowed after 6 months. Partial weight bearing with crutches was allowed at 2 weeks, followed by full weight bearing at 4 weeks. Closed kinetic chain exercises such as squat and lunge were started at 2–3 months. Jogging was permitted at 3–4 months if a single-legged squat could be performed. Jumping and agility exercises were started around 4 months. Open kinetic chain exercises including leg extension with weights were carefully controlled by 6 months because the graft tension significantly increases during active extension exercise.²⁸ Return to previous sports activities including cutting and pivoting motions was gradually allowed at 7–9 months postoperatively.

CT protocols

CT imaging was performed using a helical CT scanner (Discovery CT 750HD; General Electric, Waukesha, WI, USA). Preoperative CT

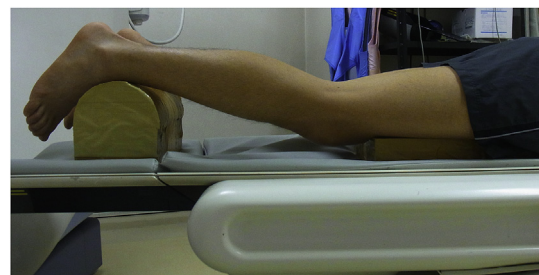

Fig. 1. Prone position with the knee flexed at 15°, wherein the calf weight of the subject could act as an anterior drawer force on the tibia due to gravity without any special instruments or devices.

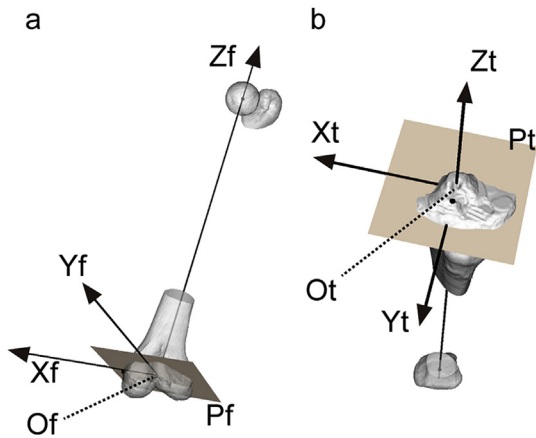


Fig. 2. **a** The femoral coordinate system was based on the centre of the femoral head and the medial/lateral epicondyles. The line between the medial and lateral epicondyles was defined as the transepicondylar axis (*TEA*). The midpoint of *TEA* was defined as the femoral origin (*Of*). The femoral proximal–distal axis (*Zf*) was created between *Of* and the centre of the femoral head. An axial plane (*Pf*) perpendicular to *Zf* was set at *Of*. The femoral medial–lateral axis (*Xf*) was created by projecting *TEA* to *Pf*. The femoral anterior–posterior axis (*Yf*) was the cross product of *Zf* and *Xf*. **b** The tibial coordinate system was based on the centre of the footprint of the anterior and posterior cruciate ligaments (*ACL* and *PCL*) and the centre of the ankle. The anterior–posterior axis (*APA*) was defined as the line between the centre of *ACL* and *PCL* insertion sites. The midpoint of the *APA* was defined as the tibial origin (*Ot*). The tibial proximal–distal axis (*Zt*) was created between *Ot* and the centre of the ankle. An axial plane (*Pt*) perpendicular to *Zt* was set at *Ot*. The tibial anterior–posterior axis (*Yt*) was created by projecting *APA* to *Pt*. The tibial medial–lateral axis (*Xt*) was the cross product of *Zt* and *Yt*.

scans were performed bilaterally, and postoperative CT scans were performed for the operated knee at 3 weeks and 6 months postoperatively. The patients were set in the prone position with the knee flexed at 15° of flexion since the gravity-assisted radiographic technique in the prone position was most preferable at 15° of knee flexion because of higher correlation with instrumented anterior laxity¹⁷ (Fig. 1). The thigh was adjusted to keep the patella downward, and the ankle was adjusted to keep the medial/lateral malleoli horizontal. The knee flexion angle was set at 15° with the use of a goniometer while adjusting a semi-cylindrical stand in front of the ankle because the length of the shank varied among individuals. Then, it was re-confirmed using a scout view. During CT examinations, the patients were asked to relax the contracting muscles, otherwise the leg dominance or muscle atrophy can affect the tibiofemoral relationship in the quadriceps contraction technique.^{29–31} The volume areas included the femoral head, the knee joint at 11 cm above and below the joint line, and the ankle joint at 3 cm above and below the joint line. The milliampere-seconds (mAs) varied for the three following regions: 80 mAs for the hip joint, 100 mAs for the knee joint, and 45 mAs for the ankle joint. The kilovoltage (kV) and slice thickness values were 120 kV and 1.25 mm, respectively, at each region. Digital Imaging and Communications in Medicine data obtained from the CT scans were transferred to a personal computer (Dell Precision T1600; Dell, Round Rock, TX, USA). Using a program based on a modified version of the Visualization Tool Kit (Kitware Inc., Clifton Park, NY, USA), these data were reconstructed into 3-D constructs.

Tibiofemoral relationship

The anatomical femoral and tibial coordinate systems were created based on a previous report.⁷ The femoral coordinate system was based on the centre of the femoral head and the medial/lateral epicondyles (Fig. 2-a). The tibial coordinate system was based on

the centre of the footprint of the ACL/posterior cruciate ligament and the centre of the ankle (Fig. 2-b). The coordinate systems of the ACL-deficient and ACL-reconstructed knees were generated by superimposing the mirror images of the contralateral intact knees. Thereafter, the 3-D tibial position relative to the femur was evaluated at each time point. Anterior–posterior/medial–lateral displacement was defined as the distance between the point of the femoral origin projected on the tibial axial plane and the tibial medial–lateral/anterior–posterior axes. Internal–external rotation was defined as the angle between the line of the femoral medial–lateral axis projected to the tibial axial plane and the tibial medial–lateral axis (Fig. 3-a). Varus–valgus rotation was defined as the angle between the line of the femoral proximal–distal axis projected to the tibial coronal plane and the tibial proximal–distal axis (Fig. 3-b). The intra- and inter-observer intra-class correlation coefficients were reliable, according to the previous report.⁷ As the position of the tibia relative to the femur and the sizes of the knee joints varied among individuals, the side-to-side differences in the tibial position relative to the femur were calculated between the ACL-deficient/ACL-reconstructed knees and the contralateral intact knees for the subjects in the patient group. In a similar manner, the side-to-side differences (right minus left) in these parameters were calculated for the control group. We 1) clarified the sequential change in the tibiofemoral relationship before and after the ATB ACL reconstruction, and 2) compared the tibiofemoral relationship between the control and patient groups. All the measurement of the tibiofemoral relationship was performed by one orthopaedic surgeon (Yuta Tachibana) and the average values of the three-time measurement were used for analysis. Additionally, we measured the posterior tibial slopes in the medial and lateral compartments in the patient and control groups (Fig. 4-a, b) (Table 1), because the posterior tibial slope might affect anterior tibial displacement in the ACL-deficient knee³¹.

Clinical examinations

Physical examinations were performed at 6 months and 2 years postoperatively for loss of range of motion, knee swelling, Lachman sign, and pivot shift test. KT-2000 Knee Arthrometer (MEDmetric, San Diego, CA, USA) was also used to measure the anterior knee laxity before surgery under general anesthesia without the administration of anesthesia.

Statistical analyses

All the statistical tests were performed using JMP software (version 13.0; SAS Institute Inc., Cary, NC, USA). A power analysis with a power of 0.8 and α value of 0.05 indicated that a minimum of 7 patients was required for comparing the preoperative tibial anterior displacement between the two groups; a 3.2-mm difference with a standard deviation of ± 1.1 mm. The Wilcoxon signed-rank test was used to detect statistically significant differences in the anterior–posterior/medial–lateral displacement and the internal–external/varus–valgus rotation within the patient group among the different time points and in the anterior knee laxity between 6 month and 2 years postoperatively. The Wilcoxon rank-sum test was used to compare the side-to-side differences in the tibiofemoral relationship the posterior tibial slope, and the demographic data between the two groups, while the Fisher's exact test was used to compare the differences in sex and Tegner activity level between the two groups and in the clinical outcomes except for the anterior knee laxity between 6 months and 2 years postoperatively. Values of $P < 0.05$ were considered statistically significant.

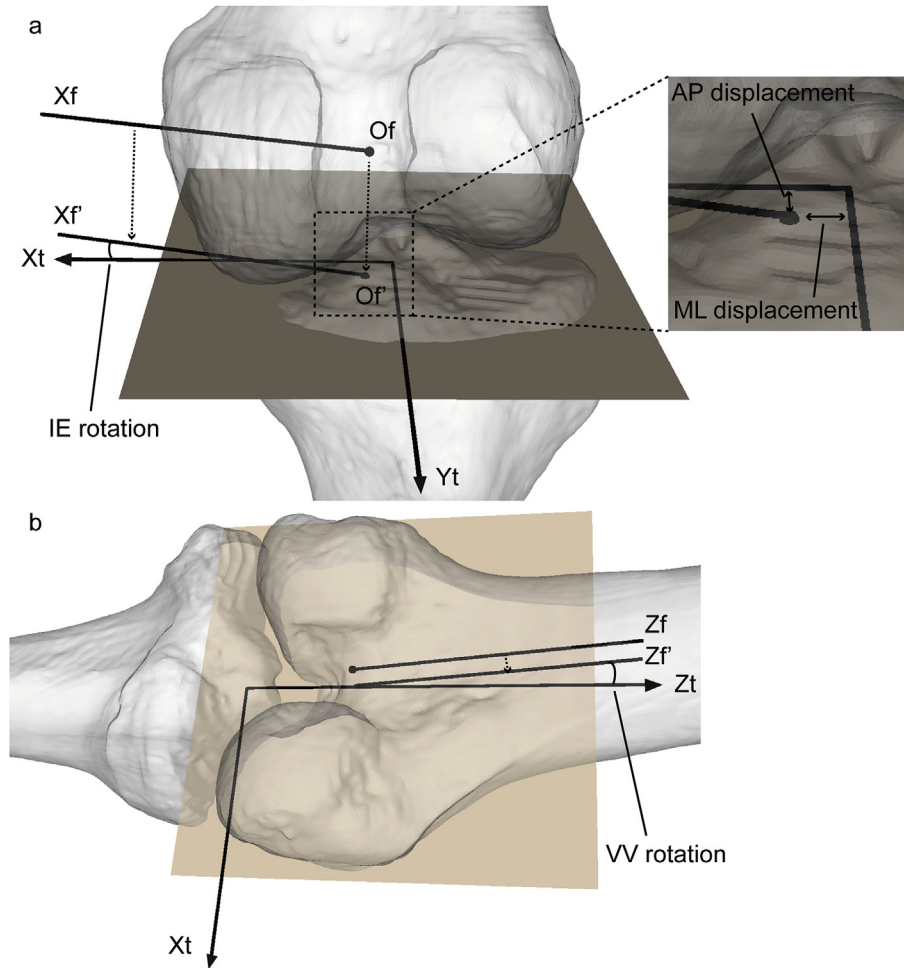


Fig. 3. **a** Measurement of anterior–posterior (AP) and medial–lateral (ML) displacement, and internal–external (IE) rotation of the tibia relative to the femur. O_f' and X_f' were created by projecting the femoral origin (O_f) and femoral medial–lateral axis (X_f) to the tibial axial plane. AP displacement was defined as the distance between O_f' and the tibial medial–lateral axis (X_t). ML displacement was defined as the distance between O_f' and the tibial anterior–posterior axis (Y_t). Internal–external (IE) rotation was defined as the angle between X_f' and X_t . **b** Measurement of varus–valgus (VV) rotation of the tibia relative to the femur. Z_f' was created by projecting the femoral proximal–distal axis (Z_f) to the tibial coronal plane. Varus–valgus (VV) rotation was defined as the angle between Z_f' and the tibial proximal–distal axis (Z_t).

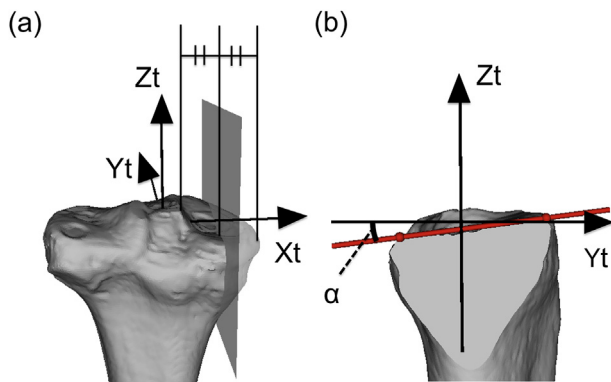


Fig. 4. **a** The 3-D construct of the tibia was sectioned by a slice, which was parallel to the plane consisting of the anterior–posterior axis (Y_t) and proximal–distal axis (Z_t) and was located at the middle of the tip of the medial intercondylar tubercle and the medial-most point of the tibial plateau. The procedure was performed in the lateral compartment as well. **b** Measurement of the posterior tibial slope in the medial compartment. The posterior tibial slope was calculated as the angle (α) between the tibial anterior–posterior axis (Y_t) and the line (red solid line) connecting the anterior-most point to the posterior-most point on the tibial joint surface. Measurement of the posterior tibial slope in the lateral compartment was also calculated in a same manner.

Results

Tibiofemoral relationship

In the sequential changes of the tibiofemoral relationship within the patient group, the anteriorly translated and internally rotated tibia in the ACL-deficient knee significantly moved posteriorly/laterally and rotated externally/valgus at 3 weeks postoperatively. Thereafter, from 3 weeks to 6 months postoperatively, the tibia significantly translated anteriorly/medially and rotated internally/varus, and it was located quite close to the contralateral intact knee (Fig. 5).

Regarding the comparison of the tibial position between the patient and control groups, the preoperative side-to-side differences in the anterior displacement and the internal rotation in the patient group were 3.5 ± 1.1 mm and $2.4^\circ \pm 2.3^\circ$, respectively; these values were significantly larger than the corresponding values of -0.2 ± 1.5 mm and $0.1^\circ \pm 2.2^\circ$, respectively, in the control group. At 3 weeks postoperatively, the tibia in the ACL-reconstructed knee was located posteriorly/laterally and rotated externally as compared to that in the control group, with significant differences. At 6 months postoperatively, no significant difference was detected in the tibial displacements/rotations between the patient and

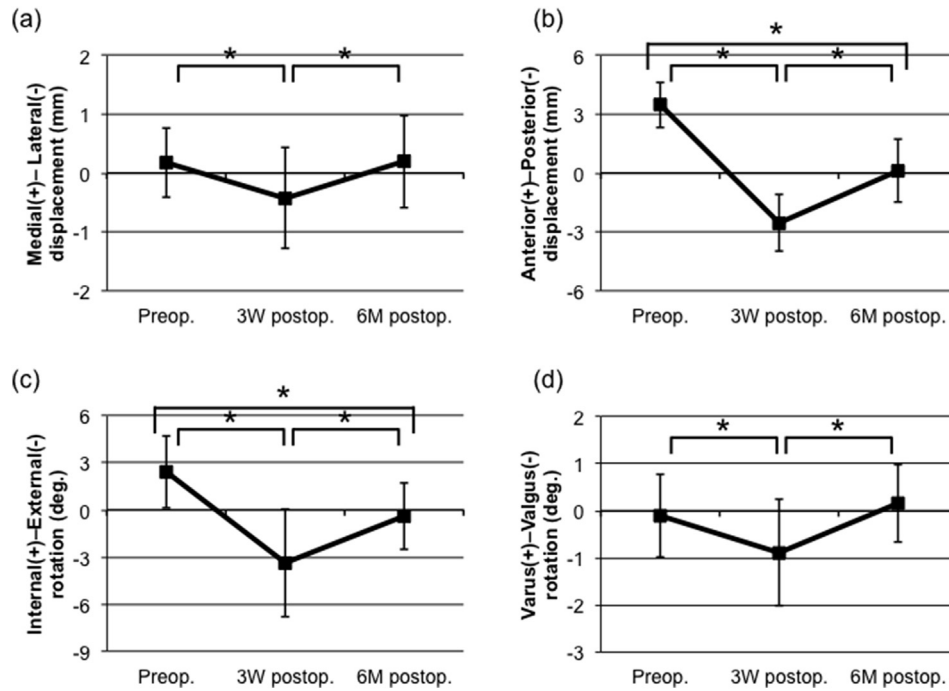


Fig. 5. Sequential changes of the side-to-side difference in the tibial position within the patient group. **a** Medial–lateral displacement. **b** Anterior–posterior displacement. **c** Internal–external rotation. **d** Varus–valgus rotation.

Preop.: preoperatively, 3W postop.: 3 weeks postoperatively, 6M postop.: 6 months postoperatively, deg.: degree

Positive values indicate anterior/medial displacement and internal/varus rotation of the tibia

*: P < 0.05.

Table 2
Side-to-side difference of tibial position.

	Control	Patient		
		Preop.	3W postop.	6M postop.
ML displacement (mm)	0.3 ± 1.1	0.2 ± 0.5	-0.4 ± 0.9*	0.2 ± 0.8
AP displacement (mm)	-0.2 ± 1.5	3.5 ± 1.1*	-2.5 ± 1.4*	0.1 ± 1.6
IE rotation (deg.)	0.1 ± 2.2	2.4 ± 2.3*	-3.4 ± 3.4*	-0.4 ± 2.1
VV rotation (deg.)	-0.2 ± 0.9	-0.1 ± 0.9	-0.9 ± 1.1	0.2 ± 0.8

ML: medial–lateral, AP: anterior–posterior, IE: internal–external, VV: varus–valgus, Preop.: preoperatively, 3W postop.: 3 weeks postoperatively, 6M postop.: 6 months postoperatively, deg.: degree.

Positive values indicate medial/anterior displacement and internal/varus rotation of the tibia.

Data are shown as mean ± standard deviation values, followed by calculation of the side-to-side difference in the tibial position; affected minus contralateral side for the patient group and the right minus left side for the control group.

*: P < 0.05 (compared with the control group).

control groups (Table 2).

Clinical outcomes

In the clinical outcomes at 2 years, all the patients belonged to normal or nearly normal in the IKDC subjective assessment. Tegner activity level did not significantly decrease comparing the preoperative one, while two patients decreased because of no longer performing club activities. There was no patient suffering loss of range of motion exceeding 5°, knee swelling, or positive Lachman sign, while one patient showing glide in pivot shift test. The side-to-side difference in the anterior knee laxity at the manual maximum anterior load with KT-2000 Knee Arthrometer was 0.3 ± 1.1 mm, indicating a significant improvement over the preoperative value of 7.4 ± 2.5 mm (P < 0.001) There was no significant change in clinical outcomes from 6 months to 2 years postoperatively (Table 3).

Discussion

The principal findings of this study was that anteriorly located and internally rotated tibial position before surgery returned to normal at 6 months after the ATB ACL reconstruction even under an anterior tibial load with the gravity-assisted radiographic technique in the prone position; however, it was over-constrained at 3 weeks.

The normal ACL fiber runs in the anterior/distal directions from the medial wall of the lateral femoral condyle to the anteromedial aspect on the tibial plateau, maintaining the tibiofemoral relationship. Thus, it is reasonable to expect that the tibia would translate anteriorly and rotate internally when the ACL is torn.^{3,7,11} Some previous studies have investigated the 3-D tibiofemoral relationship in the ACL-deficient knee under weight-bearing conditions. Using a load-bearing device, applying a 125-N axial load, Shefelbine et al. reported 2.6-mm anterior tibial displacement at full extension in the ACL-deficient knees.¹¹ Defrate et al. investigated the knee kinematics during a quasi-static lunge by projecting 3-D computer model reconstructed using magnetic resonance images onto dual fluoroscopic images and showed that the tibia in the ACL-deficient knees translated anteriorly by 3 mm and rotated internally by 2° around knee extension.³ In the present study, under a non-weight bearing condition without any special devices, the anterior displacement and internal rotation in the ACL-deficient knees were 3.5 ± 1.1 mm and 2.4° ± 2.3°, respectively, in the prone position, and the value of anterior displacement/internal rotation was equivalent to that under weight-bearing conditions.^{3,11} Thus, the gravity-assisted radiographic technique in the prone position with knee flexed at 15° was simple and useful for evaluating the 3-D tibiofemoral relationship in the ACL-deficient knees.

The tibia significantly shifted posteriorly/laterally and rotated externally/valgus from preoperatively to 3 weeks after the ATB ACL

Table 3
Clinical outcomes at 6 months and 2 years postoperatively.

	6 M postop.	2Y postop.	P
IKDC subjective assessment (A/B/C/D)	N.A.	8/7/0/0	N.A.
Tegner activity level	N.A.	7 (3–8)	N.A.
Swelling	0	0	1.000
Loss of range of motion > 5°			
Extension	0	0	1.000
Flexion	0	0	1.000
Lachman sign			
Negative/Trace/Positive	15/0/0	15/0/0	1.000
Pivot shift test			
Equal/Glide/Gross/Marked	15/0/0/0	14/1/0/0	1.000
SSD of anterior knee laxity with KT-2000 (mm)	0.1 ± 1.2	0.3 ± 1.1	0.750
Joint space narrowing			
PF (none/<50%/>50%)	15/0/0	15/0/0	1.000
Medial TF (none/<50%/>50%)	15/0/0	15/0/0	1.000
Lateral TF (none/<50%/>50%)	14/1/0	14/1/0	1.000

6 M postop.: 6 months postoperatively, 2Y postop.: 2 years postoperatively, SSD: side-to-side difference, PF: patellofemoral, TF: tibiofemoral, N.A.: not available. In the IKDC subjective assessment, 'A, B, C, and D' indicated 'normal, nearly normal, abnormal, and severely abnormal', respectively.

reconstruction, and the tibia in the patient group was over-constrained as compared to that in the control group. A previous study has reported that the side-to-side difference in anterior knee laxity under 89-N anterior load was -4.2 ± 2.0 mm immediately after the ATB ACL reconstruction.³³ It was indicated that the over-constrained condition at the immediate postoperative time point still remained until 3 weeks postoperatively. Therefore, post-operative rehabilitation programs should be carefully planned, considering that an abnormal tibiofemoral relationship was still present at 3 weeks postoperatively. Some studies have encouraged accelerated rehabilitation protocols wherein full weight bearing and active knee extension exercises are initiated immediately after the procedure.^{34,35} However, we recommend a mild rehabilitation program in the early postoperative stage because the abnormal tibiofemoral relationship may lead to abnormal stress on the articular cartilage.⁵

Through graft remodelling procedures, such as the revascularization and repopulation processes, the transplanted graft was weakened to some degree, and the laxity increased within 6 months after ACL reconstruction in animal models.³⁶ This study showed that the tibia significantly shifted anteriorly/medially and rotated internally/varus from 3 weeks to 6 months and that the tibial position returned to normal at 6 months; namely, the over-constrained condition at the immediate postoperative term would be released and the anatomically transplanted graft would achieve the stability equivalent to that of the intact knee through the graft remodelling procedures.

Previous studies have shown that the abnormal tibiofemoral relationship still remained after a conventional single-bundle ACL reconstruction, although arthrometric knee laxity was favorable.^{1,3,10,13} It is a concern that the abnormal tibiofemoral relationship can lead to stress concentration on the meniscus^{11,37} or on the articular cartilage^{5,6} and osteoarthritis in the future.¹⁴ In contrast, this study demonstrated that the anteriorly located and internally rotated tibia in the ACL-deficient knee returned close to the normal position at 6 months after ATB ACL reconstruction with satisfactory anterior knee laxity at 6 months and 2 years. Therefore, the clinical relevance in this study was that anatomic ACL reconstruction could restore not only the normal anterior knee laxity, but also the normal tibiofemoral relationship even under an anterior tibial load.

This study has certain limitations. First, the postoperative follow-up term using 3-D CT images was only 6 months and we will further follow-up the tibiofemoral relationship. In a previous study

investigating the anterior knee laxity with KT-1000 Knee Arthrometer, the reconstructed knee was over-constrained immediately postoperatively after anatomic ACL reconstruction; however, the anterior knee laxity became close to that in the contralateral intact knee at 3 months and persisted for up to 2 years.³⁸ This study also demonstrated that the anterior knee laxity restored normally at 6 months and did not significantly change from 6 months to 2 years. Thus, the normally restored tibiofemoral relationship at 6 months was expected to continue thereafter. Second, we used only an operative technique: ATB ACL reconstruction. We might have to compare the tibiofemoral relationship after TB technique with that after single- or double-bundle techniques. However, anatomic reconstruction with anatomic tunnel placement is more important matter than surgical procedure such as single- or multiple-bundle techniques.³⁹ Third, we evaluated the tibiofemoral relationship in only one position; the prone position with the knee flexed at 15°. It might be clinically interesting to evaluate the tibiofemoral relationship in various positions in the same patients. However, there is a concern regarding too much radiation exposure during the simultaneous performance of CT scans in various positions. Third, we did not evaluate the correlation between the anterior tibial displacement in plain radiographs¹⁷ and 3-D CT images. Fourth, it is certainly that the body size/weight of the patients affect the anterior drawer force on the tibia in the prone position because the calf weight correlates to the body weight. However, there was no significant difference of the weight or height between the patient and control groups. Thus, the effect of weight/size of calves would be small in this study. Fifth, it might be better to exclude meniscal tears because the anterior tibial displacement was larger after medial meniscectomy in the ACL-deficient/ACL-reconstructed knees.^{32,37,40} All the meniscal tears underwent meniscal repair except one with partial lateral meniscectomy for an incomplete radial tear. Moreover, our ACL reconstruction could restore the normal tibiofemoral relationship. Thus, the effect of the meniscal tear might be small in this study. Finally the control group consisted of only men with lower Tegner activity level; this may have exerted a slight influence on the results.

Conclusion

Anatomic ACL reconstruction could restore not only the normal anterior knee laxity, but also the normal tibiofemoral relationship even under an anterior tibial load.

Conflicts of interest

The authors have no conflicts of interest relevant to this article.

Funding/support statement

This research did not receive any specific grant from funding agencies in the public, commercial, or not-for-profit sectors.

Acknowledgements

The authors would like to thank Dr. Tsuyoshi Murase and Mr. Ryoji Nakao for developing the software.

Appendix A. Supplementary data

Supplementary data to this article can be found online at <https://doi.org/10.1016/j.asmart.2019.08.001>.

References

- Almekinders LC, de Castro D. Fixed tibial subluxation after successful anterior cruciate ligament reconstruction. *Am J Sports Med.* 2001;29(3):280–283.
- Almekinders LC, Chiavetta JB. Tibial subluxation in anterior cruciate ligament-deficient knees: implications for tibial tunnel placement. *Arthroscopy.* 2001;17(9):960–962.
- Defrate LE, Papannagari R, Gill TJ, Moses JM, Pathare NP, Li G. The 6 degrees of freedom kinematics of the knee after anterior cruciate ligament deficiency: an in vivo imaging analysis. *Am J Sports Med.* 2006;34(8):1240–1246.
- Fukuta H, Takahashi S, Hasegawa Y, Ida K, Iwata H. Passive terminal extension causes anterior tibial translation in some anterior cruciate ligament-deficient knees. *J Orthop Sci.* 2000;5(3):192–197.
- Hosseini A, Van de Velde S, Gill TJ, Li G. Tibiofemoral cartilage contact biomechanics in patients after reconstruction of a ruptured anterior cruciate ligament. *J Orthop Res.* 2012;30(11):1781–1788.
- Logan MC, Williams A, Lavelle J, Gedroyc W, Freeman M. Tibiofemoral kinematics following successful anterior cruciate ligament reconstruction using dynamic multiple resonance imaging. *Am J Sports Med.* 2004;32(4):984–992.
- Matsuo T, Mae T, Shino K, et al. Tibiofemoral relationship following anatomic triple-bundle anterior cruciate ligament reconstruction. *Knee Surg Sport Traumatol Arthrosc.* 2014;22(9):2128–2135.
- Mishima S, Takahashi S, Kondo S, Ishiguro N. Anterior tibial subluxation in anterior cruciate ligament-deficient knees: quantification using magnetic resonance imaging. *Arthroscopy.* 2005;21(10):1193–1196.
- Muller B, Duerr ER, van Dijk CN, Fu FH. Anatomic anterior cruciate ligament reconstruction: reducing anterior tibial subluxation. *Knee Surg Sport Traumatol Arthrosc.* 2016;24(9):3005–3010.
- Papannagari R, Gill TJ, Defrate LE, Moses JM, Petruska AJ, Li G. In vivo kinematics of the knee after anterior cruciate ligament reconstruction: a clinical and functional evaluation. *Am J Sports Med.* 2006;34(12):2006–2012.
- Shefelbine SJ, Ma CB, Lee KY, et al. MRI analysis of in vivo meniscal and tibiofemoral kinematics in ACL-deficient and normal knees. *J Orthop Res.* 2006;24(6):1208–1217.
- Take Y, Shino K, Mae T, et al. Early structural results after anatomic triple bundle anterior cruciate ligament reconstruction validated by tunnel location, graft orientation, and static anteroposterior tibia-femur relationship. *Arthroscopy.* 2018;34(9):2656–2665.
- Tashman S, Collon D, Anderson K, Kolowich P, Anderst W. Abnormal rotational knee motion during running after anterior cruciate ligament reconstruction. *Am J Sports Med.* 2004;32(4):975–983.
- Zaid M, Lansdown D, Su F, et al. Abnormal tibial position is correlated to early degenerative changes one year following ACL reconstruction. *J Orthop Res.* 2015;33(7):1079–1086.
- Kato Y, Ingham SJ, Maeyama A, et al. Biomechanics of the human triple-bundle anterior cruciate ligament. *Arthroscopy.* 2012;28(2):247–254.
- Mae T, Shino K, Matsumoto N, Hamada M, Yoneda M, Nakata K. Anatomical two-bundle versus Rosenberg's isometric bi-socket ACL reconstruction: a biomechanical comparison in laxity match pretension. *Knee Surg Sport Traumatol Arthrosc.* 2007;15(4):328–334.
- Mae T, Shino K, Hiramatsu K, Tachibana Y, Nakagawa S, Yoshikawa H. Anterior laxity of the knee assessed with gravity stress radiograph. *Skelet Radiol.* 2018;47(10):1349–1355.
- Shino K, Nakata K, Nakamura N, et al. Anatomic anterior cruciate ligament reconstruction using two double-looped hamstring tendon grafts via twin femoral and triple tibial tunnels. *Oper Tech Orthop.* 2005;15(2):130–134.
- Shino K, Mae T, Tachibana Y. Anatomic ACL reconstruction: rectangular tunnel/bone-patellar tendon-bone or triple-bundle/semitendinosus tendon grafting. *J Orthop Sci.* 2015;20(3):457–468.
- Norwood LA, Cross MJ. Anterior cruciate ligament: functional anatomy of its bundles in rotatory instabilities. *Am J Sports Med.* 1979;7(1):23–26.
- Otsubo H, Shino K, Suzuki D, et al. The arrangement and the attachment areas of three ACL bundles. *Knee Surg Sport Traumatol Arthrosc.* 2012;20(1):127–134.
- Suzuki D, Otsubo H, Watanabe T, et al. Ultrastructure of the three anterior cruciate ligament bundles. *Clin Anat.* 2015;28(7):910–916.
- Siebold R, Schuhmacher P, Fernandez F, et al. Flat midsubstance of the anterior cruciate ligament with tibial "C"-shaped insertion site. *Knee Surg Sport Traumatol Arthrosc.* 2015;23(11):3136–3142.
- Iwashita T, Shino K, Nakata K, et al. Direct anterior cruciate ligament insertion to the femur assessed by histology and 3-dimensional volume-rendered computed tomography. *Arthroscopy.* 2010;26(9 Suppl):S13–S20.
- Kusano M, Yonetani Y, Mae T, Nakata K, Yoshikawa H, Shino K. Tibial insertions of the anterior cruciate ligament and the anterior horn of the lateral meniscus: a histological and computed tomographic study. *The Knee.* 2017;24(4):782–791.
- Tensho K, Shimodaira H, Aoki T, et al. Bony landmarks of the anterior cruciate ligament tibial footprint: a detailed analysis comparing 3-dimensional computed tomography images to visual and histological evaluations. *Am J Sports Med.* 2014;42(6):1433–1440.
- Markolf KL, Gorek JF, Kabo JM, Shapiro MS. Direct measurement of resultant forces in the anterior cruciate ligament. An in vitro study performed with a new experimental technique. *J Bone Joint Surg Am.* 1990;72(4):557–567.
- Mae T, Shino K, Matsumoto N, Maeda A, Nakata K, Yoneda M. Graft tension during active knee extension exercise in anatomic double-bundle anterior cruciate ligament reconstruction. *Arthroscopy.* 2010;26(2):214–222.
- Franklin JL, Rosenberg TD, Paulos LE, France EP. Radiographic assessment of instability of the knee due to rupture of the anterior cruciate ligament. A quadriceps-contraction technique. *J Bone Joint Surg Am.* 1991;73(3):365–372.
- Lerat JL, Moyer BL, Cladière F, Besse JL, Abidi H. Knee instability after injury to the anterior cruciate ligament. Quantification of the Lachman test. *J Bone Joint Surg Br.* 2000;82(1):42–47.
- Lanshammar K, Ribom EL. Differences in muscle strength in dominant and non-dominant leg in females aged 20–39 years—a population-based study. *Phys Ther Sport.* 2011;12(2):76–79.
- Dejour D, Pungitore M, Valluy J, Nover L, Saffarini M, Demey G. Preoperative laxity in ACL-deficient knees increases with posterior tibial slope and medial meniscal tears. *Knee Surg Sport Traumatol Arthrosc.* 2019;27(2):564–572.
- Mae T, Shino K, Matsumoto N, Yoneda K, Yoshikawa H, Nakata K. Immediate postoperative anterior knee stability: double- versus triple-bundle anterior cruciate ligament reconstructions. *Arthroscopy.* 2013;29(2):213–219.
- Beynonn BD, Johnson RJ, Naud S, et al. Accelerated versus nonaccelerated rehabilitation after anterior cruciate ligament reconstruction: a prospective, randomized, double-blind investigation evaluating knee joint laxity using roentgen stereophotogrammetric analysis. *Am J Sports Med.* 2011;39(12):2536–2548.
- Van Grinsven S, Van Cingel RE, Holla CJ, van Loon CJ. Evidence-based rehabilitation following anterior cruciate ligament reconstruction. *Knee Surg Sport Traumatol Arthrosc.* 2010;18(8):1128–1144.
- Drez Jr DJ, DeLee J, Holden JP, Arnoczky S, Noyes FR, Roberts TS. Anterior cruciate ligament reconstruction using bone-patellar tendon-bone allografts. A biological and biomechanical evaluation in goats. *Am J Sports Med.* 1991;19(3):256–263.
- Allen CR, Wong EK, Livesay GA, Sakane M, Fu FH, Woo SL. Importance of the medial meniscus in the anterior cruciate ligament-deficient knee. *J Orthop Res.* 2000;18(1):109–115.
- Mae T, Shino K, Matsumoto N, et al. Anatomic double-bundle anterior cruciate ligament reconstruction using hamstring tendons with minimally required initial tension. *Arthroscopy.* 2010;26(10):1289–1295.
- Kondo E, Merican AM, Yasuda K, Amis AA. Biomechanical comparison of anatomic double-bundle, anatomic single-bundle, and nonanatomic single-bundle anterior cruciate ligament reconstructions. *Am J Sports Med.* 2011;39:279–288.
- Dejour D, Pungitore M, Valluy J, Nover L, Saffarini M, Demey G. Tibial slope and medial meniscectomy significantly influence short-term knee laxity following ACL reconstruction. *Knee Surg Sport Traumatol Arthrosc.* 2019;26. <https://doi.org/10.1007/s00167-019-05435-0>.