

Diagnostic accuracy of ^{18}F -FDG PET/CT for detecting synchronous advanced colorectal neoplasia in patients with gastric cancer

Byung Wook Choi, MD^{a,*}, Hae Won Kim, MD, PhD^{a,*}, Kyoung Sook Won, MD, PhD^a, Bong-Il Song, MD^a, Kwang Bum Cho, MD, PhD^b, Sung Uk Bae, MD^c

Abstract

Preoperative screening for synchronous colorectal neoplasia (CRN) has been recommended in patients with gastric cancer because patients with gastric cancer are at increased risk for synchronous CRN. The aim of this study was to investigate the diagnostic accuracy of ^{18}F -fluorodeoxyglucose (^{18}F -FDG) positron emission tomography/computed tomography (PET/CT) for detecting synchronous advanced CRN in patients with gastric cancer.

A total of 256 patients who underwent colonoscopy and ^{18}F -FDG PET/CT for preoperative staging were enrolled in this study. The diagnosis of focal colonic ^{18}F -FDG uptake on ^{18}F -FDG PET/CT image was made based on histopathologic results from the colonoscopic biopsy. The ^{18}F -FDG PET/CT result was considered as true positive for advanced CRN when focal ^{18}F -FDG uptake matched colorectal carcinoma or adenoma with high-grade dysplasia in the same location on colonoscopy.

Synchronous advanced CRN was detected in 21 of the 256 patients (4.7%). Sensitivity, specificity, and accuracy of ^{18}F -FDG PET/CT were 76.2%, 96.2%, and 94.5%. The size of CRN with a true positive result was significantly larger than that with a false negative result.

^{18}F -FDG PET/CT demonstrated high diagnostic accuracy for detecting synchronous advanced CRN in patients with gastric cancer. Colonoscopy is recommended as the next diagnostic step for further evaluation of a positive ^{18}F -FDG PET/CT result in patients with gastric cancer.

Abbreviations: ^{18}F -FDG = ^{18}F -fluorodeoxyglucose, CRC = colorectal carcinoma, CRN = colorectal neoplasia, HGD = high-grade dysplasia, LGD = low-grade dysplasia, PET/CT = positron emission tomography/computed tomography, SUV_{max} = maximum standardized uptake value.

Keywords: gastric cancer, positron emission tomography, sensitivity, specificity, synchronous colorectal cancer

Editor: Feng Yang.

Funding: This research was supported by the Bisa Research Grant of Keimyung University in 2014.

Ethical approval: All procedures involving human participants were in accordance with the ethical standards of the institutional research committee and with the 1964 Helsinki declaration. Consent was not required for this type of study.

Informed consent: The institutional review board of Dongsan Medical Center granted exempt status for this retrospective study and waived the need for informed consent.

The authors have no conflicts of interest to disclose.

^a Department of Nuclear Medicine, ^b Department of Internal Medicine,

^c Department of Surgery, Keimyung University Dongsan Medical Center, Daegu, Republic of Korea.

* Correspondence: Hae Won Kim, Department of Nuclear Medicine, Keimyung University Dongsan Medical Center, 56 Dalseong-ro, Jung-gu, Daegu 700-712, Republic of Korea (e-mail: hwkim.nm@gmail.com); Byung Wook Choi, Department of Nuclear Medicine, Keimyung University, School of Medicine, 56 Dalseong-ro, Jung-gu, Daegu 700-712, Republic of Korea (e-mail: nmchoibw@gmail.com).

Copyright © 2016 the Author(s). Published by Wolters Kluwer Health, Inc. All rights reserved.

This is an open access article distributed under the Creative Commons Attribution-NoDerivatives License 4.0, which allows for redistribution, commercial and non-commercial, as long as it is passed along unchanged and in whole, with credit to the author.

Medicine (2016) 95:36(e4741)

Received: 11 May 2016 / Received in final form: 4 August 2016 / Accepted: 6 August 2016

<http://dx.doi.org/10.1097/MD.0000000000004741>

1. Introduction

Gastric cancer is the fifth common form of cancer and the third leading cause of cancer-related deaths worldwide.^[1] Increased incidence of early gastric cancer and advances in cancer treatment, including surgical skills and adjuvant and neoadjuvant therapy, have improved the survival rate of patients with gastric cancer. Patients with gastric cancer have a risk of developing second primary cancer, and colorectal carcinoma (CRC) is the most common neoplasm associated with gastric cancer.^[2,3] The improved prognosis for gastric cancer has also led to an increased incidence of synchronous CRC, which negatively influences the prognosis of patients with gastric cancer.^[4–6] Thus, early identification of synchronous cancer may have an impact on patient management and outcome.^[7,8]

^{18}F -fluorodeoxyglucose (^{18}F -FDG) positron emission tomography/computed tomography (PET/CT) is a noninvasive imaging modality that reflects glucose metabolism and has been widely accepted for diagnosing, staging, restaging, and evaluating the therapeutic response to gastric cancer^[9,10] and CRC.^[11,12] ^{18}F -FDG PET/CT is also effective for screening synchronous cancer in patients with several different kinds of cancer,^[13] because incidental ^{18}F -FDG accumulation reflects additional pathology unrelated to the primary cancer for which the patient was originally referred for PET/CT.^[14] Several studies have reported that incidental colorectal ^{18}F -FDG-avid lesions are associated with colorectal neoplasia (CRN) and that ^{18}F -FDG PET/CT is

effective for detecting synchronous CRN in patients with different types of cancer, including lung, esophageal, pancreatic, and breast cancers.^[12,15,16] However, the diagnostic value of ¹⁸F-FDG PET/CT for detecting synchronous CRN in patients with gastric cancer has not been reported. The purpose of this study was to investigate the diagnostic accuracy of ¹⁸F-FDG PET/CT for detecting synchronous advanced CRN in patients with gastric cancer.

2. Materials and methods

2.1. Patients

The medical records of 1750 consecutive patients with gastric cancer, who underwent ¹⁸F-FDG PET/CT for preoperative staging between May 2008 and July 2014 at Dongsan Medical Center, were reviewed. The exclusion criteria were applied as follows: patients who did not undergo colonoscopy, patients with more than 1 month between ¹⁸F-FDG PET/CT and colonoscopy, patients who had colorectal lesions removed during colonoscopy before ¹⁸F-FDG PET/CT, patients with nonepithelial or metastatic tumors in the colon, and patients with a history of other malignancies including CRC or operations of the colon. Demographic characteristics and histopathological data of the patients were obtained retrospectively. The institutional review board of Dongsan Medical Center approved this study.

2.2. Colonoscopy and histopathology

Colonoscopy was performed within 1 month before or after ¹⁸F-FDG PET/CT by experienced endoscopists. All patients prepared their bowel with 4L of polyethylene glycol solution. Conscious sedation was achieved with intravenous administration of 0.1 mg/kg midazolam and 50 mg meperidine. The procedure was mainly performed with a single-channel lower gastrointestinal endoscope (CF Q260AI; Olympus Optical Co., Tokyo, Japan).

Biopsy, polypectomy, or endoscopic mucosal resection was performed as indicated. All endoscopic specimens were evaluated by a single experienced pathologist who was completely blinded to the endoscopic diagnosis. The histopathological diagnosis was based on World Health Organization criteria.^[17] Adenomas were classified into adenomas with high-grade dysplasia (HGD) and adenomas with low-grade dysplasia (LGD), depending on the degree of glandular or villous complexity, extent of nuclear stratification, and severity of abnormal nuclear morphology. An advanced CRN was defined as an adenoma with a diameter of 10 mm or more, a villous adenoma (i.e., at least 25% villous), an adenoma with HGD, or CRC.^[18,19]

2.3. ¹⁸F-FDG PET/CT

¹⁸F-FDG PET/CT was performed using 2 different PET/CT systems (Discovery STE-16, GE Healthcare, Milwaukee, WI, and Biograph mCT-64, Siemens Healthcare, Knoxville, TN). The patients were required to fast for >6 hours before the scan, and blood glucose level was checked to confirm that the level was <180 mg/dL before injecting the ¹⁸F-FDG. All diabetic patients were asked to stop taking their antihyperglycemic drugs 12 hours before the scan. Patients received intravenous administration of 4.0 MBq/kg (Biograph mCT-64) and 7.0 MBq/kg (Discovery STE-16) ¹⁸F-FDG according to the PET/CT system. Patients were encouraged to rest during the ¹⁸F-FDG uptake period. Images were acquired 60 minutes after the ¹⁸F-FDG injection. A

noncontrast CT scan was obtained for attenuation correction and localization. Immediately after the CT scan, PET images were acquired from the base of the skull or top of the brain to the proximal thigh. The PET images were reconstructed iteratively using ordered subset expectation maximization. Attenuation correction of PET images was performed using attenuation data from CT. All fusion images were viewed using dedicated workstations for each PET/CT system.

All ¹⁸F-FDG PET/CT images were interpreted by a board-certified nuclear medicine physician with appropriate training and experience. Discernable foci of increased ¹⁸F-FDG colon uptake that exceeded that of the normal hepatic parenchyma were regarded as positive findings. When ¹⁸F-FDG uptake in the colon was segmental or diffuse pattern without focal ¹⁸F-FDG uptake, it was regarded as physiologic bowel uptake. ¹⁸F-FDG uptake intensity was measured as the maximum standardized uptake value (SUV_{max}) using the software provided at the workstations for each scanner. Colonoscopy was used as gold standard to confirm the results of ¹⁸F-FDG PET/CT. The final diagnosis of focal colon ¹⁸F-FDG uptake was made based on the histopathologic results from the colonoscopic biopsy. The ¹⁸F-FDG PET/CT result was considered as true positive when focal ¹⁸F-FDG uptake matched CRC or adenoma with HGD in the same location on colonoscopy.

2.4. Statistical analysis

Numerical data (age and blood glucose level) are expressed as mean \pm standard deviation and were compared using Student *t* test. The clinicopathological features including sex, gastric cancer stage, histopathological type, or primary gastric cancer location were compared using the 2-tailed chi-square and Fisher exact tests. The clinicopathological features were analyzed by univariate logistic regression in order to identify risk factors for synchronous CRN. *P* < 0.05 was considered statistically significant.

3. Results

3.1. Patient characteristics

A total of 256 patients (165 men and 91 women; mean age, 62.8 \pm 12.0 years) were enrolled in this study (Fig. 1). Table 1

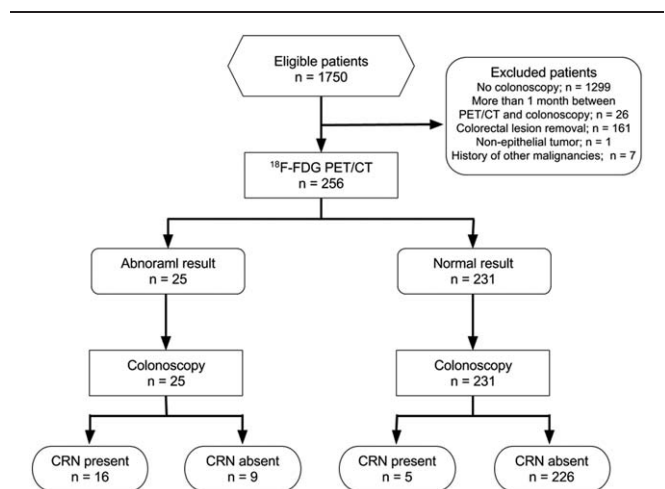


Figure 1. STARD flow diagram of study population. CRN=colorectal neoplasia, STARD=standards for reporting of diagnostic accuracy.

Table 1
Characteristics of the patients with gastric cancer.

| Characteristics | Numbers of patients |
|---|---------------------------|
| Age, y | 62.8±12.0 (ranged 29–86) |
| Sex | |
| Male | 165 |
| Female | 91 |
| Blood glucose level, mg/dL | 98.6±16.2 (ranged 65–172) |
| Stage of gastric cancer* | |
| I | 136 |
| II | 38 |
| III | 51 |
| IV | 31 |
| Histopathology of gastric cancer | |
| Well/moderate differentiated adenocarcinoma | 114 |
| Poorly differentiated adenocarcinoma | 88 |
| Poorly cohesive carcinoma | 54 |
| Location of gastric cancer | |
| Upper third | 41 |
| Middle third | 89 |
| Lower third | 126 |
| Histopathology of colorectal lesion | |
| Colorectal carcinoma | 12 |
| Adenoma with HGD | 9 |
| Adenoma with LGD | 73 |
| Hyperplastic polyp | 31 |
| Inflammatory lesion | 12 |
| Location of advanced CRN | |
| Ascending colon | 5 |
| Transverse colon | 3 |
| Descending colon | 2 |
| Sigmoid colon | 8 |
| Rectum | 3 |

CRN = colorectal neoplasia, HGD = high-grade dysplasia, LGD = low-grade dysplasia.

* American Joint Committee on Cancer (AJCC) seventh edition.

summarizes the patient characteristics. Advanced CRN was detected in 21 (8.2%) of the 256 patients. In 21 patients with advanced CRN, 12 patients (4.7%) had CRC and 9 patients (3.5%) had adenoma with HGD. Adenoma with LGD was detected in 73 (28.5%) of the 256 patients with gastric cancer. Thirty-one patients (12.1%) had hyperplastic polyps, and 12

patients (4.7%) had inflammatory lesions. The mean time interval between ^{18}F -FDG PET/CT and colonoscopy was 5.6±5.3 days (range, 0–22 days).

Mean size of advanced CRN was 3.4±3.6 cm (range; 0.5–13 cm). Patients with advanced CRN were significantly older than that of patients without advanced CRN (70.6±9.3 vs 62.2±12.0 years, $P=0.005$). The prevalence rates of advanced CRN tended to be higher in male patients than those in female patients (10.3% vs 3.3%, $P=0.052$). No differences in prevalence of advanced CRN were observed according to stage, histopathological type of gastric cancer, or primary gastric cancer location, respectively ($P=0.433$, 0.382, and 0.939). Logistic regression analysis showed that age and sex were associated with prevalence of advanced CRN in patients with gastric cancer (Table 2).

3.2. Diagnostic value of ^{18}F -FDG PET/CT

Table 3 summarizes the diagnostic value of ^{18}F -FDG PET/CT. Sensitivity, specificity, and accuracy of ^{18}F -FDG PET/CT were 83.3%, 93.9%, and 93.4% for detecting CRC and were 76.2%, 96.2%, and 94.5% for detecting advanced CRN (Fig. 2). Nine patients with focal colonic ^{18}F -FDG uptake had false positive ^{18}F -FDG PET/CT results for advanced CRN. Focal colonic ^{18}F -FDG uptake in 8 patients with false positive result was considered as physiologic bowel uptake and 1 patient with false positive result had an inflammatory lesion of the colon.

The size of advanced CRN with true positive results was significantly larger than that with false negative results ($P=0.006$). There were no significant differences in age, sex, and blood glucose level between patients with true positive and false negative results (Table 4). The SUV_{max} of true positive foci for advanced CRN higher than that of false positive foci on ^{18}F -FDG PET/CT, but it was not significant (12.9 ± 8.7 vs 7.8 ± 2.7 , $P=0.116$). The SUV_{max} were not significantly different between CRC and adenoma with HGD (12.0 ± 5.0 vs 14.7 ± 14.3 , $P=0.700$).

4. Discussion

Several studies have reported a high prevalence of synchronous CRN in patients with gastric cancer.^[6–8] Regarding the adenoma–adenocarcinoma sequence in the colorectum, a

Table 2
Logistic regression analysis of risk factors for synchronous advanced CRN in patients with gastric cancer.

| Variable | B (SE) | P | OR* (95% CI)† |
|----------------------------------|--------------|-------|-------------------|
| Age | 0.07 (0.03) | 0.007 | 1.08 (1.02–1.14) |
| Sex (male) | 1.50 (0.67) | 0.025 | 4.50 (1.21–16.77) |
| Stage of gastric cancer | | | |
| I | | 0.136 | 1 |
| II | 1.59 (1.08) | 0.141 | 4.89 (0.59–40.40) |
| III | −0.01 (1.46) | 0.995 | 0.99 (0.06–17.45) |
| IV | 0.40 (1.28) | 0.754 | 1.49 (0.12–18.23) |
| Histopathology of gastric cancer | | | |
| Well/moderate differentiated | | 0.789 | 1 |
| Poorly differentiated | −0.02 (0.63) | 0.980 | 0.99 (0.29–3.36) |
| Poorly cohesive | −0.40 (0.71) | 0.574 | 0.67 (0.17–2.68) |
| Location of gastric cancer | | | |
| Upper third | | 0.844 | 1 |
| Middle third | −0.32 (0.72) | 0.654 | 0.73 (0.18–2.96) |
| Lower third | −0.27 (0.56) | 0.631 | 0.76 (0.26–2.29) |

SE = standard error.

* OR = odds ratio.

† CI = confidence interval.

Table 3**Diagnostic value of ^{18}F -FDG PET/CT for detecting advanced CRN and colorectal carcinoma.**

| | Sensitivity | Specificity | Accuracy | PPV* | NPV† |
|----------------------|---------------|-----------------|-----------------|---------------|-----------------|
| Colorectal carcinoma | 83.3% (10/12) | 93.9% (229/244) | 93.4% (239/256) | 40.0% (10/25) | 99.1% (229/231) |
| Advanced CRN‡ | 76.2% (16/21) | 96.2% (226/235) | 94.5% (242/256) | 64.0% (16/25) | 97.8% (226/231) |

* PPV = positive predictive value.

† NPV = negative predictive value.

‡ CRN = colorectal neoplasia.

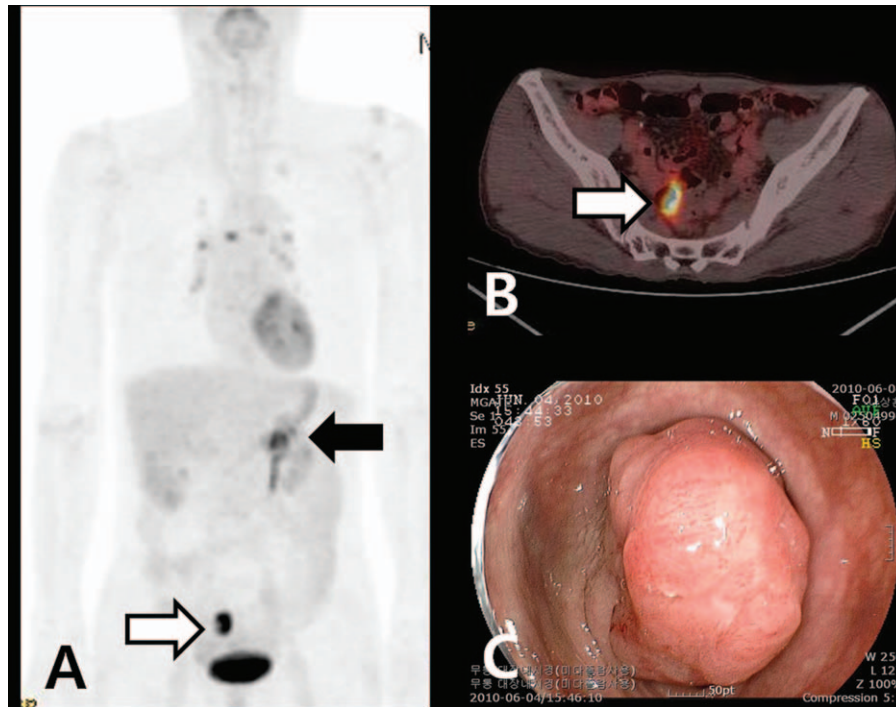


Figure 2. A 68-year-old man with gastric cancer. Preoperative maximum-intensity-projection (A) and transaxial (B) ^{18}F -FDG PET/CT images show 2 foci of increased ^{18}F -FDG uptake in the gastric body (arrow) and sigmoid colon (open arrow). Colonoscopy (C) reveals a 3.2-cm-sized polypoid mass in the sigmoid colon, which was histopathologically diagnosed as colorectal carcinoma.

synchronous CRN should be screened and eliminated in the preoperative workup in selected high-risk patients. Although several studies have reported that incidental colonic foci of ^{18}F -FDG uptake are related with CRN,^[12,15,16] the diagnostic value of ^{18}F -FDG PET/CT for detecting synchronous CRN has not been reported in patients with gastric cancer. We revealed that ^{18}F -FDG PET/CT had high diagnostic value for detecting synchronous advanced CRN in patients with gastric cancer. Sensitivity, specificity, and accuracy of ^{18}F -FDG PET/CT were 76.2%, 96.2%, and 94.5% for detecting advanced CRN.

Table 4

Comparison of characteristics between patients with true positive and false negative ^{18}F -FDG PET/CT results for detecting advanced CRN.

| | True positive (%) | False negative (%) | P |
|----------------------------|-------------------|--------------------|-------|
| Age, y | 71.5±8.5 | 67.0±11.2 | 0.357 |
| Sex (male/female) | 13/3 | 4/1 | 0.134 |
| Blood glucose level, mg/dL | 99.5±14.7 | 92.8±11.1 | 0.369 |
| Tumor size, cm | 4.2±3.8 | 1.0±4.6 | 0.006 |

^{18}F -FDG PET/CT has high sensitivity (94%–100%) for detecting primary tumors of the colon.^[11,20–22] Kantorova et al^[11] reported that ^{18}F -FDG PET/CT detected 35 of 37 (94.6%) CRC lesions, and this was the highest sensitivity compared with that of other modalities, including conventional CT and ultrasonography. The sensitivity of ^{18}F -FDG PET/CT to detect colonic adenoma is correlated with size and grade of dysplasia.^[12,23,24] Previous reports have shown that the rate of visualizing colorectal polyps on PET/CT image increases with polyp size, and histological grade of colonic adenoma was the most important independent factor affecting detectability by ^{18}F -FDG PET/CT.^[12,24] Nonpre-malignant lesions, such as hyperplastic polyps, do not tend to accumulate ^{18}F -FDG.^[22] In this study, ^{18}F -FDG PET/CT missed relatively small CRN lesions in 5 of 21 patients with advanced CRN. The sizes of true positive CRN were significantly larger than that of false negative CRN. Possible reason for a false negative ^{18}F -FDG PET/CT result could be a limitation in the current subcentimeter spatial resolution of PET scanners relative to the small size of the CRN and the partial volume effects, as nonlinear partial volume effects lead to underestimates of radioactivity concentration.^[26,27] Also,

physiological ^{18}F -FDG uptake in the colon could obscure pathological ^{18}F -FDG uptake of advanced CRN.^[28]

Varying physiological ^{18}F -FDG uptake and localization patterns in the colon have been described previously.^[16,25] The physiological accumulation of ^{18}F -FDG in the colon could create a false positive ^{18}F -FDG PET/CT result.^[28] The physiologic ^{18}F -FDG uptake in the colon has been attributed to uptake by smooth muscles, swallowed secretions, or excretion and intraluminal concentrations of ^{18}F -FDG.^[29] The intensity of ^{18}F -FDG uptake in terms of SUV_{max} does not discriminate between malignant, premalignant, and benign lesions as does physiologic uptake.^[16] In the present study, 9 patients (3.5%) had false positive results for advanced CRN, and no significant difference in SUV_{max} was noted between the true positive and false positive foci. Despite possible false positive results, focal colonic ^{18}F -FDG uptake has a high probability (70%–80%) of showing corresponding abnormal histopathological findings.^[15,16,25] Treglia et al^[25] reported that incidental colonic uptake of ^{18}F -FDG was detected in 64 of 6000 patients (1.1%) who underwent an ^{18}F -FDG PET/CT scan for diagnosis, staging, and restaging of different types of cancer, and that 65% of those patients had advanced CRN. In accordance with previous studies, we revealed a positive predictive value of 64% for advanced CRN. Colonoscopy is recommended as the next diagnostic step for further evaluation of an ^{18}F -FDG PET/CT positive result.

Several studies have reported that patients with gastric cancer have an increased risk of synchronous and metachronous CRC.^[6–8] A meta-analysis of 24 case-control studies revealed that patients with gastric neoplasms have higher risk (odds ratio, 1.72; 95% confidence interval, 1.42–2.09) of CRN compared with their controls.^[30] The prevalence of CRC in asymptomatic adult in the United States is 0.6% to 1.6%, and the prevalence of advanced CRN is 2.5% to 3.1%.^[18,19] The prevalence of CRC in asymptomatic adults in Korea is 0.2%, and the prevalence of advanced CRN is 3.7%.^[31] Previous studies with gastric cancer patients revealed that the prevalence of synchronous CRC is 2.0% to 4.8% and the prevalence of advanced CRN is 3.0% to 6.0%.^[8,30,32,33] In agreement with these studies, we demonstrated relatively high prevalence rates of CRC and advanced CRN of 4.7% and 8.2%, respectively, in patients with gastric cancer. It has been reported that older age and male sex are associated with an increased risk of CRC.^[6,8,19,31] Present study also revealed that risk factors for synchronous advanced CRN were older age and male sex in patients with gastric cancer.

The present study had some limitations. Patients with diabetes taking metformin were included in the present study. Metformin is an antihyperglycemic drug that is widely used to treat patients with type 2 diabetes mellitus, but can significantly increase ^{18}F -FDG uptake in the colon for at least 2 days and can affect visualization of CRC on the ^{18}F -FDG PET/CT image.^[34,35] In the present study, although 2 patients with false negative ^{18}F -FDG PET/CT results for CRC did not have diabetic mellitus, colonic ^{18}F -FDG uptake by metformin could affect visualization of colonic adenoma with HGD on ^{18}F -FDG PET/CT. Discontinuing metformin for a few days would reduce physiological ^{18}F -FDG uptake in the gastrointestinal tract and improve the performance of ^{18}F -FDG PET/CT for detecting advanced CRN in patients with diabetes.^[34] Another limitation is the use of different PET scanners for the investigations with different acquisition parameters. However, this may minimally affect on the accuracy of ^{18}F -FDG PET/CT in detecting advanced CRN.

In conclusion, ^{18}F -FDG PET/CT demonstrated high diagnostic accuracy for detecting synchronous advanced CRN in patients

with gastric cancer. Colonoscopy is recommended as the next diagnostic step for a further evaluation of focal ^{18}F -FDG colonic uptake in patients with gastric cancer.

References

- Ferlay J, Soerjomataram I, Dikshit R, et al. Cancer incidence and mortality worldwide: sources, methods and major patterns in GLOBOCAN 2012. *Int J Cancer* 2015;136:E359–86.
- Ikeda Y, Saku M, Kawanaka H, et al. Features of second primary cancer in patients with gastric cancer. *Oncology* 2003;65:113–7.
- Eom BW, Lee HJ, Yoo MW, et al. Synchronous and metachronous cancers in patients with gastric cancer. *J Surg Oncol* 2008;98:106–10.
- Bond JH. Polyp guideline: diagnosis, treatment, and surveillance for patients with colorectal polyps. *Am J Gastroenterol* 2000;95:3053–63.
- Lieberman DA, Rex DK, Winawer SJ, et al. Guidelines for colonoscopy surveillance after screening and polypectomy: a consensus update by the US Multi-Society Task Force on Colorectal Cancer. *Gastroenterology* 2012;143:844–57.
- Yoo HM, Gweon TG, Seo HS, et al. Role of preoperative colonoscopy in patients with gastric cancer: a case control study of the prevalence of coexisting colorectal neoplasms. *Ann Surg Oncol* 2013;20:1614–22.
- Saito S, Hosoya Y, Togashi K, et al. Prevalence of synchronous colorectal neoplasms detected by colonoscopy in patients with gastric cancer. *Surg Today* 2008;38:20–5.
- Kim HO, Hwang SI, Yoo CH, et al. Preoperative colonoscopy for patients with gastric adenocarcinoma. *J Gastroenterol Hepatol* 2009;24:1740–4.
- Kim EY, Lee WJ, Choi D, et al. The value of PET/CT for preoperative staging of advanced gastric cancer: comparison with contrast-enhanced CT. *Eur J Radiol* 2011;79:183–8.
- Yun M, Lim JS, Noh SH, et al. Lymph node staging of gastric cancer using ^{18}F -FDG PET: a comparison study with CT. *J Nucl Med* 2005;46:1582–8.
- Kantorova I, Lipska L, Belohlavek O, et al. Routine ^{18}F -FDG PET preoperative staging of colorectal cancer: comparison with conventional staging and its impact on treatment decision making. *J Nucl Med* 2003;44:1784–8.
- Yasuda S, Fujii H, Nakahara T, et al. ^{18}F -FDG PET detection of colonic adenomas. *J Nucl Med* 2001;42:989–92.
- Liu FY, Liao CT, Yen TC. Synchronous malignancies in patients with squamous cell carcinomas of the oral cavity. *Eur J Nucl Med Mol Imaging* 2011;38:1020–8.
- Agress HJr, Cooper BZ. Detection of clinically unexpected malignant and premalignant tumors with whole-body FDG PET: histopathologic comparison. *Radiology* 2004;230:417–22.
- Kamel EM, Thumshirn M, Truninger K, et al. Significance of incidental ^{18}F -FDG accumulations in the gastrointestinal tract in PET/CT: correlation with endoscopic and histopathologic results. *J Nucl Med* 2004;45:1804–10.
- Israel O, Yefremov N, Bar-Shalom R, et al. PET/CT detection of unexpected gastrointestinal foci of ^{18}F -FDG uptake: incidence, localization patterns, and clinical significance. *J Nucl Med* 2005;46:758–62.
- Bosman FT, Carneiro F, Hruban RH, et al. WHO Classification of Tumours of The Digestive System. 2010;Lyon, france:World Health Organization, 103–13.
- Lieberman DA, Weiss DG, Bond JH, et al. Use of colonoscopy to screen asymptomatic adults for colorectal cancer. *N Engl J Med* 2000;343:162–8.
- Imperiale TF, Wagner DR, Lin CY, et al. Risk of advanced proximal neoplasms in asymptomatic adults according to the distal colorectal findings. *N Engl J Med* 2000;343:169–74.
- Yamamoto Y, Kameyama R, Izuishi K, et al. Detection of colorectal cancer using ^{18}F -FLT PET: comparison with ^{18}F -FDG PET. *Nucl Med Commun* 2009;30:841–5.
- Mukai M, Sadahiro S, Yasuda S, et al. Preoperative evaluation by whole-body ^{18}F -fluorodeoxyglucose positron emission tomography in patients with primary colorectal cancer. *Oncol Rep* 2000;7:85–7.
- Abdel-Nabi H, Doerr RJ, Lamonica DM, et al. Staging of primary colorectal carcinomas with fluorine-18 fluorodeoxyglucose whole-body PET: correlation with histopathologic and CT findings. *Radiology* 1998;206:755–60.
- Nakajo M, Jinnouchi S, Tashiro Y, et al. Effect of clinicopathologic factors on visibility of colorectal polyps with FDG PET. *Am J Roentgenol* 2009;192:754–60.

- [24] van Kouwen MC, Nagengast FM, Jansen JB, et al. 2-(18F)-fluoro-2-deoxy-D-glucose positron emission tomography detects clinical relevant adenomas of the colon: a prospective study. *J Clin Oncol* 2005;23:3713–7.
- [25] Treglia G, Calcagni M, Rufini V, et al. Clinical significance of incidental focal colorectal 18F-fluorodeoxyglucose uptake: our experience and a review of the literature. *Colorectal Dis* 2012;14:174–80.
- [26] Gallivanone F, Canevari C, Gianolli L, et al. A partial volume effect correction tailored for 18F-FDG-PET oncological studies. *Biomed Res Int* 2013;2013:780458.
- [27] Cook GJ. Pitfalls in PET/CT interpretation. *Q J Nucl Med Mol Imaging* 2007;51:235–43.
- [28] Cook GJ, Fogelman I, Maisey MN. Normal physiological and benign pathological variants of 18-fluoro-2-deoxyglucose positron-emission tomography scanning: potential for error in interpretation. *Semin Nucl Med* 1996;26:308–14.
- [29] Kim S-k, Chung J-K, Kim BT, et al. Relationship between gastrointestinal F-18-fluorodeoxyglucose accumulation and gastrointestinal symptoms in whole-body PET. *Clin Positron Imaging* 1999;2:273–9.
- [30] Wu ZJ, Lin Y, Xiao J, et al. Clinical significance of colonoscopy in patients with upper gastrointestinal polyps and neoplasms: a meta-analysis. *PLoS One* 2014;9:e91810.
- [31] Chung SJ, Kim YS, Yang SY, et al. Prevalence and risk of colorectal adenoma in asymptomatic Koreans aged 40–49 years undergoing screening colonoscopy. *J Gastroenterol Hepatol* 2010;25:519–25.
- [32] Suzuki A, Koide N, Takeuchi D, et al. Prevalence of synchronous colorectal neoplasms in surgically treated gastric cancer patients and significance of screening colonoscopy. *Dig Endosc* 2014;26:396–402.
- [33] Ojima T, Iwahashi M, Nakamori M, et al. Is preoperative colonoscopy necessary for patients undergoing gastric cancer surgery? *Ann Surg Oncol* 2014;21(suppl 3):S379–84.
- [34] Oh JR, Song HC, Chong A, et al. Impact of medication discontinuation on increased intestinal FDG accumulation in diabetic patients treated with metformin. *Am J Roentgenol* 2010;195:1404–10.
- [35] Gontier E, Fourme E, Wartski M, et al. High and typical 18F-FDG bowel uptake in patients treated with metformin. *Eur J Nucl Med Mol Imaging* 2008;35:95–9.