

# Overtube-assisted enteroscopy and capsule endoscopy for the diagnosis of small-bowel polyps and tumors: a systematic review and meta-analysis

## Authors

Marianny Sulbaran<sup>1</sup>, Eduardo de Moura<sup>1</sup>, Wanderley Bernardo<sup>1</sup>, Cintia Morais<sup>1</sup>, Joel Oliveira<sup>1</sup>, Leonardo Bustamante-Lopez<sup>2</sup>, Paulo Sakai<sup>1</sup>, Klaus Mönkemüller<sup>3</sup>, Adriana Safatle-Ribeiro<sup>1</sup>

## Institutions

Institutions are listed at the end of article.

submitted 14. July 2015  
accepted after revision  
19. October 2015

## Bibliography

DOI <http://dx.doi.org/10.1055/s-0041-108261>  
Published online: 11.1.2016  
Endoscopy International Open 2016; 04: E151–E163  
© Georg Thieme Verlag KG  
Stuttgart · New York  
E-ISSN 2196-9736

## Corresponding author

**Marianny Sulbaran, MD**  
Rua Jose Antonio Coelho 207,  
Apartment 13  
04011060 Sao Paulo  
Brazil  
Phone: (5511) 948526841  
Fax: +55-11-31494790  
[mariannysulbaran@gmail.com](mailto:mariannysulbaran@gmail.com)

**Background and study aims:** Several studies have evaluated the utility of double-balloon enteroscopy (DBE) and capsule endoscopy (CE) for patients with small-bowel disease showing inconsistent results. The aim of this study was to determine the sensitivity and specificity of overtube-assisted enteroscopy (OAE) as well as the diagnostic concordance between OAE and CE for small-bowel polyps and tumors.

**Patients and methods:** We conducted a systematic review and meta-analysis of studies in which the results of OAE were compared with the results of CE for the evaluation of small-bowel polyps and tumors. When data for surgically resected lesions were available, the histopathological results of OAE and surgical specimens were compared. The sensitivity, specificity, positive likelihood ratio, and negative likelihood ratio for the diagnosis of small-bowel polyps and tumors were analyzed. Secondly, the rates of diagnostic concordance and discordance between OAE and CE were calculated.

**Results:** There were 15 full-length studies with a total of 821 patients that met the inclusion crite-

ria. The pooled sensitivity, specificity, positive likelihood ratio, and negative likelihood ratio were as follows: 0.89 (95% confidence interval [CI] 0.84–0.93), with heterogeneity  $\chi^2=41.23$  ( $P=0.0002$ ) and inconsistency ( $I^2$ )=66.0%; 0.97 (95%CI 0.95–0.98), with heterogeneity  $\chi^2=45.27$  ( $P=0.07$ ) and inconsistency ( $I^2$ )=69.1%; 16.61 (95%CI 3.74–73.82), with heterogeneity Cochrane's  $Q=225.19$  ( $P<0.01$ ) and inconsistency ( $I^2$ )=93.8%; and 0.14 (95%CI 0.05–0.35), with heterogeneity Cochrane's  $Q=81.01$  ( $P<.01$ ) and inconsistency ( $I^2$ )=82.7%, respectively. A summary receiver operating characteristic curve (SROC) curve was constructed, and the area under the curve (AUC) was 0.97.

**Conclusion:** OAE is an accurate test for the detection of small-bowel polyps and tumors. OAE and CE have a high diagnostic concordance rate for small-bowel polyps and tumors.

This study was registered in the PROSPERO international database ([www.crd.york.ac.uk/prospero/](http://www.crd.york.ac.uk/prospero/)) with the study number CRD42015016000.

## Introduction

About 5% of gastrointestinal neoplasms and 1% to 2% of gastrointestinal malignant tumors initially develop in the small bowel [1,2]. Small-bowel tumors have been difficult to diagnose as a consequence of their nonspecific presentation and the poor accessibility of the distal small bowel. Furthermore, many of these tumors can remain clinically silent for years [3].

Since the introduction of capsule endoscopy (CE) and overtube-assisted enteroscopy (OAE), the number of small-bowel polyps and tumors that are diagnosed has increased [4–6]. Obscure gastrointestinal bleeding (OGIB) is the main indication for using these enteroscopic modalities [6–10]. Importantly, the development of both dou-

ble-balloon enteroscopy (DBE) [11,12] and single-balloon enteroscopy (SBE) [13,14] has made it possible to perform diagnostic and therapeutic procedures during a single examination. More recently, spiral enteroscopy (SE) has been introduced as an alternative to balloon-assisted enteroscopy for deep intubation of the small intestine [15].

Several studies have evaluated the utility of DBE and CE in the evaluation of patients with suspected small-intestinal disease, including OGIB. However, the studies have shown inconsistent results and are largely limited by their small sample size [16]. Furthermore, these meta-analyses did not focus on small-bowel polyps and tumors. To the best of our knowledge, no systematic review has

## License terms



yet been conducted to evaluate OAE and CE for the diagnosis of small-bowel polyps and tumors.

The aim of this study was to determine the sensitivity and specificity of OAE, as well as the concordance rate between OAE and CE for the diagnosis of small-bowel polyps and tumors in patients presenting mainly with OGIB.

## Methods

This study was structured according to the PRISMA (Preferred Reporting Items for Systematic reviews and Meta-Analyses) recommendations [17]. It was registered in the PROSPERO international database ([www.crd.york.ac.uk/prospero/](http://www.crd.york.ac.uk/prospero/)) [18] with the study number CRD42015016000.

### Eligibility criteria

**Types of studies:** We included comparative studies in which OAE (including DBE, SBE, and SE) and CE were performed to diagnose small-bowel disease in patients with OGIB. Our search was applied to all databases through November 2014. Studies were excluded if they did not report specific information on the results of OAE and CE, included fewer than five patients, or were case reports, abstracts, or review articles. Studies that potentially shared enrolled patients were also excluded.

**Participants:** The patients in this meta-analysis had been given a diagnosis of OGIB, gastrointestinal polyposis, anemia, chronic abdominal pain, diarrhea, or suspected mass.

**Interventions:** We used studies that compared OAE, including DBE, SBE, and SE, with CE.

**Outcome measures:** True positives, true negatives, false positives, and false negatives were carefully extracted from the included studies. The primary outcome measures were sensitivity, specificity, positive likelihood ratio (PLR), and negative likelihood ratio (NLR) of OAE and the rates of concordance and discordance between OAE and CE for the diagnosis of small-bowel polyps and tumors.

### Information sources

Three investigators (M.S., W.B., and K.M) independently performed a search of the medical literature up to November 2014. The following electronic databases were searched: MEDLINE (via PubMed), Embase (Excerpta Medica database), LILACS (Latin American and Caribbean Health Science Literature), and Cochrane (via BVS [Biblioteca Virtual en Salud]). A manual search was also conducted of additional sources of information, such as bibliographies of identified articles, abstracts, and congress books. Potentially relevant articles were retrieved, and their reference lists were reviewed to identify studies that the search strategy might have missed. Papers were restricted to “full text.”

### Search

The following search terms were used for MEDLINE: (Capsule Endoscopy OR Enteroscopy OR Double-Balloon Enteroscopy OR Double Balloon Enteroscopy OR Double-Balloon Enteroscopies OR Enteroscopies, Double-Balloon OR Enteroscopy, Double-Balloon OR Push-and-Pull Enteroscopy OR Enteroscopies, Push-and-Pull OR Enteroscopy, Push-and-Pull OR Push and Pull Enteroscopy OR Push-and-Pull Enteroscopies OR Single-Balloon Enteroscopy OR Spiral Enteroscopy) AND (small intestines OR small intestine OR small bowel OR duodenum OR intestines, small OR jejunum OR ileum) AND (angioectasia OR angiectasia

OR angiodysplasias OR arteriovenous malformation OR malformation, arteriovenous OR malformations, arteriovenous OR Dieulafoy OR ectasia, vascular OR bleeding OR gastrointestinal bleeding OR polyps OR polyposis OR tumors).

A similar strategy was used for the LILACS, Embase, and Cochrane databases:

(Capsule OR Enteroscopy) AND (small intestine) AND (gastrointestinal bleeding OR polyps OR tumors).

### Studies selection

Three investigators (M.S., W.B., and K.M) independently reviewed abstracts identified in the initial search to determine whether they were eligible for inclusion in a full-article review. The full papers were reviewed if there was disagreement about their inclusion. The study selection process was summarized through an adapted PRISMA flow diagram.

### Data collection process

We extracted data from the included studies with a diagnostic studies checklist. The relevant data were then extracted from each study with a standardized extraction form. One review author extracted the data, and a second author checked the extracted data. Disagreements were resolved by discussion among the three review authors.

### Data items

We extracted the following information from the trials:

- ▶ The study design, number of patients who underwent OAE and CE, ages of the patients, years of patient enrollment, and main indications for interventions.
- ▶ The type of intervention, as different OAE modalities were considered (DBE, SBE, SE) as well as different models of CE. Regarding OAE, the insertion route, mean procedure time, mean depth of insertion, rate of complete examinations, and rate of complications were described. CE mean recording duration, rate of complete examinations, and rate of complications were described as well.
- ▶ The type of outcome measures, including true positives, true negatives, false positives, and false negatives. Based on these data, the primary outcome measures that underwent meta-analysis were sensitivity and specificity of OAE. The rates of diagnostic concordance and discordance between OAE and CE were described as a systematic review only. When data for surgically resected specimens were available, OAE biopsy results were compared with the final surgical histopathological diagnosis.

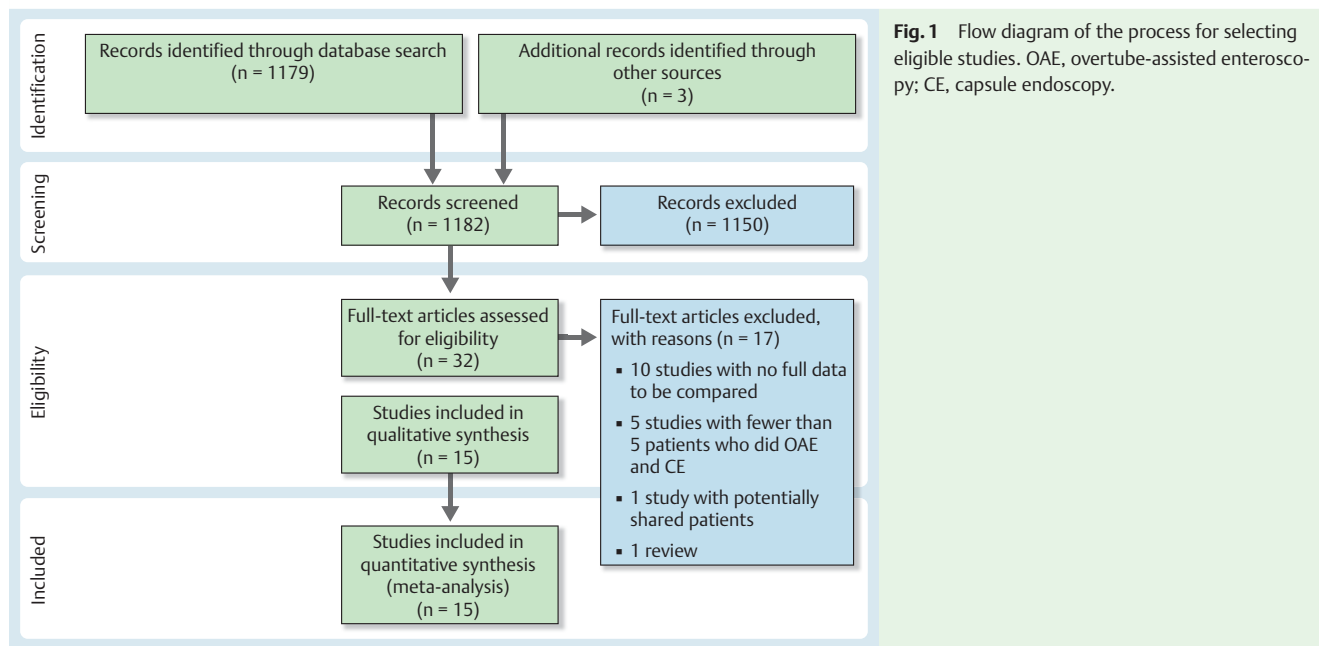
The sensitivity and specificity of OAE were calculated by establishing CE as the reference test for the diagnosis of small-bowel pathology. This was because of its ability to visualize the entire small bowel in a higher proportion of patients compared with OAE [19–21].

### Risk for bias in individual studies

Two reviewers worked independently with adequate reliability to measure the risk for bias and validate study eligibility. The data were assessed with QUADAS-2 (Quality Assessment of Diagnostic Accuracy Studies [22]) to evaluate the risk for bias and applicability in the study.

### Summary measures

The primary outcome measures were sensitivity, specificity, PLR, and NLR, as well as the pretest probability of OAE for the diagno-



sis of small-bowel polyps and tumors. The rates of concordance and discordance between OAE and CE for the diagnosis of small-bowel polyps and tumors were also assessed.

### Planned methods of analysis

Based on a comparison of OAE and CE results, 2×2 statistical tables were constructed for each study. Where 0 counts occurred in at least 1 cell of study data, a continuity correction of 0.5 was added to every value for that study to make the calculation of sensitivity and specificity. Based on these data, the sensitivity, specificity, PLR, and NLR (with corresponding 95% confidence intervals [CIs]) of enteroscopy were calculated. Pooled results with corresponding 95% CIs were derived by using the random effects model. A summary receiver operating characteristic curve (SROC) was constructed based on the Moses-Shapiro-Littenberg method [23]. The area under the curve (AUC) was computed as a measure of the overall performance of enteroscopy to accurately differentiate patients with small-bowel polyps and tumors from those without. A preferred test has an AUC close to 1, and a poor test has an AUC close to 0.5. Cochrane's Q2 test was used to assess heterogeneity, and the  $I^2$  statistic was used to measure inconsistency. A value of  $I^2$  below 30% was not considered to be statistically significant.  $I^2$  values of 30% to 60% were considered to represent moderate heterogeneity, between 50% and 90% substantial heterogeneity, and between 75% and 100% considerable heterogeneity [24]. The analysis was performed with Meta-DiSc version 1.4 statistical software (Unit of Clinical Biostatistics team of the Ramon y Cajal Hospital, Madrid, Spain). The Critically Appraised Topic (CAT) software was also used to calculate pretest probabilities.

### Risk for bias within studies

To evaluate the risk for bias within the studies, QUADAS-2 was applied to each of the studies. According to QUADAS-2, bias was classified as related to patient selection and/or OAE and/or CE and/or flow and timing. Studies of high quality were defined as those with low risk answers to at least three of four key items. Studies of poor quality were those that failed or had an unclear

answer to three of the four items. Moderate quality was assigned for every other possibility.

### Additional analysis

The rates of concordance and discordance per patient between OAE and CE for the diagnosis of small-bowel polyps and tumors were assessed.

### Results

The initial search yielded 1182 citations, and 1150 articles were excluded after preliminary abstract review. There were 32 full-length articles reviewed for eligibility. Detailed reasons for exclusion are outlined in **Appendix A**. A total of 15 full-length studies met the inclusion criteria (● **Fig. 1**).

### Study characteristics

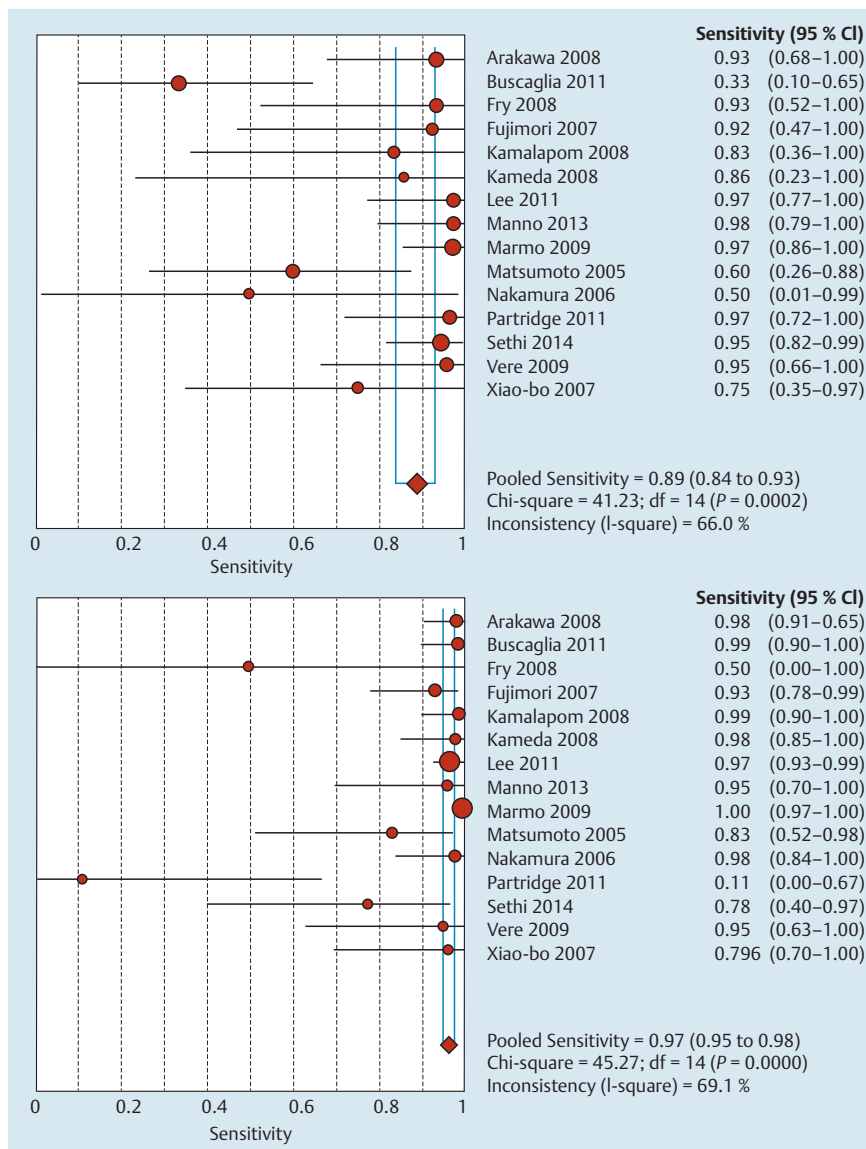
A total of 821 patients underwent both OAE and CE for a variety of indications, including OGIB, gastrointestinal polyposis, anemia, chronic abdominal pain, diarrhea, and suspected mass. The main characteristics of the included studies are detailed in ● **Table 1**. Enrolled studies were published between 2005 and 2014. Eight studies were prospectively designed, and seven were retrospective. Five studies were from Japan [19, 20, 25–27] three from the United States [28–30], two from Italy [21, 31], and one from each of the following countries: Germany [32], Romania [33], Korea [34], Canada [35], and China [36]. Four studies were conducted at multiple centers: two from Italy, one from Korea, and one from the United States. DBE was the OAE approach used in 11 studies, whereas SBE was used in three studies and SE in two studies. The M2A PillCam (Given Imaging, Yoqneam, Israel) was used in nine studies. The capsule model used in six of the studies was not specified. Data on the sequence of examinations, time between tests, OAE mean procedure time, CE recording duration, OAE depth of insertion, and percentages of OAE and CE complete examinations and complications were extracted.

**Table 1** Characteristics of studies included in a systematic review and meta-analysis of overtube-assisted enteroscopy and capsule endoscopy for the diagnosis of small-bowel polyps and tumors.

Study	Population and study design	Indication	OAE approach and route of insertion, % (n/N)	CE model	CE Examination sequence	Time between tests	OAE mean procedure time, min	CE recording duration, min	OAE mean depth of insertion, cm	OAE complete examinations, % (n/N)	CE complete examinations, % (n/N)	OAE complications	CE complications
Arakawa 2009	Retrospective, 74 pts, Nagoya University Hospital, Japan, 2003–2007	OGIB	DBE: N/A*	M2A PillCam	74 pts, DBE preceded by CE	Median 2 d (range 0–45)	N/A	N/A	N/A	70 (23/33)	68 (50/74)	1 perforation, 1 acute pancreatitis	Capsule retention in 4 pts: 2 in small bowel, 1 over jejunal lymphoma, 1 in ileal loop
Buscaglia 2011	Prospective, 56 pts, mean age 68 y, Stony Brook University, State University of New York, and Shands Hospital, University of Florida, USA, 2008–2009	OGIB, abnormal imaging, abnormal CE findings, suspected Crohn's disease	SE, antegrade, 56	N/A	56 pts, SE preceded by CE	87 d	42.1 ± 12.3	N/A	224.6 ± 68.7	N/A	N/A	No major complications; 6 minor lacerations of gastrointestinal mucosa, no interventions required	N/A
Fry 2009	Retrospective, 7 pts, mean age 51 y, University of Magdeburg Medical Center, Germany, 3.75-y period	OGIB, anemia, chronic diarrhea	DBE: N/A <sup>1</sup>	N/A	7 pts, DBE preceded by CE	N/A	75 (range 25–115)	N/A	300 (range 30–540)	N/A	N/A	1 transient oxygen desaturation, 1 post-procedural abdominal pain and bloating	Capsule retention in 2 pts, 1 extracted by DBE
Fujimori 2007	Prospective, 36 pts, mean age 60.2 ± 15.0 y, Nippon Medical School Hospital, Japan, 2004–2006	OGIB	DBE	PillCam TM	36 pts, DBE preceded by CE	72 h	N/A	N/A	N/A	N/A	N/A	Not reported	Not reported
Kamala-porn 2008	Retrospective, 51 pts, mean age 64.1 y (34–83), St. Michael's Hospital, University of Toronto, Canada, 2002–2007	OGIB	DBE, antegrade, 30; retrograde, 17; oral and anal, 12	M2A PillCam	51 pts, DBE preceded by CE	Mean 139 d (range 40–335)	Mean 179.8 (range 40–335)	Small intestine, 243.7 (0–465)	N/A	N/A	N/A	No significant complications	No capsule retention

Table 1 (Continuation)

Study	Population and study design	Indication	OAE approach and route of insertion, % (n/N)	CE model	Examination sequence	Time between tests	OAE mean procedure time, min	CE recording duration, min	OAE mean depth of insertion, cm	OAE complete examinations, % (n/N)	CE complete examinations, % (n/N)	OAE complications	CE complications
Kameda 2008	Prospective, 32 pts, mean age 62.4 ± 14.8 y, male 13; female 19, Osaka City University Graduate School of Medicine, Japan, 2005 – 2006	OGIB	DBE: both antegrade and retrograde in attempt at total enteroscopy, 32	M2A PillCam	32 pts, DBE preceded by CE	1 – 7 d	N/A	Small intestine, 245.3	N/A	50.0 (16/32)	73.3 (23/30)	Minor complications only, abdominal pain, nausea	Capsule retention (small bowel) in 2 pts, removed by DBE
Lee 2011	Retrospective, 183 pts, mean age 48.2 y (7 – 87), multicenter (8 Korean university hospitals), 2004 – 2009.	OGIB, chronic abdominal pain/diarrhea, Peutz-Jeghers syndrome	DBE	CE	183 pts, DBE preceded by CE	N/A	N/A	N/A	N/A	43.90%	N/A	N/A*	N/A
Manno 2013	Prospective, 75 pts, mean age 61 y (20 – 89), male 55.9%, multicenter (5 Italian tertiary care public hospitals or university-affiliated teaching hospitals), 2010 – 2011	OGIB, suspected tumor, Crohn's disease	SBE	CE	75 pts, DBE preceded by CE	Within 4 wk	Antegrade, 61 ± 33; retrograde, 78 ± 41	N/A	Mean 254 ± 179; antegrade, 223 ± 93 beyond Treitz; retrograde, 96 ± 56 beyond ileocecal valve	47.06 (8/17)	N/A	1 transient oxygen desaturation	N/A
Marmo 2009	Prospective, 193 pts, median age 61.6 ± 16.2 y, multicenter (6 Italian institutions, tertiary care public hospitals, or university-affiliated teaching hospitals), 2004 – 2007	OGIB	DBE; antegrade, 56.4 (109/193); retrograde, 16.6 (32/193); oral and anal, 27 (52/193)	PillCam SB	193 pts, DBE preceded by CE	2 wk in all cases	Antegrade, 88 ± 23; retrograde, 97 ± 36; oral and anal, N/A	Total, 470.21 ± 39.5; small bowel, 262.90 ± 90.80	Antegrade, 192.4 ± 89.7; retrograde, 103.5 ± 77; oral and anal, 321 ± 147.2	34.6 (18/52)	85.5 (165/193)	Minor complications only, 2 patients with transient oxygen desaturation	Capsule retention in 6 pts, 4 of them above neoplastic stricture



**Fig. 2** Forest plots of overtube-assisted enteroscopy pooled sensitivity and specificity for diagnosis of small bowel polyps and tumors. CI, confidence interval.

### Meta-analysis

Forest plots of the sensitivity and specificity of OAE for the diagnosis of small-bowel polyps and tumors are shown in [Fig. 2](#). Forest plots of the PLR and NLR of OAE for the diagnosis of small-bowel polyps and tumors are shown in [Fig. 3](#). Point estimates were plotted with 95% CIs for each cohort. The pooled sensitivity and specificity of OAE for the diagnosis of small-bowel polyps and tumors were 0.89 (95%CI 0.84–0.93), with heterogeneity  $\chi^2=41.23$  ( $P=0.0002$ ) and inconsistency ( $I^2$ )=66.0%, and 0.97 (95%CI 0.95–0.98), with heterogeneity  $\chi^2=45.27$  ( $P=0.07$ ) and inconsistency ( $I^2$ )=69.1%, respectively. The pooled PLR and NLR, random effects model, were 16.61 (95%CI 3.74–73.82), with heterogeneity Cochrane  $Q=225.19$  ( $P<0.01$ ) and inconsistency ( $I^2$ )=93.8%, and 0.14 (95%CI 0.05–0.35), with heterogeneity Cochrane  $Q=81.01$  ( $P<0.01$ ) and inconsistency ( $I^2$ )=82.7%, respectively. An SROC curve was drawn to further explore overall accuracy, and the AUC was 0.97 ([Fig. 4](#)).

### Additional analysis

Pretest probability was  $26.36 \pm 22.68$ . The rates of diagnostic concordance and discordance between OAE and CE for the identification of small-bowel polyps and tumors are presented in [Table 2](#).

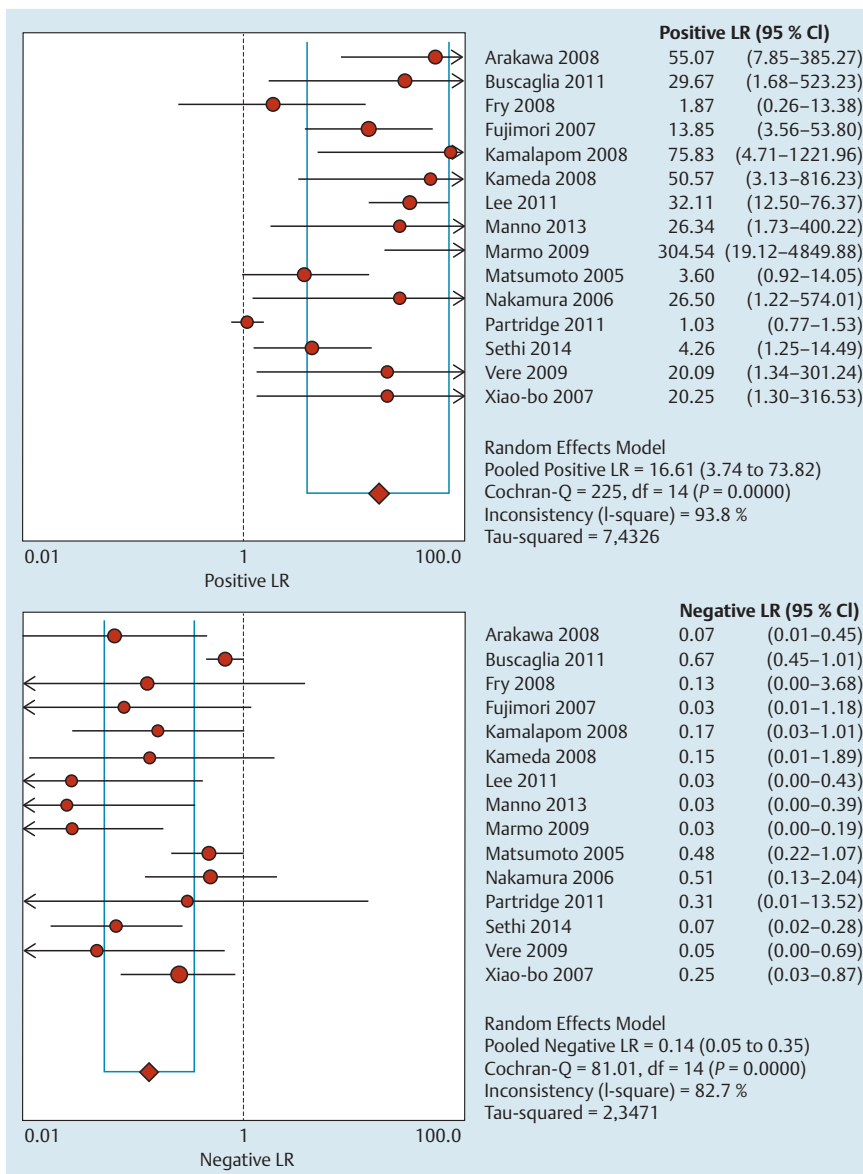
Data on histopathological analysis of OAE biopsy and/or surgical specimens and tumor location were extracted if available.

### Risk for bias within studies

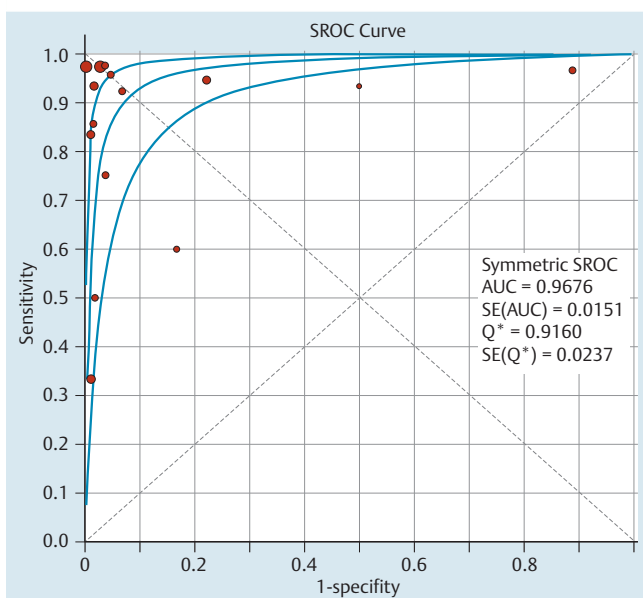
[Table 3](#) describes the risk for bias according to patient selection, OAE, and CE, as well as flow and time between the two enteroscopy sessions. Studies of high quality were defined as those with a low risk answer to at least three of the four key items. Studies of poor quality had an unclear or high risk answer to three of the four items. Moderate quality was assigned for every other possibility. Although there are some study limitations as a result of the introduction of bias within the selected studies, the overall quality of these papers was good. Nine studies were classified as good, five as moderate, and one as of poor quality according to a summary evaluation of items included in QUADAS-2.

### Discussion

Very few studies have compared the yield of and concordance between OAE and CE for the diagnosis of small-bowel polyps and tumors. Furthermore, the small number of cases included in the



**Fig. 3** Forest plots of OAE pooled positive and negative likelihood ratios for diagnosis of small bowel polyps and tumors. LR, likelihood ratio; CI, confidence interval.



**Fig. 4** Summary receiver operating characteristics (SROC) curve for the diagnosis of small-bowel polyps and tumors. AUC, area under the curve; Q\*, Q index; SE, standard error.

majority of studies has primarily limited previous analyses. In this study, 821 patients were included. Thus, it was possible to analyze and compare CE and OAE findings. We found that OAE is an accurate test for the detection of small-bowel polyps and tumors in patients presenting mainly with OGIB. OAE and CE have a high concordance rate for the diagnosis of small-bowel polyps and tumors.

Even though we did not aim to compare different enteroscopy approaches, the sensitivity and specificity of SBE were similar to pooled OAE sensitivity and specificity. The overall diagnostic yield for SBE was higher than in previously published studies [30]. The improved diagnostic yield may be related to the routine use of CE before SBE in these cases. Although there are no data on the specific increase in diagnostic yield in the diagnosis of small-bowel polyps and tumors for CE and SBE vs SBE alone, it is reasonable to propose that CE and OAE should be used in a combined approach for the diagnosis of small-bowel polyps and tumors.

Of note, the sensitivity of SE was lower than the overall OAE sensitivity. Some explanations for this observation were suggested. The first is that rotational advancement enteroscopy is simply not as effective as balloon-assisted enteroscopy for deep intes-

**Table 2** Concordance between overtube-assisted enteroscopy and capsule endoscopy for the diagnosis of small-bowel polyps and tumors.

Study	CE+, OAE+, n	CE+, OAE-, n	CE-, OAE+, n	CE-, OAE-, n	Concordance rate, %	Discordance rate, %	Histopathological diagnosis	Location of tumors, polyps
Arakawa 2009	14	1	1	58	97.29	2.71	<b>DBE/surgery</b> 70% (7/10) SBTs 100% (3/3) adenocarcinomas 100% (1/1) lymphoma 100% (1/1) metastasis 40% (2/5) GISTs <b>Observation, EMR</b> 3 inflammatory polyps 1 lipoma	<b>Location of tumors or polyps</b> 62% (16/26) in distal duodenum or jejunum 38% (10/26) in ileum <b>Location of GISTs</b> 83% (5/6) in jejunum 17% (1/6) in ileum Surgery confirmed 1 GIST in distal jejunum, observed at CE, inaccessible at DBE; 1 GIST in distal jejunum CE-, suspected at DBE; and 1 invaginated lipoma CE-, DBE+ in proximal jejunum.
Buscaglia 2011	4	8	0	44	85.71	14.28	N/A	N/A
Fry 2009	7	0	0	0	100	0	<b>DBE/surgery</b> 66.66% (4/6) SBTs 66.6% (2/3) adenocarcinomas 100% (2/2) B-cell lymphomas 0% (0/1) leiomyoma	1 jejunal adenocarcinoma 1 jejunal leiomyoma
Fujimori 2007	6	0	2	28	94.44	5.56	2 GISTs 1 carcinoma 1 lymphangioma 1 lipoma 1 inflammatory fibroid polyp <b>Observation</b> 2 GISTs CE-, DBE+	N/A
Kamalaporn 2008	5	1	0	45	98.04	1.96	<b>DBE/surgery</b> 100% (1/1) stromal tumor 100% (1/1) carcinoma	1 ileal stromal tumor 1 ileal carcinoma
Kameda 2008	3	0	0	29	100	0	N/A	1 duodenal cancer (surgical resection) 2 jejunal polyps (1 EMR)
Lee 2011	18	0	5	160	97.26	2.74	DBE histopathology consistent with final diagnosis in 72.9% of patients with SBTs <b>Observation</b> Concordance rate between CE and DBE for lymphomas and adenocarcinomas 100%, for GISTs/leiomyomas 70%	<b>SBTs overall</b> Jejunum 61.7% Ileum 34.9% Duodenum 16.1% <b>Adenocarcinomas</b> Jejunum 71.4% Duodenum 14.3% <b>Lymphomas</b> Jejunum 55.6% Ileum 50.1% <b>GISTs/leiomyomas</b> Jejunum 65.5% Ileum 24.1%
Manno 2013	20	0	0	13	100	0	<b>Observation</b> 15 tumors, 5 FAPs	N/A



**Table 2** (Continuation)

Study	CE+, OAE+, n	CE+, OAE-, n	CE-, OAE+, n	CE-, OAE-, n	Concordance rate, %	Discordance rate, %	Histopathological diagnosis	Location of tumors, polyps
Marmo 2009	36	1	0	156	99.48	0.52	<b>DBE or surgery</b> 6 stromal tumors 3 adenocarcinomas 2 carcinoids 1 lymphoma	N/A
Matsumoto 2005	6	4	2	10	72.72	27.28	<b>Observation</b> In 2 patients with polyposis, CE did not detect any polyps. In 2 of 3 patients with polyposis CE+ and DBE+, DBE detected a larger number of polyps than CE.	N/A
Nakamura 2006	1	1	0	26	96.42	3.58	<b>DBE/surgery</b> 1 SBT 100% (1/1) carcinoid <b>Observation</b> 1 SMT identified at CE, not detected with DBE	N/A
Partridge 2011	14	0	4	0	77.77	22.22	<b>OAE/surgery</b> 100% (16/16) SBTs 40% (8/20) NETs (2 multifocal) 25% (5/20) adenocarcinomas 20% (4/20) GISTs 10% (2/20) lymphomas 5% (1/20) poorly differentiated carcinomas	65% (13/20) jejunal tumors 35% (7/13) ileal NETs
Sethi 2014	35	2	2	7	91.30	8.70	<b>Observation</b> SBE identified 20 benign polyps, 9 lipomas, and 8 malignant tumors.	N/A
Vere 2009	11	0	0	10	100	0	<b>SBE or surgery</b> 11 SBTs 36.36% (4/11) GISTs 18.18% (2/11) adenocarcinomas 9.09% (1/11) neuroendocrine carcinomas 9.09% (1/11) duodenal papilla carcinomas 27.27% (3/11) tubular adenomas	N/A
Li 2007	6	2	0	13	90.47	9.53	N/A	N/A
<b>Total</b>	<b>186</b>	<b>20</b>	<b>16</b>	<b>599</b>				
<b>Percentage of total, %</b>	<b>22.66</b>	<b>2.44</b>	<b>1.95</b>	<b>72.96</b>	<b>93.39</b>	<b>6.61</b>		

CE, capsule endoscopy; OAE, overtube-assisted enteroscopy; DBE, double-balloon enteroscopy; EMR, endoscopic mucosal resection; GIST, gastrointestinal stromal tumor; N/A, not available; FAP, familial adenomatous polyposis; SMT, submucosal tumor; SBE, single-balloon enteroscopy; NET, neuroendocrine tumor.

	Selection of patients	OAE	CE	Time and flow	Study quality
Arakawa 2009	L	U	L	L	Good
Buscaglia 2011	L	H	L	H	Moderate
Fry 2009	H	H	L	L	Moderate
Fujimori 2007	L	H	L	L	Good
Kamalporn 2008	L	H	L	H	Moderate
Kameda 2008	L	L	L	U	Good
Lee 2011	H	H	L	U	Poor
Manno 2013	L	H	L	L	Good
Marmo 2009	L	L	L	L	Good
Matsumoto 2005	H	L	L	L	Good
Nakamura 2006	L	L	L	L	Good
Partridge 2011	L	H	L	U	Moderate
Sethi 2014	L	H	L	L	Good
Vere 2009	L	U	L	U	Moderate
Li 2007	L	H	L	L	Good

**Table 3** Risk for bias according to QUADAS-2 (Quality Assessment of Diagnostic Accuracy Studies).

OAE, overtube-assisted enteroscopy; CE, capsule endoscopy; L, low risk for bias; U, unclear risk for bias; H, high risk for bias.

tinal intubation. In addition, small polyps may be overlooked during enteroscopy and can also be overdiagnosed by CE [28]. Future perspectives on enteroscopy modalities should also be taken into consideration. The NaviAid AB (Advancing Balloon) device (SMART Medical Systems, Ra'anana, Israel) is a balloon-assisted enteroscopy device that uses a through-the-scope balloon to allow deep intubation of the small intestine with the use of a standard colonoscope. This system has a short learning curve and can be used without the assistance of another endoscopist [37]. More studies are required in order to evaluate its diagnostic yield compared with CE findings.

Neither CE nor OAE is an independent gold standard test for the diagnosis of small-bowel polyps and tumors. However, in our study, CE was defined as the reference test for sensitivity and specificity extraction data because it has provided a higher number of complete examinations of the small intestine compared with OAE. In this systematic review, the CE complete examination rates ranged from 68% to 90.9%, whereas the OAE complete examination rates ranged from 16.7% to 70%, in concordance with previous data [15,30,32,34]. Additionally, in a large European multicenter trial that included 5129 patients who underwent CE, confirmation of the diagnosis and location of the lesion was obtained in all cases by conventional endoscopic or surgical means. In that study, an agreement rate of 92.8% between CE and the final endoscopic or surgical diagnosis for single lesions was demonstrated [38].

Although there was a 93.39% concordance rate between OAE and CE, both tests can miss lesions. There were 20 cases detected by capsule and missed by OAE, and 16 cases missed by capsule and seen on OAE. Some possible explanations have been suggested because each method has its own strengths and limitations, and especially when small-bowel tumors and polyps are evaluated, these tests should be considered complementary.

Total enteroscopy cannot always be achieved by OAE [6,32]. A combination of antegrade and retrograde DBE approaches with the intention of total enteroscopy was successful in 85.7% of patients [6]. Furthermore, OAE is intrinsically an invasive method of enteroscopy, and not all patients with a negative evaluation on the first procedure are willing to undergo a second one via the complementary route. It is therefore likely that a complete examination of the small bowel still cannot be achieved with OAE in certain patients. Additionally, although a greater number of polyps were detected with DBE than with CE, in the area explored by DBE in patients with polyposis, the majority of the

polyps or tumors detected only by CE were located in the portion of the small bowel that was not evaluated by DBE [27]. These facts suggest that even for the surveillance of patients with polyposis syndromes, in whom the therapeutic impact of OAE is greater, CE and OAE show complementary benefits [32].

Taking into consideration studies that provided surgical specimen histopathological data [32,39,40], we demonstrated that in 80% of the DBE biopsies that missed the diagnosis, the lesions were of subepithelial origin. The misdiagnosed lesions included three gastrointestinal stromal tumors (GISTs), one leiomyoma, and one adenocarcinoma, demonstrating a low histological diagnostic yield for DBE in subepithelial tumors. This is in concordance with the findings of others [3], who also explained that the initially sampled tissue can be superficial to the targeted lesion. Additionally, 100% agreement regarding histological and laparoscopically resected specimens was shown for DBE [39], with the fact taken into consideration that in five cases of suspected GIST, biopsies were not obtained. Afterward, four GISTs and one gastrointestinal autonomic tumor (GANT) were further confirmed surgically. Chen et al. also analyzed the reasons for diagnoses missed by DBE in a large series of 440 patients who underwent DBE, in which the 11 patients with negative DBE results did indeed have tumors detected through surgery or CE. In this group of DBE false negatives, the reasons for the missed diagnoses were inadequate depth of insertion in 45% (5/11), suboptimal choice of insertion approach in 36% (4/11), and the presence of tumors that had exophytic growth with normal intestinal mucosa in 18% (2/11) [41].

CE has its own assets and drawbacks as well. Mass lesions are typically focal and thus more likely to be missed. False-positive data for submucosal tumors on CE may also be due to transient bulges into the lumen of the small bowel [39]. Although it has been stated that CE can miss mass lesions located in the proximal small bowel because of the high velocity of the capsule as it passes along the duodenal sweep and the currently limited angle of view [40,42,43], no clear association between tumor location and missed CE lesions was found in this review. Four CE-negative tumors were reported to be submucosal, three were GISTs, and one was an invaginated lipoma, findings concordant with those of a series of 150 consecutive CE examinations establishing that CE missed two small-bowel GISTs and one small-bowel mesenteric tumor diagnosed by surgery or previous contrast-enhanced computed tomography [42]. Five significant lesions missed by CE were found with other imaging modalities: DBE in three patients

and computed tomographic enterography and magnetic resonance enterography in the remaining two patients, and four of these lesions were located in the proximal jejunum [43]. The capsule system that was mostly frequently used in the included studies was the M2A PillCam, so the capsule model did not influence the variability of our results. Current capsule limitations, such as reduced angle of view, may be overcome in the near future with the recently developed 360-degree panoramic viewing capsule. More studies would be needed to demonstrate significant differences between the diagnostic yield of the panoramic capsule and that of currently widely available CE systems [44]. In contrast, at the present time, OAE may provide clearer and more comprehensive images, aided by air insufflation in the small-bowel lumen, the possibility of removing debris from the mucosa with water, and the ability to push and pull the enteroscope to re-inspect a suspicious small-bowel segment. Even though we did not aim to study the therapeutic yield of OAE, this approach offers therapeutic advantages that should be evaluated, especially for patients with polyposis syndromes. Whereas DBE was useful for the diagnosis of various types of polyps and tumors, its major endoscopic therapeutic impact was evident in patients with familial adenomatous polyposis syndrome or Peutz–Jeghers syndrome [32]. Another important issue is the higher overall prevalence of small-bowel polyps and tumors in the patients included in our study (26.36% ± 22.68) vs what has been previously reported by others (5%–17.4%) [1, 45]. This may be explained by the fact that the patients included in our study were at high risk for polyps or tumors because they had been selected to undergo OAE, with or without an abnormal CE study, or had concerning symptoms, mainly OGIB. We presented the pretest probability for the subgroup of patients who underwent both tests in each study, which does not necessarily represent the prevalence of the total number of patients who underwent OAE. Additionally, studies that included patients with benign lesions or polyposis were not excluded. This fact also could have influenced our overall higher reported prevalence. Nevertheless, our study does reflect the patients undergoing OAE and CE in clinical practice. Regarding complications, it is important to state that even though OAE is a more invasive technique than CE, 0.36% of the patients experienced significant complications (two cases of perforation and one of acute pancreatitis). Capsule retention occurred in 2% of the patients, and either OAE or surgical methods were used for retrieval. Our study has potential limitations. First, and important, is the limited number of comparison data with a gold standard method, such as intraoperative enteroscopy or surgery, found in most of the included studies. However, intraoperative enteroscopy is now rarely performed. Second, although histological confirmation is required for choosing the most adequate therapeutic option, histological confirmation by OAE may sometimes guide therapeutics other than surgery, such as chemotherapy. This is especially important in cases of malignant lymphoma or metastasis. Third, most studies had a relatively small sample size, and heterogeneity may also have limited the study. Furthermore, most studies used CE as an initial test, and its results served as a guide for the OAE route of insertion and localization of lesions. Indeed, OAE was frequently performed with an unblinded CE result, which introduced a higher risk for bias. However, this approach reflects the current standard of care, and it would not make sense to randomize patients to undergo OAE first when CE is a less invasive test.

In summary, our data show that OAE is an accurate test for the detection of small-bowel polyps and tumors in patients presenting mainly with OGIB. In addition, OAE and CE have a high concordance rate for the diagnosis of small-bowel polyps and tumors. Nevertheless, the two tests may have both false-negative and false-positive results. Thus, a combined approach is suggested. CE may be used initially to guide the OAE route of insertion and optimize its therapeutic applications.

## Appendix A



List of full-length reviewed articles excluded, with reasons for exclusion.

### Studies that could not compare full data between capsule endoscopy and overtube-assisted enteroscopy

1. Ross et al. *Dig Dis Sci* 2008 [46]
2. Choi et al. *Gastrointest Endosc* 2007 [47]
3. Schäfer et al. *Z Gastroenterol* 2007 [48]
4. Cangemi et al. *J Clin Gastroenterol* 2013 [3]
5. Pérez-Cuadrado et al. *Rev Esp Enferm Dig* 2006 [49]
6. Almeida et al. *Dig Dis Sci* 2009 [50]
7. Riccioni et al. *Surg Endosc* 2012 [39]
8. Frantz et al. *Gastrointest Endosc* 2010 [51]

### Case studies or papers that did not enroll at least five patients who underwent both capsule endoscopy and overtube-assisted enteroscopy

1. Zagorowicz et al. *World J Gastroenterol* 2013 [42]
2. Akamatsu et al. *Dig Endosc* 2010 [52]
3. Chong et al. *Gastrointest Endosc* 2006 [53]
4. Postgate et al. *Gastrointest Endosc* 2008 [43]
5. Rondonotti et al. *Endoscopy* 2008 [38]

### Studies from which data for polyps and tumors could not be extracted

1. Chen et al. *World J Gastroenterol* 2013 [41]
2. Albert et al. *Eur J Gastroenterol Hepatol* 2008 [45]

### Studies that potentially shared enrolled patients with other included studies

1. Honda et al. *Gastrointest Endosc* 2012 [40]  
The studies of Honda et al. [40] and Arakawa et al. [25] potentially shared included patients. If one takes into consideration that patients included in the study of Arakawa et al. had OGIB, and patients in the study of Honda et al. all had small-bowel tumors, we decided to exclude the study of Honda et al. because super-estimated values of sensitivity and specificity could be computed.

## Review

1. Alexander and Leighton. *Curr Opin Gastroenterol* 2009 [54]

**Competing interests:** None

## Institutions

- <sup>1</sup> Gastrointestinal Endoscopy Service, Gastroenterology Department, Clinics Hospital, University of Sao Paulo School of Medicine, Sao Paulo, Brazil
- <sup>2</sup> Surgical Division, Gastroenterology Department, Clinics Hospital, University of Sao Paulo School of Medicine, Sao Paulo, Brazil
- <sup>3</sup> Basil I. Hirschowitz Endoscopic Center of Excellence, Division of Gastroenterology and Hepatology, UAB School of Medicine, Birmingham, Alabama, USA

## References

- 1 Gay G, Delvaux M. Small-bowel endoscopy. *Endoscopy* 2008; 40: 140–146
- 2 Rustgi AK. Small intestinal neoplasms. In: Feldman M, Friedman LS, Brandt LI (eds.) *Sleisenger and Fordtran's gastrointestinal and liver disease*. 8<sup>th</sup> ed. New York, NY: Elsevier; 2006: 2703–2712
- 3 Cangemi DJ, Patel MK, Gomez V et al. Small bowel tumors discovered during double-balloon enteroscopy: analysis of a large prospectively collected single-center database. *J Clin Gastroenterol* 2013; 47: 769–772
- 4 Moglia A, Menciasci A, Dario P et al. Clinical update: endoscopy for small-bowel tumours. *Lancet* 2007; 370: 114–116
- 5 Kala Z, Válek V, Kysela P et al. A shift in the diagnostics of the small intestine tumors. *Eur J Radiol* 2007; 62: 160–165
- 6 Yamamoto H, Kita H, Sunada K et al. Clinical outcomes of double-balloon endoscopy for the diagnosis and treatment of small-intestinal diseases. *Clin Gastroenterol Hepatol* 2004; 2: 1010–1016
- 7 Kandulski A, Fry LC, Malfertheiner P. Detection of jejunal carcinoid in a patient with obscure-overt gastrointestinal bleeding by double-balloon enteroscopy. *Clin Gastroenterol Hepatol* 2008; 6: A26
- 8 Iddan G, Meron G, Glukhovsky A et al. Wireless capsule endoscopy. *Nature* 2000; 405: 417
- 9 Meron GD. The development of the swallowable video capsule (M2A). *Gastrointest Endosc* 2000; 52: 817–819
- 10 Ginsberg GG, Barkun AN, Bosco JJ et al. Wireless capsule endoscopy: August 2002. *Gastrointest Endosc* 2002; 56: 621–624
- 11 Yamamoto H, Sekine Y, Sato Y et al. Total enteroscopy with a nonsurgical steerable double-balloon method. *Gastrointest Endosc* 2001; 53: 216–220
- 12 Di Caro S, May A, Heine DG et al. The European experience with double-balloon enteroscopy: indications, methodology, safety, and clinical impact. *Gastrointest Endosc* 2005; 62: 545–550
- 13 Tsujikawa T, Saitoh Y, Andoh A et al. Novel single-balloon enteroscopy for diagnosis and treatment of the small intestine: preliminary experiences. *Endoscopy* 2008; 40: 11–15
- 14 Hartmann D, Eickhoff A, Tamm R et al. Balloon-assisted enteroscopy using a single-balloon technique. *Endoscopy* 2007; 39: E276
- 15 Akerman PA, Agrawal D, Cantero D et al. Spiral enteroscopy with the new DSB overtube: a novel technique for deep peroral small-bowel intubation. *Endoscopy* 2008; 40: 974–978
- 16 Pasha SF, Leighton JA, Das A et al. Double-balloon enteroscopy and capsule endoscopy have comparable diagnostic yield in small-bowel disease: a meta-analysis. *Clin Gastroenterol Hepatol* 2008; 6: 671–676
- 17 Liberati A, Altman DG, Tetzlaff J et al. The PRISMA statement for reporting systematic reviews and meta-analyses of studies that evaluate health care interventions: explanation and elaboration. *J Clin Epidemiol* 2009; 62: e1–e34
- 18 National Institute for Health Research. Welcome to PROSPERO: international prospective register of systematic reviews. Available from: <http://www.crd.york.ac.uk/prosperto/> (Accessed 20 October 2015)
- 19 Nakamura M, Niwa Y, Ohmiya N et al. Preliminary comparison of capsule endoscopy and double-balloon enteroscopy in patients with suspected small-bowel bleeding. *Endoscopy* 2006; 38: 59–66
- 20 Kameda N, Higuchi K, Shiba M et al. A prospective, single-blind trial comparing wireless capsule endoscopy and double-balloon enteroscopy in patients with obscure gastrointestinal bleeding. *J Gastroenterol* 2008; 43: 434–440
- 21 Marmo R, Rotondano G, Casetti T et al. Degree of concordance between double-balloon enteroscopy and capsule endoscopy in obscure gastrointestinal bleeding: a multicenter study. *Endoscopy* 2009; 41: 587–592
- 22 Whiting PF, Rutjes AW, Westwood ME et al. QUADAS-2: a revised tool for the quality assessment of diagnostic accuracy studies. *Ann Intern Med* 2011; 155: 529–536
- 23 Moses LE, Shapiro D, Littenberg B. Combining independent studies of a diagnostic test into a summary ROC curve: data-analytic approaches and some additional considerations. *Stat Med* 1993; 12: 1293–1316
- 24 Higgins JP, Thompson SG. Quantifying heterogeneity in a meta-analysis. *Stat Med* 2002; 21: 1539–1558
- 25 Arakawa D, Ohmiya N, Nakamura M et al. Outcome after enteroscopy for patients with obscure GI bleeding: diagnostic comparison between double-balloon endoscopy and videocapsule endoscopy. *Gastrointest Endosc* 2009; 69: 866–874
- 26 Fujimori S, Seo T, Gudis K et al. Diagnosis and treatment of obscure gastrointestinal bleeding using combined capsule endoscopy and double balloon endoscopy: 1-year follow-up study. *Endoscopy* 2007; 39: 1053–1058
- 27 Matsumoto T, Esaki M, Moriyama T et al. Comparison of capsule endoscopy and enteroscopy with the double-balloon method in patients with obscure bleeding and polyposis. *Endoscopy* 2005; 37: 827–832
- 28 Buscaglia JM, Richards R, Wilkinson MN et al. Diagnostic yield of spiral enteroscopy when performed for the evaluation of abnormal capsule endoscopy findings. *J Clin Gastroenterol* 2011; 45: 342–346
- 29 Partridge BJ, Tokar JL, Haluszka O et al. Small bowel cancers diagnosed by device-assisted enteroscopy at a U.S. referral center: a five-year experience. *Dig Dis Sci* 2011; 56: 2701–2705
- 30 Sethi S, Cohen J, Thaker AM et al. Prior capsule endoscopy improves the diagnostic and therapeutic yield of single-balloon enteroscopy. *Dig Dis Sci* 2014; 59: 2497–2502
- 31 Manno M, Riccioni ME, Cannizzaro R et al. Diagnostic and therapeutic yield of single balloon enteroscopy in patients with suspected small-bowel disease: results of the Italian multicentre study. *Dig Liver Dis* 2013; 45: 211–215
- 32 Fry LC, Neumann H, Kuester D et al. Small bowel polyps and tumours: endoscopic detection and treatment by double-balloon enteroscopy. *Aliment Pharmacol Ther* 2009; 29: 135–142
- 33 Vere CC, Foarfä C, Streba CT et al. Videocapsule endoscopy and single balloon enteroscopy: novel diagnostic techniques in small bowel pathology. *Rom J Morphol Embryol* 2009; 50: 467–474
- 34 Lee BI, Choi H, Choi KY et al. Clinical characteristics of small bowel tumors diagnosed by double-balloon endoscopy: KASID multi-center study. *Dig Dis Sci* 2011; 56: 2920–2927
- 35 Kamalapor N, Cho S, Basset N et al. Double-balloon enteroscopy following capsule endoscopy in the management of obscure gastrointestinal bleeding: outcome of a combined approach. *Can J Gastroenterol* 2008; 22: 491–495
- 36 Li XB, Ge ZZ, Dai J et al. The role of capsule endoscopy combined with double-balloon enteroscopy in diagnosis of small bowel diseases. *Chin Med J (Engl)* 2007; 120: 30–35
- 37 Ali R, Wild D, Shieh F et al. Deep enteroscopy with a conventional colonoscope: initial multicenter study by using a through-the-scope balloon catheter system. *Gastrointest Endosc* 2015; 82: 855–860
- 38 Rondonotti E, Pennazio M, Toth E et al. Small-bowel neoplasms in patients undergoing video capsule endoscopy: a multicenter European study. *Endoscopy* 2008; 40: 488–495
- 39 Riccioni ME, Cianci R, Urgesi R et al. Advance in diagnosis and treatment of small bowel tumors: a single-center report. *Surg Endosc* 2012; 26: 438–441
- 40 Honda W, Ohmiya N, Hirooka Y et al. Enteroscopic and radiologic diagnoses, treatment, and prognoses of small-bowel tumors. *Gastrointest Endosc* 2012; 76: 344–354
- 41 Chen WG, Shan GD, Zhang H et al. Double-balloon enteroscopy in small bowel tumors: a Chinese single-center study. *World J Gastroenterol* 2013; 19: 3665–3671
- 42 Zagorowicz ES, Pietrzak AM, Wronska E et al. Small bowel tumors detected and missed during capsule endoscopy: single center experience. *World J Gastroenterol* 2013; 19: 9043–9048
- 43 Postgate A, Despott E, Burling D et al. Significant small-bowel lesions detected by alternative diagnostic modalities after negative capsule endoscopy. *Gastrointest Endosc* 2008; 68: 1209–1214
- 44 Friedrich K, Gehrke S, Stremmel W et al. First clinical trial of a newly developed capsule endoscope with panoramic side view for small bowel: a pilot study. *J Gastroenterol Hepatol* 2013; 28: 1496–1501
- 45 Albert JG, Schülbe R, Hahn L et al. Impact of capsule endoscopy on outcome in mid-intestinal bleeding: a multicentre cohort study in 285 patients. *Eur J Gastroenterol Hepatol* 2008; 20: 971–977
- 46 Ross A, Mehdizadeh S, Tokar J et al. Double balloon enteroscopy detects small bowel mass lesions missed by capsule endoscopy. *Dig Dis Sci* 2008; 53: 2140–2143
- 47 Choi H, Choi KY, Eun CS et al. Korean experience with double balloon endoscopy: Korean Association for the Study of Intestinal Diseases multi-center study. *Gastrointest Endosc* 2007; 66: S22–S25
- 48 Schäfer C, Rothfuss K, Kreichgauer HP et al. Efficacy of double-balloon enteroscopy in the evaluation and treatment of bleeding and non-bleeding small bowel disease. *Z Gastroenterol* 2007; 45: 237–243
- 49 Pérez-Cuadrado E, Más P, Hallal H et al. Double-balloon enteroscopy: a descriptive study of 50 explorations. *Rev Esp Enferm Dig* 2006; 98: 73–81

- 50 Almeida N, Figueiredo P, Lopes S et al. Double-balloon enteroscopy and small bowel tumors: a South-European single-center experience. *Dig Dis Sci* 2009; 54: 1520–1524
- 51 Frantz DJ, Dellon ES, Grimm IS et al. Single-balloon enteroscopy: results from an initial experience at a US tertiary-care center. *Gastrointest Endosc* 2010; 72: 422–426
- 52 Akamatsu T, Kaneko Y, Ota H et al. Usefulness of double balloon enteroscopy and video capsule endoscopy for the diagnosis and management of primary follicular lymphoma of the gastrointestinal tract in its early stages. *Dig Endosc* 2010; 22: 33–38
- 53 Chong AK, Chin BW, Meredith CG. Clinically significant small-bowel pathology identified by double-balloon enteroscopy but missed by capsule endoscopy. *Gastrointest Endosc* 2006; 64: 445–449
- 54 Alexander JA, Leighton JA. Capsule endoscopy and balloon-assisted endoscopy: competing or complementary technologies in the evaluation of small bowel disease? *Curr Opin Gastroenterol* 2009; 25: 433–437