


Secukinumab-Induced Lymphocytic Colitis

Journal of Investigative Medicine High Impact Case Reports
Volume 10: 1–4
© 2022 American Federation for Medical Research
DOI: 10.1177/23247096221110399
journals.sagepub.com/home/hic


Siva Santosh Kumar Gandu, MD¹, Mohammad Hassaan Khan, MD¹, Anush Vasikaran, MD¹, and Sudha Pandit, MD¹

Abstract

Secukinumab an interleukin-17 (IL-17) monoclonal antibody inhibitor is currently approved for the treatment of rheumatological conditions, such as psoriasis and ankylosing spondylitis. Lymphocytic colitis, a phenotype of microscopic colitis, is a long-term inflammatory condition, is characterized by relapsing diarrhea. The specific entity of drug-induced lymphocytic colitis has been discussed with numerous individual cases being reported from around the world. Secukinumab has been linked with exacerbation of and de novo cases of inflammatory bowel disease. However, lymphocytic colitis in association with this drug has not been documented. The management of drug-induced lymphocytic colitis is complicated, as patients frequently exhibit spontaneous remission of symptoms. Removal of the offending agent has shown some benefit; however, some patients continue to exhibit symptoms months after drug cessation and washout. Although our patient's lymphocytic colitis was benign and responded to the cessation Secukinumab, it is an important diagnosis to consider in patients with new onset relapsing diarrhea treated with biologics.

Keywords

gastroenterology, rheumatology, immunology

Case

A 31-year-old white female was admitted with complaints of progressively worsening abdominal pain, diarrhea, nausea, fatigue, and anorexia for 10 weeks. She had a past medical history of type 2 diabetes mellitus, diagnosed in 2010 and treated with ertugliflozin, and psoriasis. The patient's psoriasis was unresponsive to treatment with topical steroids, systemic retinoids, and methotrexate. She was started on secukinumab 4 months prior to the hospitalization for diffuse abdominal pain and diarrhea. The abdominal pain had relieved after passing watery bowel movements. On examination, she had localized epigastric tenderness and scaling over erythematous patches on the knees and right elbow, consistent with a psoriatic rash. Her workup revealed a normal hemoglobin of 14.2 g/dL on arrival. Her inflammatory markers C-reactive protein (CRP) and erythrocyte sedimentation rate (ESR) were within normal limits. Normal tissue transglutaminase antibodies and IgA levels ruled out celiac disease. Stool studies were unremarkable along with fecal calprotectin. Ultrasound abdomen was unremarkable. Computed tomography (CT) abdomen pelvis with contrast was normal. Further workup with magnetic resonance cholangiopancreatography showed nonspecific dilation without evidence of choledocholithiasis. A colonoscopy was performed that was

unremarkable. Biopsies taken from the ascending and descending colon revealed lymphocytic colitis (Figures 1 and 2). Her pain, nausea, and vomiting resolved with supportive care during her hospital stay, and the patient was discharged in stable condition. Secukinumab was permanently stopped at discharge. The patient followed up at the primary care clinic and confirmed symptom resolution.

Discussion

Lymphocytic colitis, a phenotype of microscopic colitis, is a long-term inflammatory condition characterized by long-term diarrhea and normal or near normal colonic mucosa, with the presence of pronounced infiltration of the colonic mucosa by lymphocytes.^{1,2} It is a histopathological diagnosis characterized by intraepithelial lymphocytes, epithelial damage such as

¹Louisiana State University Health Sciences Center Shreveport, USA

Received April 24, 2022. Revised May 26, 2022. Accepted June 13, 2022.

Corresponding Author:

Sudha Pandit, Department of Internal Medicine, Louisiana State University Health Sciences Center Shreveport, 1501 Kings Hwy, Shreveport, LA 71105, USA.

Email: Sudha.pandit@lsuhs.edu



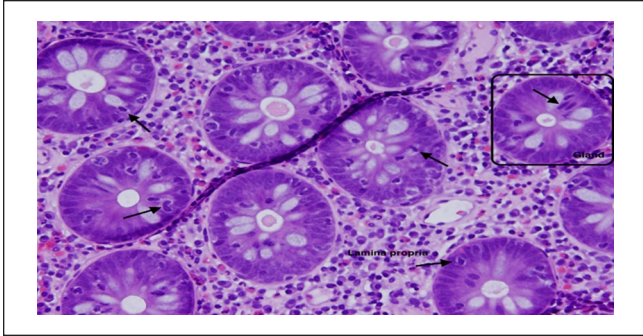


Figure 1. Image from right colon. Multiple glands/acini seen with intraepithelial lymphocytes (black arrows). “Block” seen surrounding a gland/acini. Lamina propria labeled between the glands/acini. Most glands/acini have at least 5-6 intraepithelial lymphocytes present, pathognomonic for lymphocytic colitis.

flattening and mucin depletion, and inflammation in the lamina propria with mainly mononuclear cells. Since its discovery, the reported prevalence rates of are 69 per 100 000 persons, making this disorder rare.³

Drug-induced lymphocytic colitis has been widely discussed with numerous individual cases reported from around the world. The most common culprits remain nonsteroidal anti-inflammatory drugs (NSAIDs) and proton pump inhibitors (PPIs), namely lansoprazole. Certain studies have reported NSAID use in 61% of patients with lymphocytic colitis, with other studies showing an increased incidence with concomitant multidrug usage.^{2,3} Other noteworthy agents of mention are Cyclo 3 fort, which was used for long-term venous insufficiency, acarbose, ticlopidine, flutamide, paroxetine, sertraline, and duloxetine.^{2,4,5} More recently, biological agents have been implicated in isolated cases of lymphocytic colitis. Pembrolizumab, used commonly for head and neck cancer, was reported to be associated with a case of lymphocytic colitis in a patient who was undergoing chemotherapy. Pembrolizumab has been linked to autoimmune colitis; however, this patient was discovered to have histopathological findings suggestive of lymphocytic colitis. The patient reported full resolution of his diarrhea soon after diagnostic colonoscopy.⁶ Another case report revealed teriflunomide, an agent used for the treatment of relapsing multiple sclerosis, to be linked to lymphocytic colitis. Teriflunomide is an active form of the drug leflunomide used to treat rheumatoid arthritis. The drug has reported gastrointestinal symptoms as potential adverse effects, which usually are self-limiting and alleviated with drug elimination and washout with cholestyramine. However, this patient continued to have long-term diarrhea 5 months after teriflunomide therapy was stopped along with subsequent washout with cholestyramine.⁷ Histopathological features were consistent with lymphocytic colitis.⁷ Ipilimumab, used for the treatment of advanced melanoma, was reported to have caused lymphocytic colitis. Previous studies have shown

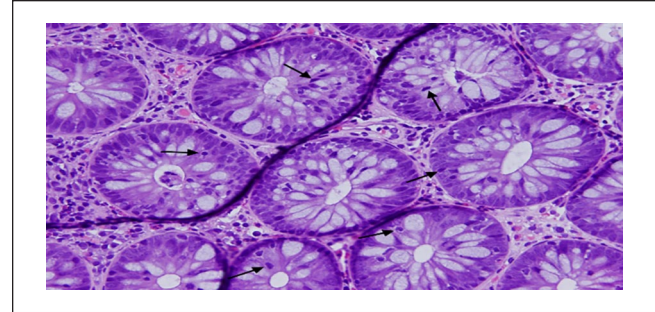


Figure 2. Image from left colon. Multiple glands/acini seen with intraepithelial lymphocytes (black arrows). Most glands/acini have at least 5-6 intraepithelial lymphocytes present, pathognomonic for lymphocytic colitis.

that ipilimumab can cause various degrees and forms of colitis, with one phase III trial revealing 4 drug-related deaths due to gastrointestinal perforation.⁸ In the only other study that evaluated colon pathology in patients taking ipilimumab, Berman evaluated 115 patients for colonic histology, of which the most frequent microscopic findings were focal cryptitis and neutrophilic infiltrates in the lamina propria.⁹

Many uncertainties lie regarding the mechanism of drug-induced lymphocytic colitis. We can hypothesize that LC could be attributed to the activation of CD25+ T-cells and expression of HLA-DR antigen by colonic epithelial cells. These findings are consistent with mucosal immune cell activation. In a study from 1994, Beaugerie performed serial examinations in patients with suspected LC secondary to Cyclo 3 fort.⁴ During the study, the patients underwent a rechallenge period after drug withdrawal.⁴ Diarrhea recurred during the rechallenge period and histopathological findings were suggestive of the involvement of HLA-DR antigen expression seen on epithelial cells.⁴

As mentioned earlier, the management of a patient with lymphocytic colitis has many variables due to its multifactorial cause and spontaneous remission of symptoms. In patients with suspected lymphocytic colitis, blood studies are usually within the reference range, but anemia, hypokalemia, hypoalbuminemia, and elevation of ESR may be present.³ Diagnosis is confirmed by biopsies obtained by sigmoidoscopy or colonoscopy. Classically under endoscopic visualization, the mucosa appears normal with mild mucosal edema.¹⁰ However, extensive linear “furrowed” mucosal patterns extending from the transverse colon to the rectum, with an elaborate mosaic pattern seen in the rectum, have been reported.¹⁰ In a study conducted by Hanyang University Guri Hospital in Korea, colonoscopy revealed macroscopic lesions associated with hypervascularity. In 6 of the 7 patients with macroscopic lesions, hypervascularity was observed, mainly in the descending colon.¹¹ There were some limitations in this study, which include a single center and a small number of patients.¹¹

Evaluating treatment options for lymphocytic colitis has also been impaired by the frequent occurrence of spontaneous remission of symptoms. Farrukh and Mayberry performed a systematic assessment of the available treatment options, unfortunately treatment is primarily based on anecdotal evidence and findings from double-blind randomized trials with budesonide.³ A trial of dietary restriction and avoidance of aggravating drugs can help alleviate symptoms in few patients, but many require medical therapy.^{3,12} Guidelines recommend induction with oral budesonide, however, loperamide may be used in mild lymphocytic colitis.¹² If patients fail therapy with budesonide, thiopurines, anti-tumor necrosis factor (TNF), or vedolizumab may be used to induce and maintain clinical remission. Surgery is the last option if all medical therapies fail.¹²

As previously mentioned, newer biological agents in isolated situations around the world are being implicated as a cause of lymphocytic colitis. Secukinumab, an interleukin (IL)-17 antagonist, with U.S. Food and Drug Administration (FDA) approval for treatment of psoriasis, psoriatic arthritis, and ankylosing spondylitis has been associated with inflammatory bowel disease (IBD). It has been linked to Crohn's disease exacerbation and de novo cases of IBD.^{13,14} What remains an uncertainty is the role of IL-17, as it is involved in the pathogenesis of inflammatory bowel disease, and this drug is a specific antagonist to the cytokine. This may suggest that IL-17 may carry a protective effect in inflammatory bowel disease. However, in our patient secukinumab was neither associated with the development of fulminant colitis nor inflammatory bowel disease. Pathology from the biopsies revealed lymphocytic colitis. The drug was held, followed by resolution of symptoms soon after. This is a unique case describing the onset of lymphocytic colitis in a patient with psoriasis on secukinumab. Although her lymphocytic colitis was benign and responded to the cessation of the drug, it is important to consider in patients with new onset diarrhea taking new biologics. Pembrolizumab, teriflunomide, ipilimumab, and secukinumab have all been demonstrated links to autoimmune colitis, gastrointestinal side effects, colitis, and inflammatory bowel disease; however, it is important to consider lymphocytic colitis as a potential adverse effect of these medications.

Declaration of Conflicting Interests

The author(s) declared no potential conflicts of interest with respect to the research, authorship, and/or publication of this article.

Funding

The author(s) received no financial support for the research, authorship, and/or publication of this article.

Ethics Approval

Our institution does not require ethical approval for reporting individual cases or case series.

Informed Consent

Verbal informed consent was obtained from the patient(s) for their anonymized information to be published in this article.

References

1. Boland K, Nguyen G. Microscopic colitis: a review of collagenous and lymphocytic Colitis. *Gastroenterol Hepatol.* 2017;13:671-677. <https://www.ncbi.nlm.nih.gov/pmc/articles/PMC5717882/>. Accessed March 5, 2022.
2. Piche T, Raimondi V, Schneider S, Hébuterne X, Rampal P. Acarbose and lymphocytic colitis. *Lancet.* 2000;356(9237):1246. [https://www.thelancet.com/journals/lancet/article/PIIS0140-6736\(00\)02797-5/fulltext](https://www.thelancet.com/journals/lancet/article/PIIS0140-6736(00)02797-5/fulltext). Accessed March 1, 2022.
3. Balagani H. Microscopic colitis (collagenous and lymphocytic colitis) treatment & management: approach considerations, medical care. *Medscape.* March 25, 2021. <https://emedicine.medscape.com/article/180664-treatment>. Accessed March 5, 2022.
4. Beaugerie L, Luboinski J, Brousse N, et al. Drug induced lymphocytic colitis. *Gut.* 1994;35(3):426-428. <https://gut.bmj.com/content/35/3/426>. Accessed February 20, 2022.
5. Gwillim EC, Bowyer BA. Duloxetine-induced lymphocytic colitis. *J Clin Gastroenterol.* 2012;46(8):717-718. https://journals.lww.com/jcge/Citation/2012/09000/Duloxetine_induced_Lymphocytic_Colitis.20.aspx. Accessed March 1, 2022.
6. Ahmed M, Francis G. Pembrolizumab-induced microscopic colitis. *Am J Gastroenterol.* 2018;113(4):629-630. https://journals.lww.com/ajg/Citation/2018/04000/Pembrolizumab_Induced_Microscopic_Colitis.31.aspx. Accessed February 15, 2022.
7. Son M, McEwan L, Ubaidat M, Bovell K, Morrow SA. Lymphocytic colitis in the setting of teriflunomide use for relapsing multiple sclerosis. *Mult Scler.* 2020;26(13):1801-1803. <https://pubmed.ncbi.nlm.nih.gov/32031458/>. Accessed February 20, 2022.
8. García-Varona A, Odze RD, Makrauer F. Lymphocytic colitis secondary to ipilimumab treatment. *Inflamm Bowel Dis.* 2011;19(2):E15-E16. <https://academic.oup.com/ibdjournal/article/19/2/E15/4604345>. Accessed February 15, 2022.
9. Romain PES, Salama AKS, Ferguson NL, Burbridge RA. Ipilimumab-associated lymphocytic colitis: a case report. *Transl Gastrointest Cancer.* 2015;5(1):44-46. <https://tgc.amegroups.com/article/view/8563/9649>. Accessed March 26, 2022.
10. Aggarwal A, Helper D. Macroscopic findings in lymphocytic colitis. *Clin Gastroenterol Hepatol.* 2014;12(8):E65-E66. [https://www.cghjournal.org/article/S1542-3565\(13\)01722-9/fulltext](https://www.cghjournal.org/article/S1542-3565(13)01722-9/fulltext). Accessed February 16, 2022.
11. Park HS, Han DS, Ro Y, Eun CS, Yoo K-S. Does lymphocytic colitis always present with normal endoscopic findings? *Gut Liver.* 2015;9(2):197-201. <https://www.gutnliver.org/journal/view.html?doi=10.5009/gnl13373>. Accessed February 16, 2022.
12. Miehke S, Guagnozzi D, Zabana Y, et al. European guidelines on microscopic colitis: United European Gastroenterology and European microscopic colitis group statements and recommendations. *United European Gastroenterol J.* 2021;9(1):13-37. <https://onlinelibrary.wiley.com/doi/10.1177/2050640620951905>. Accessed February 16, 2022.

13. Wang J, Bhatia A, Cleveland NK, et al. Rapid onset of inflammatory bowel disease after receiving secukinumab infusion. *ACG Case Rep J*. 2018;5(1):E56. <https://www.ncbi.nlm.nih.gov/pmc/articles/PMC6072803/>. Accessed February 17, 2022.
14. Ehrlich D, Jamaluddin N, Pisegna J, Padua D. A challenging case of severe ulcerative colitis following the initiation of secukinumab for ankylosing spondylitis. *Case Rep in Gastrointest Med*. 2018;2018:9679287.