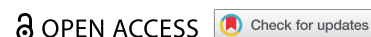

CASE REPORT



## Stemi mimicking post COVID: a case of focal myopericarditis post COVID infection

Muhammad Atif Masood Noori<sup>a</sup>, Abanoub Rushdy<sup>b</sup>, Hardik Fichadiya<sup>a</sup>, Roman Sherif<sup>b</sup>, Islam Younes<sup>a</sup>, Peter D. Lenchur<sup>c</sup>, Peter M. Lenchur<sup>d</sup> and Fayaz Shamoon<sup>b</sup>

<sup>a</sup>Department of Medicine, Rutgers New Jersey Medical School, Elizabeth, NJ, USA; <sup>b</sup>Department of Cardiology, St. Joseph's University Medical Center, Paterson, NJ, USA; <sup>c</sup>Department of Medicine, New York Medical College, Valhalla, NY, USA; <sup>d</sup>Department of Cardiology, Robert Wood Johnson University Hospital, Rahway, NJ, USA

### ABSTRACT

Since the beginning of the coronavirus disease 2019 (COVID19) pandemic, several cases of myocarditis related to COVID-19 infection have been reported. These cases range from asymptomatic disease to fulminant heart failure or sudden cardiac death. Cardiac injury has also been found in asymptomatic patients and patients who recovered from the disease. Data regarding cardiovascular involvement due to COVID-19 infection are still limited, and the actual prevalence of myocarditis due to COVID-19 infection is still unknown.

We present a case of focal myopericarditis in a patient recently recovered from COVID-19 pneumonia with electrocardiogram showing ST elevation in inferior and lateral leads.

This case highlights the need for studying the long-term cardiovascular complications of COVID-19 and reinforces the use of cardiac magnetic resonance (CMR) and cardiac biomarkers in the diagnosis of COVID-19-related myocarditis.

### ARTICLE HISTORY

Received 13 July 2021  
Accepted 10 September 2021

### KEYWORDS

COVID-related myocardial injury; myopericarditis; COVID-19; inflammatory cardiomyopathy; cardiac magnetic resonance (CMR)

## 1. Introduction

In December 2019, the first cases of coronavirus disease 2019 (COVID19) were identified in Wuhan, China, and subsequently, the virus spread rapidly and became a pandemic with severe impacts on public health.

Respiratory tract symptoms mainly characterize the clinical course of COVID19 infection; however, several extrapulmonary complications have been noticed. A broad spectrum of cardiovascular complications, including heart failure, arrhythmias, acute coronary syndrome, myocarditis, and cardiac arrest, have been reported. In some patients, cardiac injury has been reported without clinical features of respiratory disease, and in other patients, the injury happened even after complete recovery from the infection [1].

We present a case of focal myopericarditis involves the inferior-posterolateral wall at the base of the left ventricle in a patient recently recovered from COVID-19 pneumonia. Initial 12 lead electrocardiogram showed ST elevation in inferior and lateral leads.

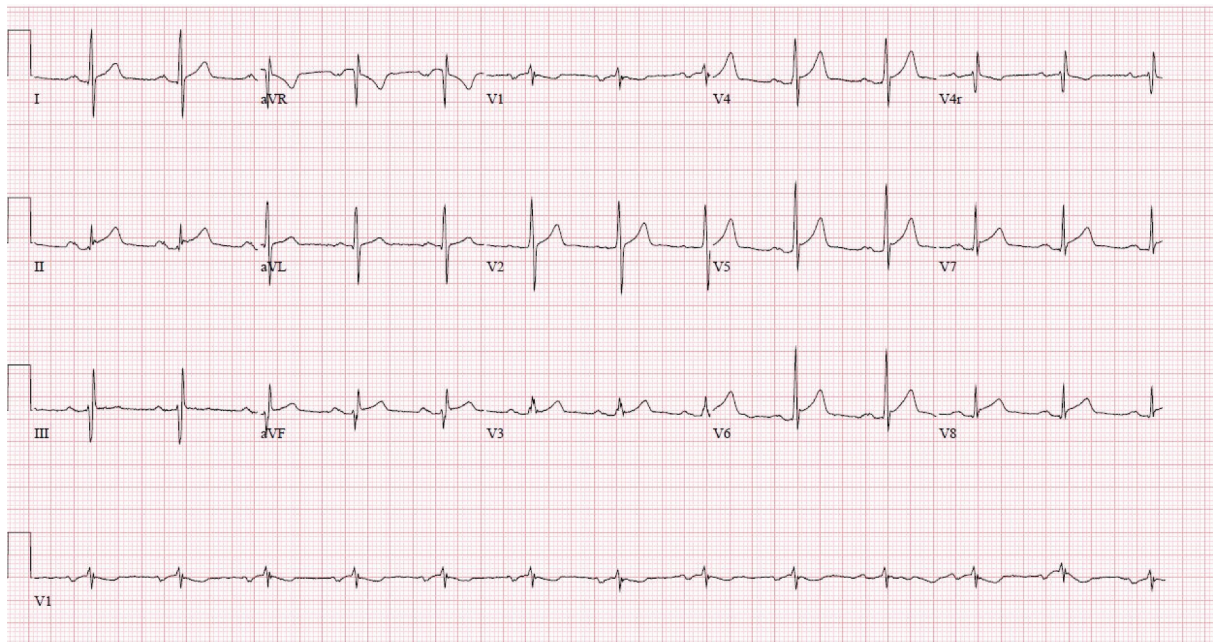
This case highlights the utility of CMR and biomarkers in the diagnosis of COVID-19-related myocarditis.

## 2. Case presentation

A 44-year-old male with a history of recent COVID-19 pneumonia was brought into our facility as an ST-elevation myocardial infarction (STEMI) alert. The patient was transferred to our emergency department from a nearby cardiology office as he was found to have ST elevation in anterolateral leads during his regular follow-up visit. The patient reported dry cough associated with generalized body ache but denied any chest pain, shortness of breath, palpitation, orthopnea, or fever.

The patient stated that he was diagnosed with COVID-19 pneumonia 1 month ago; however, it did not require hospitalization. He was also admitted to another hospital 2 weeks ago for non-ST-elevation myocardial infarction (NSTEMI), where he had cardiac catheterization showed no significant coronary artery disease.

Upon his arrival to the emergency department, he had a blood pressure of 139/82, pulse 76, respiratory rate 19, temperature 97.9 F, and oxygen saturation of 97% on ambient air. The initial 12 lead electrocardiogram showed concave-shaped ST elevation in inferior and lateral leads (Figure 1). CODE STEMI was activated, and the patient underwent emergent cardiac catheterization.



**Figure 1.** Electrocardiogram showing concave shaped ST- elevation in inferior and lateral leads.

The study showed no significant coronary artery disease and normal LV function. Laboratory examination was significant for Troponin 11.67, Erythrocyte sedimentation rate (ESR) 25, CRP 3.2, D-dimer 514, COVID antigen was positive; however, COVID-19 PCR was negative. A chest radiograph was unremarkable

Given cardiac catheterization showed no significant coronary artery disease, the patient was admitted with a presumed diagnosis of myopericarditis. He was started on aspirin (81 mg once daily), Clopidogrel (75 mg once daily) and colchicine (0.6 mg twice daily). The next day, his troponins started trending down, but ST-elevation persisted in inferior and lateral leads. A transthoracic echocardiogram (TTE) demonstrated left ventricular ejection fraction (LVEF) of 40–45%, mildly decreased globular left ventricular systolic function and moderate to severe hypokinesis involving inferior, inferoposterior wall without thinning of myocardium (Video 1 & 2). Enalapril (2.5 mg once daily) and carvedilol (3.125 mg twice daily) were added to the treatment regimen.

Cardiac MRI showed mild to moderately reduced LVEF (38%); moderate hypokinesis of midventricular inferolateral wall; edema/inflammation of epicardium and epicardial scar of basal anteroseptal and anterior wall and midventricular anterolateral, inferolateral and inferior wall (Video 3). Given patient was asymptomatic, his troponin levels continued to trend down, and ST-segment elevations became less prominent, patient was discharged to follow up with cardiology as an outpatient. Two weeks later, patient was seen in clinic and was noted to be completely asymptomatic

with EKG showing complete resolution of ST segment elevation.

### 3. Discussion

Cardiac manifestations of COVID 19 can range from myocarditis, heart failure, arrhythmias, sudden cardiac death, acute coronary syndromes, and arterial/venous thrombosis.

As per early reports from China, up to 7–20% of patients with COVID 19 were had elevated cardiac biomarkers or EKG abnormalities. Patients with myocardium involvement were found to have worse outcomes and significantly higher mortality compared to those without cardiac involvement (51% vs. 5%) [2].

Inflammatory cardiomyopathy is characterized by inflammatory cell infiltration into the myocardium and a high risk of deteriorating cardiac function. The most commonly known etiology is a viral infection, but it can also be caused by bacterial, fungal, or protozoal infections, toxic substances, and systemic immune-mediated disorders [3].

Severe acute respiratory syndrome coronavirus 2 (SARS-CoV-2/COVID 19) infection is now being recognized as an important cause of inflammatory cardiomyopathy [3]. As per our literature review, up to the 15th of February 2021 only a few cases of COVID-19 induced myocarditis have been reported [4].

The virus tends to gain entry into the human cells via Angiotensin-converting enzyme (ACE 2) receptors expressed on cardiac tissue, endothelial cells, lung alveolar cells, and gastrointestinal epithelial cells. ACE 2 receptor expression on cardiac cells is

up regulated in patients with heart failure putting them at a higher risk of cardiac complications [2].

COVID-19 associated myocarditis can have a widely variable presentation ranging from asymptomatic disease to fulminant congestive heart failure or sudden cardiac death [5]. It is typically seen post the acute phase of the illness, like in our patient. It can also occur in the absence of pneumonia [6].

Myo-pericardial involvement can be either diffuse or focal, and focal myocarditis typically involves the inferior-posterolateral wall at the base of the left ventricle, as in our case [5]. Presentations with both preserved and impaired left ventricular systolic dysfunction have been documented [4]. Our patient presented with decreased ejection fraction in addition to wall motion abnormalities.

Typical ECG findings of myocarditis are PR depression, ST elevation, down-sloping TP (Spodick's sign, best seen in inferior and lateral leads in stage 1), but new-onset bundle branch block, QT prolongation, pseudo-infarct pattern, premature ventricular complexes, and bradyarrhythmia with an advanced atrioventricular nodal block are documented [7].

Myo-pericarditis presents with rising troponin leaks due to myocardial inflammation and injury; however, other differentials in COVID-19 infection include acute coronary syndrome, pulmonary embolism, cerebrovascular accident, Takotsubo cardiomyopathy, or demand-supply mismatch in critically ill patients [2].

Regarding clinical presentation, focal ST elevation and troponin leak focal viral myopericarditis could not be indistinguishable from ST-elevation myocardial infarction (STEMI) without further workup.

Although endomyocardial biopsy (EMB) is the gold standard for diagnosis, it has a sensitivity of only 64%, is invasive, and is associated with significant adverse events like risk bleeding, infection, and cardiac arrhythmia. Cardiac MRI (CMR) is a noninvasive test with a sensitivity of 90% and is now the preferred modality for diagnosis [5].

In a German study, CMR revealed cardiac involvement in 78% and ongoing myocardial inflammation 60% of patients recently recovered from COVID-19 infection [1]. These results indicate the need for studying the long-term cardiac complications of COVID-19.

CMR for myocarditis can be interpreted using the lake Louis criteria, including edema; irreversible cell injury/necrosis; and hyperemia or capillary leak [8]. Our case had edema/inflammation and scarring of the epicardium along with LV hypokinesis and dysfunction.

The pattern of myocarditis on CMR includes an early myocardial enhancement ratio greater than 4.5 compared to skeletal muscles, intense T2 signals indicative of cardiac edema, and late gadolinium enhancement with a non-regional ischemic distribution. It

typically involves the epicardium towards the myocardium sparing the sub-endocardium, while myocardial infarction tends to involve the sub-endocardium [9].

Management includes the use of immunosuppression, steroids, and cytokine blockade (especially IL-6) [6]. We used colchicine for peri-myocarditis and goal-directed medical therapy for heart failure.

These patients are at increased risk of cardiac arrhythmia and dilated cardiomyopathy [2]. Therefore, a close watch and follow-up are needed.

#### 4. Conclusion

Cardiac complications related to COVID-19 infection such as myocarditis have frequently been reported. Early diagnosis of these complications is essential. Data regarding the relation between COVID-19 and cardiac complications are still limited. Further research is needed to evaluate the long-term cardiovascular consequences of COVID-19 and to establish the guidelines for the proper management of cardiovascular complications related to COVID-19.

#### References

- [1] Puntmann VO, Carerj ML, Wieters I, et al. Outcomes of cardiovascular magnetic resonance imaging in patients recently recovered from coronavirus disease 2019 (COVID-19). *JAMA Cardiol.* 2020;5(11):1265–1273.
- [2] Basu-ray I, Almaddah NK, Adeboy A, et al. Cardiac Manifestations Of Coronavirus (COVID-19). In: StatPearls [Internet]. Treasure Island (FL): StatPearls Publishing; 2021 Jan. 2021 May 19. PMID: 32310612, Bookshelf ID: NBK556152.
- [3] Tschöpe C, Ammirati E, Bozkurt B, et al. Myocarditis and inflammatory cardiomyopathy: current evidence and future directions. *Nat Rev Cardiol.* 2021;18(3):169–193.
- [4] Meel R, Ramsamy TD, Narsing R, et al. Focal myocarditis in a young male with SARS-CoV-2 infection. *Oxf Med Case Reports.* 2021;2021(2):omaa142.
- [5] Munguti CM, Akidiva S, Wallace J, et al. ST segment elevation is not always myocardial infarction: a case of focal myopericarditis. *Case Rep Cardiol.* 2017; 2017:3031792.
- [6] Pirzada A, Mokhtar AT, Moeller AD. COVID-19 and myocarditis: what do we know so far? *CJC Open.* 2020;2(4):278–285.
- [7] Caforio AL, Pankuweit S, Arbustini E, et al. Current state of knowledge on aetiology, diagnosis, management, and therapy of myocarditis: a position statement of the European society of cardiology working group on myocardial and pericardial diseases. *Eur Heart J.* 2013;34(33):2636–48, 2648a-2648d.
- [8] Inciardi RM, Lupi L, Zaccone G, et al. Cardiac involvement in a patient with coronavirus disease 2019 (COVID-19). *JAMA Cardiol.* 2020;5(7):819–824.
- [9] Mahrholdt H, Wagner A, Judd RM, et al. Delayed enhancement cardiovascular magnetic resonance assessment of non-ischaemic cardiomyopathies. *Eur Heart J.* 2005;26(15):1461–1474.