

MAGNETIC RESONANCE IMAGING OF THE NORMAL AND DISEASED FELINE MIDDLE EAR

INGRID ALLGOEWER, DVM, SUSANNE LUCAS, DVM, STEPHAN ALBERT SCHMITZ, MD

The magnetic resonance imaging appearance of the feline middle ear is described in three healthy cats and in five cats with middle ear disease. Owing to the good spatial resolution, multiplanar slice orientation as well as display high contrast resolution of soft tissue, in particular fluids, MR imaging was helpful prior to surgery. It is superior to radiography which failed to allow identification of the abnormality in two of our five cats. MR imaging for middle ear disease should include dorsal and transverse plane images using T1- and T2-weighted sequences. In the presence of a mass within the bulla or the external ear canal application of contrast medium is helpful. *Veterinary Radiology & Ultrasound*, Vol. 41, No. 5, 2000, pp 413-418.

Key words: magnetic resonance imaging, middle ear, bulla tympanica, cat.

Introduction

OTITIS MEDIA is a frequent diagnostic problem in daily veterinary practice.¹ The diagnosis of middle ear disease may be difficult because clinical signs may be masked by otitis externa or confused with otitis interna.² However it is important to establish the diagnosis of otitis media since it should be managed surgically to avoid chronicity and irreversible hearing deficits. The value of physical examination is limited by anatomy but otoscopy may reveal discharge, foreign bodies, polyps or neoplasia.³ Otitis media most commonly occurs across the tympanic membrane as a result of primary otitis externa. Other routes of involvement of the middle ear are either by hematogenous infection or the auditory tube.¹ The otoscopic observation of the tympanic membrane was long considered to be crucial for the diagnosis of middle ear disease⁴ and the presence of a ruptured tympanic membrane is a strong indicator for middle ear involvement. However otoscopy may be misleading since an intact tympanic membrane does not eliminate middle ear disease⁵. Radiography is useful in chronic infection but may be normal in early or mild infections. Therefore it is not regarded as a highly sensitive tool in the diagnosis of middle ear disease.^{1,6,7} In humans, high resolution computed tomography (CT) and magnetic resonance (MR) imaging have replaced radiography in the diagnosis of

middle ear disease. High resolution CT allows tomographic visualization of the temporal bone with approximately 1 mm slice thickness and an in-plane resolution of less than 1 mm. CT may outperform MR imaging owing to the superb bone detail. When compared to MR imaging, however, CT is not as sensitive for evaluating the soft tissues.⁸ The objective of this study was to describe the MR imaging appearance of the feline middle ear in three normal cats and in five cats with clinical signs of middle ear disease.

Materials and Methods

Survey skull radiography using ventrodorsal, lateral and open-mouth views, as well as results of routine laboratory analysis, were available in all animals. Cranial MR imaging was performed in three cats without clinical evidence of middle ear disease (cats 1-3) and in five with clinical or radiographic signs of otitis media (cats 4-8). Images were obtained with a 2.3 T magnet* using a standard small animal coil. A proton density weighted turbo spin-echo pulse sequence with a repetition time (TR) of 1000 ms, an echo time (TE) of 13.6 ms, turbo factor (TF) of 8 and a single signal average was used as a localizer. The animals were sedated with ketamin and acepromacine and positioned in dorsal recumbency. T2-weighted images were acquired using a turbo spin-echo sequence at a TR of 4000 ms, TE of 30 ms, TF of 4 and 2 averages. T1-weighted spin echo (SE) images were acquired at a TR of 400 ms, TE of 15 ms, TF 1 and also 2 averages before and after administration of 0.2 mmol/kg gadolinium-DPTA.† The slice thickness was 3 mm. The MR images were acquired in dorsal, sagittal and transversal planes.

From the Klinik und Poliklinik fuer kleine Haustiere an der Freien Universitaet Berlin (Director: L. Brunnberg) (Allgoewer), Radiologische Klinik und Poliklinik, Abteilung fuer Radiologische Diagnostik und Nuklearmedizin am Universitaetsklinikum Benjamin Franklin (Director: K.-J. Wolf) (Lucas, Schmitz).

Address correspondence and reprint requests to Dr. Ingrid Allgoewer, Klinik fuer kleine Haustiere an der FU Berlin, Oertzenweg 19b, D-14163 Berlin, Germany.

Received June 14, 1999; accepted for publication December 7, 1999.

*Biospec (Bruker, Karlsruhe, Germany).

†(Magnevist®, Schering AG, Berlin).

The five diseased cats subsequently underwent ventral bulla osteotomy. In each cat tissue and fluid within the bulla tympanica was obtained and submitted for cytologic and histologic examination, as well as for culturing. The MR images of these five cats were analyzed qualitatively, compared to the three supposedly normal cats and to the MR imaging appearance of the middle ear in humans with otitis media.

Results

Cats 1-3

Both bullae could be evaluated and compared in dorsal and transverse planes. The aerated vertical and horizontal portion of the external auditory canal as well as the bulla itself could be seen in their full extent. Both compartments of the bulla were clearly distinguished since the thin separating bony lamella could clearly be seen (Fig. 1-3). The larger ventromedial as well as the smaller dorsolateral part of the bulla were airfilled. The inner ear structures were outlined and the semicircular canal could be identified. Due

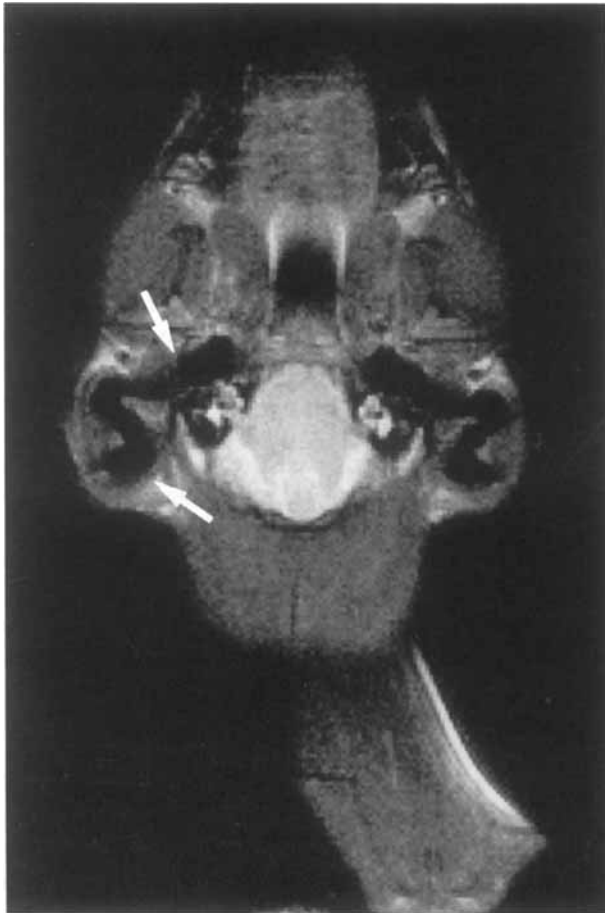

FIG. 1. Normal cat, dorsal plane, T2-weighted (TSE 4000/30) image. The horizontal (rostral arrow) and vertical portion (caudal arrow) of the external ear canal are seen.

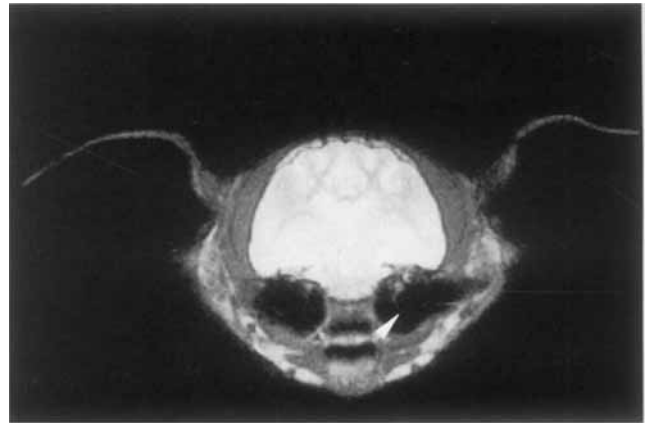


FIG. 2. Normal cat, transverse plane, T2-weighted (TSE 4000/30) image. A bony lamella within the bulla tympanica (arrow head) was identified.

to the high fluid content the inner ear structures appeared of high signal intensity on T2-weighted images.

Cat 4

A 15-month-old neutered female Domestic Shorthair cat had unilateral chronic otitis externa which had been treated for several months. On otoscopic examination purulent discharge was present in the right ear canal and a polypous mass could be identified in the vertical portion of the canal. General examination, complete blood count (CBC) and serum biochemistry were normal and testing for FeLV/FIV was negative. On the ventrodorsal skull radiograph the right bulla tympanica had a soft tissue opacity. On the lateral view the bony wall of the right bulla was thicker compared to the left one. MR imaging was performed to characterize and identify the extent of the mass within the right external auditory canal prior to surgery. The presence of a soft tissue mass within the right external auditory canal was confirmed

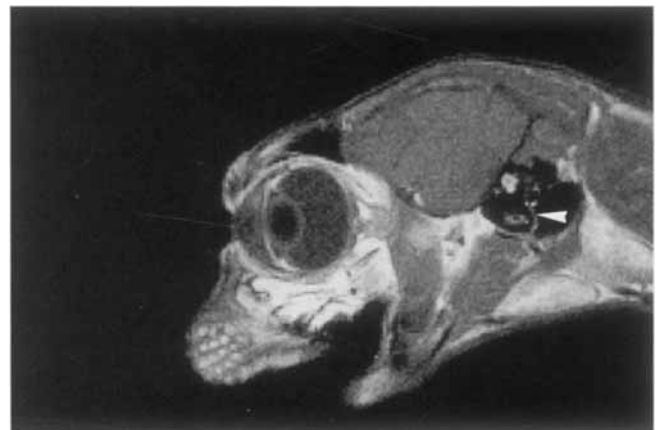


FIG. 3. Normal cat, saggital plane, T1-weighted (SE 600/15) image. In this image the bony lamella separating the ventromedial and dorsolateral compartment is visualized (arrow head).

and also soft tissue material was present within the right bulla tympanica. The osseous bulla itself was conserved and of regular shape. The mass was well circumscribed, extended into the dorsolateral compartment of the bulla, and had medium signal intensity on the T1- and higher signal intensity (i.e., fluid) on the T2 weighted images (Fig. 4). The left sided bulla appeared to be normal.

A right lateral ear canal resection combined with a ventral bulla osteotomy was performed. The mass could be excised from the innermost site of the vertical portion of the external ear canal. It was solid and of white to light yellow color. The tissue within the bulla had the same macroscopic appearance. Some milky, grey fluid could be obtained. *Streptococcus canis* and *Pasteurella canis* were isolated in high concentrations. Upon histologic examination the mass was classified as a malignant melanoma. Recovery of the cat was uneventful. Fifteen months after surgery the cat is clinically normal.

Cat 5

A two-and-a-half year-old neutered male Domestic Shorthair cat had ataxia, apathy and inappetence with a duration of one week. On clinical examination the cat also had a peripheral vestibular syndrome on the right side (head tilt, ataxia). There was a slight hyperglobulinemia (total protein 8.83 g/dl, albumin 3.2 g/dl). Serologic testing for FeLV/FIV was negative. The otoscopic examination was unremarkable. Radiographically, there was a soft tissue

opacity of the right bulla tympanica. On MR imaging opacification of the bulla was confirmed. The material in the bulla was inhomogenous and hyperintense to muscle on T2 consistent with a high water content (Fig. 5). The left bulla appeared normal. Right ventral bulla osteotomy was subsequently performed. Yellow milky flocculent fluid leaked out through the perforation in the ventral bony wall. Cytologically there were numerous inflammatory cells. No organisms were isolated. Recovery was uneventful. Fourteen months later the cat is clinically normal.

Cat 6

A 13-year-old neutered male Domestic Shorthair cat had chronic left otitis externa. The referring veterinarian had noticed a mass in the left ear canal. The cat had been treated for chronic left uveitis with secondary glaucoma. Except for the ocular and aural problems the cat appeared normal. Otoscopically there was a small red mass covered with tenacious discharge in the horizontal portion of the left ear canal. There was hyperglobulinemia (total protein: 9.27 g/dl, albumin: 3.9 g/dl). Serologic testing was negative for FeLV and positive for FIV. Coronavirus titers were within normal limits (<1:400). On radiographs the bony wall of the left tympanic bulla was thickened. MR imaging was performed to characterize the mass in the left ear canal and evaluate its extent. The entire left tympanic bulla was filled with an inhomogenous tissue formation which was isointense to cerebrum on T2 weighted images. When compared to the right side which seemed to be normal the left bulla was not enlarged (Fig. 6). After MR imaging a left lateral ear canal

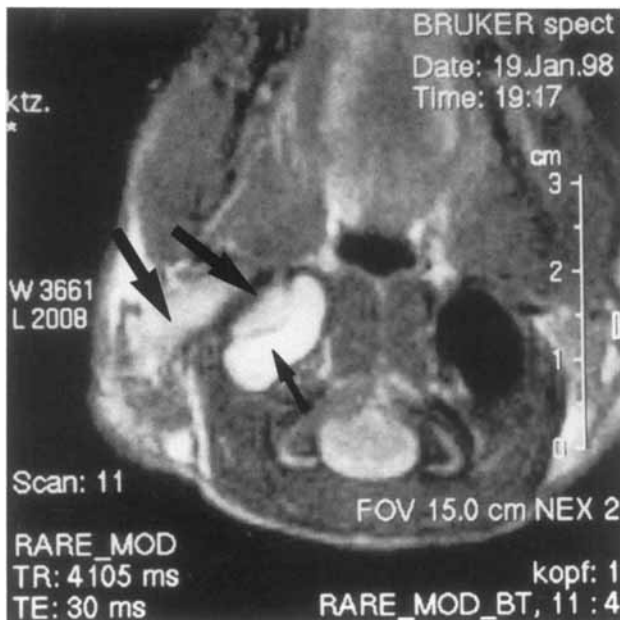


FIG. 4. Cat No. 4: Melanoma of the external auditory canal (lateral-most large arrow) extending into the dorsolateral compartment of the bulla (arrow), transverse plane, T2-weighted image (TSE 4000/30). The signal intensity of the ventromedial compartment is of higher signal (arrow) and was thought to be fluid which was confirmed at surgery.

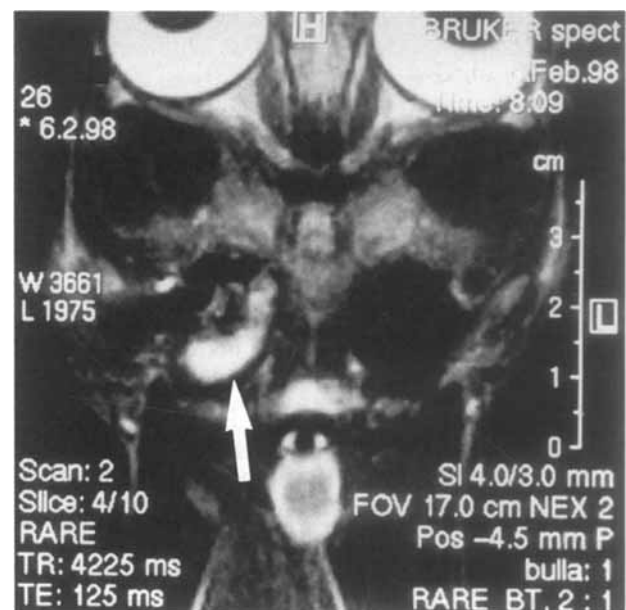


FIG. 5. Cat No. 5: Chronic otitis media, dorsal plane T2-weighted image (TSE 4000/30). Note the hyperintense bulla contents, compatible with mucosal swelling and/or fluid retention (arrow).

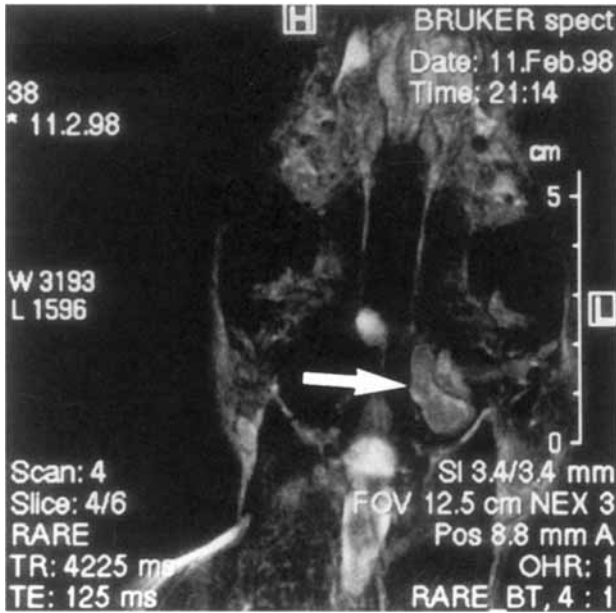


FIG. 6. Cat No. 6: Chronic lymphocytic otitis media, dorsal plane T2-weighted image (TSE 4000/30). There is evidence of obstruction of the bulla. The bulla contents were isointense to cerebrum and hypointense to cerebrospinal fluid.

resection was combined with a ventral bulla osteotomy. Upon drilling an opening into the ventromedial compartment of the bulla milky fluid exuded. The tissue obtained from the bulla as well as from the external ear canal was well vascularized. *Staphylococcus epidermidis* was isolated in a high concentration. The histologic diagnosis of the tissue samples was chronic granulation tissue with massive infiltration of immunocytes and marked mucosal epithelial hyperplasia. Recovery was uneventful. Thirteen months after surgery there was no regrowth of tissue. Recurrent episodes of otitis externa resolved with antibiotic treatment.

Cat 7

An 8-month-old female Domestic Shorthair cat had chronic pharyngeal stridor. A polyp was identified in the nasopharynx. On general examination the cat seemed otherwise healthy. Otoscopic examination was unremarkable. CBC and serum biochemistry were normal and testing for FeLV/FIV was negative. In skull radiographs the bullae appeared normal. MR imaging was performed to evaluate the extent of the nasopharyngeal polyp. A mass with a size of 3.5×1.5 cm was identified in the nasopharynx. On T2 weighted images the mass was inhomogeneous. It was capsulated, isointense to muscle (T1) and had an inhomogeneous and hypointense center. A thin stalk of tissue continued into the left tympanic bulla. The capsule of the pharyngeal tumor as well as the stalk to the bulla was characterized by strong marginal enhancement after administration of gadolinium-DTPA. The center showed no contrast enhancement, most

likely indicating cavitation (Fig. 7A,B). The bulla was not enlarged and its bony structure was conserved. After extraction of the pharyngeal mass via an oral approach with splitting of the soft palate a left ventral bulla osteotomy was performed. The entire ventromedial compartment of the left tympanic bulla was filled with white firm inhomogeneous tissue. Organisms were not isolated. The histologic diagnosis of the nasopharyngeal tumor was mucosal polyp with fibrous as well as glandular parts and lymphoid follicles. The samples from the left bulla were histologically diagnosed as polypous which contained areas of chronic purulent inflammation with necrosis and granulation tissue. Ten months after surgery the cat is clinically normal.

Cat 8

A 10-year-old neutered female Domestic Shorthair cat had chronic rhinitis and right sided otitis externa. According to the owner a mass had been extracted from the right ear some years ago. On clinical examination the cat had signs of rhinitis and right sided purulent aural discharge. On oto-

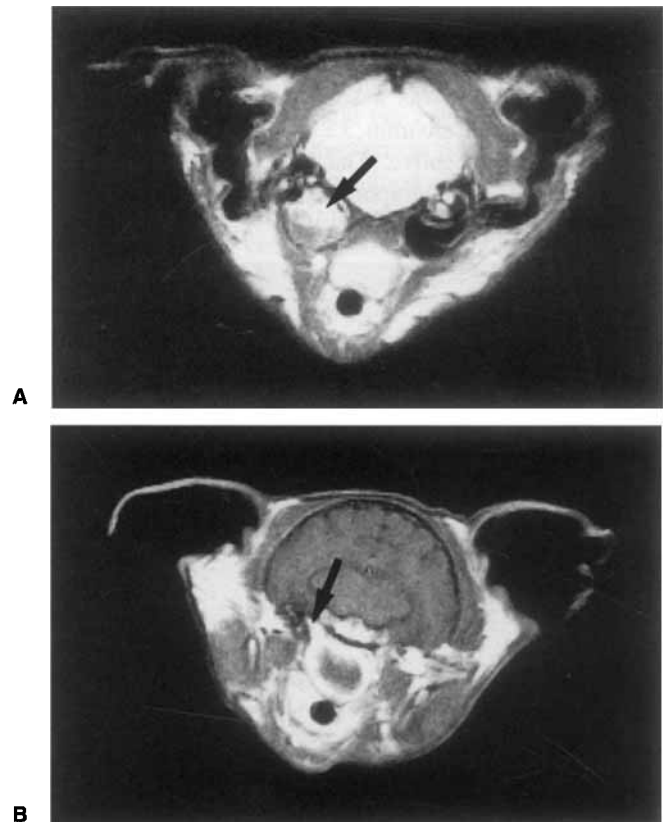


FIG. 7. (A) Cat No. 7: Inflammatory polyp, transverse plane (TSE 4000/30). There is an inhomogeneous mass occupying the entire bulla (arrow). (B) Same cat as Fig. 7A: Inflammatory polyp, transverse plane T1-weighted image (SE 600/15). A huge pharyngeal pedunculated contrast-enhanced mass is seen. There is marginal contrast enhancement. The arrow indicates the location of the stalk. The contrast medium allows clear distinction between vascularized mucosa and non-vascularized structures.

scopic examination a small yellow mass was visible in the right horizontal part of the ear canal. CBC and serum biochemistry were normal, serologic testing for FeLV/FIV was negative. In radiographs of the skull there were no abnormalities in the area of the bullae. MR imaging confirmed an inhomogenous mass in the horizontal ear canal with contrast enhancement after administration of gadolinium-DTPA. The dorsolateral compartment of the bulla was filled with a similar material, the ventromedial compartment was free of abnormal contents (Fig. 8A,B). Right lateral ear canal resection and ventral bulla osteotomy was performed subsequently. A mass of light red color was resected from the external ear canal. It appeared to originate from the tympanic membrane. Macroscopically the tissue encountered in the small compartment of the bulla resembled the tumor in the ear canal. Organisms were not isolated. Histological diagnosis of the tissue samples was chronic inflammatory polyp with reactive mucosal epithelial hyperplasia. Recovery after surgery was uneventful. Five months after surgery the cat is clinically normal.

Discussion

In people, computed tomography is reported to be the diagnostic tool of choice in middle ear disease.⁸ In a small series of cats computed tomography allowed identification of the presence and extent of nasopharyngeal polyps.⁶ However MR imaging may provide supplementary information in those animals where an accurate diagnosis cannot be established by CT. This report describes the normal MR imaging appearance of the middle ear in the cat as well as in five feline patients with pathologic conditions involving the middle ear. The feline bulla tympanica differs anatomically from that in the canine.^{10,12} It consists of a larger ventromedial and a smaller dorsolateral compartment and is divided by a very thin bony lamella. On MR imaging the ventromedial and dorsolateral compartment as well as the thin bony lamella were well visualized in normal cats as well as in the diseased cats. In all cats with signs of middle ear disease on MR imaging the diagnosis was confirmed surgically.

Especially helpful were transverse and dorsal plane images as they allowed comparison of the two sides. All five cats had unilateral involvement of the middle ear. Therefore comparison between the affected and unaffected side was possible with the normal side serving as a reference. Filling of the bulla tympanica with fluid or a mass was the most reliable MR finding. The obstructed compartment could be clearly identified with all sequences. In humans, mucosal swelling of the paranasal sinuses is a frequent finding. It is characterized by a thickening and visualization mucosal lining of the paranasal cavities. The signal intensity of the thickened mucosa is high on T2-weighted and intermediate on T1-weighted images with marked enhancement following administration of intravenous contrast medium.¹³ In our

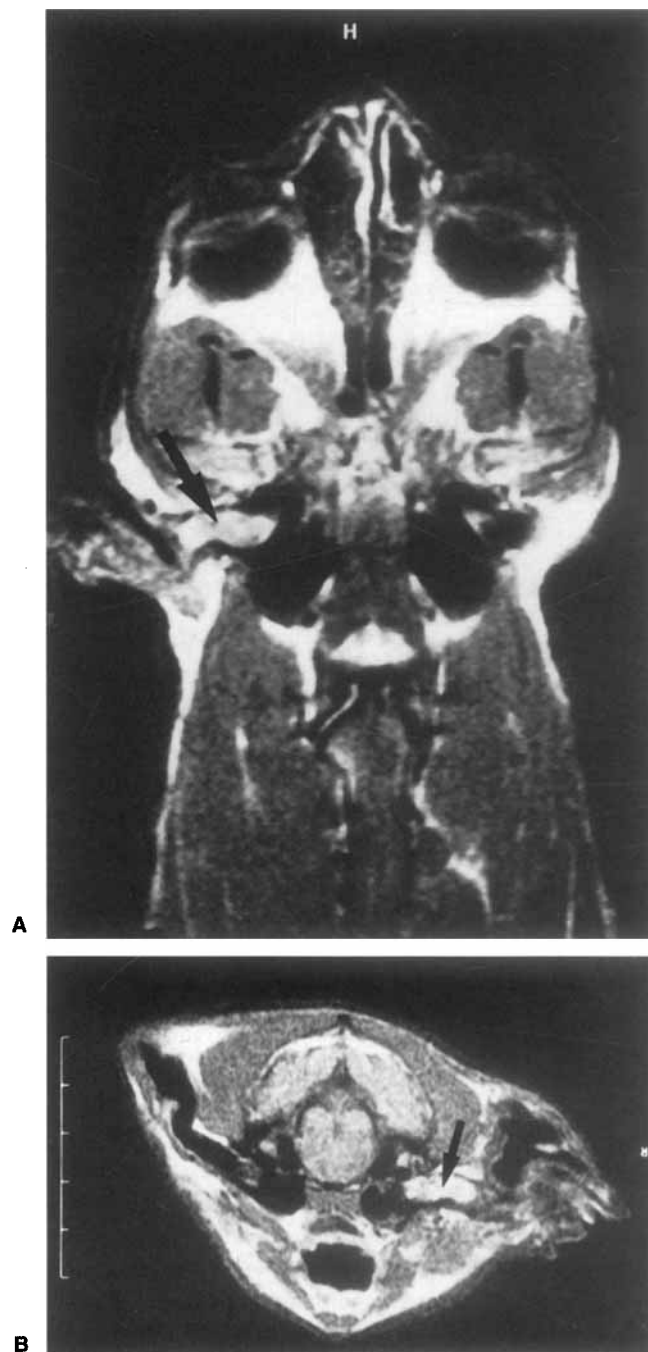

FIG. 8. (A) Cat No. 8: Chronic otitis media, dorsal plane moderately T1-weighted image (SE 340/26). There is an inhomogenous, contrast enhancing mass in the horizontal ear canal and the dorsolateral compartment of the bulla (arrow). (B) Same cat as in Fig. 8A: Chronic otitis media, transverse plane moderately T1-weighted image (SE 340/26). There is an inhomogenous, contrast enhancing mass in the horizontal external auditory canal and the dorsolateral compartment of the bulla (arrow).

study, however, we could not differentiate mucosal swelling from fluid retention on the basis of T2-weighted images. We speculate that the small size of the external auditory canal may have resulted in our inability to differentiate between

mucosa and fluid retention on T2-weighted images owing to partial volume effects. Contrast enhancement was observed in an inflammatory polyp and in thickened mucosa (cat 7). Contrast enhancement allowed these entities to be differentiated from mucus. In the two cats with inflammatory polyps, the uptake of contrast medium was especially strong. The only malignant tumor in our series, the melanoma, did not have accumulation of contrast medium. Based on our experience with MR imaging in five cats with middle ear disease and three control animals, it allowed a precise description of the presence and extent of the disease process.

Similar to the experiences in humans, MR imaging also allowed differentiation between solid and fluid structures. However solid soft tissue masses due to granulomatous proliferations and polyps which are frequently encountered in chronic otitis media could not be differentiated from a solid malignant tumor in our small series. Based on our first experience MR imaging may be a problem solving tool in the evaluation of feline middle ear disease. It is superior to radiography which was not diagnostic in two of our five cats.

REFERENCES

1. Remedios AM, Fowler JD, Pharr JW. A comparison of radiographic versus surgical diagnosis of otitis media. *J Am Anim Hosp Assoc* 1991; 27:183-188.
2. Spruell JS. Treatment of otitis media in the dog. *J Small Anim Pract* 1964;5:107-122.
3. Neer TM. Otitis media. *Comp Cont Ed* 1982;4:410-417.
4. Shell LG. Otitis media and otitis interna. *Vet Clin North Am Small Anim Pract* 1988;18:885-899.
5. Harvey CE. Disease of the middle ear. In: Slatter D. *Textbook of small animal surgery*, 1st ed. Philadelphia: WB Saunders, 1985.
6. Seitz SE, Losonsky JM, Marretta SM. Computed tomography appearance in inflammatory polyps in three cats. *Vet Radiol Ultrasound* 1996;37:99-104.
7. Hoskinson JJ. Imaging techniques in the diagnosis of middle ear disease. *Sem Vet Med Surg (Small Animal)* 1993;8:10-16.
8. Czerny C, Turtschek K, Duman M, Imhof H. [Imaging of the middle ear. CT and MRI.] *Radiologe* 1997;37:945-953.
9. Myer W. Cranial vault and associated structures. In: Thrall DE. *Textbook of veterinary diagnostic radiology*, 3rd ed. Philadelphia: WB Saunders.
10. Little CJL, Lane JG. The surgical anatomy of the feline bulla tympanica. *J Small Anim Pract* 1986;27:371-378.
11. Hoskinson JJ. Imaging techniques in the diagnosis of middle ear disease. *Sem Vet Med Surg (Small Animal)* 1993;8(1):10-16.
12. Hartmann FD, König HE. [On the topographical anatomy of the bulla tympanica of the cat.] *Wien Tieraerztl Mschr* 1993;80:311-315.
13. Yoshioka H, Kamada T, Kandatsu S, Koga M, Yshikawa K, Matsuoka Y, Mizoe J, Itai Y, Tsujii H. MRI of mucosal malignant melanoma of the head and neck. *J Comput Assist Tomogr* 1998;22:492-497.